

**TERRA FIRMA-FORME DERMATOSIS. A CASE REPORT**

Anagha Ramesh Babu, Metikurke Vijayashankar

*MVJ Medical College and Research Hospital, Bangalore, India***Source of Support:**

Nil

**Competing Interests:**

None

**Corresponding author:** Dr. Anagha Ramesh Babu[anagha27888@gmail.com](mailto:anagha27888@gmail.com)

Our Dermatol Online. 2013; 4(1): 89-90

Date of submission: 05.09.2012 / acceptance: 10.10.2012

**Abstract**

Terra firma-forme dermatosis is a cutaneous discoloration. 'Dirty' brown grey cutaneous patches and plaques that can be rid off by forceful swabbing with alcohol pads characterize it. The pathogenesis has been attributed to abnormal and delayed keratinization. It poses no medical threat. A 40-year-old male patient presented to the Department of Dermatology with a 2-3 month history of persistent pigmented patches on both upper arms. The lesions were not associated with itching or burning sensation. He gives no history of exacerbation on exposure to the sun.

**Key words:** Terra firma-forme; Duncan dermatosis; isopropyl alcohol**Cite this article:***Anagha Ramesh Babu, Metikurke Vijayashankar: Terra Firma-forme Dermatoses. A case report. Our Dermatol Online. 2013; 4(1): 89-90***Introduction**

Terra firma-forme dermatosis is a cutaneous discoloration. 'Dirty' brown grey cutaneous patches and plaques that can be rid off by forceful swabbing with alcohol pads characterize it. The pathogenesis has been attributed to abnormal and delayed keratinization. It poses no medical threat.

**Case Report**

A 40-year-old male patient presented to the Department of Dermatology with a 2-3 month history of persistent pigmented patches on both upper arms. The lesions were not associated with itching or burning sensation. He gives no history of exacerbation on exposure to the sun. The patient is on treatment for diabetes mellitus since 6 months.

On examination there were brownish-pigmented patches measuring around 6 x 7 cms present on the lateral aspect of both upper arms. The lesions had islands of normal skin (Fig. 1). They could be rubbed off with isopropyl alcohol (70%) over 2 sittings. (Fig. 2) A KOH mount was negative. A 3.5 mm punch biopsy was taken from the lesion.

**Histopathological examination revealed:**

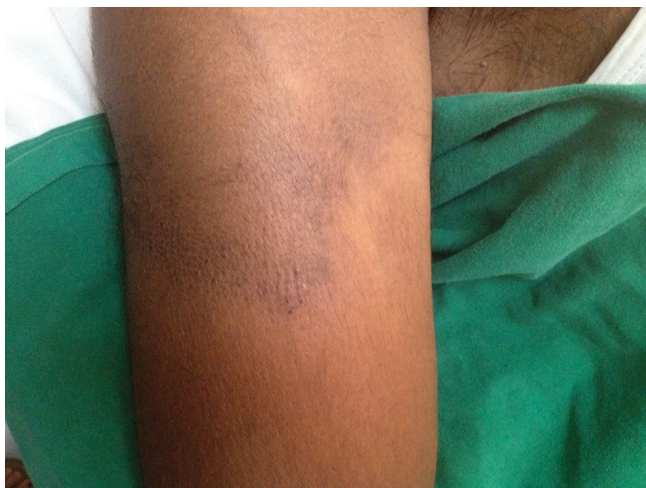The epidermis was characterized by hyperkeratosis. Mild increase in melanin and melanin incontinence in the keratinocytes was present in the papillary dermis (Fig. 3). There was also perivascular and periadnexal chronic inflammatory infiltrate. Other features like focal areas of compact whorled orthokeratosis were present (Fig. 4).

**Discussion**

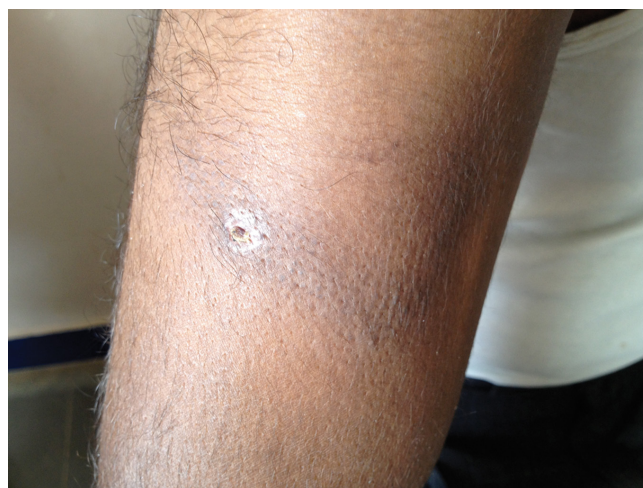Terra firma-forme dermatosis (TFFD) is a benign disorder of keratinization characterized by retention hyperkeratosis,

presenting as dirt-like plaques, despite normal hygiene. This condition is under-reported in the dermatology literature but may be more common in the general population. This type of dermatosis was first described in the 20th century. It derives its name from the Latin phrase 'terra firma' that means dry land. It has been referred to as 'DUNCAN' DIRTY DERMATOSIS after the physician who described in 1987 [1]. It is characterized by dirt-like muddy brown discoloration, which cannot be removed with just water, requires detergent to do the same. This condition has most often been seen in children, also in adults with equal incidence in males and females. It most commonly involves the neck and trunk followed by limbs, scalp, axillary line and pubic regions [1]. Differential diagnosis includes acanthosis nigricans, Gougerot and Carteaud confluent and reticulated papillomatosis [2], pityriasis versicolor, epidermal nevi, dirty neck syndrome of atopic dermatitis and dermatosis neglecta (DN) [3]. TFFD is distinguished from Dermatitis Neglecta arbitrarily by presence of adequate hygiene, absence of cornflake-like brownish scales and successful eradication of pigmentation with isopropyl alcohol in the former and effective clearance of lesions with soap and water in the latter. However, isopropyl alcohol is operative in both disorders. Histologically, DN is similar to TFFD, except for the absence of whorled hyperkeratosis in DN [3]. Nevertheless, the distinction between TFFD and DN is blurred and there seems to be a considerable clinical and histological overlap between the two disorders.

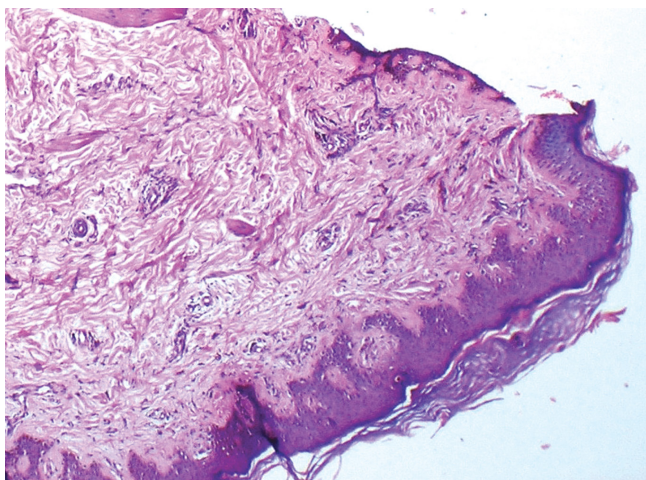
The diagnosis is made with a single wipe of the affected area using an alcohol-soaked cotton ball. The dermatosis often wipes off with the pad soaked in 70% alcohol [4].



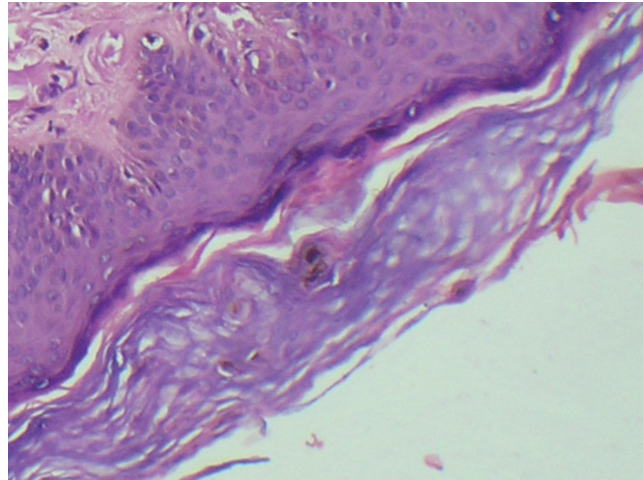
**Figure 1. Brownish pigmented patches**



**Figure 2. After wiping with Isopropyl alcohol, biopsy site**



**Figure 3. Hyperkeratosis with periadnexal and perivascular inflammatory infiltrate**



**Figure 4. Whorled orthokeratosis**

One hypothesis portrays TFFD as a disorder of abnormal and delayed keratinization and incriminates incomplete keratinocyte maturation, melanin retention and buildup and compaction of scales in the pathogenesis. TFFD represents retention, rather than a proliferative hyperkeratosis [3]. Some reports have focused on sunlight exposure as a triggering factor [3].

Existing data does not support a familial predominance or genetic susceptibility [4].

Patient with extensive terra firma forme dermatosis and their families were educated regarding cleaning the skin at home. After removal of pigmentation with isopropyl alcohol, discoloration usually does not recur. However, if it does, one may simply apply alcohol once a week to keep the skin clear [2].

## Conclusion

Awareness of Terra firma-forme dermatosis and timely diagnosis prevents unnecessary investigations like biopsy and extensive endocrine evaluation. This cosmetically distressing condition brings relief to the patient after prompt treatment by application of isopropyl alcohol.

## Acknowledgement

Dr. Sujatha C, Professor and Head of the Department of Dermatology, MVJ Medical College and Research Hospital, Bangalore.

Dr. Padmini Jeyachandran, Professor and Head of the Department of Pathology, MVJ Medical College and Research Hospital, Bangalore.

Principal, MVJ Medical College and Research Hospital, Bangalore.

## REFERENCES

1. Browning J, Rosen T: Terra firma-forme dermatosis revisited. *Dermatol Online J.* 2005;11:5.
2. Pavloviæ MD, Dragos V, Potocnik M, Adamic M: Terra firma-forme dermatosis in a child. *Acta Dermatovenerol Alp Panonica Adriat.* 2008;17:41-2.
3. Erkek E, Sahin S, Çetin ED, Sezer E: Terra firma-forme dermatosis. *Indian J Dermatol Venereol Leprol.* 2012;78:358-60.
4. Guarneri C, Guarneri F, Cannavò SP: Terra firma-forme dermatosis. *International Journal of Dermatology.* 2008;47:482-4.