

## EVOLUTION OF VIDEO CAPILLAROSCOPY FOR 10 YEARS IN A PATIENT WITH RAYNAUD

Maria Bibiana Leroux, Celina Lashak

*Centro de Referencia en Raynaud y Colagenopatías, Rosario, Argentina*

Source of Support:

Nil

Competing Interests:

None

Corresponding author: Dr Maria Bibiana Leroux

[leroux\\_mb@hotmail.com](mailto:leroux_mb@hotmail.com)

Our Dermatol Online. 2014; 5(4): 374-377

Date of submission: 18.08.2014 / acceptance: 10.09.2014

### Abstract

**Introduction:** The nail fold video capillaroscopy allows the study of micro vascular abnormalities in autoimmune rheumatic diseases.

**Aim:** Report a case of Raynaud's phenomenon, in which images of video capillaroscopy correlate with disease course.

**Case Report:** Patient with Raynaud's phenomenon that after ten years of evolution develops pulmonary hypertension. The progression of micro vascular disease in the nail fold and lip mucosa was studied.

**Discussion:** Scleroderma pattern progresses in successive controls were observed in studies of video capillaroscopy. Pro-angiogenic and anti-angiogenic factors may trigger the formation of micro vascular changes during systemic scleroderma. The same can be correlated with lung involvement.

**Conclusion:** Images of video capillaroscopy collaborate with the diagnosis and prognosis in the spectrum of Systemic Scleroderma.

**Key words:** capillaroscopy; Raynaud; systemic scleroderma; pulmonary hypertension; SD pattern

### Cite this article:

Leroux MB, Lashak C. Evolution of video capillaroscopy for 10 years in a patient with Raynaud. *Our Dermatol Online*. 2014; 5(4): 374-377.

### Introduction

The nail fold video capillaroscopy allows the study of micro vascular abnormalities in patients with autoimmune rheumatic diseases. Its indication is the gold standard in the differential diagnosis between primary and secondary Raynaud. Recognition of the characteristic pattern scleroderma (SD) allows diagnosis of very early stage of systemic scleroderma and its correlation with systemic involvement. The micro vascular damage is considered an independent predictor and proposed as validation criteria for early systemic scleroderma [1-6].

### Aim

Report a case of Raynaud's phenomenon, in which images of video capillaroscopy correlate with disease course.

### Case Report

The female patient age 48, referred raynaud for 10 years. She refers pallor and cyanosis of hands after contact with the cold. This symptom was treated with nifedipine 20 mg/d during the winter months. During this time, regular checks are made. In control this year, lung involvement is detected. Typical signs of skin sclerosis in face and hands are not observed. In the personal history relates: absence of tobacco, alcohol, drugs, radiation or occupational exposure, and hypothyroidism in treatment. History of present illness is summarized in Table I. In each of the checks,

complete physical examination, hematological laboratory, antinuclear antibodies and auto-specific antibodies, radiology, and spirometry, is performed. In the immune laboratory have not detected anti-centromere, anti-topoisomerase 1 RNP or anti-Jo in successive controls. Pulmonary hypertension could correspond to systemic scleroderma or related disease (Figs 1a - c, 2a - c, 3).

### Discussion

Video capillaroscopy images in this patient are progressing over ten years. During this time the patient does not meet the classic diagnostic criteria for systemic sclerosis (1980), nor does it have specific auto antibodies. However, after 10 years starting with raynaud develops pulmonary hypertension. According to the proposed criteria for early diagnosis of systemic scleroderma, this case could be considered pre or early systemic scleroderma. Currently the definition of criteria for the diagnosis of this entity remain in debate [7-9]. In the study by video capillaroscopy, the characteristic pathological pattern scleroderma (SD) is recognized. It consists megacapilares, decrease or loss of capillaries, neo vessel formation, altered structure of the bed. You can also observe meandering, curled vessels and few branched capillaries (Tabl. II). SD pattern variants are listed in Table III.

In the first study conducted video capillaroscopy scleroderma early pattern is displayed. The density is relatively preserved, absence of avascular areas or neovascularization (Fig. 1).

In the second study, lower capillary density as above is checked. The presence of neovascularization reveals the vascular injury and repair attempt. This description corresponds to active SD pattern (Figs 1b, 1c).

In the third study, a nail fold telangiectasia is observed. These are formed by vessels which are visible to the naked eye (Fig. 2a). They are due to dilation of the post capillary venules located in the papillary and reticular dermis surface. The appearance of telangiectasias on skin is a common skin sign in systemic scleroderma and its presence is associated with pulmonary arterial hypertension. They are a marker of micro vascular

disease spread [10].

In the mucosa of the lower lip has a normal appearance with the naked eye. In our case study of megacapilares and neovascularization are detected (Figs 2b, 2c).

The video capillaroscopy in this area ranks as second choice site, because of its easy access. It has a similar capillary perfusion to the fingers, so the display close to 75% of the vessels is ensured. The study of Grassi et al notes that video capillaroscopy labial mucosa in patients with systemic scleroderma characteristic exhibited as more generalized disruption of the micro vascular network [11,12].

A full nail fold is also analyzed (Fig. 3). Arrows indicate multiple avascular areas. These are very close to the bizarre vessels due to angiogenesis.

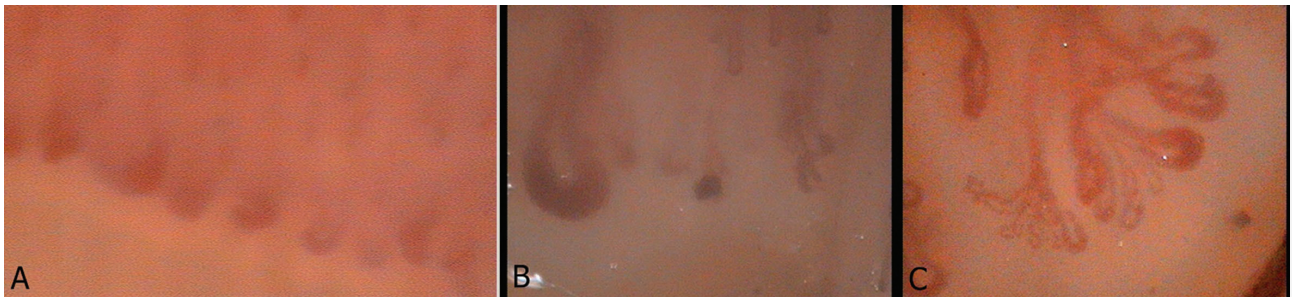


Figure 1. (A). Image video capillaroscopy by 200X in nail fold. 1 study. Very enlarged (mega capilares) capillaries. The largest is marked. Capillary density cap by 7 mm within normal limits. Vision in frosted glass. Scleroderma pattern. (B). Image of video capillaroscopy by 200X in nail fold. Obtained five years ago. One mega capilar shown. Capillary density greatly decreased. Micro hemorrhages. (C). Figure n°3: Image of video capillaroscopy by 200X in nail fold. Obtained five years ago. Neo capillary formation is observed well developed.

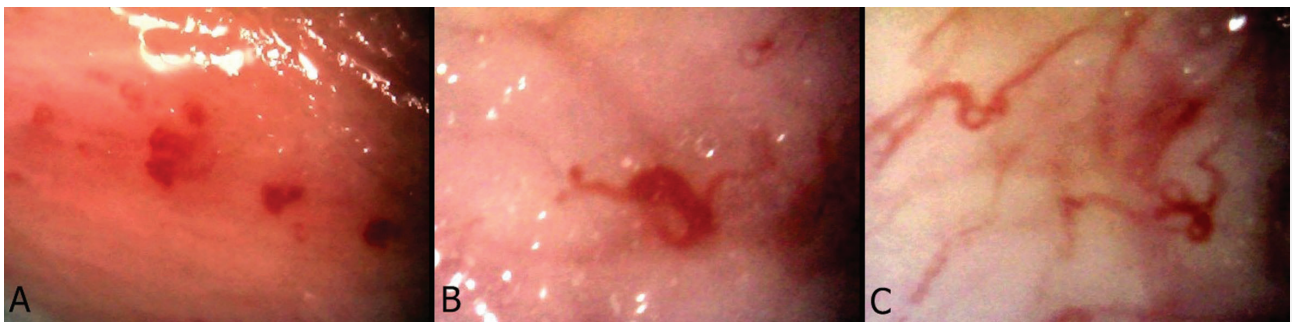

Figure 2. (A). Image video capillaroscopy by 200X in nail fold. Nail fold telangiectasia consist of very enlarged vessels. (B). Image of lower lip mucosa. Mega capilar. (C). Image of lower lip mucosa. Bushy capilar.

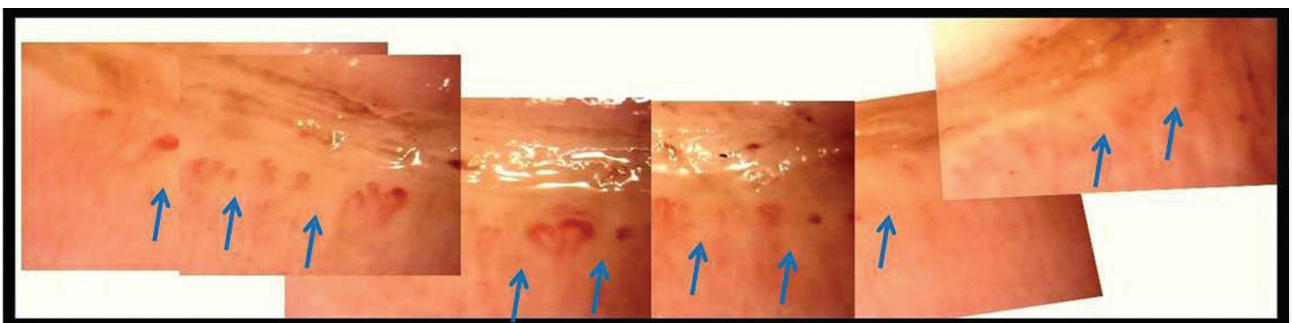


Figure 3. Video capillaroscopy image digitally, full nail fold. Multiple avascular areas, mega capilares, vessels caused by neo angiogenesis and Hemorrhages. Vision in frosted glass. Disorganization of the capillary bed. Pattern SD late.

Evolution	Cutaneous manifestation	Extra cutaneous manifestation	Autoantibodies	Videocapillaroscopy
10 years ago	Raynaud	Not detected	ANA negative	Not performed
8 years ago	Raynaud Periungual erythema Fragility of skin fingertips	Not detected	ANA 1/1280 N	Nail fold SD pattern 1st Study Figure 1a
5 years ago	Same as previous Add hands with persistent edema	Arthralgia	ANA 1/1280 NM	Nail fold SD pattern 2nd Study Figures 1b and 1c
Present day	Same as previoustelangiectasias periungulares Figure 2a	Pulmonary hypertension	ANA 1/1280 N	Nail fold and lip mucose SD pattern 3rd Study Figures 2b, 2c and 3

**Table I. Evolution patient.**

ANA: antinuclear antibodies

N: nucleolar pattern

M: speckled

SD: scleroderma

Alteration of the microcirculation	Description
Megacapillaries	Very increased in size capillaries to ten times normal. They can coexist with preserved capillaries. They are characteristic of secondary Raynaud and systemic sclerosis.
Vessels caused by neo angiogenesis	Increased in size, heterogeneous, bizarre, bushy capillaries
Tortuous vessels	Capillaries with serpentine arms like that can interbreed or turned on the long axis of the capillary.
Decreased capillary density	Less than 7 cap / mm. It is related to systemic scleroderma syndromes.
Avascular areas	These are caused by capillary loss. It can include one or more dermal papillae. A larger, more severe and are associated with decreased nutrient flow.
Disorder of the vascular bed	Alteration of the polarity of the capillaries.
Hemorrhages	Produced by injury of the capillary wall and consequent outflow of blood to the dermis. Red spots are arranged in rows extending from the capillary into the cuticle.
Exudates	Plasma present in the dermis can be observed in two ways: as a ground glass viewing or tenuous wave shaped figures surrounding the vessel originates.
Vision in frosted glass	Structures are blurred. This is due to the presence of plasma proteins the adjacent dermis.

**Table II. Glossary capillaroscopic.**

SD Pattern	Characteristics
Early SD	Mega capillaries, few hemorrhages, no apparent capillary loss, bed architecture preserved
Active SD	Mega capillaries and frequent hemorrhages, mild capillary loss, moderate disorganization of the architecture of the bed, formation of new blood vessels in small proportion. Presence of edema. Picture can progress
Late SD	Irregular increase size capillary, hemorrhages, severe capillary loss with extensive avascular areas, disorganization of the capillary bed, bizarre vessels. Picture stable

**Table III. SD pattern variants.**

SD: scleroderma



In the pathogenesis of systemic sclerosis, endothelial injury and apoptosis are early in the affected skin, prior to the presence of fibrosis events. In early disease, the pro-inflammatory state and increased production of pro-angiogenic factors stimulates angiogenesis. The presence of hemorrhage, giant capillaries and microvascular tortuosity changes are formed by uncontrolled angiogenic response. Subsequently, a process where actuated angiostatic factors resulting in reduction in capillary density and extensive areas of avascularity develops. Therefore the imbalance between pro-angiogenic and anti-angiogenic factors would play an active role in the formation of microvascular alterations [13].

In Systemic sclerosis lower capillary density compared with systemic lupus erythematosus, undifferentiated connective tissue disease and normal controls was demonstrated. In these patients, increased frequency of severe avascularity, megacapillaries and microbleeding was found. The prognostic value of capillaroscopy is manifested in the relationship between the avascularity and organic disease in systemic sclerosis. The presence and severity of pulmonary hypertension in patients are specifically correlated with the reduction in capillary density per millimeter. Recently suggested that the presence of large avascularity is a predictor of mortality in patients with systemic sclerosis [14-21].

The bizarre or bushy capillaries caused by neovascularization are indicators of disease activity. The finding of avascular areas correlates with interstitial lung disease and is more common in patients receiving immunosuppressants, indicating severe disease. The dynamic nature of the process is observed in 16% of patients. The SD pattern is a good indicator of the severity and evolution of the lung [22,23].

## Conclusion

Images of video capillaroscopy collaborate with the diagnosis and prognosis of patients in the spectrum of systemic sclerosis.

## REFERENCES

1. Roustit M, Cracowski JL. Non-invasive assessment of skin microvascular function in humans: an insight into methods. *Microcirculation*. 2012;19:47-64.
2. Maricq HR, Valter I. A working classification of scleroderma spectrum disorders: a proposal and the results of testing on a sample of patients. *Clin Exp Rheumatol*. 2004;22:S5-13.
3. Pistorius MA, Carpentier PH, le groupe de travail « Microcirculation » de la Société française de médecine vasculaire. Minimal work-up for Raynaud syndrome: a consensus report. *Microcirculation Working Group of the French Vascular Medicine Society. J Mal Vasc*. 2012;37:207-12.
4. Leroux MB, Rinaldi M, Palatnik S, Jorfren M, Fernandez Bussy R. Raynaud primario y secundario a síndromes esclerodermiformes. Comunicación de 97 pacientes estudiados por capilaroscopia periungueal. *Arch Argent Dermatol*. 2000;50:1519-23.
5. Sulli A, Burroni A, Tuccio M, Pizzorni C, Craviotto C, Ghio M, et al. Nailfold videocapillaroscopy in systemic sclerosis: diagnostic and follow-up parameters and correlation with both specific serum autoantibodies and subsets of skin involvement. *Reumatismo*. 2004;56:34-45.
6. Avouac J, Fransen J, Walker UA, Ricciari V, Smith V, Muller C, et al. Preliminary criteria for the very early diagnosis of systemic sclerosis: results of a Delphi Consensus Study from EULAR Scleroderma Trials and Research Group. *Ann Rheum Dis*. 2011;70:476-81.
7. Simeón-Aznar CP, Tolosa-Vilella C, Gabarró-Juliá L. Systemic sclerosis sine scleroderma and limited cutaneous systemic sclerosis: similarities and differences. *Clin Exp Rheumatol*. 2014;Apr 28
8. Valentini G, Marcocchia A, Cuomo G, Iudici M, Vettori S. The Concept of Early Systemic Sclerosis Following 2013 ACR/EULAR Criteria for the Classification of Systemic Sclerosis. *Curr Rheumatol Rev*. 2014 Apr 3.
9. Hudson M, Fritzler MJ. Diagnostic criteria of systemic sclerosis. *J Autoimmun*. 2014;48-49:38-41.
10. Matucci-Cerinic M, Kahaleh B, Wigley M. Review: evidence that systemic sclerosis is a vascular disease. *Arthritis Rheum*. 2013;65:1953-62.
11. Scardina GA, Pisano T, Carini F, Valenza V, Messina P. Burning Mouth Syndrome: An Evaluation of In Vivo Microcirculation. *J Am Dent Assoc*. 2008;139:940-6.
12. Grassi W, Core P, Carlino G, Blasetti P, Cervini M. Labial capillary microscopy in systemic sclerosis. *Ann Rheum Dis*. 1993;52:564-9.
13. Manetti M, Guiducci S, Ibbá-Manneschi L, Matucci-Cerinic M. Mechanisms in the loss of capillaries in systemic sclerosis: angiogenesis versus vasculogenesis. *J Cell Mol Med*. 2010;14:1241-54.
14. Lambova S, Müller-Ladner U. Capillaroscopic findings in systemic sclerosis -- are they associated with disease duration and presence of digital ulcers? *Discov Med*. 2011;12:413-8.
15. Wildt M, Wuttge DM, Hesselstrand R, Scheja A. Assessment of capillary density in systemic sclerosis with three different capillaroscopic methods. *Clin Exp Rheumatol*. 2012;30:S50-4.
16. Sulli A, Pizzorni C, Smith V, Zampogna G, Ravera F, Cutolo M. Timing of transition between capillaroscopic patterns in systemic sclerosis. *Arthritis Rheum*. 2012;64:821-5.
17. Herrick AL, Cutolo M. Clinical implications from capillaroscopic analysis in patients with raynaud's phenomenon and systemic sclerosis. *Arthritis Rheum*. 2010;62:2595-604.
18. Smith VI, Decuman S, Sulli A, Bonroy C, Piette Y, Deschepper E, et al. Do worsening scleroderma capillaroscopic patterns predict future severe organ involvement? a pilot study. *Ann Rheum Dis*. 2012;71:1636-9.
19. Sebastiani M, Manfredi A, Colaci M. Capillaroscopic skin ulcer risk index: a new prognostic tool for digital skin ulcer development in systemic sclerosis patients. *Arthritis Rheum*. 2009;61:688-94.
20. Corrado A, Carpagnano GE, Gaudio A, Foschino-Barbaro MP, Cantatore FP. Nailfold capillaroscopic findings in systemic sclerosis related lung fibrosis and in idiopathic lung fibrosis. *Joint Bone Spine*. 2010;77:570-4.
21. Kayser C, Sekiyama JY, Próspero LC, Camargo CZ, Andrade LE. Nailfold capillaroscopy abnormalities as predictors of mortality in patients with systemic sclerosis. *Clin Exp Rheumatol*. 2013;31:103-8
22. Granier F, Vayssairat M, Priollet P, Housset E. Nailfold capillary microscopy in mixed connective tissue disease. *Arthritis Rheum*. 1986;29:189-95.
23. de Holanda Mafaldo Diógenes A, Bonfá E, Fuller R, Correia Caleiro MT. Capillaroscopy is a dynamic process in mixed connective tissue disease. *Lupus*. 2007;16:254-8.