

IATROGENIC CUSHING SYNDROME DUE TO TOPICAL GLUCOCORTICOSTEROID THERAPY

Alicja Rustowska, Aleksandra Wilkowska, Roman Nowicki

*Department of Dermatology, Venereology and Allergology, Medical University of Gdansk, Gdansk, Poland***Source of Support:**

Nil

Competing Interests:

None

Corresponding author: Dr Alicja Rustowskaalicja.rustowska@gumed.edu.pl

Our Dermatol Online. 2013; 4(4): 503-505

Date of submission: 07.08.2013 / acceptance: 10.09.2013

Abstract

Topical glucocorticosteroids are the most common drugs to treat acute and chronic inflammatory skin diseases. Prolonged use of them may cause systemic adverse effects including Cushing's syndrome and hypothalamic-pituitary-adrenal axis suppression. We present a case of four year old girl who developed iatrogenic Cushing syndrome and adrenal insufficiency after atopic dermatitis treatment through the misuse of Mometasone treatment without doctor's prescription. We observe a redness and a moon face, a buffalo hump, central obesity, ginecomasty, subcutaneous hypertrophy, hirsutism, buttocks muscle atrophy and growth retardation. Wrist X-Ray revealed a bone age of two year old child. Laboratory values revealed hypothalamic-pituitary-adrenal axis suppression. The discontinuation of Mometasone treatment and supplement treatment with oral Hydrocortisone three times per day proved successful in this patient.

For this case, the serious side effects of topical glucocorticosteroid treatment should be explained to the family and their long-term therapy should be refrained. Iatrogenic Cushing syndrome in childhood caused by topical treatment is a rare event.

Key words: Cushing syndrome; atopic dermatitis; adrenal insufficiency; mometasone**Cite this article:**

Alicja Rustowska, Aleksandra Wilkowska, Roman Nowicki: Iatrogenic Cushing syndrome due to topical glucocorticosteroid therapy. *Our Dermatol Online*. 2013; 4(4): 503-505.

Introduction

Cushing's syndrome is a group of symptoms due to high levels of glucocorticoids, which can be either endogenous or exogenous. It can be ACTH dependent such as - Cushing's disease, ectopic ACTH – producing tumours or excess ACTH administration or non-dependent such as adrenal adenomas, adrenal carcinomas and excess glucocorticoid administration. Exogenous glucocorticoids are the most common etiological factor [1].

Atopic dermatitis is a chronic, inflammatory disease, an inherited predisposition to eczema, asthma bronchiale or hayfever and atopic individuals may have one or all of these manifestations [2]. The eczema usually begins between the ages of 3 and 12 months, asthma at age 3 and 4 years and the hayfever in the teens. In infancy the eczema may affect the whole body. About fifty percent of such children will also have ichthyosis, in about 90 percent of children the eczema will clear spontaneously by puberty, but in a small minority, it can persist into adult life. A few of these will have very extensive and troublesome eczema all their lives [3]. Prolonged use of glucocorticosteroids may cause systemic adverse effects including Cushing's syndrome and hypothalamic-pituitary-adrenal axis suppression.

Case Report

We present a case of four year old girl who developed iatrogenic Cushing syndrome and adrenal insufficiency after

atopic dermatitis treatment through the misuse of Mometasone treatment without doctor's prescription. The girl was admitted to the Dermatological Ward in December 2012 because of erythrodermia due to atopic dermatitis, which she suffers from birth. Skin lesions were localized on a face, hairy scalp, trunk, limbs and flexures. They were erythematous with raised red papules above the surface and had a scaly surface on palms and soles. Lichenification due to continual scratching in the area of antecubital fossae and wrists was observed. The clinical examination showed facial fullness, redness, acne and a moon face, (Fig. 1) hirsutism (Fig. 2), a buffalo hump, central obesity, ginecomasty, subcutaneous hypertrophy (Fig. 3), buttocks muscle atrophy and growth retardation (Fig. 4).

In the admission to the ward: the vital signs showed blood pressure 110/80mmHg, tachycardia 110 beats/min, body weight 1390g, height 89.2cm. The centile chart- under third centile.

The laboratory workup revealed blood cell count with platelets, glucose, electrolytes, total cholesterol, thyroid hormones- tests within normal limits.

Morning cortisol levels at 8.00 am showed value below normal range (cortisol: <22,1; normal range: 101-536nmol/l).

Synacthen test revealed the secondary adrenal insufficiency.

Wrist X-Ray - a bone age of two year old child.

Physiologic dose of oral Hydrocortisone 8,5mg daily was prescribed.

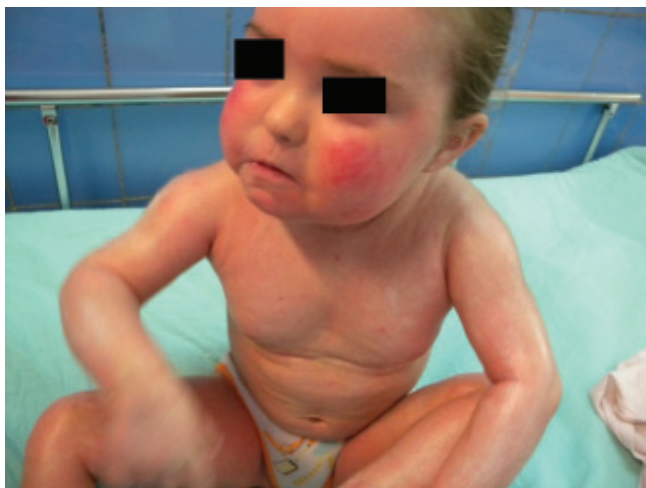

Figure 1. Facial fullness, redness, acne and a moon face.

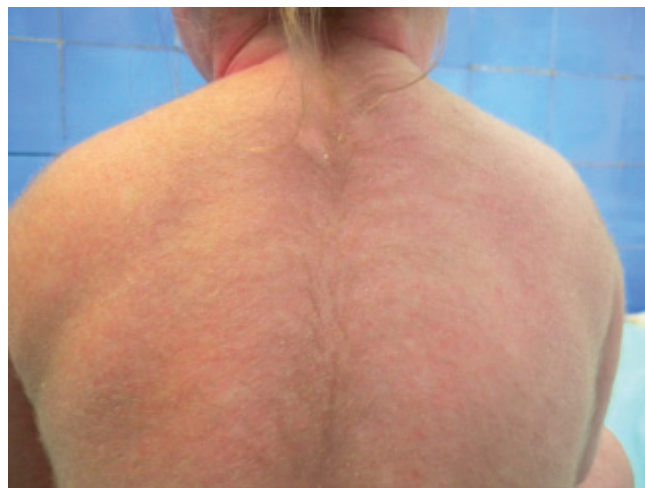


Figure 2. Hirsutism.

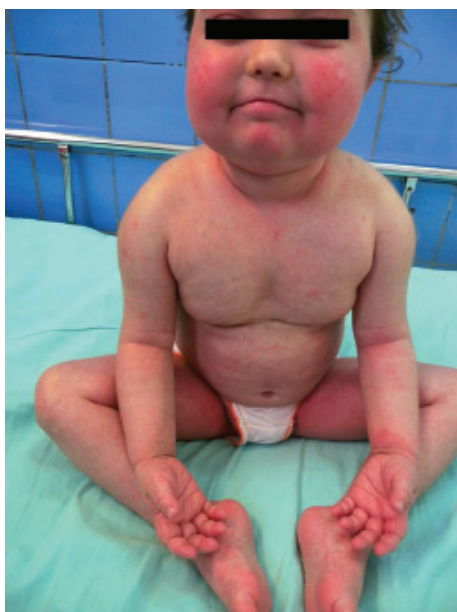

Figure 3. A buffalo hump, central obesity, gynecomasty, subcutaneous hypertrophy.

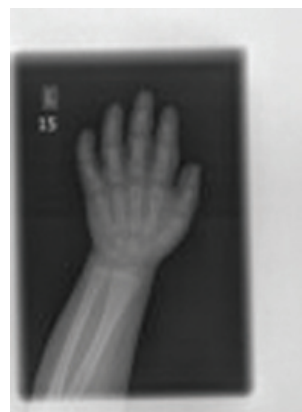

Figure 4. The growth retardation.

After 6 months of treatment laboratory values revealed blood cell count with platelets, electrolytes, total cholesterol, thyroid hormones - tests within normal limits. Morning cortisol level at 8.00 am- 353nmol/l. The Synacthen test – still showed adrenal insufficiency- the continuation of therapy was demanded.

The dose of Hydrocortisone was reduced after 3 months of treatment to 5,5mg daily, then to 3mg daily. The treatment will be discontinued when hypothalamus-pituitary-adrenal axis recovery is confirmed by normal morning cortisol level.

We observed the body proportions (Fig. 5a, b) and the disappearance of hirsutism (Fig. 6a, b). Body weight- 13.7kg, body height- 93.3cm.

Discussion

Topical corticosteroids are the most common drugs to treat acute and chronic inflammatory diseases in dermatology. Adverse effects of these are well known both in localized and systemic adverse effects depending on duration of use and potency of corticosteroid. They can be absorbed through normal skin but more in inflammatory and occlusive skin [4]. Children are more prone to develop systemic reactions to topically

applied medication because of their higher ratio of total surface area to body weight [5] and poorly developed skin barrier. Application of agents to large surface areas, occlusion, higher concentrations, increase the risk of side effects of steroids.

There are cases in the literature of iatrogenic Cushing's syndrome and suppression of hypothalamic-pituitary-adrenal axis due to topical corticosteroid therapy. Serap Semiz et al. described two cases of Cushing's syndrome in infants due to overuse of Clobetasol propionate on the diaper area [5]. Moreover, Therdpong Tempark et al. in case report draws attention to application of Clobetasol propionate for diaper dermatitis in infants. Among 86% infants with diaper dermatitis and 27% with psoriasis, burn, skin dryness were treated with Clobetasol (82%), Bethamethasone (18%) with the duration of application average about 2.75 months induced typical Cushing's features with suppressed cortisol and ACTH levels [4]. Caroline P. Halverstam et. al presented a Netherton syndrome patient – an 11 year old boy, who had been using excessive amounts of hydrocortisone 1% ointments for more than one year and developed Cushing's syndrome [6].

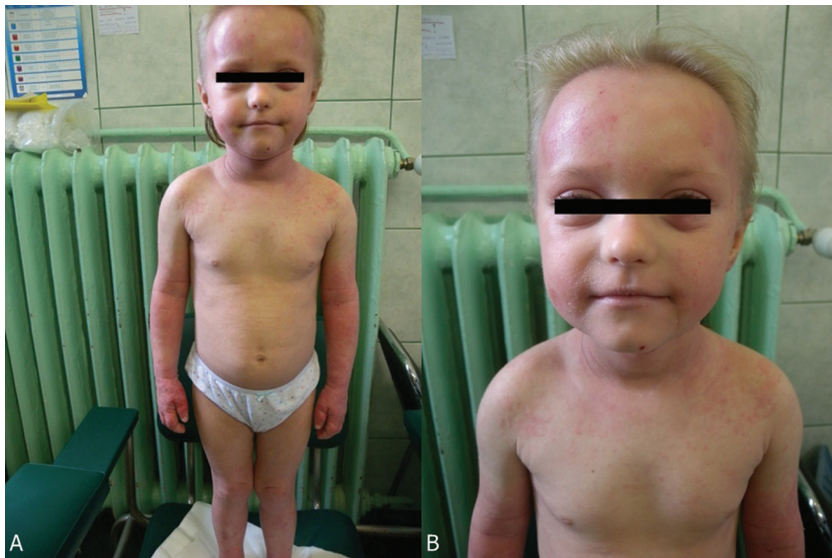

Figure 5a, b. Normalisation of body proportions after 6 months of treatment.

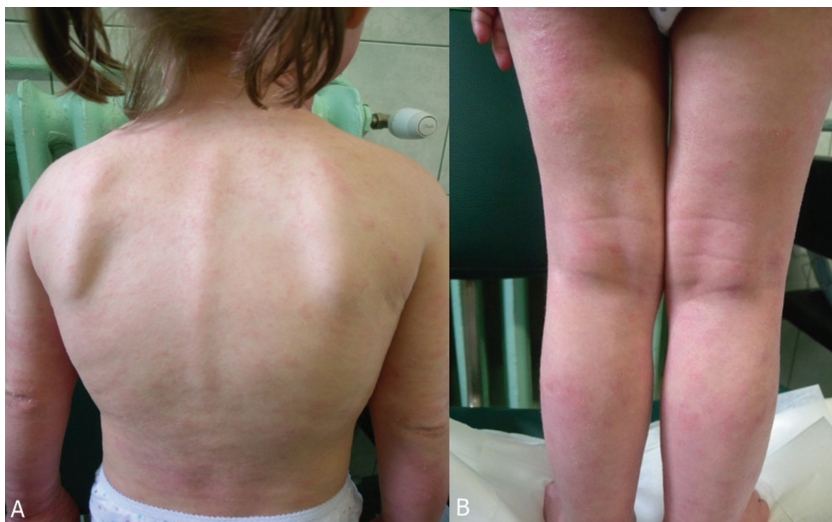

Figure 6a, b. The disappearance of hirsutism after 6 months of treatment.

Iatrogenic CS with hypothalamic-pituitary-adrenal axis suppression through the misuse of topical glucocorticosteroid therapy with Mometasone, is a very rare case. To our knowledge, our patient is the first one with atopic dermatitis who developed Cushing's syndrome after Mometasone application.

Conclusions

In conclusion, the serious side effects of topical glucocorticosteroid treatment should be explained to the family, monitored in young patients, especially the ones with reduced skin barrier function. A long-term therapy should be refrained.

REFERENCES

1. [Internal Medicine. The state of the 2011]. Edr: Andrzej Szczeklik. [Diseases of the endocrine system]. p.1197-8.
2. Bugdorf WHC, Plewig G, Wolff HH, Landthaler M: Edr: Braun-Falco. *Dermatologia Wyd. II polskie*, tom I, Czelej, Lublin, 2010 p. 425.
3. Cohen BA: *Dermatologia pediatryczna Wyd.II polskie* red: Andrzej Kaszuby s. 77.
4. Tempark T, Phatarakijirund V, Chatproedprai SA, Watcharasindhu S, Supornsilchai V, Wanankul S: Exogenous Cushing's syndrome due to topical corticosteroid application: case report and review literature. *Endocr.* 2010;38:328-4.
5. Semiz S, Balci YI, Ergin S, Candemir M, Polat A: Two cases of Cushing's syndrome due to overuse of topical steroid in the diaper area. *Pediatric Dermatol.* 2008;25:544-7.
6. Caroline P: Halverstam, Akshaya Vachharajani, Susan Bayliss Mallory. Cushing syndrome from percutaneous absorption of 1% hydrocortisone ointment in Netherton Syndrome. *Pediatric Dermatol.* 2007;24:42-5.