

**VARIED MALIGNANT PRESENTATIONS IN A SINGLE CASE OF XERODERMA PIGMENTOSA**Rahul Shetty, Aashish Sashidharan, Elvino Barreto,  
Kingsly M Paul*Department of Plastic and Reconstructive Surgery, Christian Medical College,  
Vellore, India***Source of Support:**  
Nil**Competing Interests:**  
None**Corresponding author:** Ass. Prof. Rahul Shetty[rahulplastic@hotmail.com](mailto:rahulplastic@hotmail.com)

Our Dermatol Online. 2013; 4(4): 493-495

Date of submission: 23.06.2013 / acceptance: 06.08.2013

**Abstract**

Xeroderma pigmentosum is an autosomal recessive genetic disorder in which cutaneous malignancies are very common. We report a rare case where four different varieties of cutaneous malignancies were seen in the same patient.

**Key words:** Xeroderma Pigmentosa; cutaneous malignancies; squamous cell carcinoma; basal cell carcinoma**Cite this article:**

Rahul Shetty, Aashish Shashidharan, Elvino Barreto, Kingsly Paul M: Varied Malignant presentations in a single case of xeroderma pigmentosa. *Our Dermatol Online*. 2013; 4(4): 493-495.

**Introduction**

Patients with XP are at a high risk for developing skin cancers, such as basal cell carcinoma. Xeroderma pigmentosum, or XP, is an autosomal recessive genetic disorder of DNA repair in which the ability to repair damage caused by ultraviolet (UV) light is deficient [1]. This disease involves both sexes and all races, with an incidence of 1:250,000 and a gene frequency of 1:200.

Metastatic malignant melanoma and squamous cell carcinoma [2] are the two most common causes of death in XP victims.

**Case Report**

A 19 years of age female patient presented to us with multiple lesions on her face. In addition she had skin pigmentation all over the body, freckles over the face and she complained of photophobia. She had already been diagnosed as a case of Xeroderma pigmentosa. An excision biopsy was done on the ulcerated lesion. Biopsy report of the excised portion revealed basal cell carcinoma. She received 6-7 weeks of radiotherapy for the same. Her younger brother is also affected with the disease. There was no history of consanguineous marriage. Closer examination revealed, a) big lesion (three by three cms) over the left cheek with presence of slough present in the centre, b) Ulcerated nodule of size two cms by two cms over the left forehead with and scab over it, margins were distinct, c) firm nodular swelling of size two cm by one cm over the left inferior border of mandible, d) a nodular swelling of size one cm by

one cm over the left cheek just anterior to the previous ulcerated lesion (Fig. 1).

There were small multiple nodular lesions over the right side of face. No significant.

Cervical lymphadenopathy was present. Systemic examinations including neurological function were normal. All investigations with serum biochemistry were within normal limits.

Though the biopsy of one of the lesions showed basal cell carcinoma, a wider margin of one centimeter was taken during excision. Cover was done with intermediate thickness skin graft. Post operative care was uneventful (Fig. 2 - 4). The excised lesions were sent for histopathological examination which revealed four types of cutaneous malignancy, i.e-spindle cell (sarcomatoid) carcinoma and focus of basal cell carcinoma in the cheek lesion, basal cell carcinoma of the forehead lesion, squamous cell carcinoma of the mandibular lesion and a foci of atypical melanocytic hyperplasia, which was not reported as malignant by the pathologist, in the left cheek lesion. All margins were free of tumor.

**Discussion**

Patients with xeroderma pigmentosa have extreme sensitivity to the sun's ultraviolet rays and should be protected from these rays. Proper protection from the sun and early adequate treatment helps in increasing the longevity of these patients. Unless protected from sunlight, the skin and eyes may be severely damaged [3-5].

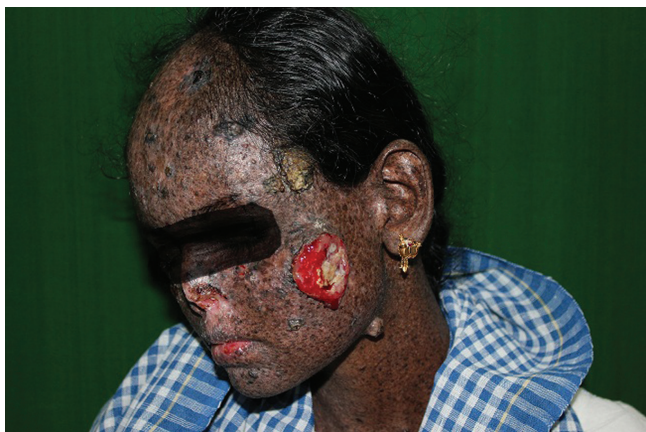

Figure 1. Pre operative picture showing the lesions on the face including a large ulcerated lesion on the cheek.

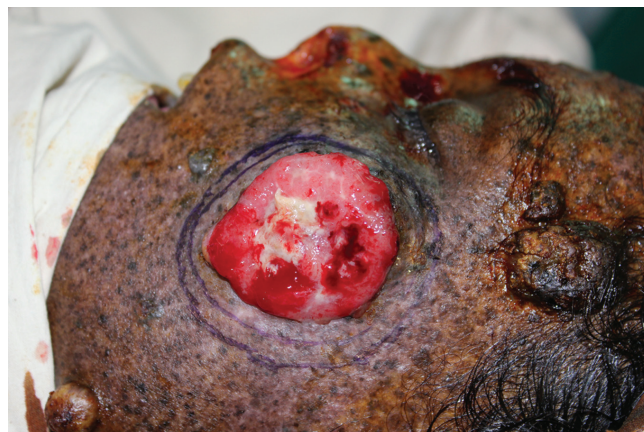


Figure 2. Intra operative picture showing the markings.

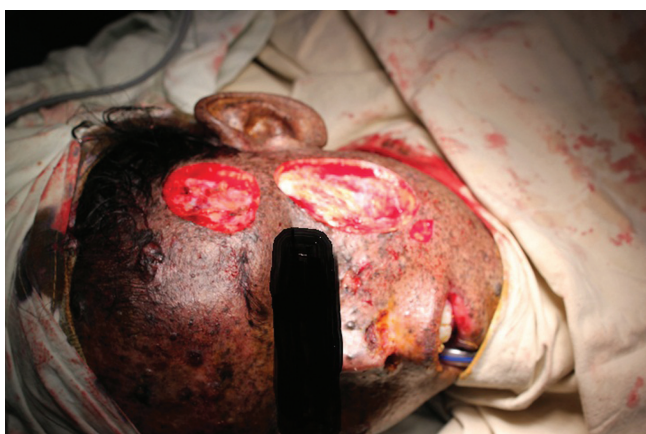

Figure 3. Intraoperative picture after a wide local excision was done.

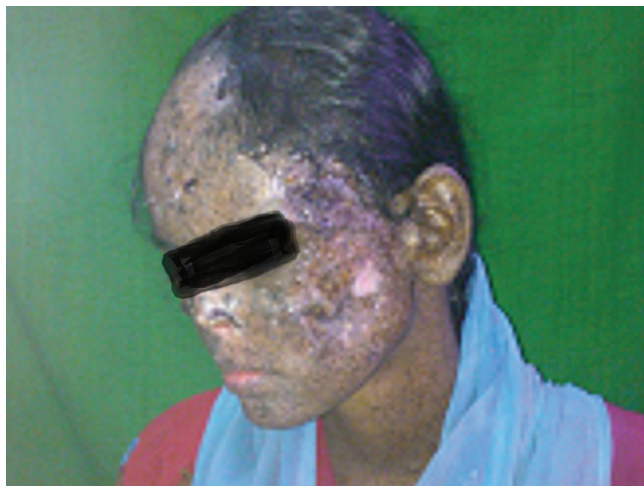

Figure 4. Post operative picture.

Individuals with XP develop multiple cutaneous neoplasms at a young age [6]. Two important causes of mortality are metastatic malignant melanoma and squamous cell carcinoma [7]. Patients younger than 20 years have a 1000-fold increase in the incidence of non melanoma skin cancer and melanoma [8]. The mean patient age for the development of skin cancer is 8 years in the patients with XP compared to 60 years in the healthy population. Actinic damage occurs in the age range of 1-2 years

Variations in the type of malignancies in XP appears to be related to the degree of sun exposure and genetic heterogeneity [9]. The two most common types of cancer found in XP patients are BCC and SCC, mainly occurring on the face, head, and neck. Melanomas occur in one-fourth of cases, and one-third of these occur in the head and neck [10].

A patient presenting with any two of these malignancies is a rare occurrence, with only a few cases reported in the literature; the presence of all the three types of malignancies in one patient is extremely unusual [11]. Early detection of these malignancies is necessary because they are fast growing, metastasize early and lead to an early death. Two important causes of mortality are metastatic melanoma and SCC. Most patients with XP do not live beyond the third decade because of the development of tumors [10]. Cutaneous neoplasms in XP patients cannot

be prevented but early protection from UV radiation should be advised, and undertaken.

In our case we have the synchronous occurrence of four different types of cancer which to our knowledge has never been reported before. From a surgeons perspective this holds a lot of importance because of the margin of excision varies for different types of skin tumors. Usually, since the most common tumor is Basal cell carcinomas, in the absence of preoperative tissue biopsy, one is inclined to treat most lesions as basal cell carcinomas and take a comparatively smaller margin. If the tumor turns out to be squamous cell carcinoma this may result in recurrence. Also in a patient with multiple lesion, when a biopsy is taken only from one tumor, considering it thinking it to be a representative lesion, it may prove wrong ,as illustrated in this patient. It is very important one ensures a complete excision of the tumor in view of the fact that metastatic squamous cell carcinoma and melanoma are the most common cause of mortality in these patients.

Keeping this is mind we propose that in absence of a confirmatory preoperative biopsy it would be advisable to give a considerable margin or plan for frozen section during the surgery so that one can ensure complete clearance. This would be safe and appropriate even if the biopsy turns out to be a SCC.

## Conclusion

We present this case wherein four different types of skin tumors were diagnosed on the same patient and in the same anatomical region (face). Synchronous occurrence of multiple cutaneous malignancies in a patient of xeroderma pigmentosa is extremely rare. This underlines the fact that almost any tumor can develop in these patients and hence it becomes imperative that resection with a wide margin is made to ensure total tumor excision.

## REFERENCES

1. Halpern J, Hopping B, Brostoff J: Photosensitivity, corneal scarring and developmental delay: Xeroderma Pigmentosum in a tropical country. *Cases J.* 2008;1:254.
2. *Medical Biochemistry at a Glance.* John Wiley & Sons. 28 November 2011. ISBN 1118292405. Retrieved 17 June 2011.
3. Lei L: Chapter 3 Nucleotide Excision Repair. DNA repair, genetic instability, and cancer. World Scientific Publishing. January 8, 2007. pp. 75–76. ISBN 981-270-014-5.
4. Friedberg EC, Walker GC, Siede W, Wood RD, Schultz RA, Ellenberger T: DNA repair and mutagenesis. Washington: ASM Press. 2006:1118.
5. Cleaver JE: DNA damage and repair in light sensitive human skin. *J Invest Dermatol.* 1970;54:181-95
6. Kramer KH: Xeroderma pigmentosum, In: Demis DJ, Dobson RL, Mc Guire J., eds. *Clinical Dermatology, Vol.4,Unit-19-7.* Hagerstown, Maryland: Harper and Row 1980;1-33.
7. English JS, Swerdlow AJ: The risk of malignant melanoma, internal malignancy in xeroderma pigmentosum patients. *Br J Dermatol.* 1987;117:457-61.
8. Itin HP, Burgdorf WH, Happle R, Paller A, Konig A, Pierini A, et al: Genodermatoses. In: Schaner LA, Hansen RC, editors. *Pediatric Dermatology.* 3 rd ed. Mosby: Elsevier Limited; 2003. p. 328-32
9. Alymlahi E, Dafiri R: Bilateral facial squamous cell carcinoma in an 18-month-old girl with xeroderma pigmentosum. *J Postgrad Med.* 2005;51:128-30.
10. Mohanty P, Mohanty L, Devi BP: Multiple cutaneous malignancies in xeroderma pigmentosum. *Indian J Dermatol Venereol Leprol.* 2001;67:96-7.