

DERMATOLOGY EPONYMS – SIGN – LEXICON – (J)Piotr Brzeziński¹, Anca Chiriac², Cecil Munsey³,
Ahmad Thabit Sinjab⁴¹*Dermatological Clinic, 6th Military Support Unit, Ustka, Poland**brzoo77@yahoo.com*²*Nicolina Medical Center, Department of Dermatology Iasi-Romania**ancachiriac@yahoo.com*³*Servicio de Dermatología, Hospital del Bierzo, Ponferrada, España**cecilmunsey@cox.net*⁴*Department of General Surgery, District Hospital in Wyrzysk a Limited
Liability Company, Wyrzysk, Poland**sinjab@wp.pl***Source of Support:**

Nil

Competing Interests:

None

Our Dermatol Online. 2013; 4(3): 399-402

Date of submission: 16.04.2013 / acceptance: 04.06.2013

Abstract

Eponyms are used almost daily in the clinical practice of dermatology. And yet, information about the person behind the eponyms is difficult to find. Indeed, who is? What is this person's nationality? Is this person alive or dead? How can one find the paper in which this person first described the disease? Eponyms are used to describe not only disease, but also clinical signs, surgical procedures, staining techniques, pharmacological formulations, and even pieces of equipment. In this article we present the symptoms starting with (J) and other. The symptoms and their synonyms, and those who have described this symptom or phenomenon.

Key words: eponyms; skin diseases; sign; phenomenon**Cite this article:***Piotr Brzeziński, Anca Chiriac, Cecil Munsey, Ahmad Thabit Sinjab: Dermatology Eponyms – Sign – Lexicon – (J). Our Dermatol Online. 2013; 4(3): 399-402.***JACQUET'S SIGN**

Baldness and dental anomalies [1]. Papulo-lenticular erythema of the napkin area. A minor form of congenital ectodermal defect is associated with other tegumentary changes, including congenital absence of nails and dental anomalies. Alopecia may be present at birth, or develop in first month of life. The syndrome is rare and may be partial or complete. Autosomal dominant inheritance reported; autoimmune mechanism suggested. Also Jacquet's reflex alopecia and Jacquet's syndrome.

LÉONARD MARIE LUCIEN JACQUET

French dermatologist, 1860–1914 (Fig. 1). He obtained his doctorate in 1888, became médecin des hôpitaux 1896 and from 1903 worked in the Hôpital Saint-Antoine. He chose dermatology and syphilology as his speciality and concerned himself with pruritus, the pathogenesis of pruriginous eruptions and the alopecia areata. With his "bio-kinetic" treatment he gave new ways in the treatment of certain dermatoses [2]. Jacquet's syndrome, Vidal-Jacquet syndrome, diaper dermatitis.

**Figure 1. Léonard Marie Lucien Jacquet**

JADASSOHN'S SIGN

=Maculopapular erythrodermia, pityriasis lichenoides chronica [3].

The term applied to a group of relatively uncommon inflammatory, maculopapular, scaly eruptions of unknown etiology and resistant to conventional treatment. Eruptions are both psoriatic and lichenoid in appearance, but the diseases are distinct from psoriasis, lichen planus, or other recognized dermatoses. Proposed nomenclature divides parapsoriasis into two distinct subgroups, pityriasis lichenoides and parapsoriasis en plaques (small- and large-plaque parapsoriasis).

JOSEPH JADASSOHN

German dermatologist, 1863-1936 (Fig. 2). Jadassohn, who was born at Liegnitz (current Poland), studied at Breslau (current Poland). He was an assistant of Albert Neisser at Allerheiligen Hospital in Breslau until 1892, the director of the university skin clinic in Bern (1896–1917), and a professor of dermatology at Breslau University (1917–1932). Jadassohn was a pioneer in the field of allergology and was among the first to take an immunological approach in the research of dermatological disorders, contributing to the understanding of the immunopathology of tuberculosis and trichophytosis. Jadassohn is credited for introducing patch testing to diagnose contact dermatitis, and in 1901, he described a rare childhood dermatological disorder, known as *granulosis rubra nasi* (a papular red lesion of the nose associated with increased sweating).

He was particularly interested in drug reactions, leprosy, eczema, tuberculosis, syphilis, and mycotic infections. His awareness of the social aspects of venereal diseases led to his appointment to the Committee on Hygiene of the League of Nations. He was a corresponding member of the British Association of Dermatology, and in the year prior to his death, he was made an honorary fellow of the Royal Society of Medicine. Jadassohn devoted much of his time to research. Maculopapular erythematosa, a scaling skin affection, is known as „Jadassohn's disease” because he first identified it and his name is also associated with the Jadassohn-Bloch skin test for allergic conditions. He described the patch test and *nevus sebaceus* (1895). His publications include *Krankheiten der Haut und die venerischen Krankheiten* written in collaboration with Albert Neisser (1900–01) and *Allgemeine Aetologie, Pathologie, Diagnose und Therapie der Gonorrhoe* (1910). He edited *Handbuch der Haut-und Geschlechtskrankheiten* (1927–32) and coedited the *Archiv fuer Dermatologie und Syphilis* [4].



Figure 2. Joseph Jadassohn. History of Medicine (NLM)

JAIL-FEVER SIGN

=typhus fever (endemic typhus) (Fig. 3). Also called „camp fever”, „hospital fever”, „ship fever”, „famine fever”, „putrid fever”, „petechial fever”, „Epidemic louse-borne typhus”, and „louse-borne typhus”. It is usually seen in areas where hygiene is poor and the temperature is cold [5,6].

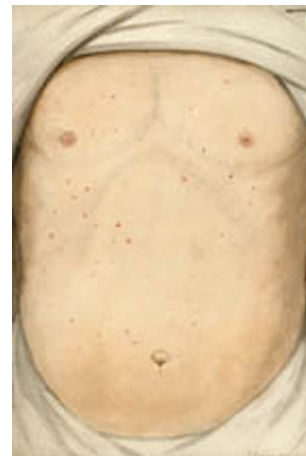


Figure 3. Jail-Fever sign

JAKE LEG SIGN (c. 1930)

A form of leg paralysis, caused by Jamaican ginger extract adulterated with tri-orthocresyl phosphate (Fig. 4).

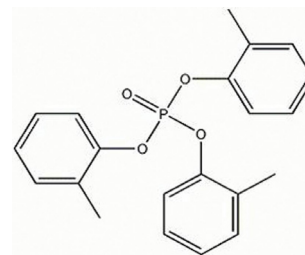


Figure 4. Tri-ortho cresyl phosphate (TOCP)

Jamaican Ginger Extract, known colloquially as „jake,” was a patent medicine that happened to be up to 80% ethyl alcohol, yet was legal to import to the United States. But to keep it from being drunk as an alcoholic beverage, the government insisted that the manufacturers add so much ginger that it was impossibly bitter (Fig. 5).

To test for this ginger content, inspectors would often boil it down and weigh the solids.



Figure 5. Motimer's box and bottle for Jamaica Ginger, Boston (alcohol 90)

Eventually a pair of unscrupulous chemists found another chemical that would pass the inspectors' test, while still leaving the jake drinkable: a neurotoxin called Tricresyl phosphate (TOCP).

TOCP caused paralysis at the spinal cord which left sufferers with a characteristic limp-footed walk. Either one or both feet would be paralyzed such that they dangled loose from the leg, and had to be picked up and flopped down in a tap-shuffle rhythm that became part of the „jake walk” lore [7,8].

JANEWAY'S SIGN

Erythematous lesions on the palm or sole seen in subacute bacterial endocarditis [9].

THEODORE CALDWELL JANEWAY

American physician, 1872-1917 (Fig. 6). He was educated at the Sheffield Scientific school, Yale university, and the College of Physicians and Surgeons, Columbia university. From 1898 to 1906 he taught medical diagnosis in New York university. In 1907 he became associate in medicine in Columbia university, and two years later professor of medicine. In 1914 he was called to Johns Hopkins university as professor of medicine, and became physician-in-chief to Johns Hopkins hospital.

His investigations in the phenomena of blood pressure opened up a hitherto unexplored field of medical research. During the World War, he became major in the Medical Officers' Reserve Corps and was engaged in research in Washington (D.C.). He died at Baltimore (Md.) Dec. 27, 1917. He was a member of the board of scientific directors of the Rockefeller Institute for Medical Research. He was the author of The Clinical Study of Blood Pressure [10].




Figure 6. Theodore Caldwell Janeway. History of Medicine (NLM)

JELLINEK'S SIGN

The pigmentation, usually brownish, occurring on the lid margins in many cases of hyperparathyroidism [11]. In Graves disease, a brownish pigmentation of the eyelids, especially the upper ones. Also known as Rasin's sign.

STEFAN JELLINEK

Austrian physician, 1871-1968 (Fig. 7). He studied medicine at

the University of Vienna from 1892 to 1898. From December 1898 to April 1899 Senator's assistant at the clinic in Berlin. In the years 1900-1903 the aspirant in the third clinic in Vienna, from 1903 sekundariusz in the Department of Dermatology. In December 1908 his habilitation in internal medicine. Since 1910 assistant at the Institute Elektropatologicznym. May 14, 1929 elektropatologii was an associate professor at the University of Vienna. In 1938, because of his Jewish origin had lost his job, then emigrated to the UK. He practiced at Queen's College [12].



Figure 7. Stefan Jellinek

JUNIN SIGN (South America)

Fever and bleeding caused by the zoonotic Argentinean hemorrhagic fever Arenaviridae virus (Junin virus) [13]. A member of the genus Arenavirus, Junin virus characteristically causes Argentine hemorrhagic fever (AHF). AHF leads to major alterations within the vascular, neurological and immune systems and has a mortality rate of between 20 and 30%. Symptoms of the disease are conjunctivitis, purpura, petechia and occasional sepsis. The symptoms of the disease are relatively indistinct and may therefore be mistaken for a different condition.

Since the discovery of the Junin virus in 1958, the geographical distribution of the pathogen, although still confined to Argentina, has risen. At the time of discovery, Junin virus was confined to an area of around 15,000 km². At the beginning of 2000, the distribution had risen to around 150,000 km². The natural hosts of Junin virus are rodents, particularly *Mus musculus*, *Calomys* spp. and *Akodon azarae*. Direct rodent to human transmission only transpires when contact is made with excrement of an infected rodent. This commonly occurs via ingestion of contaminated food or water, inhalation of particles within urine or via direct contact of broken skin with rodent excrement.

JUZAM SIGN

=Elephantiasis graecorum.

„.....No mention is made in the Hippocratic writings of elephantiasis graecorum, which was really a type of leprosy, and is now considered synonymous with it. According to Rayer, some writers insist that the affection then existed under the name of the Phoenician disease. Before the time of Celsus, the poet Lucretius first speaks of elephantiasis graecorum, and assigns Egypt as the country where it occurs.

Celsus gives the principal characteristics, and adds that the disease is scarcely known in Italy, but is very common in certain other countries. Galen supplies us with several particular but imperfect cases--histories of elephantiasis graecorum, with a view to demonstrate the value of the flesh of the viper, and in another review he adds that the disease is common in Alexandria. Aretaeus has left a very accurate picture of the symptoms of elephantiasis graecorum; and Pliny recapitulates the principal features and tells us that the disease is indigenous in Egypt. The opinion of the contagiousness of elephantiasis graecorum which we find announced in Herodotus and Galen is more strongly insisted upon by Caelius Aurelianus who recommends isolation of those affected. Paulus aegenita discusses the disease. The Arabian writers have described elephantiasis graecorum under the name of juzam, which their translators have rendered by the word lepra. Later, Hensler, Fernel Pare, Vesalius, Horstius, Forestus, and others have discussed it. affected in the East....." [14,15].

REFERENCES

1. Gil Montoya JA, Cutando Soriano A, Jiménez Prat MJ: Alopecia areata of dental origin. *Medicina Oral*. 2002;7:303-8.
2. <http://www.whonamedit.com/doctor.cfm/744.html>
3. Someshwar S, Udare S: Pityriasis lichenoides. *Indian Pediatr*. 2012;49:936-7.
4. Al Aboud A, Al Aboud K: Josef Jadassohn (1863–1936), Felix Lewandowsky (1879–1921), and their syndrome. *Clin Cosmet Investig Dermatol*. 2011;4:179–82.
5. Brzeziński P, Passarini B, Nogueira A: Dermatology eponyms – phenomenon / sign –dictionary (C). *N Dermatol Online* 2011;2:81-100.
6. Mikić Ž, Lešić A: [Dr. Elizabeth Ross: heroine and victim of the World War I in Serbia]. *Srp Arh Celok Lek*. 2012;140:537-42.
7. Munsey C: Paralysis in a bottle (The “Jake Walk” Story). *Bottles and Extras*. 2006. http://www.johnsonsdspot.com/chicago/jake_cmunsey.pdf
8. Crandall FG: Paralysis-from spurious jamaica ginger extract: report on los angeles county outbreak. *Cal West Med*. 1931;35:180-2.
9. Matsui Y, Okada N, Nishizawa M, Kaneko H, Watanabe M, Miura Y: An Osler’s node and a Janeway lesion. *Intern Med*. 2009;48:1487-8.
10. Prutkin JM: Theodore Caldwell Janeway, clinician and pathophysiologist. *Clin Cardiol*. 2007;30:146-8.
11. Castillo F, Garrity JA, Kravitz DJ: Intractable graves ophthalmopathy? *JAMA Ophthalmol*. 2013;131:269-70.
12. [No authors listed]: Stefan Jellnek. M. D. Vienna. *Lancet*. 1968 Nov 2;2:982. http://ub.meduniwien.ac.at/edocmed/?f_ac=AC06638230&f_file=1
13. Grant A, Seregin A, Huang C, Kolokoltsova O, Brasier A, Peters C, et al: Junín virus pathogenesis and virus replication. *Viruses*. 2012;4:2317-39.
14. Crocker HR, Pernet G: Two Cases of Elephantiasis graecorum. *Proc R Soc Med*. 1908;1(Dermatol Sect):53-6.
15. Zafarullah M, Bano H, Vohora SB: Juzam (leprosy) and its treatment in Unani medicine. *Am J Chin Med*. 1980;8:370-84.