

KIMURA'S DISEASE - A RARE ENTITYAshutosh Talwar¹, Neerja Puri²¹Department of Surgery, Punjab Health Systems Corporation, Punjab, India²Department of Dermatology and Venereology, Punjab Health Systems Corporation, Ferozpur, Punjab, India

Source of Support:

Nil

Competing Interests:

None

Corresponding author: Dr. Neerja Puri

neerjaashu@rediffmail.com

Our Dermatol Online. 2013; 4(3): 325-327

Date of submission: 16.02.2013 / acceptance: 19.03.2013

Abstract

Introduction: Kimura's disease is a benign, but locally injurious disease with a marked predilection for the head and neck. **Case Report:** We present two cases of this rare disease. **Discussion:** Of uncertain aetiology, its tendency to present as a discrete, enlarging mass with associated lymphadenopathy makes it a condition of interest to clinicians who see head and neck pathology. Although rare, there are increasing numbers of reports of the condition and it should become part of the standard differential diagnosis.

Key words: head and neck; eosinophilia; immunoglobulin**Cite this article:**Ashutosh Talwar, Neerja Puri: Kimura's disease - a rare entity. *Our Dermatol Online.* 2013; 4(3): 325-327.**Introduction**

Kimura's disease is an unusual condition in several respects. It was first reported by Chinese authors Kimm and Szeto in 1937 [1] and, besides its eponym, has been variously known as epithelioid haemangioma, atypical pyogenic granuloma and cutaneous eosinophilic lymphofolliculosis. The disorder received its current name in 1948, when Kimura et al noted the vascular component and referred to it as an "unusual granulation combined with hyperplastic changes in lymphoid tissue" [2]. Kimura's disease is a chronic inflammatory condition which presents with a characteristic triad of signs and symptoms, namely a painless, slowly enlarging soft tissue mass (or masses), associated lymphadenopathy and peripheral eosinophilia [3]. Eighty-five per cent of cases occur in men. Approximately 67 to 100% of patients develop regional lymphadenopathy and, in longstanding disease, this may become generalized [4]. Patients may complain of local or generalized pruritus and sub acute or chronic dermatitis. There may be proteinuria and laboratory investigations will invariably reveal peripheral eosinophilia and increased serum immunoglobulin (Ig)E [5]. While there has been considerable discussion in the pathology literature concerning this disease, it is still unknown by most surgeons. This report seeks to increase awareness of an interesting condition. Management of this disease is personalized due to lack of consensus and conservative approach is best suited.

Case report**Case 1**

This is a second case of 15 years old male who had a swelling in the left cervical area for the past 8 months. The swelling was

5cm x 3cm and was non tender but firm in consistency (Fig. 1). It was non adherent to mandible. The skin overlying the swelling was normal. Patient was treated conservatively with antibiotics and analgesics for two weeks but the swelling persisted. Then the patient was subjected to fine needle aspiration cytological examination. FNAC showed eosinophilia. Biopsy was taken to confirm the diagnosis which revealed the following features: Dilated blood vessels, some with bizarre and irregular shapes in the reticular dermis (Fig. 2). Inflammatory infiltrate contained mainly lymphocytes and eosinophils (HE x 100).

Case 2

A 3 year male presented in surgery OPD with complaints of swellings in the head and neck with involvement of the subcutaneous tissues and cervical lymphadenopathy. The swelling was noticed by his mother 4 months back which was treated by quacks in the near by village which gradually became small in size but again increased in size and now there was swelling 6cm x 3cm on the left side of the neck. The overlying skin was discoloured and the patient was running fever also. He was given antibiotics and was further subjected to fine needle aspiration cytology before doing incision and drainage & wedge biopsy of the swelling.

The histopathological examination revealed lymphoid nodules with discrete germinal centers occupying an area extending from the reticular dermis to the fascia and muscle. A marked eosinophilic infiltrate with eosinophilic abscesses was seen. Capillary proliferation was seen with masses of canalized vessels with flat endothelial cells alongwith fibrosis (Fig. 3).



Figure 1. 15 years male with swelling neck

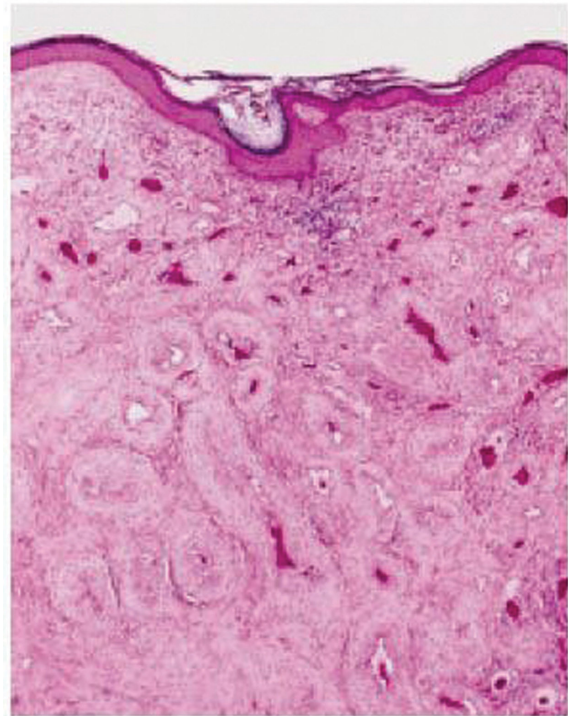


Figure 2. Photomicrograph showing dilated blood vessels alongw

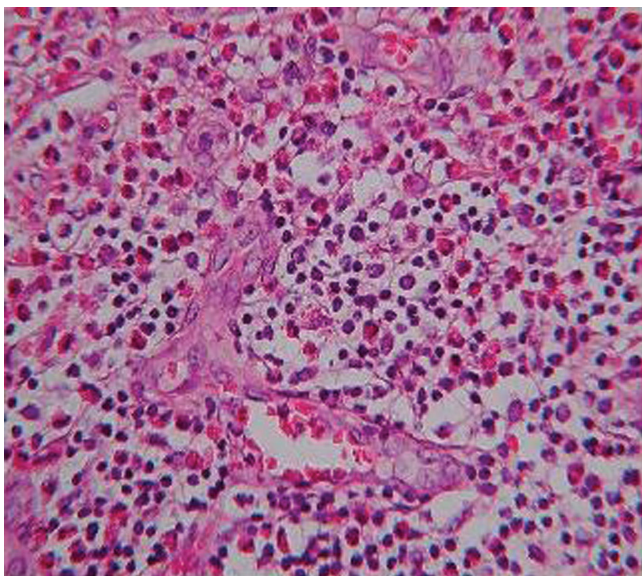


Figure 3. Photomicrograph showing lymphoid nodules with marked

Discussion

The differential diagnosis, while including obvious lesions such as dermatofibrosarcoma protruberans and cylindroma (turban tumours), will ultimately be determined by both the clinical picture and the histopathology. Clinically, malignant lymphoma, parotid tumours, haemangioma, pyogenic granuloma, Mikulicz's disease and Kikuchi's disease are all conditions for which Kimura's disease has been mistaken in the past [6,7]. Other conditions to consider include Kaposi's, sarcoma, angiosarcoma, eosinophilic lymphoma and angioimmunoblastic lymphadenopathy; parasitic diseases responsible for subcutaneous masses with an associated

lymphadenopathy, such as tissue-invasive helminth infections, cysticercosis, sparganosis, toxocariasis and several forms of invasive misaim may also need to be ruled out [8].

In Kimura's disease there is classically a dense inflammatory infiltrate characterized by eosinophilic lymphoid tissue with germinal centers and microabscesses. There is often marked fibrosis found within the typical lesions. Pathologically, the picture is perhaps most difficult to distinguish from angiolymphoid hyperplasia with eosinophilia (ALHE), and for a long time these two conditions were thought to represent one and the same pathology, but the current consensus is that they represent two ends of a spectrum of similar diseases [9]. KD is generally limited to the skin, lymph nodes, and salivary glands but patients with KD and nephrotic syndrome have been reported. The basis of this association is unclear. Males are affected by KD more commonly than females, with a 6:1 ratio in one series. KD is usually seen in young adults. A series by Kung et al reported a median age of 28 years [10].

In Kimura's disease there is classically a dense inflammatory infiltrate characterized by proliferating lymphoid tissue with germinal centres, eosinophilic microabscesses and fibrosis. There is often marked fibrosis. The lesion need to be distinguished from angiolymphoid hyperplasia with eosinophilia (ALHE), which is believed to be a true neoplasm of the endothelium [11]. The histology of ALHE is typified by an exuberant proliferation of capillary vessels some of which may not be canalized. These are lined by epithelioid (histiocytoid) endothelial cells which are not seen in Kimura's disease. While there is an inflammatory infiltrate, the associated lymphocytes are not arranged in germinal centres as they are in Kimura's disease.

Clinically, Kimura's disease is believed to be a disease of the Orient, and ALHE one of the western world. ALHE occurs in older (20-40 years), predominantly female populations. Kimura's disease is primarily a disease of younger males.

The pathophysiology of KD remains unknown, although an allergic reaction, trauma, and an autoimmune process have all been implicated as the possible cause. The disease is manifested by an abnormal proliferation of lymphoid follicles and vascular endothelium. Peripheral eosinophilia and the presence of eosinophils in the inflammatory infiltrate suggest that KD may be a hypersensitivity reaction. Some evidence has indicated that TH2 lymphocytes may also play a role, but further investigation is needed [12].

Treatment options range from conservative observation for asymptomatic patients to surgical excision, steroid therapy, and radiotherapy for symptomatic patients. The treatment of choice for localized disease would thus appear to be surgical excision. Conservative management is recommended in anatomically sensitive areas. There had been some case reports in the otorhinolaryngeal, plastic surgery and ophthalmic specialties reflecting problems in management when this lesion affects important anatomical structures. For refractory lesions, Intralesional or oral steroids can shrink the nodules but seldom results in cure. A medium-potency steroid, such as triamcinolone acetonide, used in solution form for intralesional injection usually is well tolerated. Cyclosporine recently was reported to induce remission in a patient with KD of the earlobe. A dose of 5 mg/kg/day was administered for 7 days, then tapered. Radiotherapy has been used to treat recurrent or persistent lesions [13]. In summary, Kimura's disease is an indolent, benign, but locally disfiguring disease, whose true importance lies in its ability to mimic a number of other benign inflammatory and neoplastic conditions of the head and neck. Knowledge of the condition, its clinical appearance, course and histopathology puts the practitioner in a better position to answer questions from concerned patients and primary caregivers, and optimize management strategies.

REFERENCES

1. Kimm HT, Szeto C: Eosinophilic hyperplastic lymphogranuloma, comparison with Mikulicz's disease. *Proc Chin Med Soc.* 1937;1:329.
2. Kimura T, Yoshimura S, Ishikawa: Unusual granulomata combined with hyperplastic change in lymphatic tissue. *Trans Soc Pathol Jpn.* 1948;13:179-80.
3. Chen H, Thompson LD, Aguilera NS, Abbondanzo SL: Kimura disease: a clinicopathologic study of 21 cases. *Am J Surg Pathol.* 2004;28:505-13.
4. Day TA, Abreo F, Hoajsoe DK, Aarstad RF, Stucker FJ: Treatment of Kimura's disease: a therapeutic enigma. *Otolaryngol Head Neck Surg.* 1995;112:333-7.
5. Helander SD, Peters MS, Kuo TT, Su WP: Kimura's disease and angiolymphoid hyperplasia with eosinophilia: new observations from immunohistochemical studies of lymphocyte markers, endothelial antigens, and granulocyte proteins. *J Cutan Pathol.* 1995;22:319-26.
6. Kuo TT, Shih LY, Chan HL: Kimura's disease. Involvement of regional lymph nodes and distinction from angiolymphoid hyperplasia with eosinophilia. *Am J Surg Pathol.* 1988;12:843-54.
7. Som PM, Biller HF: Kimura disease involving parotid gland and cervical nodes: CT and MR findings. *J Comput Assist Tomogr.* 1992;16:320-2.
8. Irish JC, Kain K, Keystone JS, Gullane PJ, Dardick I: Kimura's disease: An unusual cause of head and neck masses. *J Otolaryngol.* 1994;23:88-91.
9. Jambhekar NA, Bores AM, Saxena R, Parikh D, Soman C: Angiolymphoid hyperplasia with eosinophilia (Kimura's disease): Report of a large-sized lesion. *J Surg Oncol.* 1991;47:206-8.
10. Kung IT, Gibson JB, Bannatyne PM: Kimura's disease: a clinicopathological study of 21 cases and its distinction from angiolymphoid hyperplasia with eosinophilia. *Pathology.* 1984;16:39-44.
11. Rosai J, Gold J, Landy R: A Unifying concept embracing several previously described entities of skin, soft tissues, large vessels, bone and heart. *Human Pathol.* 1979;10:707-23.
12. Gumbs MA, Pai NB, Saraiya RJ, Rubinstein J, Vythilingam L, Choi YJ: Kimura's disease: a case report and literature review. *J Surg Oncol.* 1999;70:190-3.
13. Hareyama M, Oouchi A, Nagakura H, Asakura K, Saito A, Satoh M et al: Radiotherapy for Kimura's disease: the optimum dosage. *Int J Radiat Oncol Biol Phys.* 1998;40:647-51.