

## MILIA-LIKE IDIOPATHIC CALCINOSIS CUTIS OF THE MEDIAL CANTHUS

Faten Limaïem, Sirine Bouslema, Inès Haddad,  
Fadoua Abdelmoula, Saâdia Bouraoui, Ahlem Lahmar,  
Sabeh Mzabi

*Department of Pathology, Mongi Slim Hospital, La Marsa (2046), Tunisia*

Source of Support:  
Nil

Competing Interests:  
None

Corresponding author: Dr Faten Limaïem

[fatenlimaïem@yahoo.fr](mailto:fatenlimaïem@yahoo.fr)

Our Dermatol Online. 2013; 4(2): 212-214

Date of submission: 07.01.2013 / acceptance: 11.02.2013

### Abstract

Calcinosis cutis is a term used to describe a group of disorders in which calcium deposits form in the skin and may be classified as dystrophic, metastatic, idiopathic or iatrogenic calcification, and calciphylaxis. Idiopathic calcinosis cutis occurs without any underlying tissue damage or metabolic disorder. In this paper, the authors report a new case of idiopathic calcinosis involving the medial canthus of the left eye that was mistaken for milia. An 18-year-old previously healthy male patient, presented with an asymptomatic whitish solitary tumour of the medial canthus of the left eye. The patient had no systemic or trauma history, and the serum levels of calcium and phosphorous were normal. An excisional biopsy was performed and histopathologic examination revealed subepidermal calcinosis. Calcinosis cutis is a rare condition that should be included in the differential diagnosis of a benign-appearing lesion of the face. While it can occur in patients with a history of inflammation, trauma, or hypercalcemia, its etiology can also be idiopathic.

**Key words:** idiopathic; calcinosis cutis; medial canthus

### Cite this article:

Faten Limaïem, Sirine Bouslema, Inès Haddad, Fadoua Abdelmoula, Saâdia Bouraoui, Ahlem Lahmar, Sabeh Mzabi: Milia-like idiopathic calcinosis cutis of the medial canthus. *Our Dermatol Online*. 2013; 4(2): 212-214.

### Introduction

Calcinosis cutis is a rare disease characterized by the deposition of insoluble calcium salts in cutaneous tissue [1]. Idiopathic calcinosis cutis occurs in the absence of tissue injury or systemic metabolic effect. No causative factor is identifiable and calcification is most commonly localized to one general area. Idiopathic calcification of normal skin has been described mainly in scrotum, penis, vulva and breast but rarely in the face. In this paper, the authors report a new case of idiopathic calcinosis involving the medial canthus of the left eye which was mistaken for milia.

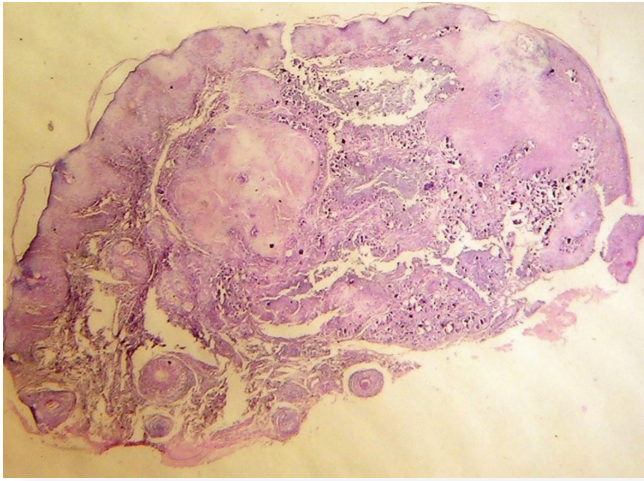
### Case Report

An 18-year-old previously healthy male patient, presented with an indolent lesion of the medial canthus of the left eye of one year duration. The patient had no systemic or trauma history. Laboratory data showed no abnormalities. Serum calcium and phosphorous levels were within normal range. On examination, there was a 2mm hard, whitish nodule involving the medial canthus of the left eye with oozing of central whitish material. The suspected clinical diagnosis was milia. The contralateral eye was unremarkable. An excisional

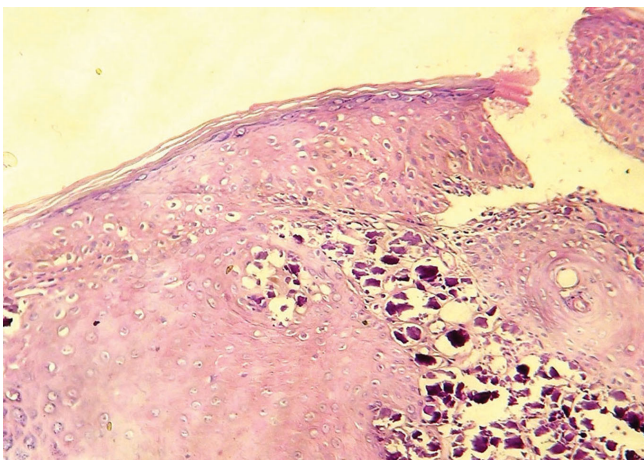
biopsy of the nodule was performed. Histopathologic examination, demonstrated the presence of massive amorphous basophilic-stained calcification deposits beneath the epidermis, with occasional foreign body giant cells around the calcific masses and acanthosis of the overlying epithelium (Fig. 1-4). The final pathological diagnosis was idiopathic calcinosis cutis of the medial canthus. The patient has been followed on an outpatient basis without specific findings over 3 months of follow-up.

### Discussion

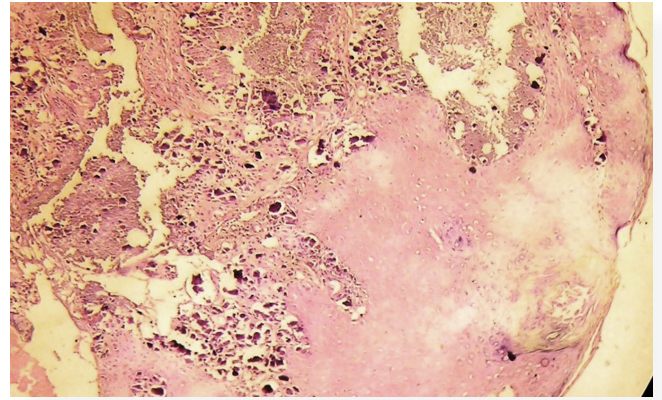
Calcinosis cutis is separated into five subtypes: dystrophic, metastatic, idiopathic, iatrogenic calcification, and calciphylaxis [2]. Dystrophic calcification appears as a result of local tissue damage with normal calcium and phosphate levels in serum [1,2]. Metastatic calcification is characterized by an abnormal calcium and/or phosphate metabolism, leading to the precipitation of calcium in cutaneous and subcutaneous tissue. Skin calcification in iatrogenic calcinosis cutis is a side effect of therapy. Calciphylaxis presents with small vessel calcification mainly affecting blood vessels of the dermis or subcutaneous fat.



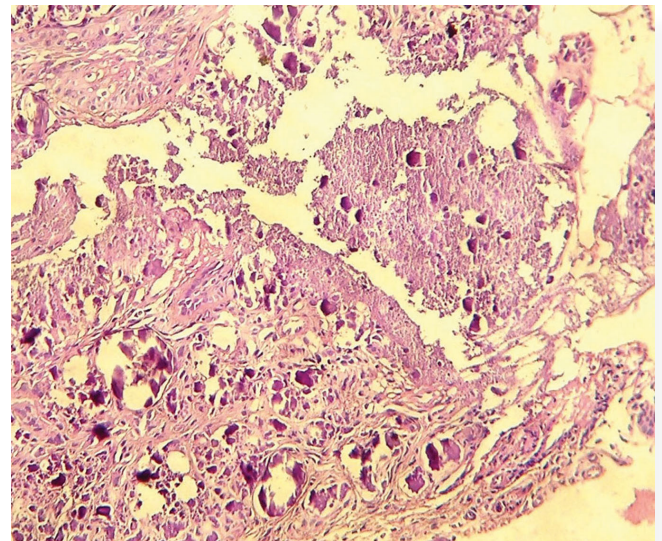
**Figure 1.** Histological section showing massive amorphous basophilic-stained calcification deposits beneath the epidermis. (H & E, original magnification x 10)



**Figure 3.** Amorphous basophilic calcification deposits in the papillary dermis. (H & E, original magnification x 40)



**Figure 2.** Granular basophilic deposits in the dermis with acanthosis of the overlying epidermis. (H & E, original magnification x 25)



**Figure 4.** Massive amorphous basophilic-stained calcification deposits. (H & E, original magnification x 40)

Idiopathic calcification occurs without any underlying tissue damage or metabolic disorder. The calcification is most commonly localized to one general area, but a case of unusually widespread calcinosis cutis has been reported [1]. Idiopathic calcinosis cutis comprises tumoral calcinosis, subepidermal calcified nodules, and scrotal calcinosis. Subepidermal calcified nodules occur on the head and extremities, mainly as solitary, hard, white yellowish papules of 3 mm to 11 mm. The disorder usually occurs in children and can even be present at birth [3,4]. Some investigators suggest that they represent calcified adnexal structures [5-7]. Idiopathic calcinosis has also been reported in patients with Down Syndrome in association with syringomas where lesions are found on the hands, forearms, and thighs [8]. In our case, dystrophic, metastatic and iatrogenic calcinosis cutis were ruled out, respectively, by the lack of history of trauma, no preceding pathologic lesions at the sites of the nodular lesion, normal serum calcium and phosphorus levels and absence of history of parenteral therapy. The pathogenic mechanism of idiopathic calcinosis cutis is unknown. Some advocate an active role of the increased sweat duct calcium levels in the development of these lesions [8]. Therefore, the

high concentration of sweat glands in the groin and pubic areas may play a role in the development of calcium deposits at these sites [1,8]. Calcinosis cutis has been mistaken clinically for molluscum contagiosum, milia, verruca, and xanthoma [6]. In our case, calcinosis cutis was clinically mistaken for milia. Histopathologically, calcium deposits stain dark blue with hematoxylin eosin and black with von Kossa stain. Fine granules of calcium can be observed in the dermis and large, irregular calcium masses occur in the subcutaneous tissue [9]. A foreign body reaction with inflammation and fibrosis may be seen around larger calcified deposits [9]. Because calcinosis cutis is rare, there is a notable lack of controlled clinical trials on its treatment. The efficacy of calcinosis treatment has only been reported in single cases or small case series. No treatment has been generally accepted as standard therapy, although various treatments have been reported to be beneficial. Small calcified deposits or larger localized lesions can be successfully treated by surgical intervention. Disseminated, extended calcinosis often requires systemic treatment. The effect of surgery can be evaluated within days or weeks, whereas systemic therapy may need months of treatment before improvement is seen [1].

In summary, a case of idiopathic calcinosis of the medial canthus is reported along with pathological findings. Calcinosis cutis is a rare condition that should be included in the differential diagnosis of a benign - appearing lesion of the face. While it can occur in patients with a history of inflammation, trauma, or hypercalcemia, its etiology can also be idiopathic.

#### REFERENCES

1. Guermazi A, Grigoryan M, Cordoliani F, Kerob D: Unusually diffuse idiopathic calcinosis cutis. *Clinical Rheumatology*. 2007;26:268-70.
2. Reiter N, El-Shabrawi L, Leinweber B, Berghold A, Aberer E: Calcinosis cutis: part II. Treatment options. *J Am Acad Dermatol*. 2011;65:15-22.
3. Walsh JS, Fairley JA: Calcifying disorders of the skin. *J Am Acad Dermatol*. 1995;33:693-706.
4. Aksoy HM, Ozdemir R, Karaaslan O, Tiftikcioglu YO, Oruc M, Kocer U: Incidental idiopathic calcinosis cutis in a rhytidectomy patient. *Dermatol Surg*. 2004;30:1145-7.
5. Valdatta L, Buoro M, Thione A, Mortarino C, Tuinder S, Fianza C, et al: Idiopathic circumscripta calcinosis cutis of the knee. *Dermatol Surg*. 2003; 29:1222-4.
6. Plott T, Wiss K, Raimer S, Solomon A: Recurrent subepidermal calcified nodule of the nose. *Pediatr Dermatol*. 1988;5:107.
7. Eng A, Mander E: Perforating calcinosis cutis presenting as milia. *J Cutan Pathol*. 1981;8:247.
8. Maroon M, Tyler W, Marks V: Calcinosis cutis associated with syringomas: a transepidermal elimination disorder in a patient with Down Syndrome. *J Am Acad Dermatol*. 1990;23:372.
9. Touart DM, Sau P: Cutaneous deposition diseases. Part II. *J Am Acad Dermatol*. 1998;39:527-46.