

DERMATOLOGY EPONYMS – SIGN – LEXICON – (I)Piotr Brzeziński¹, Iffat Hassan², Anca Chiriac³,
Ahmad Thabit Sinjab³¹*Dermatological Clinic, 6th Military Support Unit, Ustka, Poland**brzezoo77@yahoo.com*²*Department of Dermatology, STD and Leprosy, Government Medical College,
Srinagar (University of Kashmir), J&K, India**hassaniffat@gmail.com*³*Nicolina Medical Center, Department of Dermatology Iasi-Romania**ancachiriac@yahoo.com*⁴*Department of General Surgery, District Hospital in Wyrzysk a Limited
Liability Company, Wyrzysk, Poland**sinjab@wp.pl***Source of Support:**

Nil

Competing Interests:

None

Our Dermatol Online. 2013; 4(2): 256-259

Date of submission: 02.02.2013 / acceptance: 28.02.2013

Abstract

Eponyms are used almost daily in the clinical practice of dermatology. And yet, information about the person behind the eponyms is difficult to find. Indeed, who is? What is this person's nationality? Is this person alive or dead? How can one find the paper in which this person first described the disease? Eponyms are used to describe not only disease, but also clinical signs, surgical procedures, staining techniques, pharmacological formulations, and even pieces of equipment. In this article we present the symptoms starting with (I) and other. The symptoms and their synonyms, and those who have described this symptom or phenomenon.

Key words: eponyms; skin diseases; sign; phenomenon**Cite this article:**Piotr Brzezinski, Iffat Hassan, Anca Chiriac, Ahmad Thabit Sinjab: *Dermatology Eponyms – Sign – Lexicon – (H)*. Our Dermatol Online. 2013; 4(2): 256-259.**„I LOVE YOU” SIGN**

The appearance of this hand is very typical of infants with trisomy 18, occurring in about 50% of affected infants. The clenched hand with a tendency for the index finger to overlap the third and for the fifth finger to overlap the fourth. At times these fingers are extended, giving the appearance of the sign for “I love you” in American sign language (Fig. 1). Infants with trisomy 18 also commonly have hypoplasia of the nails on both the fingers (especially the fifth finger) and the toes [1].

IDIOPATHIC DISEASE SIGN

One not consequent upon other disease, nor upon any known lesion or injury.

INMAN’S SIGN

=myalgia [2]



Figure 1. „I love you” sign

THOMAS INMAN

English physician, 1820-1876. House-surgeon to the Liverpool Royal Infirmary. In his lifetime he had numerous medical papers published. He was also an amateur mythologist, and wrote *Ancient Pagan and Modern Christian Symbolism*, first published in 1869 and then again in 1875. He entered King's College, London, where he graduated M.B. in 1842 and M.D. in 1844 at the University of London. Declining a commission as an army surgeon, Inman settled in Liverpool as house-surgeon to the Royal Infirmary. He obtained a good practice as a physician, and was for many years physician to the Royal Infirmary. Inman's publications on personal hygiene are practical advice.

INNOCENCE'S SIGN

In the eastern region of Nigeria natives used the extract of the Calabar bean (*Physostigma vevevsum*) (Fig. 2) which is the seed of a leguminos plant for judicial execution. However, if after ingestion the man vomited it back, then he was considered innocent [3].




Figure 2. Calabar bean

DOUGLAS MORAY COOPER LAMB AGRYLL ROBERTSON



Figure 3. Douglas Moray Cooper Lamb Agryll Robertson

Scottish ophthalmologist and surgeon, 1837-1909 (Fig. 3). After earning his degree in 1857 from the University of St Andrews, he went to Berlin to study under Albrecht von Graefe. Robertson spent most of his medical career

in Edinburgh as an eye surgeon at the Edinburgh Royal Infirmary and teacher of ophthalmology at the University of Edinburgh. For a while he was honorary eye physician to Queen Victoria and King Edward VII. Robertson made several contributions in the field of ophthalmology; in 1863 he researched the effects on the eye made by physostigmine, an extract from the Calabar bean (*Physostigma venenosum*), which is found in tropical Africa. He correctly predicted that physostigmine would become very important in the treatment of eye disorders. He also described a symptom of neurosyphilis that affects the pupils of the eye, which is known today as Argyll Robertson pupils [4].

INTERCURRENT DISEASE SIGN

A disease occurring during the course of another disease with which it has no connection.

INTERFERENCE SIGN

1. The interference of one drug with the therapeutic activity of another drug; especially a sort of drug-fastness toward full therapeutic doses of one drug conferred on a parasite by subtherapeutic doses of another drug.
2. The interference with the replication or virulence of a virus by the simultaneous infection with another that may not be related. Called also preemptive immunity or interference phenomenon.

ITALIAN SIGN

=syphilis. Also called mal d'Italie.

HIERONYMUS FRACASTORIUS



Figure 4. Hieronymus Fracastorius

Physician, astronomer, a naturalist, a poet and a philosopher, 1483-1553 (Fig. 4). The poem *Syphilis sive morbus gallicus* was published by Fracastor in 1530.

In *De morbis contagiosis*, printed in Venice in 1546, Fracastor describes the cause of syphilis and appears as a precursor of bacteriology. Fracastor was born in 1483 within a well-known medical family. He studied the Fine Arts, Mathematics and Medicine in Padova [5-9].

ISOMORPHIC SIGN

Development of lesions after injury [10-12].

BIEDERMAN SIGN

A dusky redness of the lower portion of the anterior pillars of the fauces in certain cases of syphilis [13].

JOSEPH B. BIEDERMAN

Australian physician, (1907-...).

BITOT SIGN

Bitot's spots are the buildup of keratin debris located superficially in the conjunctiva, which are oval, triangular or irregular in shape. These spots are a sign of vitamin A deficiency and are associated with conjunctival xerosis. In 1863, Pierre Bitot, first described these spots [14].

PIERRE ALAIN BITÔT

French physician, anatomist and surgeon, (1822-1888). He attended medical school in Bordeaux, qualifying in 1846. He gained his M.D. in 1848 from the faculty of Paris, and joined the anatomy department in Bordeaux. He became Professor of anatomy in 1854, and gained his *Chirurgien des Hôpitaux* in 1878. Bitôt published on a wide variety of topics, ranging from hare lip to studies of the best form of ligatures to use in limb amputations, the use of quinine sulphate to prevent fever following blood transfusions, as well as some aspects of cerebral anatomy and function [15].

BORSIERI SIGN

Positive if white line that results when fingernail drawn across skin subsequently turns red; seen in early scarlet fever [16,17].

GIOVANNI BATTISTA BORSIERI DE KANIFELD

Italian parasitologist, (1725-1785). Physician and medical writer. Pupil of Morgagni and Vallisneri, taught medical clinics at the University of Pavia. He wrote, in Latin, a very popular book, *Institutiones medicinae practicae* (1781-1789), which was later translated into Italian and English. Borsieri recommended the use of emetic tartar against tapeworms; also, in *De anthelminthica argenti vivi facultate* (1753) he reported on the successful use of mercury for the expulsion of roundworms.

DEMARQUAY SIGN

Absence of elevation of the larynx during deglutition, said to indicate syphilitic induration of the trachea.

JEAN NICHOLAS DEMARQUAY

French surgeon, 1814-1875 (Fig. 5). In 1863, became the first to record the observation of microfilariae in fluid extracted from a hydrocoele (another common symptom of lymphatic filariasis) [19].



Figure 5. Jean Nicholas Demarquay

FROSTED GLASS SIGN

syn. Hair in the eye sign

Inflamed and thickened eyelids which curl in upon themselves, inverting the eyelashes, which begin to scratch the cornea causing a frosted glass appearance and blindness. An indication of infection by zoonotic *Chlamydia trachomatis* transmitted by the fly known as *Musca sorbens*. Also known as Frosted Glass sign [9].

HONEYCOMB SIGN CELSI

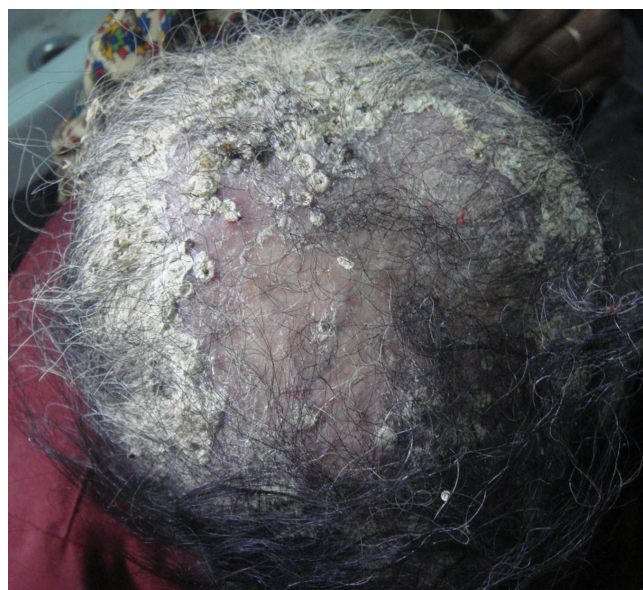

Figure 6. Honeycomb sign Celsi

There are three type of tinea capitis, microsporiasis, trichophytosis, and favus (Fig. 6). Favus is caused by *T. schoenleii*, and is endemic in South Africa and the Middle East. It is characterized by a number of yellowish, circular, cup-shaped crusts (scutula) grouped in patches like a piece of honeycomb, each about the size of a split pea, with a hair projecting in the center. These increase in size and become crusted over, so that the characteristic lesion can only be seen around the edge of the scab [20-22].

AULUS AURELIUS CORNELIUS CELSUS

(25 BC-AD 50) was a Roman writer on medicine and surgery (Fig. 7). He wrote several works, of which only one remains entire, his treatise *De Medicina* in eight books. Probably lived in Gallia Narbonensis.

(ur. ok. 25 p.n.e., zm. ok. 50), pisarz rzymski w medycynie i chirurgii. Napisał wiele dzieł, z których tylko jedno pozostaje kompletne jego traktat *De Medicina* w ośmiu ksiągach. Mieszkał prawdopodobnie w Gallia Narbonensis [6].



Figure 7. Aulus Aurelius Cornelius Celsus

GERDY SIGN

In typical plaques of alopecia areata, the diagnosis is easy to do, because these features are clear: precise edges, glowing skin and hair with orthostatic around as an exclamation point [23].

REFERENCES

1. Quintero RA, Johnson MP, Mendoza G, Evans MI: Ontogeny of clenched-hand development in trisomy 18 fetuses: A serial transabdominal fetoscopic observation. *Fetal Diagn Ther.* 1999;14:68-70.

2. Škodrić-Trifunović V, Vučinić V, Simić-Ogrizović S, Stević R, Stjepanović M, Ilić K, et al: *Srp Arh Celok Lek.* 2012;140:768-71.
3. Zhao B, Mochhala SM, Tham SY: Biologically active components of *Physostigma venenosum*. *J Chromatogr B Analyt Technol Biomed Life Sci.* 2004;812:183-92.
4. Brzeziński P, Sinjab AT, Campbell CM, Kentorp N, Sand C, Karwan K: *Dermatology eponyms – phenomenon / sign – lexicon – (supplement).* *Our Dermatol Online.* 2012;3:147-55.
5. Brzeziński P, Sanaei-Zadeh H, Tubbs S, Bonifaz A, Arenas R, Royer-Bégyn M: *Dermatology eponyms – phenomenon / sign – dictionary (B)*
6. Brzeziński P, Passarini B, Nogueira A, Sokolowska-Wojdyło M: *Dermatology eponyms – phenomenon / sign – dictionary (C).* *N Dermatol Online.* 2011;2:81-100.
7. Brzeziński P: *Dermatology eponyms – phenomenon / sign – lexicon (E).* *Our Dermatol Online.* 2011;2:235-240.
8. Brzeziński P, Godoy Gijón E, López-López J, Toyokawa T, Scrimshaw NS, Malard O, et al.: *Dermatology eponyms – phenomenon / sign – lexicon (F).* *Our Dermatol Online.* 2012;3:66-78.
9. Brzeziński P, Pessoa L, Galvão V, Barja Lopez JM, Adaskevich U, Niamba PA, et al.: *Dermatology Eponyms – Sign – Lexicon – (H).* *Our Dermatol Online.* 2013;4:130-43.
10. Sobhy N, Atia A, Elramly M: Some modifications in transplantation of autologous non-cultured melanocytes-keratinocytes suspension in treatment of segmental and focal vitiligo (Egyptian experience in Alexandria University). *Our Dermatol Online.* 2013;4:5-10.
11. Ajith P, Kannangara, Alan B, Fleischer, Gil Yosipovitch: The Sparing Phenomenon. A case series of the inverse Koebner and related phenomena. *Our Dermatol Online.* 2013;4:35-9.
12. Falguni Nag, Arghyaprasun Ghosh, Gobinda Chatterjee, Nidhi Choudhary: Lichen planus pigmentosus: two atypical presentation. *Our Dermatol Online.* 2013;4:78-9.
13. Biederman JB: Diagnostic Sign, A Preliminary Report of Another. *Am J Syph Neurol.* 1934;3:306.
14. Kheir AE, Dirar TO, Elhassan HO, Elshikh MA, Ahmed MB, Abbass MA: Xerophthalmia in a traditional Quran boarding school in Sudan. *Middle East Afr J Ophthalmol.* 2012;19:190-3.
15. <http://www.whonamedit.com/doctor.cfm/3215.html>
16. Opstelten W, Eekhof JA, Knuistingh Neven A: [Childhood diseases with exanthema]. *Ned Tijdschr Geneesk.* 2011;155:A3671.
17. Patel LM, Lambert PJ, Gagna CE, Maghari A, Lambert WC: Cutaneous signs of systemic disease. *Clin Dermatol.* 2011;29:511-22
18. Amici RR: The history of Italian parasitology. *Vet Parasitol.* 2001;98:3–30.
19. Terranella A, Eigiege A, Gontor I, Dagwa P, Damishi S, Miri E, et al: Urban lymphatic filariasis in central Nigeria. *Ann Trop Med Parasitol.* 2006;100:163-72.
20. Brzeziński P, Sinjab AT, Masferrer E, Gopie P, Naraysingh V, Yamamoto T, et al: *Dermatology Eponyms – sign –Lexicon (G).* *Our Dermatol Online* 2012;3:243-57.
21. Hassan I, Mashkooor W, Hassan Z: Extensive favus – clinical images. *N Dermatol Online* 2011;2:25-6.
22. Saiz MS, Uribe LP, Gallardo Martínez A: [Kerion celsi]. *Rev Argent Microbiol.* 2012;44:134.
23. Sobhy N, Aly H, El Shafee A, El Deeb M: Evaluation of the effect of injection of dutasteride as mesotherapeutic tool in treatment of androgenetic alopecia in males. *Our Dermatol Online.* 2013;4:40-5.