

# Dermatologic Emergencies CME Part I: Inflammatory disorders, angioedema, and anaphylaxis

**Mohammed Shanshal**

*Department of Dermatology, Basildon University Hospital NHS Foundation Trust, UK*

**Corresponding author:** Mohammed Shanshal, MD, E-mail: Mohammed.Shanshal@nhs.net

## ABSTRACT

Early detection of erythroderma is essential in clinical practice since the related systemic implications might be fatal. It is characterized by widespread redness with a highly variable degree of scaling. Most of cases have an underlying skin problem or a systemic disorder that is known to be related to erythroderma. Idiopathic erythroderma occurs in about 30% of cases. Generalized pustular psoriasis is a rare and life-threatening variant of psoriasis manifests with successive crops of pustules on a background of red and tender skin that covers most of the body. Erythroderma and generalized pustular psoriasis are typically managed with hospitalization, supportive measures, and specialist care.

**Key words:** Erythroderma; Anaphylaxis; Angioedema; Skin failure; Generalized pustular psoriasis

## WHAT IS ALREADY KNOWN ABOUT THIS TOPIC?

Various primary dermatologic conditions can present in a life-threatening manner, with high mortality and morbidity rates without adequate early intervention.

## WHAT DOES THIS REVIEW ADD?

Participants should be able to identify the distinguishing features of the main dermatologic emergencies, the common pitfalls in making their diagnosis, and the appropriate early intervention strategies.

Variety of primary dermatological conditions can present as an emergency, in some cases due to **primary** skin failure, and in others, dermatological disease may imply secondary life-threatening internal organ complications. Acute skin failure (ASF) is defined as the loss of normal temperature control with an inability to maintain the core body temperature and failure to prevent percutaneous loss of fluid, electrolytes, and protein, resulting in the imbalance and failure of the mechanical barrier to prevent penetration of foreign materials [1]. It represents

a dermatological emergency requiring urgent care through a multidisciplinary approach comparable to other organ failures such as heart, respiratory and renal failure. To avoid adverse outcome, prompt identification and appropriate management of dermatologic emergencies are crucial.

The first section of this CME series reviews cutaneous inflammatory disorders, angioedema, and anaphylaxis

## INFLAMMATORY CUTANEOUS DISORDERS

### • Erythroderma (Exfoliative dermatitis)

Erythroderma is a potentially life-threatening condition characterized by diffuse erythema and scaling that involves at least 90% of the body surface area. Clinical diagnosis of erythroderma can be problematic, as it constitutes the final clinical endpoint of a broad spectrum of skin and systemic diseases (Table 1). Other manifestations of erythroderma include severe pruritus, diffuse alopecia, palmoplantar keratoderma, nail dystrophy, ectropion, lymphadenopathy, tachycardia, and peripheral

**How to cite this article:** Shanshal M. Dermatologic Emergencies CME Part I: Inflammatory disorders, angioedema, and anaphylaxis. Our Dermatol Online. 2022;13(4):475-482.

**Submission:** 18.06.2022; **Acceptance:** 01.10.2022

**DOI:** 10.7241/ourd.20224cme.1

edema [2,3]. Major systemic complications include loss of fluid and electrolytes, hypoalbuminemia, thermoregulatory disturbance, capillary leak syndrome, heart failure, infections, and even death [4].

Defining the underlying cause of erythroderma represents a challenge and must include a thorough history, complete clinical examination, and profound clinicopathological

correlation with or without immunohistochemistry. Despite a comprehensive evaluation, the cause may remain unrecognized (idiopathic erythroderma) in approximately 25%–30% of cases [5,6].

### Treatment

The treatment approach should include discontinuing all non-essential medications and adequate workup to address the underlying causes combined with supportive measures (Fig. 1). Sedating antihistamines may be used to ease severe pruritus, and systemic corticosteroids may be necessary for severe idiopathic and drug-related erythroderma [7]. Cyclosporine, acitretin, methotrexate, and biologics are among the most commonly used drugs for the treatment of erythroderma [8,9].

**Table 1:** The most important causes of erythroderma [10,11]

- Erythroderma secondary to preexisting inflammatory dermatosis  
Psoriasis\*, dermatitis, pityriasis rubra pilaris
- Hypersensitivity drug reaction
- Uncommon causes  
Lichen planus, immunobullous disorders\*\*, ichthyosis, papuloerythroderma of Ofuji, infections (dermatophytosis, crusted scabies, SSSS)
- Malignancy-related erythroderma  
Cutaneous lymphoma (cutaneous T cell lymphoma, sezary syndrome), other lymphomas (Hodgkin's, non-Hodgkin's), leukemias, and solid organ malignancies
- Systemic causes  
Hypereosinophilic syndrome, graft-versus-host disease, mastocytosis, sarcoidosis, connective tissue diseases (dermatomyositis, subacute lupus erythematosus)
- Idiopathic erythroderma^  
Most patients with idiopathic type will eventually be diagnosed with atopic dermatitis, drug reaction, or CTCL.

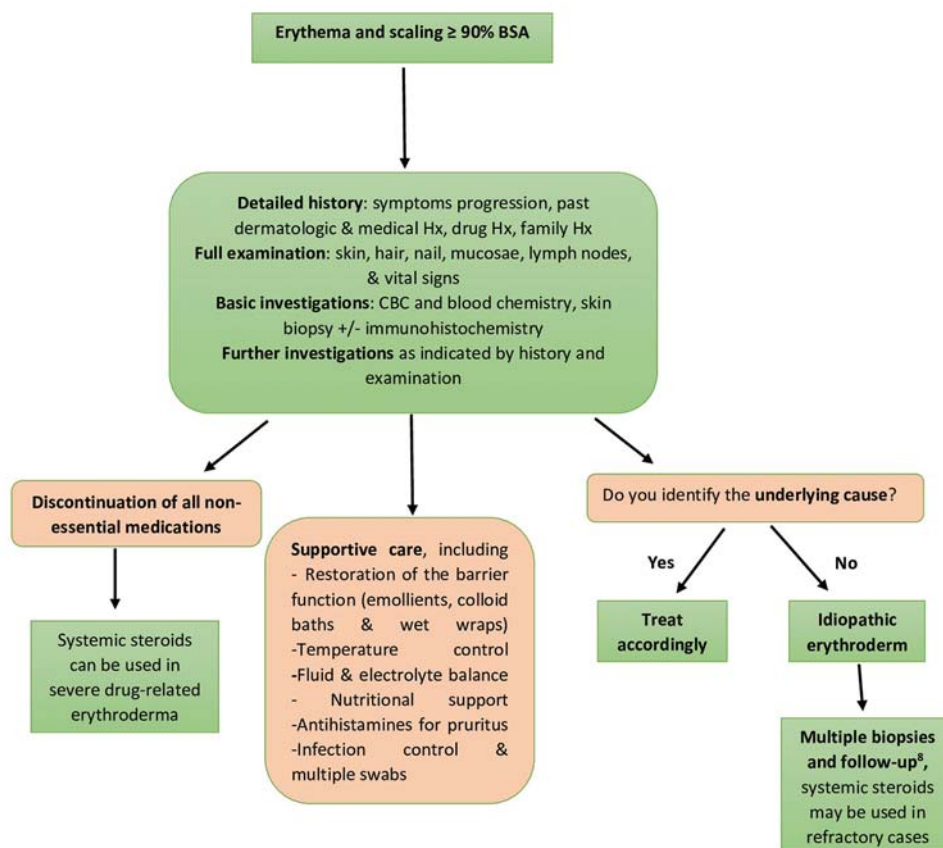
\*usually follows the abrupt withdrawal of systemic steroids or other immunosuppressive agents

\*\*specifically pemphigus foliaceus

^sometimes referred to as "red man syndrome"

### • Acute generalized pustular psoriasis (AGPP)

While psoriasis is rarely seen as a life-threatening condition, emergency medical care is required in patients with erythrodermic and acute generalized pustular psoriasis [16].



**Figure 1:** Erythroderma. Approach to patients with erythroderma includes identifying and removing the possible underlying triggers and supportive care [14,15].

**Practical pearls**

- Patients presented with erythroderma needs urgent medical attention to avoid a variety of medical complications
- Multiple skin biopsies are required to improve diagnostic accuracy
- Nail findings may be a useful indication for the underlying pathology as pitting provides a clue of psoriasis
- Severe pruritus in erythrodermic patient is mainly seen in atopic dermatitis and Sezary syndrome
- Steroid administration in patients with psoriasis may precipitate a life-threatening flare, so it is essential to distinguish the psoriasis-related erythroderma from other causes [12]
- Underlying causes can be summarized by the mnemonic “SCALPID” [13]
  - Seborrheic/Stasis dermatitis
  - Contact dermatitis
  - Atopic dermatitis/ Autoimmune disease (systemic lupus, dermatomyositis, bullous pemphigoid, pemphigus foliaceus)
  - Lymphoma/Leukemia and solid organ malignancy
  - Psoriasis/PRP
  - Infection (dermatophytosis) /Infestation (Norwegian scabies)/ ichthyoses
  - Drugs

AGPP (also known as von Zumbusch psoriasis) is characterized by abrupt onset, widespread, painful erythema studded with extensive sterile pinpoint-sized pustules, particularly flexures. The pustules often coalesce and expand to form lakes of pus, and subungual pus collection may lead to nail avulsion. AGPP is often accompanied by prominent systemic symptoms such as fever, malaise, and polyarthralgia. Potential life-threatening complications may occur during the course of AGPP, including neutrophilic cholangitis, interstitial pneumonitis, acute renal failure, sepsis and death [17,18].

AGEP can be induced by drugs, especially abrupt corticosteroid withdrawal, infections, hypocalcemia, psychological stress, and pregnancy (also known as impetigo herpetiformis) [19-21].

Diagnostic criteria have been proposed including recurrent episodes of typical cutaneous eruption accompanied by systemic manifestations, laboratory abnormalities

(leukocytosis, elevated erythrocyte sedimentation rate or C-reactive protein, hypoalbuminemia, etc.), and findings of Kogoj spongiform pustules on histopathological examination [22].

**Treatment**

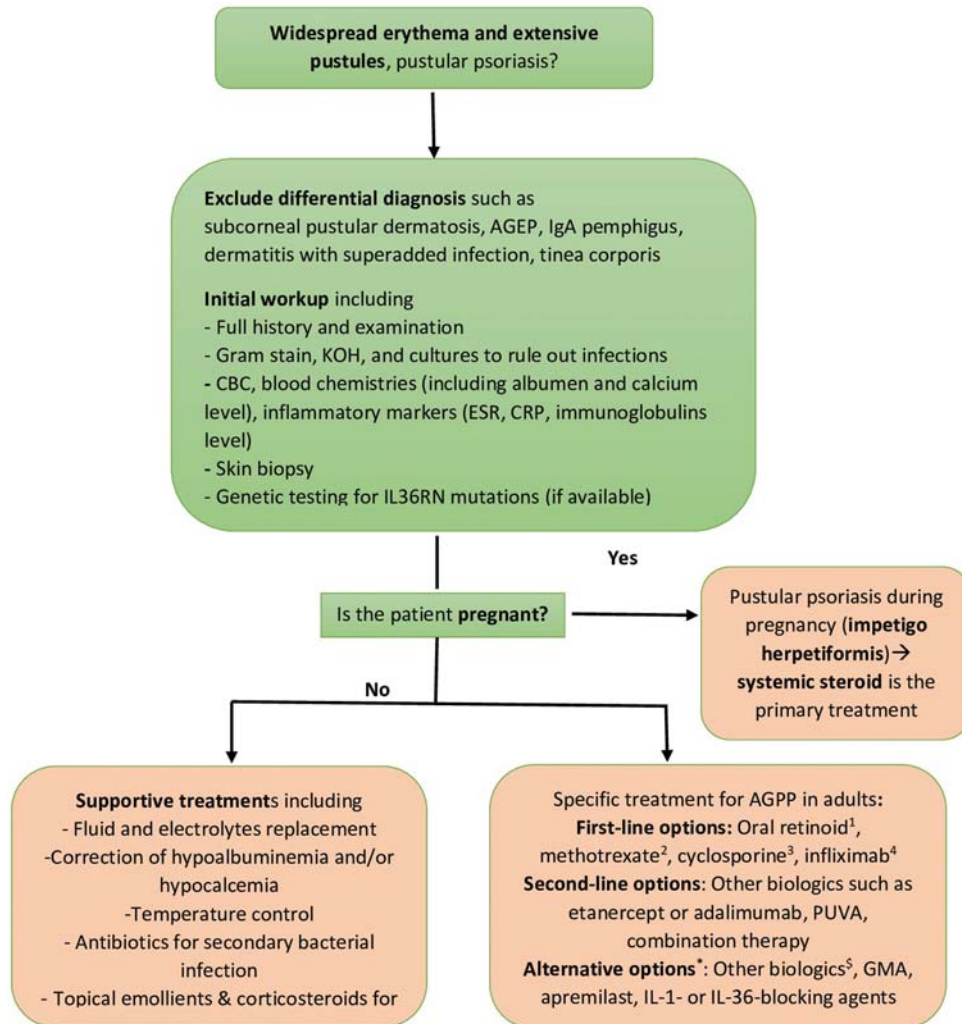
Hospital admission and supportive treatment are necessary for severe cases. The first-line treatments include acitretin, cyclosporin A, methotrexate, or infliximab. Other therapeutic options include other biologics such as etanercept or adalimumab, PUVA, and combination therapy (Fig. 2) [23,24]. A monoclonal antibody against the interleukin-36 receptor shows promising results in phase 2 trials irrespective of the IL36RN mutation [25].

**Practical pearls**

- AGPP is induced by discontinuation or dose tapering of systemic steroids. In addition to the significant adverse effects of long-term steroid therapy. Therefore, their use in the presence of safer therapeutic options is not advisable. The only exception is pustular psoriasis during pregnancy (impetigo herpetiformis), in which systemic steroids are the preferred treatment.
- No RCTs have compared the efficacy of the first-line drugs used to treat GGP (acitretin, cyclosporin A, methotrexate) with each other's or placebo. Hence, the selection of the first-line agent depends on patient's age, comorbidities and preference, and the duration of treatment.
- In September 2022, FDA approved the first Interleukin-36 Receptor Antagonist, Spesolimab, as a treatment option for generalized pustular psoriasis flares in adults.

**ANGIOEDEMA, ANAPHYLAXIS AND RELATED DISORDERS****● Angioedema**

Angioedema is a common presentation in the ED, and it could be fatal when involving the airway; hence prompt diagnosis and proper management are vital. Angioedema is characterized by the abrupt onset of non-pitting and non-pruritic swelling that involves the reticular dermis and subcutaneous and submucosal layers [26]. Lesions are typically well-defined, asymmetric in distribution, and are located in non-dependent areas. Common locations include the face, especially the



**Figure 2:** Approach to patients with acute generalized pustular psoriasis. 1 Acitretin is the preferred oral retinoid, teratogenic and effective contraception is essential. 2 Slower onset of action; blood, liver, and kidney monitoring is required. 3 Rapid onset of action; blood pressure and renal function monitoring is necessary. 4 provides quick response in severe cases. 5 Newly approved interleukin-36 receptor inhibitor \* Based on limited case reports. \$ Ustekinumab (anti-IL-12/23), secukinumab and ixekizumab (anti-IL-17A), brodalumab (anti-IL-17 receptor A), guselkumab (anti-IL-23). AGEP= Acute generalized exanthematous pustulosis, GMA= granulocyte and monocyte apheresis.

lips and periorbital area; the extremities; genitalia; and abdominal viscera. In contrast to urticaria, angioedema typically lasts from 24 to 96 h [27].

Histamine mediates the most common pathophysiologic mechanism of angioedema in ED (allergic or histaminergic angioedema); however, physicians should be alert to the less common forms mediated by bradykinin (non-allergic or non-histaminergic angioedema) that do not respond to the usual treatment of histaminergic angioedema. Therefore, identifying a particular type of angioedema is crucial for proper treatment [28] (Table 2).

Angioedema is a clinical diagnosis based on suggestive history and physical examination. There is no laboratory

test to differentiate histamine from bradykinin-mediated angioedema. Laboratory tests may help identify the underlying triggering allergens, infections, or systemic diseases. Measurement of C1 inhibitor, C4, and C1q levels may help in the diagnosis of hereditary and acquired angioedema associated with C1 inhibitor abnormalities [29,30] (Fig. 3).

## Treatment

Assessment and securing airway patency are essential for patients presenting with angioedema in or near the airway. Patients with angioedema associated with anaphylaxis should be treated with intramuscular adrenaline, fluids, oxygen, and other supportive measures [31].

Antihistamines and corticosteroids are the main therapeutic agents for less severe mast cell-mediated angioedema [32]. The treatment options for acute attacks of hereditary angioedema include C1 inhibitor concentrate, ecallantide, icatibant, and fresh frozen plasma if the aforementioned treatments are not available [33].

**Practical pearls:**

- ACEi- related angioedema
  - Angioedema is a well-recognized side effect of ACEi, and it accounts for about one-third of angioedema-related ED visits. It commonly occurs in the first year after ACEi use; however, late presentation may occur years following stable ACEi therapy [34,35].
  - Swelling of the tongue can rapidly progress and compromise the airways. Hence, it is a significant predictor for urgent hospitalization, laryngoscopy, and tracheal intubation [36,37].
  - Further attacks may occur even after ACEi withdrawal and switching to other antihypertensive agents.
- Patients who experienced angioedema with anaphylaxis should be supplied with epinephrine autoinjectors and an emergency card or anaphylaxis alert bracelet.
  - All patients with a positive family history of HAE should be screened as soon as possible as they are at risk of HAE attack

**● Anaphylaxis**

Anaphylaxis is a severe, life-threatening generalized or systemic hypersensitivity reaction caused by the sudden release of mast cells and basophils mediators into the

circulation. Anaphylaxis is characterized by gradual onset, life-threatening bronchospasm, circulatory collapse, and gastrointestinal symptoms and is usually associated with skin and mucosal urticarial/angioedema lesions [40].

Common triggers include food, drugs, contact allergens, and insect bites; however, sometimes, no trigger can be identified despite careful evaluation (idiopathic anaphylaxis). Anaphylaxis rarely complicates dermatologic conditions and/or therapeutic modalities (Table 3). The World Allergy Organization clinical

**Table 3:** Dermatologic causes of anaphylaxis

<ul style="list-style-type: none"> <li>● urticaria including physical (inducible) subtype</li> <li>● Contact urticaria</li> <li>● Hyperimmunoglobulin E syndrome</li> <li>● Mastocytosis</li> <li>● Patch testing</li> <li>● Bites and stings</li> <li>● Drug reactions including local anesthetics, soft tissue fillers, sclerotherapy, and topical medications (e.g. bacitracin, chlorhexidine)</li> <li>● Intravenous Immunoglobulin (IVIg) therapy in patients with IgA deficiency</li> <li>● Phototherapy in patients with solar urticaria</li> <li>● Hemin therapy for acute porphyria</li> </ul>
---

**Table 4:** 2011 World Allergy Organization clinical criteria for anaphylaxis [44]

<p>If any one of the following <i>three criteria</i> are met, anaphylaxis is highly probable</p> <ul style="list-style-type: none"> <li>● <i>Acute onset</i> of symptoms involving the skin, mucosal tissues, or both accompanied by at least one of the following: respiratory symptoms, hypotension, and/or end-organ dysfunction</li> <li>● Exposure to a <i>probable allergen</i> that is quickly followed by <math>\geq 2</math> of the following: respiratory symptoms, hypotension, skin-mucosal tissue involvement, persistent gastrointestinal symptoms</li> <li>● Age-related low systolic pressure<sup>§</sup> or &gt;30% decrease in systolic blood pressure compared to baseline, following exposure to a <i>known allergen</i></li> </ul>
---

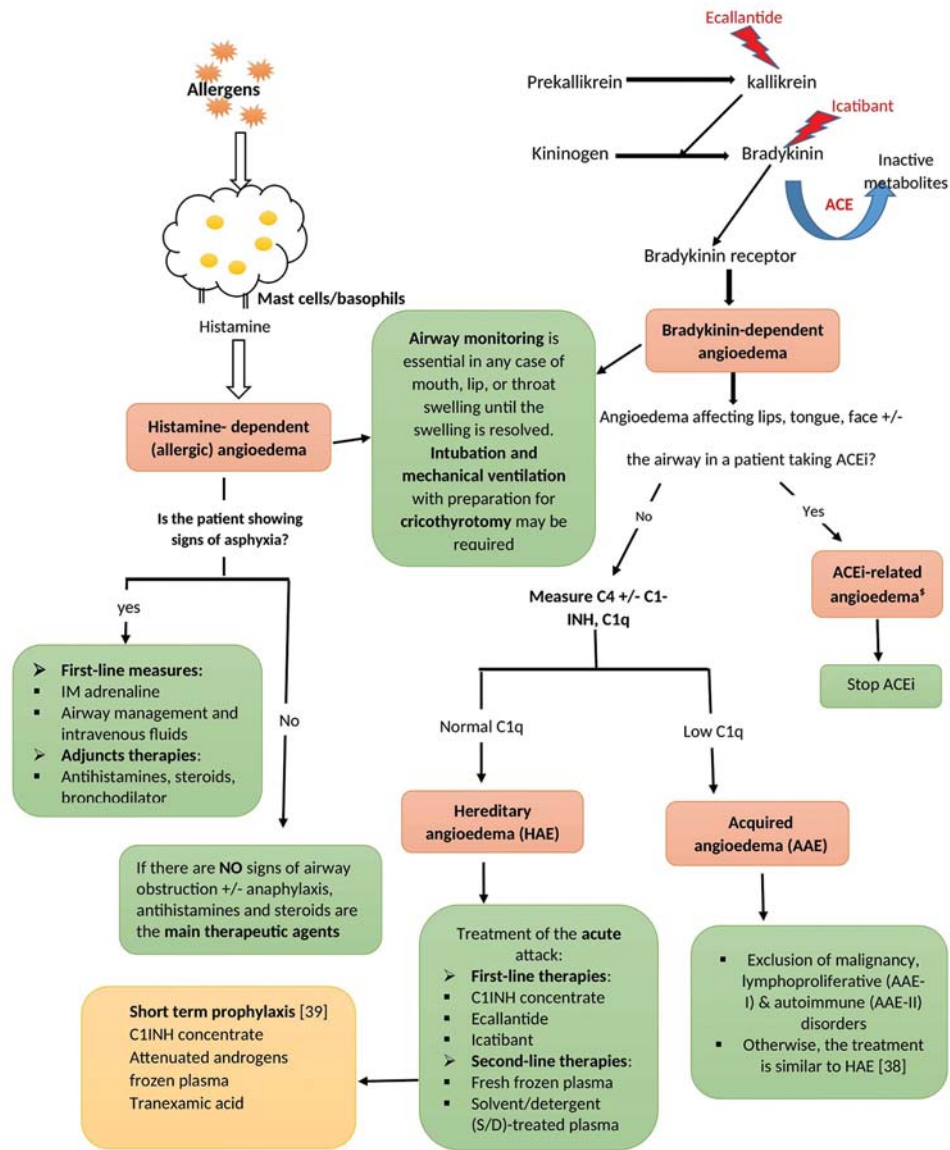
<sup>§</sup> low systolic blood pressure in adult is <90 mm Hg, while in infants and children it is defined as <70 mm Hg from 1 month to 1 year; <[70 mm Hg + 2 × age] from 1-10 years; and <90 mm Hg from 11-17 years

**Table 5:** Biologics and Anaphylaxis

<ul style="list-style-type: none"> <li>● Despite being a real game-changer in treating numerous skin diseases, biologics can also induce significant adverse reactions, including anaphylaxis.</li> <li>● Anaphylaxis is not a rare complication of infliximab, a tumor necrosis factor- alpha [TNF<math>\alpha</math>] inhibitor; hence an initial small testing dose should be administered in a highly controlled specialized center [45].</li> <li>● Episodic (interrupted) treatment with infliximab should be avoided as it can increase the risk of infusion reaction due to the formation of neutralizing antibodies.</li> <li>● The use of corticosteroids +/- antihistamines as pre-medications does not modify the risk of acute infliximab reaction in many trials [46].</li> <li>● Rituximab is a monoclonal antibody to CD20 (B-cell marker CD20) that showed promising results in the treatment of autoimmune bullous dermatoses. Rituximab is associated with severe infusion reactions, including anaphylaxis, especially during the first infusion. Slow infusion, stopping antihypertensive medications, vital sign monitoring, and using pre-medications may reduce the incidence of a severe allergic reaction to rituximab.</li> <li>● Anaphylaxis has been rarely reported with other biologics including, TNF<math>\alpha</math> inhibitors, IL-17 inhibitors, ustekinumab, dupilumab, omalizumab, and rituximab [47-49].</li> </ul>
--

**Table 2:** Types of angioedema according to pathogenesis

	<b>Histamine-mediated angioedema</b>	<b>Bradykinin-mediated angioedema</b>
Prevalence	More common	Rare
Onset	Occurs rapidly after exposure to an allergen (minutes)	Usually slower, progressive onset (over hours)
Duration of attack	24–<48 hours	> 48 hours
Urticaria and pruritus	May occur	Usually absent
Hypotension +/- wheeze	May occur	Usually absent
Abdominal pain +/- swelling	Usually absent	May occur
Response to steroids, histamine & epinephrine	Responsive	Non-responsive



**Figure 3:** Angioedema. Main types of angioedema, pathogenesis, diagnostic and therapeutic approach. \$ Although the diagnosis is usually based on history, measurement of C4, C1q, and C1 inhibitor levels is essential to distinguish ACEI-related angioedema from hereditary angioedema.

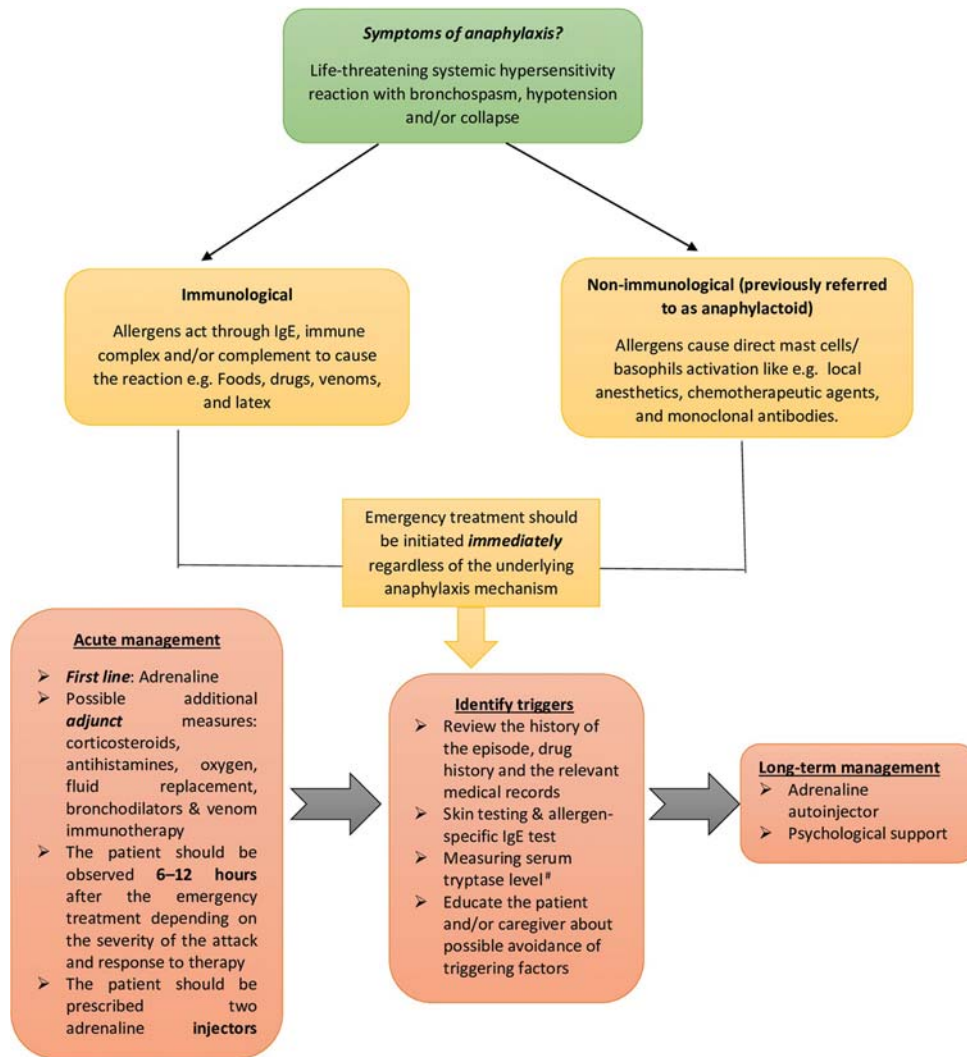
criteria for the diagnosis of anaphylaxis are summarized in Table 4.

### Treatment

Anaphylaxis is a serious and potentially life-threatening event that must be immediately treated with epinephrine, regardless of the underlying pathophysiological mechanism. Intramuscular adrenaline is considered the first-line intervention that can be repeated every 5-10 min Figure 4. Adjunct measures include removal of the trigger and call for help, oxygen, fluid resuscitation, antihistamines, glucocorticosteroids, and inhaled short-acting beta-2-agonists [41-43]. Anaphylaxis related to the use of biological agents is discussed in Table 5.

**Practical pearls**

- All patients with anaphylaxis should be educated about the condition, possible trigger avoidance, and the risk of recurrence.
- All Patients at risk of subsequent attacks should be provided with epinephrine autoinjector, like EpiPen®
- Patients taking  $\beta$ -blockers may have a limited response to epinephrine.
- Patients with cardiovascular diseases, uncontrolled hyperthyroidism, aortic aneurysm, recent intracranial surgery, and patients receiving tricyclic antidepressants or monoamine oxidase inhibitors need close monitoring as there is increased risk of epinephrine side effects.



**Figure 4:** Anaphylaxis. Flow chart for the management approach of anaphylaxis. \* NICE guidelines recommend measuring tryptase on two occasions, immediately after the emergency treatment of anaphylaxis and a second sample ideally within 1–2 hours of the onset of symptoms [50].

## REFERENCES

- Irvine C. 'Skin Failure'—A Real Entity: Discussion Paper. *J R Soc Med.* 1991;84:412-3.
- Li J, Zheng HY. Erythroderma: a clinical and prognostic study. *Dermatology.* 2012;225:154-62.
- Sehgal VN, Srivastava G, Sardana K. Erythroderma/exfoliative dermatitis: a synopsis. *Int J Dermatol.* 2004;43:39-47.
- Bruno TF, Grewal P. Erythroderma: a dermatologic emergency. *CJEM.* 2009;11:244-6.
- Megna M, Sidikov AA, Zaslavsky DV, Chuprov IN, Timoshchuk EA, Egorova U, et al. The role of histological presentation in erythroderma. *Int J Dermatol.* 2017;56:400-4.
- Sigurdsson V, Toonstra J, van Vloten WA. Idiopathic erythroderma: a follow-up study of 28 patients. *Dermatology.* 1997;194:98-101.
- Sterry W, Steinhoff M. Erythroderma. In: Jean L Bologna, Joseph L Jorizzo, Julie V Schaffer. *Dermatology.* 4<sup>th</sup> edition. Philadelphia: Elsevier Saunders; 2016. 182-83.
- Ohga Y, Bayaraa B, Imafuku S. Therapeutic options and prognosis of chronic idiopathic erythroderma in older adults. *Dermatol Ther.* 2019;32:e12977.
- Zattra E, Fortina AB, Peserico A, Alaibac M. Erythroderma in the era of biological therapies. *Eur J Dermatol.* 2012;22:167-71.
- Zhang P, Chen HX, Xing JJ, Jin Z, Hu F, Li TL, et al. Clinical analysis of 84 cases of erythrodermic psoriasis and 121 cases of other types of erythroderma from 2010–2015. *J Huazhong Univ Sci Technolog Med Sci.* 2017;37:563-7.
- Rothe MJ, Bernstein ML, Grant-Kels JM. Life-threatening erythroderma: diagnosing and treating the “red man.” *Clin Dermatol.* 2005;23:206-17.
- Rice SA, Swale VJ, Haque R, Rustin MH. Erythroderma in the emergency department. *BMJ.* 2013;13:346.
- Mistry N, Gupta A, Alavi A, Sibbald RG. A review of the diagnosis and management of erythroderma (generalized red skin). *Adv Skin Wound Care.* 2015;28:228-36.
- Cuellar-Barboza A, Ocampo-Candiani J, Herz-Ruelas ME. A practical approach to the diagnosis and treatment of adult erythroderma. *Actas Dermosifiliogr (Engl Ed).* 2018;109:777-90.
- Dobson JS, Levell NJ. Erythroderma. *Medicine.* 2017;45:417-21.
- Akiyama M. Early-onset generalized pustular psoriasis is representative of autoinflammatory keratinization diseases. *J Allergy Clin Immunol.* 2019;143:809-10.
- Hoegler KM, John AM, Handler MZ, Schwartz RA. Generalized pustular psoriasis: a review and update on treatment. *J Eur Acad Dermatol Venereol.* 2018;32:1645-51.
- Navarini AA, Burden AD, Capon F, Mrowietz U, Puig L, Köks S,

- et al, ERASPEN Network, Bachelez H. European consensus statement on phenotypes of pustular psoriasis. *J Eur Acad Dermatol Venereol.* 2017;31:1792-9.
19. Elston GE, Charles-Holmes R, Carr RA. Precipitation of generalized pustular psoriasis by prednisolone. *Clin Exp Dermatol.* 2006;31:133-4.
  20. Luan L, Han S, Zhang Z, Liu X. Personal treatment experience for severe generalized pustular psoriasis of pregnancy: two case reports. *Dermatol Ther.* 2014;27:174-7.
  21. de Moura CA, de Assis LH, Góes P, Rosa F, Nunes V, Gusmão ÍM, et al. A case of acute generalized pustular psoriasis of von Zumbusch triggered by hypocalcemia. *Case Rep Dermatol.* 2015;7:345-51.
  22. Umezawa Y, Ozawa A, Kawasima T, Shimizu H, Terui T, Tagami H, et al. Therapeutic guidelines for the treatment of generalized pustular psoriasis (GPP) based on a proposed classification of disease severity. *Arch Dermatol Res.* 2003;295(Suppl 1):S43-S54.
  23. Bachelez H. Pustular psoriasis and related pustular skin diseases. *Br J Dermatol.* 2018;178:614-8.
  24. Benjegerdes KE, Hyde K, Kivelevitch D, Mansouri B. Pustular psoriasis: pathophysiology and current treatment perspectives. *Psoriasis (Auckl).* 2016;6:131.
  25. Bachelez H, Choon SE, Marrakchi S, Burden AD, Tsai TF, Morita A, et al. Trial of spesolimab for generalized pustular psoriasis. *N Engl J Med.* 2021;385:2431-40.
  26. Cicardi M, Zuraw BL. Angioedema due to bradykinin dysregulation. *J Allergy Clin Immunol Pract.* 2018;6:1132-41.
  27. Kanani A, Betschel SD, Warrington R. Urticaria and angioedema. *Allergy Asthma Clin Immunol.* 2018;14:59.
  28. Bernstein JA, Cremonesi P, Hoffmann TK, Hollingsworth J. Angioedema in the emergency department: a practical guide to differential diagnosis and management. *Int J Emerg Med.* 2017;10:1-11.
  29. LoVerde D, Files DC, Krishnaswamy G. Angioedema. *Crit Care Med.* 2017;45:725-35.
  30. Long BJ, Koyfman A, Gottlieb M. Evaluation and Management of Angioedema in the emergency department. *West J Emerg Med.* 2019;20:587.
  31. Depetri F, Tedeschi A, Cugno M. Angioedema and emergency medicine: From pathophysiology to diagnosis and treatment. *Eur J Intern Med.* 2019;59:8-13.
  32. Sánchez-Borges M, Asero R, Ansotegui IJ, Baiardini I, Bernstein JA, Canonica GW, et al. Diagnosis and treatment of urticaria and angioedema: a worldwide perspective. *World Allergy Organ J.* 2012;5:125-47.
  33. Busse PJ, Christiansen SC. Hereditary Angioedema. *N Engl J Med.* 2020;382:1136-48.
  34. Banerji A, Blumenthal KG, Lai KH, Zhou L. Epidemiology of ACE inhibitor angioedema utilizing a large electronic health record. *J Allergy Clin Immunol Pract.* 2017;5:744-9.
  35. Kostis WJ, Shetty M, Chowdhury YS, Kostis JB. ACE inhibitor-induced angioedema: a review. *Curr Hypertens Rep.* 2018;20:55.
  36. Agah R, Bandi V, Guntupalli KK. Angioedema: the role of ACE inhibitors and factors associated with poor clinical outcome. *Intensive Care Med.* 1997;23:793-6.
  37. Howarth D. ACE inhibitor angioedema: a very late presentation. *Aust Fam Physician.* 2013;42:860.
  38. Bork K, Staubach-Renz P, Hardt J. Angioedema due to acquired C1-inhibitor deficiency: spectrum and treatment with C1-inhibitor concentrate. *Orphanet J Rare Dis.* 2019;14:65.
  39. Betschel S, Badiou J, Binkley K, Borici-Mazi R, Hébert J, Kanani A, et al. The international/Canadian hereditary angioedema guideline. *Allergy Asthma Clin Immunol.* 2019;15:1-29.
  40. Johansson SG, Hourihane JB, Bousquet J, Bruijnzeel-Koomen C, Dreborg S, Haahtela T, et al. A revised nomenclature for allergy: an EAACI position statement from the EAACI nomenclature task force. *Allergy.* 2001;56:813-24.
  41. Dhami S, Panesar SS, Roberts G, Muraro A, Worm M, Bilò MB, et al. Management of anaphylaxis: a systematic review. *Allergy.* 2014;69:168-75.
  42. Pumphrey RS. Lessons for management of anaphylaxis from a study of fatal reactions. *Clin Exp Allergy.* 2000;30:1144-50.
  43. Sampson HA, Muñoz-Furlong A, Campbell RL, Adkinson Jr NF, Bock SA, Branum A, et al. Second symposium on the definition and management of anaphylaxis: summary report—Second National Institute of Allergy and Infectious Disease/Food Allergy and Anaphylaxis Network symposium. *J Allergy Clin Immunol.* 2006;117:391-7.
  44. Simons FE, Arduzzo LR, Bilò MB, El-Gamal YM, Ledford DK, Ring J, et al, World Allergy Organization. World allergy organization guidelines for the assessment and management of anaphylaxis. *World Allergy Organ J.* 2011;4:13-37.
  45. Lichtenstein L, Ron Y, Kivity S, Ben-Horin S, Israeli E, Fraser GM, et al. Infliximab-related infusion reactions: systematic review. *J Crohns Colitis.* 2015;9:806-15.
  46. Fumery M, Tilmant M, Yzet C, Brazier F, Loreau J, Turpin J, et al. Premedication as primary prophylaxis does not influence the risk of acute infliximab infusion reactions in immune-mediated inflammatory diseases: A systematic review and meta-analysis. *Dig Liver Dis.* 2019;51:484-8.
  47. Abramowicz M, Zuccotti G, Pflomm JM. Dupilumab (Dupixent) for Asthma. *JAMA.* 2019;321:1000-1.
  48. Limb SL, Starke PR, Lee CE, Chowdhury BA. Delayed onset and protracted progression of anaphylaxis after omalizumab administration in patients with asthma. *J Allergy Clin Immunol.* 2007;120:1378-81.
  49. Cox L, Platts-Mills TA, Finegold I, Schwartz LB, Simons FE, Wallace DV. American academy of allergy, asthma & immunology/ American college of allergy, asthma and immunology joint task force report on omalizumab-associated anaphylaxis. *J Allergy Clin Immunol.* 2007;120:1373-7.
  50. Anaphylaxis: assessment to confirm an anaphylactic episode and the decision to refer after emergency treatment for a suspected anaphylactic episode. NICE (UK); 2011 Dec.

Copyright by Mohammed Shanshal. This is an open-access article distributed under the terms of the Creative Commons Attribution License, which permits unrestricted use, distribution, and reproduction in any medium, provided the original author and source are credited.

**Source of Support:** This article has no funding source.

**Conflict of Interest:** The authors have no conflict of interest to declare.