

## PURPURA FOLLOWING A RARE ETIOLOGY; A DIAGNOSTIC DILEMMA

PLAMICA POSTĘPUJĄCA O RZADKIEJ ETIOLOGII; DIAGNOSTYCZNY  
DYLEMAT

Nithya Raghunath<sup>1</sup>, Sreekar Harinatha<sup>2</sup>, Sreeharsha Harinatha<sup>3</sup>

<sup>1</sup>Department of Dermatology, MVJ Medical College and Research Hospital,  
Bangalore, India

<sup>2</sup>Department of Plastic and Reconstructive Surgery, Christian Medical College,  
Vellore, India

<sup>3</sup>Department of Urology, SMS Medical College, Jaipur, India

**Corresponding author:** Dr. Sreekar Harinatha

[drsreekarh@yahoo.com](mailto:drsreekarh@yahoo.com)

Our Dermatol Online. 2012; 3(3): 231

Date of submission: 28.03.2012 / acceptance: 18.04.2012

Conflicts of interest: None

Sir,

Jatropha Curcas poisoning is a fairly common occurrence in Indian population [1,2]. It follows ingestion of the plant's nuts. It generally manifests with complaints of vomiting, abdominal pain and diarrhea [3]. These are attributed to the Toxalbumin, Curcin and cyanic acid found in these nuts. Though it generally presents with symptoms of mild gastroenteritis, it may sometimes be severe enough to cause hypovolemic shock. We came across an 8 year old child who presented with these symptoms following consumption of the Jatropha Curcas nuts. She also presented with newly developed purpuric spots over whole of the body (Fig. 1). They were especially prominent over the knees. Her blood work-up did not reveal any other cause of the purpurae. There were no signs of vasculitis either. She was managed conservatively with fluid resuscitation. The purpuric spots resolved over 3 weeks.

We conclude that, though poisoning following Jatropha Curcas results in gastroenteritis, it can also result in purpuric spots. This is the first known dermatologic manifestation and may be misinterpreted by the unwary physician.

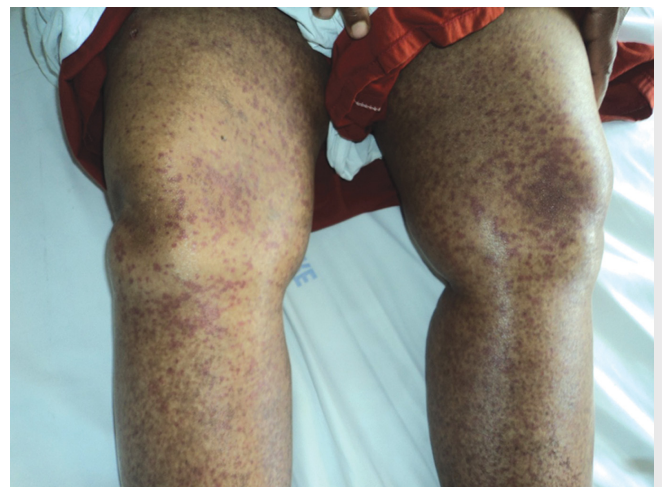


Figure 1. Multiple purpuric spots over the lower limbs

### REFERENCES

1. Kulkarni ML, Sreekar H, Keshavamurthy KS, Shenoy N: Jatropha Curcas - Poisoning. Indian J Pediatr. 2005; 72: 75-76.
2. Shah V, Sanmukhani J: Five cases of Jatropha curcas poisoning. J Assoc Physicians India. 2010; 58: 245-246.
3. Joubert PH, Brown JM, Hay IT, Sebata PD: Acute poisoning with Jatropha curcas (purging nut tree) in children. S Afr Med J. 1984; 65: 729-730.