Volume 3, Number 1, January 2012
p. 1 - 78

ISSN: 2081-9390

Issue online since Monday, January 02, 2012

NASZA DERMATOLOGIA Online

www.odermatol.com

OUR DERMATOLOGY Online

1 / 2012

Editorial Pages / Strona Redakcyjna

NASZA DERMATOLOGIA Online

OUR DERMATOLOGY Online

e-ISSN: 2081-9390

Quarterly

Our Dermatol Online

published since 01/06/2010 years

www.odermatol.com

Editor in Chief :

Piotr Brzeziński, MD PhD

Address:

ul. Andersa 5/8, 76200 Słupsk, Poland

tel. 48 692121516, fax.48 598151829

e-mail: **brzezoo77@yahoo.com**

Publisher:

Our Dermatology Online

ul. Andersa 5/8, 76200 Słupsk, Poland

tel. 48 692121516, fax.48 598151829

e-mail: **brzezoo77@yahoo.com**

Indexed in:

system of opinion of scientific periodicals INDEX COPERNICUS (3,42)
DOAJ (Directory of Open Acces Journals)
Geneva Foundation for Medical Education and Research (GFMER)
International Committee of Medical Journal Editors (ICMJE)
Bielefeld Academic Search Engine (BASE)
NewJour
Google Scholar
Open J-Gate
WorldCat
e-journal

Previous website:	since issue 1.2010 to issue 2.2010	**www.ndermatol.like.pl**
	since issue 2.2010 to issue 3.2011	**www.odermatol.like.pl**
	since issue 4.2011	**www.odermatol.com**
Previous shortcut:	since issue 1.2010 to issue 3.2011	**N Dermatol Online**
	since issue 4.2011	**Our Dermatol Online**

Open access journal:

This is an open access journal which means that all content is freely available without charge to the user or his/her institution. Users are allowed to read, download, copy, distribute, print, search, or link to the fullor texts of the articles in this journal without asking prior permission from the publisher or the author.
Our Dermatology Online is a international journal that publishes original contributions in the field of dermatology, including papers on biochemistry, morphology and immunology of the skin.
The journal is among the few not related to dermatological associations or belonging to respective societies which guarantees complete independence. Offers a platform for review articles in areas of interest for dermatologists.
OurDermatologyOnline offers article in English as well as in other languages.
This is in accordance with the BOAI definition of open access.

Editorial Board:

Al Aboud Khalid, MD (Saudi Arabia)
Abreu-Velez Ana Maria, MD Ph.D (USA)
Abreu Hilda, MD (Urugway)
Adaskevich Uladzimir, Prof. (Belarus)
Aghaei Shahin, MD (Iran)
Amichai Boaz, MD (Israel)
Arenas Roberto, MD (Mexico)
Asuquo Maurice Efana (Nigeria)
Bharti Rakesh, MD (India)
Bonifaz Alexandro, MD (Mexico)
Bukhari Iqbal A., MD (Saudi Arabia)
Chamcheu Jean Christopher, Ph.D (USA)
Chang Patricia, MD Ph.D (Guatemala)
Chuh An Tung Antonio, Prof. (Hong Kong)
Crump Vincent, MD (New Zealand)
Daboul Mohamed Wael, MD (Syria)
Darkoska Jovanka, MD (Macedonia)
Doganay Mehmet, Prof. (Turkey)
Dong Huiting, Prof. (China)
Drljević Irdina, MD, Ph.D. Ass. Prof. (Bosnia and Herzegovina)
Dubakienė Rūta, Prof. (Lithuania)
Fernandez-Flores Angel, MD, PhD (Spain)
Grattan Clive, MD (United Kingdom)
Guzmán Antonio, MD (Paraguay)
Hashimoto Takashi, MD (Japan)
Hassan Iffat, MD (India)
Howard I. Maibach, Prof. (USA)
Hysi Katerina, MD (Albania)
Janjua Shahbaz, MD (Pakistan)
Jordán Rodriguez Ramiro, Prof. (Bolivia)
Julian Rolando, MD (El Salvador)
Kaszuba Andrzej, Prof. (Poland)
Khamesipour Ali, MD (Iran)
Kuiate Jules-Roger, MD (Cameroon)
Lopez-Granja Jorge, MD (Belize)
Lotti Torello, Prof. (Italy)
Al-Mashaleh Manal Sulaiman, MD (Jordan)
Mikkelsen Carsten Sauer, MD (Denmark)
Mourad Mokni, Prof. (Tunisia)
Mota Luiz Alberto Alves, MD (Brazil)
Mrisho Fatma, MD (Tanzania)
Nedelciuc Boris, MD PhD (Moldova)
Nowicki Roman, Prof. (Poland)
Nwabudike Lawrence Chukwudi, MD Ph.D (Romania)
Sudip Parajuli, MD (Nepal)
Parvin Rukhsana, MD (Bangladesh)
du Plessis Jeanetta, Prof. (South Africa)
Sayad Ibrahim, Prof. (Kuwait)
Sharquie Khalifa E., Prof. (Iraq)
Shawa Mary, MD (Malawi)
Sinclair Rodney Daniel, Prof. (Australia)
Sumathipala Gayan Saranga, MD (Sri Lanka)
Tapia Felix J., MD (Venezuela)
Tatu Alin, MD (Romania)
Teixeira Roni Leonardo, MD (Brazil)
Tincopa-Wong Oscar Wilfredo, MD (Peru)
Usharani Anaparthy, MD (India)
Valdebran Manuel, MD (Dominican Republic)
Vok Marko, MD (Slovenia)
Win Oo Soe, MD (Myanmar)
Wollina Uwe, Prof. (Germany)
Wortsman Ximena, MD (Chile)
Zabielski Stanisław, Prof. (Poland)
Zoya Zaidi, MD (India)

CONTENTS

Editorial Pages 1

Original Articles

► Sujatha Vijayalekshmi, M S Padmajothi, Sujatha C, Ambika Hariharasubramony

Herpes Zoster Ophthalmicus: Clinical Profile in Adults less than 30 years of age 5
Herpes zoster ophthalmicus: kliniczny profil u dorosłych poniżej 30-go roku życia
Comment: Dr. Manuel Valdebran 9
Instituto Dermatológico y Cirugía de Piel Dr. Huberto Bogaert Díaz, Dominican Republic

► Beatriz Di Martino Ortiz

Dermatitis de interfase por drogas. De las formas leves a las severas. Una visión dermatopatológica 10
Skórne odczyny polekowe. Od łagodnych do ciężkich postaci. Dermatopatologiczny punkt widzenia

Case Report

► Hosahalli Rajaiah Yogeesh HR, Sujatha Chankramath, Hari Kishan Kumar Yadalla, Shameem Shariff, Suhas Bettadapura Ramesh, Sapnashree Budhnoor Sreekantaiah

Type 2 lepra reactions presenting with extensive cutaneous ulcerations 17
Reakcja leprotyczna typu 2-go (ENL) z rozległymi owrzodzeniami skórnymi

► Rokon Uddin, Farzana Akhter, Abu Baker

Giant Tuberculosis Verrucosa Cutis 21
Olbrzymia brodawkująca gruźlica skóry

► Iffat Hassan, Abid Keen, Parvaiz A. Shah

Facial Plexiform neurofibromatosis in a patient with neurofibromatosis type1: a case report 24
Nerwiakowłókniak splotowaty w obrębie twarzy u pacjenta z neurofibromatozą typu I: opis przypadku
Comment: Dr. Daisuke Tsuruta PhD, Dr. Takashi Hashimoto 28
Department of Dermatology, Kurume University School of Medicine, and Kurume University Institute of Cutaneous Cell Biology, Japan

► Saadia Bouraoui, Mona Mlika, Rim Kort, Fayka Cherif , Ahlem Lahmar , Sabeh Mzabi-Regaya

Miliary osteoma cutis of the face: A case report 29
Rozsiany kostniak skóry twarzy

► Iffat Hassan, Mashkoor Ahmad, Shazia Jeelani

Sebaceous Naevus Located in Nasal Cavity – A Unique Case 33
Znamię łojotokowe zlokalizowane w obrębie jamy nosowej – rzadki przypadek

► Ana Maria Abreu Velez, Michael S. Howard, Piotr Brzezinski

Immunofluorescence in multiple tissues utilizing serum from a patient affected by systemic lupus erythematosus 36
Immunofluorescencja w wielu tkankach z wykorzystaniem serum od pacjenta z toczniem rumieniowatym układowym

► Mona Mlika, Beya Chelly, Sadok Boudaya, Aida Ayadi-kaddour, Tarek Kilani, Faouzi El Mezni

Poroid hidradenoma: a case report 43
Poroid hidradenoma: opis przypadku

► Beatriz Di Martino Ortiz, Ana Soskin Reidman

Tumor cutáneo de células granulares. Descripción de tres casos y revisión de la literatura 46
Guz z komórek ziarnistych. Raport trzech przypadków i przegląd piśmiennictwa

► Anca Chiriac, Anca E Chiriac, Alina Murgu, Liliana Foia

Seborrheic dermatitis eye lid involment (seborrheic blepharitis) in children not a rare clinical observation 52
Łojotokowe zapalenie skóry powiek (seborrheic blepharitis), nie rzadkie obserwacje u dzieci
Comment: Dr. Shahbaz Janjua 54
Ayza Skin & Research Center, Pakistan

Historical Article

► Ahmad Al Aboud, Khalid Al Aboud

Gilbert Omenn and his syndrome 55
Gilbert Omenn i opisany przez niego zespół chorobowy

Clinical Images

► Patricia Chang

Dorsal Ungual Pterygium 57
Dorsal Ungual Pterygium

Letter to the Editor

► Marina Rodríguez-Martín, Desiré Díaz Melián, Miguel Sáez Rodríguez, Antonio Noda Cabrera, Marta García Bustínduy

Assessment of psychiatric disorders in vitiligo. Conclusions for our daily practice 61
Ocena zaburzeń psychicznych w bielactwie. Postępowanie w naszej codziennej praktyce
Comment: Dr. Hari Kishan Kumar Yadalla 63
M.V.J. Medical College & Research Hospital, Hoskote, Bangalore, India

Dermatology Eponyms

► Ahmad Al Aboud, Khalid Al Aboud

Separating "Bart's" apart in dermatology eponyms 64
Niezależne występowanie „Bart's" w eponimach dermatologicznych

► Piotr Brzezinski, Elena Godoy Gijón, José López-López, Takao Toyokawa, Nevin S. Scrimshaw, Olivier Malard, Cesar Bimbi

Dermatology eponyms – phenomen / sign – Lexicon (F) 66

NASZA DERMATOLOGIA Online
OUR DERMATOLOGY Online

HERPES ZOSTER OPHTHALMICUS: CLINICAL PROFILE IN ADULTS LESS THAN 30 YEARS OF AGE

HERPES ZOSTER OPHTHALMICUS: KLINICZNY PROFIL U DOROSŁYCH PONIŻEJ 30-go ROKU ŻYCIA

Vijayalekshmi Sujatha[1], Mudianur Subrahmanyam Padmajothi[1], Hariharasubramony Ambika[2], Chankramath Sujatha[2]

[1]*Department of Ophthalmology, M.V.J.Medical College & Research Hospital, Hoskote, Bangalore, India*
[2]*Department of Dermatology, M.V.J.Medical College & Research Hospital, Hoskote, Bangalore, India*

***Corresponding author**:* Dr. Vijayalekshmi Sujatha drsujatha2006@yahoo.co.in

Our Dermatol Online. 2012; 3(1): 5-8 Date of submission: 14.09.2011 / acceptance: 28.10.2011
Conflicts of interest: None

Abstract
Introduction: To establish the clinical profile of Herpes Zoster Ophthalmicus (HZO) in individuals less than 30 years of age and to correlate clinical manifestation with their immune status. **Materials and methods:** A retrospective chart review was performed of patients younger than 30 years of age who presented with HZO from June 2010 to June 2011. Data was collected on their demographics, medical history, clinical presentation, results of serological investigations, and visual outcome. A detailed evaluation of clinical profile with ocular implications and a sequel was done in each case. **Results:** The mean age of the patients was 23.25 years. Ophthalmic features presented included lid edema, ptosis, keratitis, and superficial punctate keratitis with dry eye, optic neuritis. None of them was found to be HIV positive. Final visual acuity was 20/40 or better in 90% of the subjects. **Conclusion:** Immunocompetent young adults do present with features of HZO. However, the disease spectrum in HIV-negative patients is localized, less severe, and more amenable to therapy.

Streszczenie
Wstęp: Celem pracy było stworzenie klinicznego profilu postaci ocznej półpaśca u osób poniżej 30-go roku życia oraz skorelowanie objawów klinicznych z poziomem odporności tych osób. **Materiał i metody:** Wykonano retrospektywną analizę historii chorób u pacjentów poniżej 30-go roku życia z rozpoznaniem ocznej postaci półpaśca. Zebrano dane dotyczące demografii, przebytych chorób, klinicznych objawów, wyników badań serologicznych oraz badań okulistycznych. Dokładna ocena klinicznego profilu z implikacjami okulistycznymi i dalszymi ich następstwami była przeprowadzona w każdym przypadku. **Rezultaty:** Średnia wieku pacjentów wynosiła 23,25 lat. Prezentowane objawy okulistyczne obejmowały obrzęk powiek, opadanie górnej powieki, zapalenie rogówki oraz powierzchowne, punktowane zapalenie rogówki z zespołem suchego oka a także zapalenie nerwu wzrokowego. Żaden z pacjentów nie był HIV- pozytywny. Końcowa ostrość widzenia wynosiła 20/40 lub powyżej u 90% pacjentów. **Podsumowanie:** Młodzi immunokompetentni dorośli także zapadają na oczną postać półpaśca. Jednakże spektrum choroby u osób HIV-negatywnych jest ograniczone, mniej ciężkie i bardziej podatne dla terapii.

Key words: herpes zoster ophthalmicus; Human Immunodeficiency Virus infection; immune status; young adults
Słowa klucze: herpes zoster ophthalmicus; infekcja ludzkim wirusem niedoboru odporności; stan odporności; młody dorosły

Introduction

Herpes Zoster Ophthalmicus (HZO) is a serious infection because of its implications on vision and the cosmetic blemish it leaves in addition to the distressing post herpetic neuralgia. Herpes Zoster is caused by the reactivation of the Varicella–Zoster virus lying dormant in the spinal or cerebral sensory ganglia and is commonly seen in patients with depressed cellular immunity, such as the elderly, patients on immunosuppressive therapy, and patients with lymphoma or positive HIV status [1,2]. The incidence and severity of Herpes Zoster increases with advancing age, especially after the seventh decade [3]. The pain associated with Herpes Zoster can be debilitating, with a serious impact on the quality of life, and the economic costs of managing the disease represent an important burden on both health services and society [4].

With the emergence of the Acquired Immune Deficiency Syndrome (AIDS) pandemic, adults younger than 45 years of age are increasingly presenting with Herpes Zoster due to HIV [5]. The relative risk of Herpes Zoster is at least fifteen times greater in patients with HIV than

in patients without HIV [6]. Studies indicate that the occurrence of HZO in young individuals correlates strongly with immunosuppression. The present study was undertaken to highlight the clinical profile of (HZO) in young adults who are less than 30 years of age.

Materials and methods

A retrospective analysis of available records of young adults (less than 30 years of age) with HZO was performed. Clinical features, results of blood laboratory workup, and treatment prescribed were noted. The median duration of follow up was nine months.

Results

The clinical data of eight young adults presenting with features of HZO were evaluated. Their average age was 23.25 years (range, 13-28 years). There was a predominance of males (62.8%) among the young adults presenting with HZO (Tabl. I).

None of the subjects in our study had a history of varicella vaccination. All of them had a history of chicken pox in childhood.

The clinical features are summarized in (Tabl. II). All subjects presented with skin lesions consistent with zoster involving the ophthalmic division of the trigeminal nerve on the affected side (right side affected in 75% subjects) of the face and head. It was limited to the ophthalmic division in all subjects. Results of other systemic investigations including a complete hemogram with peripheral smear, blood sugar profile, and serological tests for HIV,VDRL and Hepatitis B and C were negative for the all the subjects. There was no evidence of any co-existing systemic disease in any of the individuals. Serological tests were repeated in four previously negative subjects six months after their first test. The repeat test was negative in each case. Visual acuity was impaired in all subjects, the extent of impairment ranging from 20/400 to 20/60.

Age	Gender	Occupation
13	Female	Student
22	Male	Shop keeper
28	Male	Labourer
26	Male	Truck driver
28	Male	Farmer
25	Male	Farmer
22	Female	Housewife
23	Female	Housewife

Table I. Demographic profile and immune status of young patients with HZO

Case	Initial BCVA	Lid edema	Corneal findings	Corneal sensation	Uveiitis	Posterior segment findings	Final BCVA
1	20/60	+	Punctate keratitis	-	-	-	20/20
2	20/60	+	Dendritic keratitis	+	-	-	20/20
3	20/400	-	-	-	-	Optic neuritis	20/30
4	20/400	-	-	-	-	Optic neuritis	20/60
5	20/80	-	Dendritic keratitis	+	-	-	20/20
6	20/60	-	Punctate keratitis	-	-	-	20/20
7	20/60	-	Punctate keratitis	-	-	-	20/20
8	20/400	-	Punctate keratitis	-	++	-	20/40

Table II. Ocular features at presentation and final visual acuity in young adults with HZO

Conjunctival hyperemia and lid edema ranging from mild to severe was observed in all subjects in the acute phase. Corneal involvement was seen in 7(87.5%) of the 8 subjects in the form of dendritic keratitis (25%), punctate keratopathy (50%) and stromal keratitis (12.5%). Corneal sensitivity was abnormal in 75% of the cases. One of the eight patients (12.5%) presented with uveal inflammation. Evaluation of the posterior segment showed optic neuritis in12.5%(1/8) of the patients. Nebulomacular corneal opacities was seen in 50% (4/8) of the patients. All the subjects with active HZO were prescribed 800mg of oral acyclovir five times a day for 2 weeks.

Discussion

Herpes zoster is uncommon in adults younger than 30 years of age and the peak incidence occurs in the fifth to the seventh decade of life. The annual incidence of Herpes Zoster in adults 20–40 years old is 1.2 per 1000 person year compared with 9.4 per 1000 person-year in adults above 80 years of age in the United States [7] Similarly, the incidence of Herpes Zoster in the European primary care population was the lowest in young adults (1.9/1000 person-years in persons less than forty four years old) [8]. The disease spectrum and clinical features in adults younger than 30 years of age has not been extensively described. Our study highlights the clinical and demographic profile of HZO in this age group and also aims to correlate the clinical manifestations and final outcome of vision with the immune status.

Clinically, many believe that the occurrence of HZO at such a young age is associated with an underlying HIV infection [9]. The normal spectrum of HZO in immunocompetent individuals has been described by Zaal et al [10] where 23 patients were younger than 50 years of age and 50 patients were older than 50 years. In the prospective study by Zaal et al [10]. immunocompetent young adults (<50 years) formed 31% of the study group, but their unique clinical features and disease spectrum were not highlighted. HZO has also been reported in immunocompetent, healthy children with a favorable outcome [11]. In the study by Gupta et. al [12], 56% of the cases had no clinical evidence of immunosuppression. In our study none of the subjects had any immunosuppression or any systemic disease. Half of them had exposure to chickenpox virus.

All the patients presented with a localized, less severe form of the disease with better response to medical therapy. The main cause of moderate to severe visual loss at presentation in the young, patients was optic neuritis and stromal keratitis, but it was reversible with an early course of pulse intravenous steroids and aggressive antiviral therapy. Some degree of reduced corneal sensitivity was present in the majority (70%) of the immunocompetent patients without any associated long-term morbidity. This hypesthetic corneal surface, often with impaired tear secretion, predisposes the cornea to secondary infections. However, no superimposed bacterial infection was found in the group despite the diminution of corneal sensation in 70% of these subjects.

None of the subjects presented with Post Herpetic Neuralgia (PHN). This correlates with the study from Iceland [13], which demonstrated variations in risk of developing PHN with different age groups and in that study patients younger than 50 years never developed severe pain at any time.

Conclusion

Our study outlines the spectrum of HZO in young adults who are immunocompetent. No study has been reported of HZO in young immunocompetent adults less than 30 years of age. The lack of Cell Mediated Immunity (CMI) is a significant factor in triggering Herpes zoster. While CMI is definitely compromised in immunocompromised individuals, several other factors such as malnutrition or prior infection (such as typhoid) can also lower CMI and increase the risk of virus reactivation even in young adults who are otherwise clinically healthy. Yet another trend observed was that prompt diagnosis and early intervention is effective in healthy patients.

REFERENCES

1. Miller AE: Selective decline in cellular immune response to varicella-zoster in the elderly. Neurology. 1980; 30: 582–587.

2. Kestelyn P, Stevens AM, Bakkers E, Rouvroy D, Van de Perre P: Severe herpes zoster ophthalmicus in young African adults: A marker for HTLV- III seropositivity. Br J Ophthalmol. 1987; 71: 806–809.

3. Cooper M: The epidemiology of herpes zoster. Eye. 1987; 1: 413–421.

4 Whitley RJ: Varicella Zoster. In: Mandell GL, Bennett JE, Dolin R, eds. Mandell, Douglas, and Bennett's principles and practice of infectious diseases,6th ed.Philadelphia: Elsevier Churchill Livingstone, 2004.

5. Bayu S, Alemayehu W: Clinical profile of herpes zoster ophthalmicus in Ethiopians. Clin Infect Dis. 1997; 24: 1256–1260.

6. Buchbinder SP, Katz MH, Hessol NA, Liu JY, O'Malley PM, Underwood R, et al: Herpes zoster and human immunodeficiency virus infection. J Infect Dis. 1992; 166: 1153–1156.

7. Insinga RP, Itzler RF, Pellissier JM, Saddier P, Nikas AA: The Incidence of herpes zoster in a United States administrative database. J Gen Intern Med. 2005; 20: 748–753.

8. Opstelten W, Mauritz JW, de Wit NJ, van Wijck AJ, Stalman WA, van Essen GA: Herpes zoster and postherpetic neuralgia: Incidence and risk indicators using a general practice research database. Fam Pract. 2002; 19: 471–475.
9. Hodge WG, Seiff SR, Margolis TP: Ocular opportunistic infection incidences among patients who are HIV positive compared to patients who are HIV negative. Ophthalmology. 1998; 105: 895–900.
10. Zaal MJ, Volker-Dieben HJ, D'Amaro J: Visual prognosis in immunocompetent patients with herpes zoster ophthalmicus. Acta Ophthalmol Scand. 2003; 81: 216-220.
11. De Freitas D, Martins EN, Adan C, Alvarenga LS, Pavan-Langston D: Herpes zoster ophthalmicus in otherwise healthy children. Am J Ophthalmol. 2006; 142: 393–399.
12 Gupta N, Sachdev R, Sinha R, Titiyal JS, Tandon R: Herpes Zoster Ophthalmicus: Disease Spectrum in Young Adults iddle East Afr J Ophthalmol. 2011; 18: 178–182.
13. Helgason S, Petursson G, Gudmundsson S, Sigerddson JA: Prevalence of postherpetic neuralgia after a first episode of herpes zoster: prospective study with long term follow up. BMJ. 2000; 321: 794–796.

Copyright *Vijayalekshmi Sujatha et al.* This is an open access article distributed under the terms of the Creative Commons Attribution License, which permits unrestricted use, distribution, and reproduction in any medium, provided the original author and source are credited.

HERPES ZOSTER OPHTHALMICUS: CLINICAL PROFILE IN ADULTS LESS THAN 30 YEARS OF AGE

Vijayalekshmi Sujatha, Mudianur Subrahmanyam Padmajothi, Hariharasubramony Ambika, Chankramath Sujatha

Dr. Manuel Valdebran

Our Dermatol Online. 2012; 3(1): 9

Date of submission: 08.12.2011 / acceptance: 10.12.2011

Conflicts of interest: None

The article of Herpes Zoster Ophthalmicus is very interesting, specially to remember dermatologists the importance to derive patients to further specialized ophthalmologic evaluation.

In a revision done at our institution, conducted by Miniño et al., of 36 children up to 13 years of age, authors found 5 cases with ophthalmic involvement, and association with HIV in 2/36. the authors concluded that the main possible detonating factor in all cases was malnutrition followed by non-HIV-viral infections [1]. It is important to consider that in underdeveloped countries nutrition status and infectious diseases should be sought as possible detonating factors of the disease and not just HIV status. In the case of young healthy adults it would have been interesting to have an stress assessment done.

In table I there is a reference to immune status which is not actually there. Other variables would have been included.

Instituto Dermatológico y Cirugía de Piel Dr. Huberto Bogaert Díaz, Dominican Republic.

Correspondence:
E-mail: admin@valdebran.com

REFERENCES

1. Miniño M, Herrera-Franco G: Herpes Zoster in Children. Our Experience of 36 cases at IDCP. 1998-2000. Revista Dominicana de Dermatología. 2001; 28: 15-20.

Copyright *Manuel Valdebran.* This is an open access article distributed under the terms of the Creative Commons Attribution License, which permits unrestricted use, distribution, and reproduction in any medium, provided the original author and source are credited.

NASZA DERMATOLOGIA Online
OUR DERMATOLOGY Online

DERMATITIS DE INTERFASE POR DROGAS. DE LAS FORMAS LEVES A LAS SEVERAS. UNA VISIÓN DERMATOPATOLÓGICA

INTERFACE DRUG INDUCED DERMATITIS. FROM MILD TO SEVERE FORMS. A DERMATOPATHOLOGICAL VIEW

SKÓRNE ODCZYNY POLEKOWE. OD ŁAGODNYCH DO CIĘŻKICH POSTACI. DERMATOPATOLOGICZNY PUNKT WIDZENIA

Beatriz Di Martino Ortiz

Cátedra de Dermatología. Hospital de Clínicas de la Facultad de Ciencias Médicas de la Universidad Nacional de Asunción,Paraguay beatrizdimartino@gmail.com

Our Dermatol Online. 2012; 3(1): 10-16 Date of submission: 15.09.2011 / acceptance: 05.11.2011
Conflicts of interest: None

Resumen
En la actualidad, una de las causas más frecuentes de biopsia en la patología cutánea no tumoral son las reacciones cutáneas a fármacos. Estas pueden manifestarse en forma de prácticamente todos los patrones histopatológicos conocidos.
Reacción adversa a medicamentos (RAM) es definida por la OMS como cualquier respuesta a un medicamento, que sea nociva e inesperada, que ocurre a dosis normalmente utilizadas en el ser humano para profilaxis, diagnóstico, terapia de enfermedad o para modificación de la función fisiológica.
Describimos aquí las farmacodermias de interfase más frecuentes y presentamos tres casos clínicos.

Abstract
Currently, one of the most common causes of skin biopsy in non-tumor pathology are skin reactions to drugs. These can manifest virtually as all known histopathological patterns.
Adverse drug reaction (ADR) is defined by WHO as a response to a drug which is noxious and unexpected, which occurs at doses normally used in humans for prophylaxis, diagnosis, therapy of a disease or for modification of physiological function.
We describe here the most frequent interface drug induced dermatitis and present three clinical cases.

Streszczenie
Obecnie jednym z najczęstszych powodów biopsji skóry w przypadkach nie podejrzanych o patologię nowotworową są skórne odczyny polekowe. Odczyny te mogą w rzeczywistości manifestować się całym spektrum histopatologicznych wzorów.
Niepożądane reakcje polekowe (ADR) są zdefiniowane przez WHO jako odpowiedź na lek, która jest szkodliwa i nieoczekiwana oraz występuje w trakcie normalnego dozowania leku stosowanego w celach profilaktycznych, diagnostycznych, terapeutycznych lub też w celu modyfikacji fizjologicznych funkcji (organizmu – przyp. red.). W artykule tym opisujemy najczęstsze zapalenia skóry wywołane w skutek nakładania się działań niepożądanych leków na podstawie 3 przypadków klinicznych.

Palabras clave: dermatitis de interfase; eritema exudativo multiforme; erupción liquenoide por drogas; necrolisis epidérmica tóxica; dermatopatología
Key words: interface dermatitis; multiform exudative erythema; lichenoid drug reaction; toxic epidermal necrolysis; dermatopathology
Słowa klucze: interface dermatitis; rumień wielopostaciowy wysiękowy; liszajowata reakcja polekowa; toksyczna nekroliza naskórka; dermatopatologia

Introducción

El término dermatitis de interfase se refiere a un patrón histopatológico de reacción tisular que tiene como característica principal el daño a la capa de células basales. Este daño puede manifestarse por Muerte celular (liquenoide) que puede afectar solo escasas células en la capa basal de la epidermis (apoptosis) que se vuelven arrugadas, con citoplasma hipereosinófilo y presentan remanentes nucleares picnóticos (Civatte) (Fig. 1). Se pueden encontrar cuerpos coloides en la dermis o en capas epidérmicas superiores y no contienen remanentes nucleares. Puede usarse el término de disqueratocito para

referirse a estas células apoptóticas. A veces la muerte celular es por necrosis (Fig. 2), o como Daño vacuolar que resulta de la formación de una vacuola intracelular, edema y separación de la lámina densa de la membrana de las células basales (Fig. 3).

Como consecuencia del daño a la capa basal hay incontinencia melánica por la interferencia en la transferencia de melanina de los melanocitos a los queratinocitos basales (Fig. 1,3). Otro hallazgo es el infiltrado inflamatorio que varía en distribución (superficial y superficial y profundo), composición (tipo celular: linfocitos, eosinófilos, plasmocitos) y densidad (escaso o denso) de acuerdo a la patología [1] (Tab. I, II).

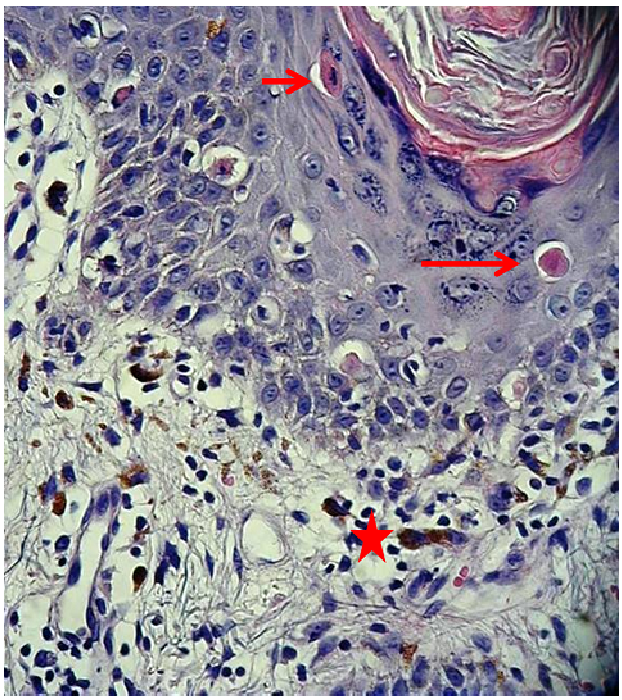

Figura 1. Histopatología. Erupción liquenoide por drogas. Se observan numerosos queratinocitos apoptóticos intraepidérmicos (flecha corta) algunos con remanentes nucleares (Civatte) y otros sin ellos (cuerpos coloides) (flecha larga). Los cuerpos coloides pueden ser dérmicos o epidérmicos. Numerosos melanófagos en dermis superficial como manifestación de la incontinencia melánica (asterisco)

Figure 1. Histopathology. Lichenoid drug eruption. Numerous apoptotic intraepidermal keratinocytes are observed (short arrow) some with nuclear remnants (Civatte) and others without them (colloid bodies) (long arrow). Colloid bodies may be dermal or epidermal. Numerous melanophages in the superficial dermis as a manifestation of melanin incontinence (asterisk)

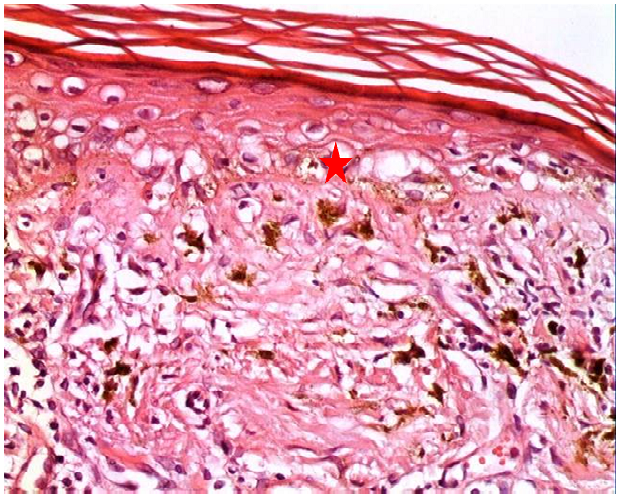

Figura 2. Histopatología. NET. Se observa necrosis completa de la epidermis

Figure 2. Histopathology. TEN. Note the complete necrosis of the epidermis

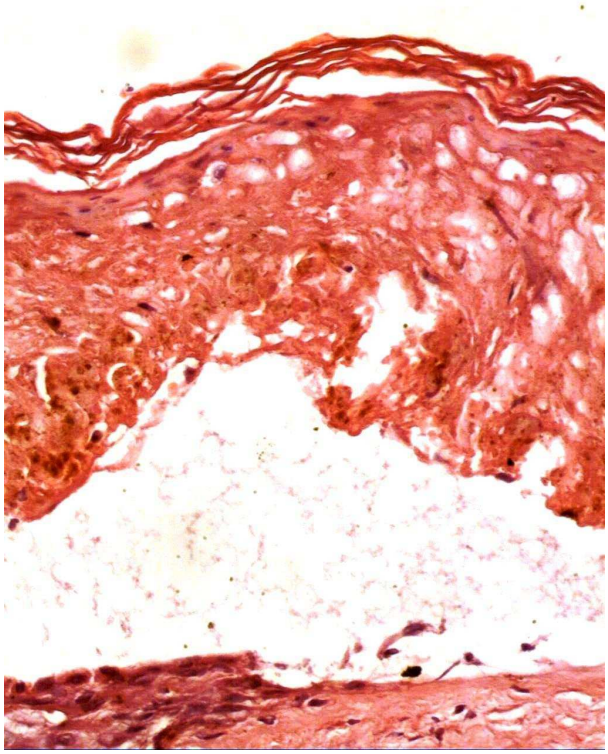

Figura 3. Histopatología. Lupus eritematoso. Degeneración vacuolar de la capa basal (asterisco)

Figure 3. Histopathology. Lupus erythematosus. Vacuolar degeneration of the basal layer (asterisk)

Daño a la capa de células basales
Daño vacuolar
Muerte celular
Incontinencia pigmentaria
Infiltrado inflamatorio
Superficial
Superficial y profundo

Tabla I. Características histopatológicas de la dermatitis de interfase

Table I. Histopathological characteristics of interface dermatitis

Vacuolar		Liquenoide	
Superficial	Superficial y profundo	Superficial	Superficial y profundo
EEM/SSJ/NET	LECSA/LECC	LP	Liquen estriado
LES/DM	PLEVA	***Erupción liquenoide por drogas***	Sífilis secundaria
EICH	***EMF***	Liquen nítido	
LSA		Púrpura pigmentosa liquenoide	
		Queratosis liquenoide	

Tabla II. Clasificación de las principales patologías del grupo, según sus características histopatológicas

Table II. Classification of the main pathologies of the group according to their histopathological characteristics

EEM/SSJ/NET: Eritema exudativo multiforme/Síndrome de Stevens Johnson/Necrolisis epidérmica tóxica. LES/DM: Lupus eritematoso sistémico/Dermatomiositis. EICH: Enfermedad de injerto contra huésped. LSA: Liquen esclero-atrófico. LECSA/LECC: Lupus eritematoso cutáneo subagudo/Lupus eritematoso cutáneo crónico. PLEVA: Pitiriasis liquenoide aguda. EMF: Erupción medicamentosa fija. LP: liquen plano

Dermatitis De Interfase Por Drogas

Erupciones Liquenoides Por Drogas

Las Lesiones no foto distribuidas difieren del LP en (Tab. III):

Presencia de paraqueratosis focal (en el LP la queratinización es ortoqueratósica).

Leve daño basal (en el LP el daño es muy intenso, y a veces tanto como para formar hendiduras en la unión dermo-epidérmica (hendiduras de Caspary o Max-Joseph).

Eosinófilos y plasmocitos en el infiltrado (el infiltrado del LP está constituido en su práctica totalidad por linfocitos, y el número de eosinófilos no debe ser >3 por muestra de biopsia de 4 mm) [1,2].

Mayor incontinencia pigmentaria.

Infiltrado menos denso y menos en banda y se puede extender escasamente a dermis media.

Las Lesiones fotodistribuidas son idénticas al LP.

	Erupción liquenoide por drogas	**LP**
Queratinización	Paraqueratósica	Ortoqueratósica
Daño a la capa basal	+ a ++	++ a ++
Tipo celular en el infiltrado inflamatorio	Eosinófilos + plasmocitos + linfocitos	Linfocitos
Densidad del infiltrado inflamatorio	+ a ++	++ a +++
Disposición del infiltrado inflamatorio	Superficial. Puede extenderse a dermis media	Superficial
Incontinencia pigmentaria	+++	+

Tabla III. Diagnóstico diferencial entre las erupciones liquenoides por drogas y el LP

Tabla III. Differential diagnosis between lichenoid drug eruptions and LP

Erupción Medicamentosa Fija (EMF)

Dermatitis de interfase con prominente degeneración vacuolar y presencia de cuerpos de Civatte. El infiltrado inflamatorio oscurece la interfase dermo-epidérmica (igual que en el EEM y PLEVA). El infiltrado a veces se extiende a la epidermis media y superior produciendo muerte de queratinocitos por encima de la capa basal.

Puede distinguirse del EEM por (Tab. IV):

La extensión más profunda del infiltrado (El EEM solo posee infiltrado superficial).

La presencia de algunos neutrófilos y eosinófilos.

Más prominente incontinencia melánica.

EMF	**EEM**
Vesiculación si está presente es subepidérmica	Vesiculación subepidérmica
Infiltrado linfocitario escaso a moderado, incluye neutrófilos, eosinófilos, superficial y profundo	Infiltrado linfocitario escaso superficial
Incontinencia pigmentaria +++	Incontinencia pigmentaria +

Tabla IV. Diagnóstico diferencial entre la EMF y el EEM

Tabla IV. Differential diagnosis between FDE and EM

EEM/SSJ/NET [3-5]
La clasificación clásica separa a este grupo de dermatitis de interfase en [6]:
EEM minor: afecta primariamente la piel. La afectación de mucosas es en solo 25%.
EEM major: formación de ampollas cutáneas. Mayor afectación de mucosas. Incluye al:
Sd. de Stevens-Johnson (SSJ): de presentación aguda en pacientes jóvenes. 10% o menos de la piel se halla afecta, pero con frecuente afectación mucosa.
Sd. de superposición (SSJ/NET): afectación de la piel entre 10-30%.
Necrolisis epidérmica tóxica (NET): forma muy severa asociada con alta mortalidad. Despegamiento cutáneo >30%.
La clasificación de Bastuji-Garin es la siguiente [7]:
Eritema multiforme bulloso:
Forma recurrente: es la más frecuente. Se asocia a infecciones como VHS, VCH, mycoplasma, etc., medicamentos o inmunizaciones.
Forma persistente: asociada a malignidad subyacente o infección por VEB.
SSJ: erosiones mucosas y despegamiento < 10%.
Síndrome de superposición (SSJ/NET): despegamiento entre 10-30%.
NET con spots (máculas purpúricas diseminadas o lesiones en diana): despegamiento > 30%.
NET sin spots: despegamiento > 30%.
Histopatología:
EEM: dermatitis de interfase con un leve a moderado infiltrado de linfocitos, algunos de los cuales se desplazan a la capa basal oscureciendo la interfase dermo-epidérmica.
La muerte celular es prominente (por mecanismo de apoptosis) no confinada a la capa basal. Las lesiones vesiculares tienen despegamiento dermo-epidérmico con prominentes células muertas en el techo. El infiltrado dérmico son linfocitos y macrófagos. No son prominentes los eosinófilos.
NET: ampolla subepidérmica siendo el techo de la misma una epidermis enteramente necrosada (lesión establecida). La lesión es inicial es la necrosis de células individuales con satelitosis de linfocitos. Hay un escaso infiltrado linfocitario perivascular [8-10].

Casos Clínicos
Caso Nº 1:
Mujer, 17 años, estudiante. Presenta un cuadro gripal de 8 días de evolución por lo que se automedica con un caramelo para la garganta que contiene sulfas en su composición.
Examen físico: placa eritematoviolácea, con ampollitas en su superficie, límites netos, bordes regulares, de 8 x 6 cm. de ejes mayores en cara lateral del cuello, lado derecho, extendiéndose a región maxilar inferior (Fig. 4).
Histopatología: dermatitis de interfase con vesiculación subepidérmica. Infiltrado linfocitario superficial con extensión a dermis media. El mismo incluye eosinófilos. Incontinencia pigmentaria muy marcada (Fig. 5,6).
Diagnóstico: Erupción medicamentosa fija (EMF).

Figura 4. Caso clínico 1. Clínica. EMF. Placa eritematoviolácea, con ampollitas en su superficie, límites netos, bordes regulares, de 8 x 6 cm. de ejes mayores en cara lateral derecha del cuello, extendiéndose a región maxilar inferior

Figure 4. Case report 1. Clinic. FDE. Erythematoviolaceuos plaque, with blisters on the surface, regular edges, 8 x 6 cm. in the neck

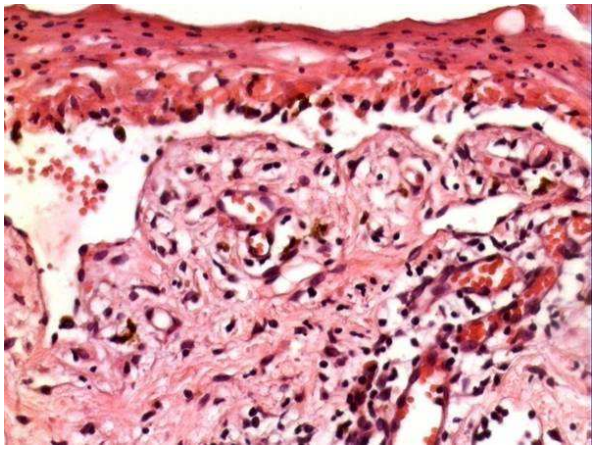

Figura 5. Caso clínico 1. Histopatología. EMF. Dermatitis de interfase con vesiculación subepidérmica

Figure 5. Case report 1. Histopathology. FDE. Interface dermatitis with subepidermal blister

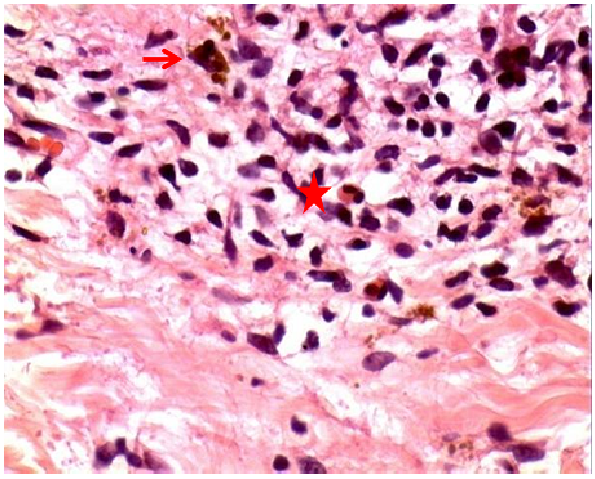

Figura 6. Caso clínico 1. Histopatología. EMF. Infiltrado linfocitario superficial con extensión a dermis media. El mismo incluye eosinófilos (asterisco). La incontinencia pigmentaria es muy marcada (flecha)

Figure 6. Case report 1. Histopathology. FDE. Superficial lymphocytic infiltrate extending into the mid-dermis. It includes eosinophils (asterisk). The PI is marked (arrow)

Figura 7. Caso clínico 2. Clínica. SSJ.- Erosiones y costras hemáticas en ambos labios. Máculas purpúricas diseminadas y ampollas que ocupan <30% de la superficie cutánea. También había afectación de mucosa genital

Figure 7. Case report 2. Clinic. SJS.- Erosions and hematic crusts in both lips. Disseminated purpuric macules and blisters that affects <30% of the skin surface. There was also involvement of genital mucosa

Caso Nº 2:
Varón, 23 años, estudiante. Portador de epilepsia criptogenética desde los 20 años. Un mes antes del inicio del cuadro inicia tratamiento con carbamazepina 600 mg/d.
Examen físico: Boca: Erosiones y costras hemáticas en ambos labios. Placas blanquecinas de varios tamaños en mucosa yugal, paladar duro, paladar blando, faringe y amigdalas. Piel y faneras: máculas purpúricas diseminadas y ampollas que ocupan <30% de la superficie cutánea. Afectación de mucosa genital (glande) (Fig. 7).
Histopatología: dermatitis de interfase con vesiculación subepidérmica donde el techo de la ampolla lo constituye una epidermis con presencia de necrosis celular. Infiltrado linfocitario superficial escaso sin extensión a dermis media. No se observan eosinófilos. Se observan muy escasos melanófagos (Fig. 8).
Diagnóstico: EEM major/SSJ.

Caso Nº 3:
Varón, 17 años, agricultor. Tres días antes del inicio del cuadro síndrome gripal por lo que se medica con 1 gr. de dipirona VO + dipirona EV en centro de salud.
Examen físico: Ictericia universal marcada. Ampollas múltiples, variadas formas y tamaños, la mayoría de ellas conteniendo líquido amarillo claro, la mayor parte de ellas fláccidas, escasas tensas y eclosionadas, entre 0,5 cm. y 6 cm. de diámetros, de distribución generalizada, predominio en tórax y tercio proximal de miembros. Signo de Nicolsky: +. Erosiones múltiples, variadas formas y tamaños, entre 1 cm. y 10 cm. de diámetros de distribución generalizada, incluyendo conjuntivas bulbar y palpebral, mucosa yugal y paladar duro, mucosa nasal. Costras hemáticas en borde libre de labios superior e inferior (Fig. 9).
Signos vitales: FC: 124/min., FR: 30/min., PA: 110/70.
Aparato Cardiovascular: taquicádico, ritmo regular. RC normofonéticos. No soplos
Aparato Respiratorio: taquipnéico, tiraje intercostal bilateral, roncus bilaterales de vértice a base.
Abdomen: se palpa hígado a 3 cm. del reborde costal derecho.
SNC: vigil, lúcido, sin déficit sensitivo un motor.
Histopatología: dermatitis de interfase con vesiculación subepidérmica donde el techo de la ampolla lo constituye una epidermis enteramente necrosada. Ausencia de infiltrados inflamatorios dérmicos (Fig. 10).
Evolución: óbito.
Diagnóstico: NET.

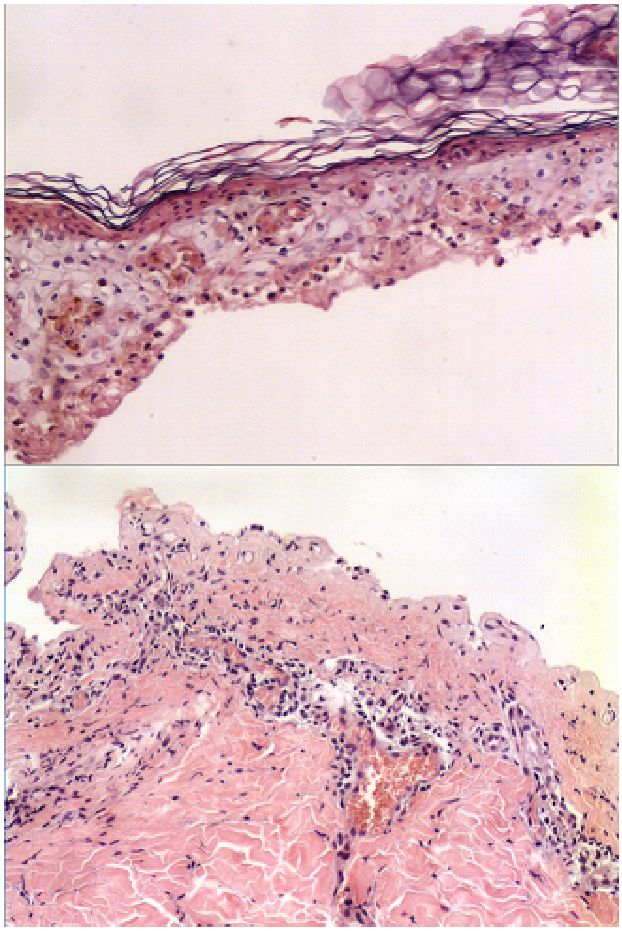

Figura 8. Caso clínico 2. Histopatología. SSJ.- Dermatitis de interfase con vesiculación subepidérmica donde el techo de la ampolla lo constituye una epidermis con presencia de necrosis celular. Infiltrado linfocitario superficial escaso sin extensión a dermis media. No se observan eosinófilos. Se observan muy escasos melanófagos

Figure 8. Case report 2. Histopathology. SSJ.- Interface dermatitis interface with subepidermal blistering where the blister roof consists in an epidermis with cell necrosis. Sacnat superficial lymphocytic infiltrate with no extension to the mid-dermis. Eosinophils not present. Very rare melanophages are observed

Figura 9. Caso clínico 3. Clínica. NET.- Ictericia universal, ampollas y erosiones múltiples

Figure 9. Case report 3. Clinic. TEN.- Universal jaundice, multiple blisters and erosions

Figura 10. Caso clínico 3. Histopatología. NET.- Dermatitis de interfase con vesiculación subepidérmica donde el techo de la ampolla lo constituye una epidermis enteramente necrosada. Ausencia de infiltrados inflamatorios dérmicos

Figure 10. Case report 3. Histopathology. TEN.- Interface dermatitis with subepidermal blistering where the roof of the blister is formed by a completely necrotic epidermis. No dermal inflammatory infiltrates

Conclusiones

La continua aparición de nuevos tratamientos farmacológicos obliga a estar preparados para reconocer sus posibles efectos adversos en la piel. Pese a la apariencia inocua de muchos medicamentos, cada vez son más comunes las patologías causadas por sus efectos adversos o colaterales (RAM), que adoptan un amplio espectro de formas clínicas e histopatológicas. Cuando RAM compromete a la piel se denomina farmacodermia.

Cualquier droga puede ser causante de una reacción adversa, y administrado por cualquier vía, si bien han sido implicados con mayor frecuencia los antibióticos, anticonvulsivantes y AINES, entre otros.

Algunas drogas causan solo un tipo de reacción, otras diferentes tipos de reacciones.

La biopsia cutánea es una excelente herramienta para reconocer tales reacciones.

El diagnóstico de las farmacodermias se basa como en la gran mayoría de las enfermedades dermatológicas en una buena correlación clínico-patológica. Sin embargo existen ciertos hallazgos microscópicos que nos pueden sugerir esta posibilidad diagnóstica, tales como: edema dérmico superficial-urticarial (en algunas reacciones), linfocitos activados, células plasmáticas (en algunas reacciones) y/o eosinófilos, extravasación de hematíes (en 50% o más), edema del endotelio vascular, exocitosis de linfocitos y queratinocitos apoptóticos.

Las erupciones por drogas que producen primariamente dermatitis de interfase se consideran entre las más frecuentes, y si bien la mayoría son benignas existen otras que pueden poner en riesgo la vida del paciente, tal y como se demuestra en el último de los casos presentados.

BIBLIOGRAFÍA

1. Neil CA, Magro CM, Mihm Jr. MC: Interface dermatitis. Arch Pathol Lab Med. 2008; 132: 652–666.
2. Horn TD: Interface dermatitis. En: Barnhill R, Crowson AN, eds. Texbook of dermatopathology. 2nd ed. New York, NY. McGraw Hill Co; 2004: 35-60.
3. French LE: Toxic epidermal necrolysis and Stevens Johnson syndrome: our current understanding. Allergol Int. 2006; 55: 9–16.
4. Fernández Figueras MT: Reacciones cutáneas a tratamientos farmacológicos y cosméticos. Rev Esp Patol. 2007; 40: 69-78.
5. Sehgal VN, Srivastava G: Toxic epidermis necrolysis (TEN) Lyell's syndrome. J Dermatol Trat. 2005; 16: 278-286.
6. Huff JC, Weston WL, Tonnesen MG: Erythema multiforme: a critical review of characteristics, diagnostic criteria and causes. J Am Acad Dermtol 1983; 8: 763-775.

7. Bastuji-Garin S, Rzany B, Stern RS, Shear NH, Naldi L, Roujeau JC: Clinical classification of cases of toxic epidermal necrolysis, Stevens-Johnson syndrome and erythema multiforme. Arch Dermatol 1993; 129: 92-96. Grupo internacional para la categorización del EEM.
8. Arévaloa JM, Lorente JA: Tratamiento de la necrólisis epidérmica tóxica. Med Clin (Barc) 1998; 111: 27-31.
9. Rzany B, Hering O, Mockenhaupt M, Schröder W, Goerttler E, Ring J, et al: Histopathological and epidemiological characteristics of patients with erythema exudativum multiforme major, Stevens-Johnson syndrome and toxic epidermal necrolysis. Br J Dermatol. 1996; 135: 6-11.
10. Gavaldá Esteve C, Murillo Cortés J, Poveda Roda R: Eritema multiforme revisión y puesta al día. RCOE 2004; 9: 415-423.

Copyright *Beatriz Di Martino Ortiz.* This is an open access article distributed under the terms of the Creative Commons Attribution License, which permits unrestricted use, distribution, and reproduction in any medium, provided the original author and source are credited.

NASZA DERMATOLOGIA Online
OUR DERMATOLOGY Online

TYPE 2 LEPRA REACTION (ENL) PRESENTING WITH EXTENSIVE CUTANEOUS ULCERATIONS

REAKCJA LEPROTYCZNA TYPU 2-GO (ENL) Z ROZLEGŁYMI OWRZODZENIAMI SKÓRNYMI

Hosahalli Rajaiah Yogeesh HR[1], Sujatha Chankramath[1], Hari Kishan Kumar Yadalla[1], Shameem Shariff[2], Suhas Bettadapura Ramesh[1], Sapnashree Budhnoor Sreekantaiah[1]

[1]*Department of Dermatology, M.V.J. Medical College & Research Hospital, Hoskote, Bangalore, Karnataka, India*
[2]*Department of Pathology, M.V.J. Medical College & Research Hospital, Hoskote, Bangalore, Karnataka, India*

Corresponding author: Dr. Hosahalli Rajaiah Yogeesh hryogesh@yahoo.com

Our Dermatol Online. 2012; 3(1): 17-20 Date of submission: 18.07.2011 / acceptance: 25.10.2011
Conflicts of interest: None

Abstract
A 45 year old lady presented with multiple painful necrotic ulcerations over the trunk, arms, thighs and gluteal areas of two months duration. She also had erythematous papules and pustules over the face since 1 week. History of recurrent papular lesions, some of them undergoing ulceration were present since 3 years. All biochemical parameters were within normal limits. Rheumatoid factor, ANA, Elisa for HIV and VDRL were negative. Pus culture showed growth of *Staphylococcus aureus*. Smear for AFB showed multiple globi. Skin biopsy showed atrophic epidermis with grenz zone; dermis showed sheets of foamy macrophages and oedematous blood vessels infiltrated with neutrophils and ocasional plasma cells. Patient was admitted and was started on MDT-MB along with thalidomide and prednisolone.

Streszczenie
45-letnia kobieta zgłosiła się do naszego oddziału z 2-miesięcznym wywiadem obejmującym liczne, bolesne, nekrotyczne owrzodzenia skóry tułowia, ramion, ud i okolic pośladkowych. Od tygodnia pojawiały się także rumieniowe grudki i krosty na skórze twarzy. W wywiadzie, pacjentka podawała pojawiające się od 3 lat nawrotowe zmiany grudkowe, niektóre ulegające owrzodzeniu. Wyniki przeprowadzonych badań laboratoryjnych były w normie. Czynnik reumatoidalny (RA), przeciwciała ANA, test typu Elisa przeciw HIV oraz odczyn VDRL były także ujemne. Posiew ropy wykazał obecność ***Staphylococcus aureus***. Rozmaz dla AFB (kwasoopornych prątków) wykazały wiele ziarnistości. Biopsja skóry wykazała atroficzny naskórek ze strefą grenza, w skórze właściwej liczne piankowate makrofagi oraz obrzęknięte naczynia krwionośne nacieczone neutrofilami oraz pojedynczymi komórkami plazmatycznymi. Pacjentka została przyjęta (do naszego oddziału), wdrożono kurację MDT-MB połączoną z talidomidem i prednizolonem.

Key words: type 2 Lepra reaction; necrotic ulcers; AFB; MDT
Słowa klucze: typ 2 Lepra reakcji; wrzód nekrotyczny; AFB; MDT

Introduction

Type 2 lepra reaction, otherwise termed erythema nodosum leprosum, is an acute inflammatory reaction seen in patients with lepromatous leprosy or occasionally in borderline lepromatous leprosy. Though it is usually seen during the course of treatment it may occur in previously untreated patients as well. The lesions described in type 2 reactions are erythematous painful tender papules and nodules. In mild reaction nodules are small in number and spontaneously resolve leaving behind hyperpigmented macules. In severe reactions, nodules tend to increase in size and ulcerate. Ulcerations heal with scarring. Sometimes erythema nodosum leprosum may be the presenting manifestation of leprosy [1]. Vesiculobullous, pustular, ulcerated, and hemorrhagic and erythema multiforme-like lesions have been reported in ENL (erythema nodosum leprosum) [2]. In this article, we have discussed a case which presented to us with severe skin ulcerations. The case was admitted in our hospital, MVJ medical college and research hospital, situated in the outskirts of Bangalore, where she was investigated and diagnosed and started on treatment.

Case report

A 45 year old lady was brought to our OPD with multiple painful ulcerated skin lesions over the trunk, arms, thighs and gluteal area of 2 months duration. She also had multiple reddish eruptions and pustules over the face since 1 week; she gives history of recurrent attacks of papulo-pustular lesions, and ulceration since three years. Patient says that she was taking treatment from a doctor with partial subsidence of ulcers. It is possible that patient must have been put on steroid injections as history suggests. Six months ago she was diagnosed to have diabetes mellitus and she has been on irregular treatment for the same. In the present episode ulceration first started over the gluteal region and slowly developed over the other sites. According to the patient the present episode was the most severe one. Current episode is associated with history of fever since 1week - high grade and intermittent. No history of joint pains or abdominal symptoms suggestive of inflammatory bowel disease.

On general physical examination, the patient was afebrile, vitals were stable,pallor was present and there were enlarged tender lymph nodes in the cervial, axillary and inguinal groups. Cutaneous examination revealed multiple erythematous indurated plaques surmounted with multiloculated ulcers of size varying from 1x1cm to 5x5cms, with undermined edges and covered with purulent discharge and crusts over both arms, forearms, thighs, abdomen and gluteal areas (Fig. 1,2).

Forehead and both cheeks showed erythematous plaques with surmounted papules and pustules (Fig. 3). Multiple hypertrophic and keloidal scars were seen over both upper limbs and back (Fig. 4). Bilateral ulnar nerves, common peroneal nerves and supraorbital nerves were thickened and tender. Sensations could not be examined because of generalized cutaneous tenderness. Ophthalmic examination revealed no abnormality. Differential diagnosis of disseminated pyoderma gangrenosum and erythema nodosum leprosum and disseminated sweet's syndrome was made and the patient was investigated.

Figure 1. Clinical Photograph showing multiple plaques with ulcerations over abdomen, forearms and arms

Figure 2. Clinical photograph showing ulcerations over the gluteal region

Figure 3. Clinical photograph showing pustules and nodules on face

Figure 4. Clinical photograph showing scars and hyperpigmentation

Haematological investigations revealed Hb – 8.8gm%, TLC – 11000/mm3 with 78% of neutrophils, ESR showed 30mm in the 1st hour, FBS – 168mg% and PPBS – 295mg%. Urine analysis and all other biochemical parameters were within normal limits. Rheumatoid factor, ANA, HbsAg, Elisa for HIV and VDRL were negative. Pus culture showed growth of *Staphylococcus aureus*. Smear for AFB (acid-fast bacilli) showed multiple globi. Skin biopsy showed atrophic epidermis with grenz zone, dermis showed sheets of foamy macrophages intermingled with small aggregates of neutrophils and ocassional plasma cells, dermal vessels were oedematous and infiltrated with neutrophils (Fig. 5,6). Fite faraco stain showed macrophages packed with AFB (Fig. 7). A diagnosis of lepromatous leprosy with type 2 reaction was made and patient was started on MDT MB along with prednisolone 30mg and thalidomide 100mg tds. Patient did show some improvement; however she went against medical advice in spite of repeated requests and lost for follow up.

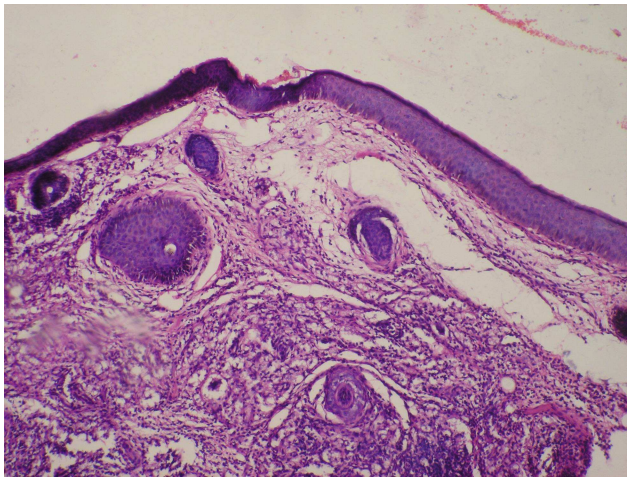

Figure 5. Histopathology (H&E) (100X)

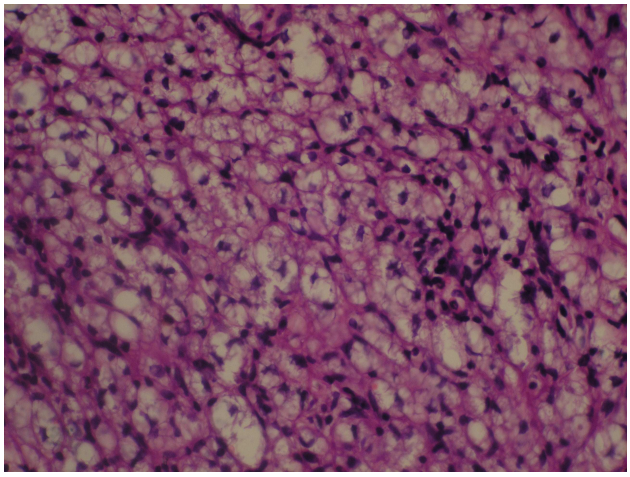

Figure 6. Histopathology showing sheets of foamy macrophages (H&E) (400X)

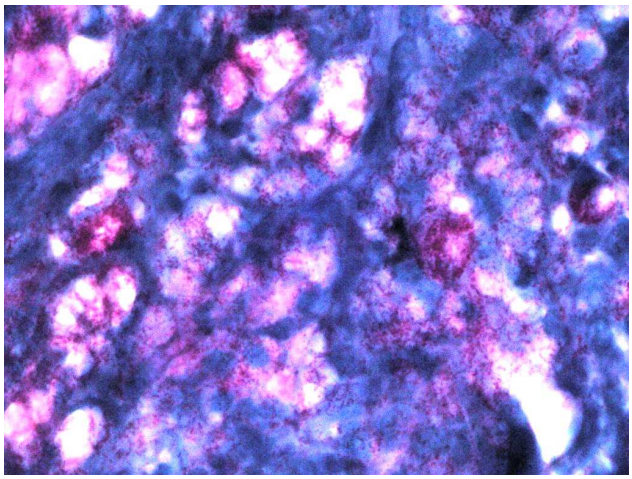

Figure 7. Fite-faraco stain of biopsy specimen showing AFB

Discussion

Leprosy is a chronic granulomatous infectious disease caused by Mycobacterium leprae. There is no other human infectious disease in which the clinical picture is as varied as leprosy. Type 2 lepra reaction is a type 3 Coomb and Gell hypersensitivity reaction usually seen in lepromatous and borderline lepromatous patients. It usually occurs later during the course of treatment and in longstanding untreated patients [2]. Antigen-antibody complexes are formed during the treatment in multibacillary leprosy and in patients with longstanding untreated disease with high bacillary load due to the death of bacilli; deposition of these complexes in various tissues causes inflammatory response with constitutional symptoms.

Over half of Lepromatous leprosy and quarter of borderline lepromatous patients can develop type 2 reaction. In skin it presents most commonly with crops of multiple red dusky brown tender papules and nodules over the face and extensor aspects of the limbs. Lesions tend to recur at the same sites and if they do not resolve completely a chronic painful panniculitis develops which may persisit for months to years. Exacerbating factors for ENL are stress, pregnancy, lactation, concurrent illness and medication [3]. Arthritis, iritis, iridocyclitis and nephrits are other known features of ENL.

ENL is more severe in caucasians and mongolians than in negroes. Ulceration occurs more readily and rapidly and unusual forms are seen. Various rare and atypical variants of ENL have been described in literature. Verma KK etal have reported necrotic erythema nodosum leprosum as a presenting manifestation of leprosy [4]. A rare variant of type 2 reaction characterised by pustular lesions on switching from WHO MDT to ofloxacin aided MDT was reported by Dave et al [5]. A persistent and localized variant of ENL was reported by S Prabhu et al [6]. Galvez et al reported an atypical evolution of BL as well as type 2 reaction primarily involving multiple nerves than skin [7]. A case of ENL clinically presenting as urticarial vasculitis that was then diagnosed to have LL has been reported by Funk WK et al [8]. Kou et al have reported a male with underlying lepromatous leprosy presenting with atypical reactional state simulating sweet syndrome [9]. A fatal case of erythema necroticans, the cause of death being septicemia secondary to skin ulcers and URTI

ENL has been reported by Sethuraman et al and Petro et al [10,11]. This case is presented due to rarity of ENL leprosy presenting with such severe ulcerations, especially at a time when we have eliminated leprosy as a major health hazard in our country.

Conclusion

Although we encounter an occasional type 2 lepra reaction after initiating the multibacillary leprosy patients on MDT-MB, cases of ENL presenting with extensive cutaneous ulcerations are a very rare entity. However one should have a high index of suspicion in clinical practice failing which an easily treatable disease can be missed.

REFERENCES

1. Gomathy S, Divakaran J, Chakravarthy RS: Bullous erythema nodosum leprosum (bullous type 2 reaction). Int J of Dermatol 2002; 41: 363-364.
2. Meyerson MS: Erythema nodosum leprosum. Int J Dermatol 1996; 35: 389-392.
3. Pflatzgraff RE, Gopal R: Clinical leprosy. In: hastings RC, Opromolla DV A, ed. Leprosy. London: Churchill Livingstone, 1994: 237-287.
4. Verma KK, Pandhi RK: Necrotic erythema nodosum leprosum; A presenting manifestation of lepromatous leprosy. Int J Lepr Other Mycobact Dis 1993; 61: 293-294.
5. Dave S, Thappa DM, Nove AV, Jayanthi S: A rare variant of erythema nodosum leprosum: a case report. Dermatol Online J 2003; 9: 11.
6. Prabhu S, Rao R, Sripathi H, Rao L, Singh R: Localized and persistent erythema nodosum leprosum – a rare variant?. Dermatol Online J 2008; 14 :16.
7. Galvez J, Lopez-Dominguez JM, Navarro A, Creagh R, Casado JL, Chinchón Lara I: Patient with Hansen disease and lepromatous reaction with predominant neural involvement. Neurologia 1998; 13: 412-444.
8. Funk WK: Lepromatous leprosy and erythema nodosum. Hongkong dermatology and venereology bulletin 2001; 28-30.
9. Kou TT, Chan HL: Severe reactional state in lepromatous leprosy simulating sweet`s syndrome. Int J Dermatol 1987; 26: 518-520.
11. Sethuraman G, Jeevan D, Srinivas CR, Ramu G: Bullous erythema nodosum leprosum (bullous type-2 reaction). Int J Dermatol 2002; 41: 363-364.
12. Petro TS: Bullous type of reaction mimicking pemphigus in lepromatous leprosy. Indian J Lepr 1996; 68: 179-181.

Copyright by *Hosahalli Rajaiah Yogeesh, et al*. This is an open access article distributed under the terms of the Creative Commons Attribution License, which permits unrestricted use, distribution, and reproduction in any medium, provided the original author and source are credited.

NASZA DERMATOLOGIA Online
OUR DERMATOLOGY Online

GIANT TUBERCULOSIS VERRUCOSA CUTIS

OLBRZYMIA BRODAWKUJĄCA GRUŹLICA SKÓRY

Rokon Uddin[1], Farzana Akhter[2], Abu Baker[1]

[1]*Department of skin & VD, Enam Medical College & Hospital, Savar, Dhaka, Bangladesh*
[2]*Department of skin & VD Upozila Health Complex, Savar, Dhaka, Bangladesh*

***Corresponding author**:* Dr. Md. Rokon Uddin drrokon47@gmail.com

Our Dermatol Online. 2012; 3(1): 21-23 Date of submission: 04.08.2011 / acceptance: 19.10.2011
Conflicts of interest: None

Abstract
A 38year old man had asymptomatic slowly progressive warty lesion on extensor surface of left elbow and arm for about 20 years. Examination revealed larger one sized of 16cm×15cm and smaller one about 8cm×5cm. Lesions were Keratotic, verrucous, nontender, cauliflower-like indurated plaque. Mantoux test resulted 20mm×18mm on 48 hours observation. Histopathological examination of the lesion showed epitheloid cell granuloma with giant cells and lymphocytes in the mid dermis. The conclusive diagnosis was tuberculosis verrucosa cutis based on above findings. Six month therapy with INH 300mg plus Rifampicin 600mg supplemented initial 2 months ethambulol 1000mg plus pyrazinamide 1500mg daily resulted complete clearance of the lesions.

Streszczenie
38-letnia kobieta zgłosiła się z asymptomatyczną, powoli powiększającą się brodawkowatą zmianą na powierzchni wyprostnej lewego łokcia i ramienia, obecną od 20 lat. Badanie fizykalne wykazało dwie zmiany: większą o wym. 16x15cm i mniejszą o wym. 8x5cm. Zmiany miały postać keratotycznych, brodawkowatych, niebolesnych, kalafiorowatego kształtu blaszek. Test Mantoux po 48 godzinach wyniósł 20x18mm. Badanie histopatologiczne ujawniło ziarniniaki komórkowe w naskórku wraz z komórkami olbrzymimi oraz limfocytami w warstwie środkowej skóry. Na podstawie w/w badań postawiono diagnozę gruźlicy brodawkującej skóry. Wdrożono 6-miesięczną terapię 300mg INH z 600mg rifampicyną, wspomaganą przez pierwsze 2 miesiące: 1000mg etambutolu i 1500mg pirazynamidu, które zaskutkowały całkowitym ustąpieniem zmian skórnych.

Key words: skin tuberculosis; tuberculosis verrucosa cutis; gaint
Słowa klucze: skórna postać gruźlicy; tuberculosis verrucosa cutis; olbrzymi

Introduction

Tuberculosis is quite common in Bangladesh. Tuberculosis verrucosa cutis (TVC) occurs from exogenous inoculation of bacilli into the skin of a previously sensitized person with strong immunity against *Mycobacterium tuberculosis* [1].The tuberculin test is strongly positive. Clinically, the lesion begins as a small papule, which becomes hyperkeratotic, resembling a wart. The lesion enlarges by peripheral expansion, with or without central clearing, sometimes reaching several centimeters or more in diameter [1]. Lesions are almost always solitary, and regional adenopathy is usually present only if secondary bacterial infection occurs. The infection is exogenously acquired and hence the lesions usually appear on exposed or trauma prone areas [2]. A case of accidental infection through throne pricks leading to the lesions which spared gradually for the last 20 years, larger one almost cover the left extensor elbow.

Case report

A 38 years old man presented with history of asymptomatic, gradually progressing, warty growth, on the back of left elbow and arm for 20 years. The lesions were preceded by thorn pricks. There were no constitutional or systemic symptoms. He did not have any past or family history of tuberculosis. Cutaneous examination revealed keratotic, nontender, cauliflower like indurated plague ranging from 16cm ×15cm to 8cm× 5cm on the back of left elbow and on back of the left arm (Fig. 1,2).

There was no lymphadenopathy. Systemic examination was unremarkable. Histopathological examination of the lesion showed pseudoepitheliomatous hyperplasia of the epidermis and a epitheloid cell granuloma having giants cells and lymphocytes in the mid dermis (Fig. 3). Ziehl-Neelson staing of the tissue did not reveal any acid fast bacilli. Mantoux test was positive (20mm×18mm on 2nd day).

Hematological investigations revealed a normal haemogram except ESR which was marked as 40mm in 1st hour (Westergren method). Other routine investigations of the blood, urine and stool were unremarkable. Skiagram of the chest showed no abnormality.

Figure 1. Hyperkeratotic plaque arising at the site of inoculation in an individual

Figure 2. Hyperkeratotic cauliflower like indurated plaque left extensor elbow

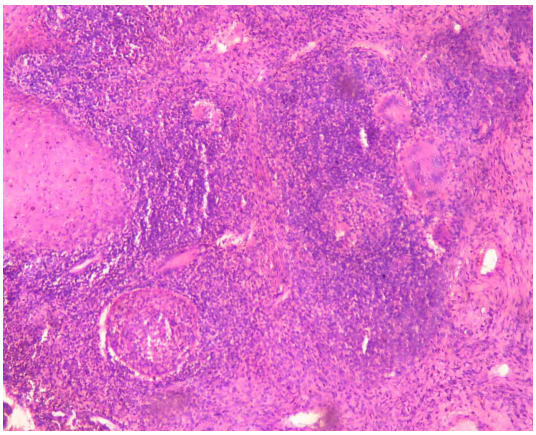

Figure 3. Focus under Zeiss Microscope with Epitheloid cell granuloma having giants cells and lymphocytes in the mid dermis 10 magnificsation

Based on these clinical features, histopathology and Montoux test, a diagnosis of tuberculosis verrucosa cuits was confirmed. The patient was treated with six month therapy INH 300mg plus Rifampicin 600mg supplemented with initial 2 months ethambulol 1000mg plus pyrazinamide 1500mg daily resulted complete clearence of the lesion. Six months later the histopathological examination of the tissue was done and the result found unremarkable.

Conclusion

TVC patients usually have moderate or high degree of immunity. This patient had positive Mantoux test to support these criteria. The sites which are commonly involved are exposed parts of the body such as fingers, hands, wrists, forearm, arm, ankles, feet, knees, heels and in case of children buttocks [3]. This patient's lesion was also over the extensor elbow & back of arm- which support the criteria. The man acquired the infection through thorn pricks. Usually TVC begins as small papule and become hyperkeratotic enlarges by peripheral expansion and sometimes reaching several centimeters. This case had cauliflower like lesion about 16cm ×15cm which was quite larger than usual. Complete clearance of warty lesions after the treatment with the anti tubercular regimen composed of INH, Rifampicin, Ethambulol, and Pyrazinamide was strongly suggestive of tubercular etiology.

REFERENCES

1. Janes WD, Berger TG, Elston DM: Andrews' Disease of the Skin Clinical Dermatology. 10th edition USA: Elsevier 2006; 334-335.
2. Cloides RL: Sir William Osler and the anatomical tubercle. AJ AM Acad Dermatol 1987; 16: 1071-1074.
3. Wolff K, Goldsmith LA, Katz SI, Gilcrest BA, Paller AS, Ieffell DJ: Fitzpatrick's Dermatology In General Medicine. 7th edition, Vol.2. New York; McGraw Hill, 2008; 1768-1775.

Copyright *Rokon Uddin et al.* This is an open access article distributed under the terms of the Creative Commons Attribution License, which permits unrestricted use, distribution, and reproduction in any medium, provided the original author and source are credited.

NASZA DERMATOLOGIA Online
OUR DERMATOLOGY Online

FACIAL PLEXIFORM NEUROFIBROMATOSIS IN A PATIENT WITH NEUROFIBROMATOSIS TYPE1: A CASE REPORT

NERWIAKOWŁÓKNIAK SPLOTOWATY W OBRĘBIE TWARZY U PACJENTA Z NEUROFIBROMATOZĄ TYPU I: OPIS PRZYPADKU

Iffat Hassan[1], Abid Keen[1], Parvaiz Ahmad Shah[2]

[1]*Deptament of Dermatology, STD & Leprosy Govt. Medical College & Associated SMHS Hospital, Srinagar-Kashmir, India*
[2]*Division of Neurology, Department of Medicine, Govt.Medical College & Associated SMHS Hospital,Srinagar-Kashmir, India*

***Corresponding author**:* Dr. Iffat Hassan hassaniffat@gmail.com

Our Dermatol Online. 2012; 3(1): 24-27 Date of submission: 13.08.2011 / acceptance: 21.10.2011
Conflicts of interest: None

Abstract
Plexiform neurofibroma is a poorly circumscribed, diffuse enlargement of neural sheets that typically involves major nerve trunks of the head and neck region because of the rich innervations of this area. It is a benign tumor and is a virtually pathognomonic and often disabling feature of neurofibromatosis type 1 (NF-1 or Von Recklinghausen's disease). We hereby report a case of facial neurofibroma in an adult female with neurofibromatosis type 1 (NF-1).

Streszczenie
Nerwiakowłókniak splotowaty to słabo odgraniczone, rozlane powiększenie osłonek nerwowych, które typowo dotyczy korzeni nerwowych okolic twarzy i szyi, co spowodowane jest ich bogatym unerwieniem. Jest to guz łagodny, w rzeczywistości patognomoniczny dla neurofibromatozy typu 1 (NF-1 lub choroba Von Recklinghausena), którego postać jest często traktowana jako cecha upośledzająca (zwł. wygląd pacjenta – przyp. redakcji). W tym artykule opisujemy przypadek nerwiakowłókniaka okolicy twarzy u dorosłej kobiety z NF-1.

Key words: plexiform neurofibroma; cafe-au-lait macules; neurofibromatosis
Słowa klucze: włókniak splotowaty; plamy cafe-au-lait; neurofibromatoza

Introduction

Plexiform neurofibroma is a relatively common but potentially devastating manifestation of neurofibromatosis type 1 (NF-1). It is a poorly defined benign tumor of the peripheral nerve sheath spreading out just under the skin or deeper in the body. The diffuse and soft nature of plexiform neurofibroma is often compared to 'a bag of worms' and is to be distinguished from a vascular malformation or a lymphangioma. Plexiform neurofibromas are locally invasive, non-metastasizing, and generally categorized by their location. Tumors of head, neck and face are the most common, followed by lesions of the spine, extremities, mediastinum and abdomen [1].

Facial plexiform neurofibroma may produce various degrees of cosmetic and functional deformities in the head and neck region. Surgical management is the mainstay of treatment, but within the head and neck region it is limited by the infiltrating nature of these tumors, inherent operative morbidity and a high rate of regrowth.

Case report

A 45-year old unmarried female, normotensive, nondiabetic, presented to the out-patient department of our institute with a history of a swelling on the right side of her face especially over the right infraorbital region, right side of nose, adjacent right cheek, chin and jaw.The patient reported that her facial disfiguring growth had started at birth and continuously increased in size since then. She had difficulty in speaking properly. She also complained of intermittent dull aching pain and itching on her face. There was no history of any regression in size or discharge from the swelling. The patient never noticed any similar swelling elsewhere in the body. There was no history of trauma over the area. Also, there

was no history suggestive of any constitutional symptoms, tingling and numbness elsewhere over the body. There was no history of seizures, deafness, tinnitus or any other neurological deficit. The past medical and surgical histories were unremarkable.There was no history of similar disease in any of the family members or first degree relatives. There was no known evidence of any hereditary disease in the family or first degree relatives.

General physical examination revealed an averagely built adult female with a steady gait, and satisfactory vital signs with no signs of pallor, icterus, cyanosis or lymphadenopathy. Systemic examination was also non-contributory.

Cutaneous examination revealed a large solitary swelling measuring approximately 6x5 cm in size with indistinct borders, overhanging on itself, present on the right side of face involving the right cheek, right side of upper lip, chin and right jaw. The overlying skin showed hyperpigmentation and hypertrichosis with follicular prominence (Fig. 1,2). On palpation, there was no local rise in temperature or any tenderness. The swelling had a peculiar consistency, soft in most of the areas with few firm nodular areas, similar to that described in literature as a 'bag of worms'. On auscultation, no bruit could be detected.

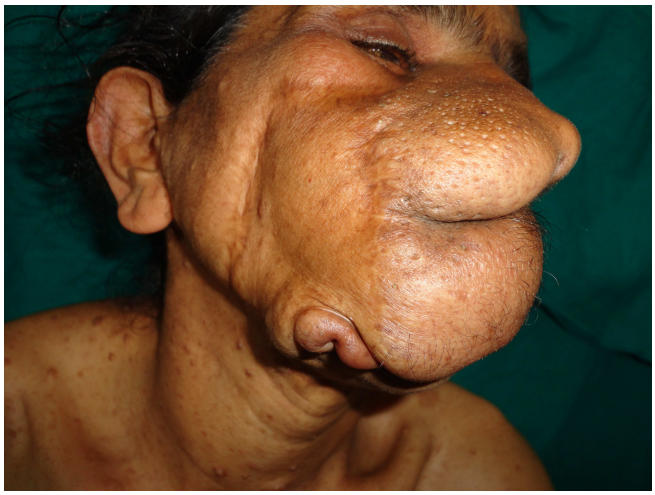

Figure 1. Facial plexiform neurofibroma

Figure 2. Facial plexiform neurofibroma (lateral view) with hypertrichosis and follicular prominence

Rest of the cutaneous examination revealed multiple hyperpigmented macules over her trunk and arms (Fig. 3). These macules were sharply defined, ranging in size from a few mm to more than 3 cm in diameter and were more fifteen in number. Axillary and inguinal freckling (Crowe's sign) was also present. There were also multiple skin coloured papules and nodules distributed over trunk and upper limbs, ranging in size from a few mm to more than 3 cms in size.

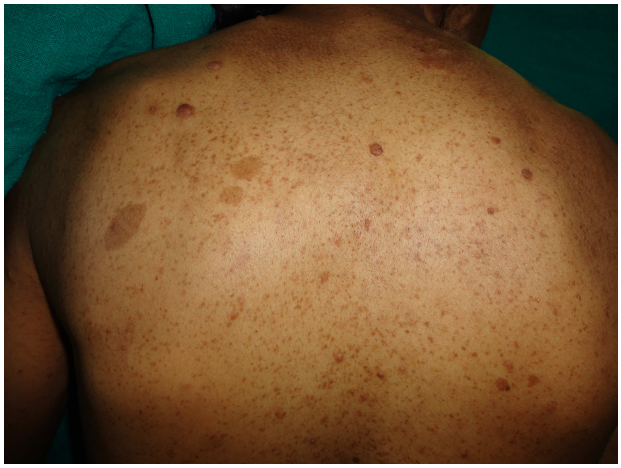

Figure 3. Cafe-au-lait macules and neurofibromas on trunk

Slit lamp examination did not reveal any Lisch nodules. Fundus examination was also normal. Routine haematological and biochemical investigations were normal. Chest X-ray, skull X-ray and X-ray of long bones did not reveal any abnormality. Ultrasonography of the abdomen was also normal. Craniospinal MRI did not reveal any abnormality. Excisional biopsy of ane of the cutaneous nodules was done and sent for histopathological analysis. It revealed features of neurofibroma. Based on the constellation of clinical and histological features, a diagnosis of facial plexiform neurofibroma with neurofibromatosis type 1 was entertained.

Discussion

Neurofibromatosis type-1 (NF-1) is a common neurocutaneous condition with an autosomal dominant inheritance. Descriptions of individuals reported to have neurofibromatosis have been discovered in manuscripts dating from 1000 A.D [2]. However, it was not until 1881 that Von Recklinghausen described neurofibromatosis in his patients Marie Kientz and Michael Bar [3]. His colleagues honoured his contribution by naming the condition as Von Recklinghausen's disease. However the different forms of neurofibromatosis were not separated and delineated until the latter part of the twentieth century. At last eight forms of neurofibromatosis have been recognized, the most common form being NF-1, or Von

Recklinghausen's disease. It accounts for about 90% of all the cases and is estimated to occur in one of every 3000 births. There is no sex predilection.

It is an autosomal dominant disease caused by a spectrum of mutations in the NF-1 gene. The NF-1 gene is located on the long arm of chromosome 17q 11.2 and encodes a 327 kDa protein called Neurofibromin [4]. The exact function of this protein is poorly understood, but the gene encoding neurofibromin has a sequence similar to a group of proteins called GTPase-activating proteins (GAP). This similarity suggests its involvement in negatively regulating the proteins coded by the Ras oncogene [5].

The Ras protein is like other G proteins and is dependent upon GTP binding for its full activity; GAP removes GTP by increasing the conversion of GTP to GDP. Enhanced Ras protein activity has been correlated with human cancer development, and dysfunction of neurofibromin could contribute to this [6]. Most NF-1 mutations result in reduced intracellular levels of the NF-1 gene product, neurofibromin. This appears to be sufficient to cause most of the clinical manifestations of this disorder.

A consensus development conference was held by the National Institute of Health (NIH) in 1987 to establish diagnostic criteria of patients with NF-1. There were seven diagnostic features recognized at this conference that have been applied without modification during the last 22 yrs. The diagnosis of NF-1 is established when two or more of these seven features listed below are present [7]:

- Six or more Café-au-lait macules larger than 5 mm in greatest diameter in prepubertal individuals: 15 mm in greatest diameter in postpubertal individuals.
- Two or more neurofibromas of any type or one plexiform neurofibroma.
- Freckling in the axillary or inguinal regions.
- Optic glioma.
- Two or more Lisch nodules (iris hamartomas).
- A distinctive osseus lesion such as sphenoid dysplasia or thinning of the long bone cortex, with or without pseudoarthrosis.
- A first degree relative with NF-1 according to the above criteria.

In our patient, three of the seven NIH diagnostic criteria were present.

Plexiform neurofibromas are benign peripheral nerve sheath tumours, often involving the trigeminal and upper cervical nerves [8]. They are diffuse, elongated fibromas, histologically similar to discrete neurofibromas and are usually seen in only 5-10 % of patients with NF-1. They often develop and become physically apparent within the first 2-5 years of life [9]. Their growth rate is highly variable. Often, overlying hyperpigmentation ('giant Café-au lait spot') or hypertrichosis can be seen.

There are two types of plexiform neurofibromas, nodular and diffuse. Diffuse plexiform neurofibroma is also known as elephantiasis neurofibromatosa and is characterized by an overgrowth of epidermal and subcutaneous tissue associated with a wrinkled and pendulous appearance. They can arise anywhere along a nerve and have poorly defined margins. They may appear on the face, legs, or spinal cord and frequently involve the cranial and upper cervical nerves. The cranial nerves most commonly involved in plexiform neurofibromas are the fifth, ninth and tenth nerves [10]. They can be quite disfiguring and hemifacial hypertrophy can occur secondary to a plexiform tumor involvement [11]. These tumors are known to cause symptoms ranging from minor discomfort to extreme pain. The consistency of the lesion has been compared to thtat of 'a bag of worms' because of the presence of soft areas interspersed with firm nodular areas and this very consistency was well appreciable in the lesions seen in our patient. They sometimes show vascular nature causing dangerous bleeding and may complicate surgical procedure. There appears to be an increase in the size of these tumors during puberty and pregnancy [12]. About 5% of the plexiform neurofibromas may turn malignant, usually into malignant peripheral nerve sheath tumors.

On microscopy, plexiform neurofibromas have a loose myxoid background with a low cellularity. They consist of poorly organized mixture of nerve fibrils with extensive interlacing of the nerve tissue. Small axons may be seen among the proliferating Schwann cells and perineural cells. These distorted masses are still contained within perineurium and surrounded by neurofibroma. The tumor is immunoreactive for S-100 protein.

The management of patients with plexiform neurofibromas is not well defined and is aimed mostly at controlling symptoms. Surgical excision is probably the only therapy available because there is no medication that can prevent or treat plexiform neurofibromas. However the results of surgical excisioin can be poor and the procedures can be complicated due to the size, location, vascular status, neural involvement, microscopic extension of the tumor, and the high rate of tumor regrowth. Tumors of the head / neck / face recur twice as compared to the plexiform neurofibromas of other locations. Also, subtotal resections recur more frequently than total resection of tumors. Retinoic acid therapy, angiogenesis inhibitors (such as interferons and thalidomide) are alternative therapies to surgery that have been tried. Oral Farnesyl protein transferase inhibitors and cytokine modulators are also under investigation.

The disfiguring nature of facial plexiform neurofibromatosis can be psychologically traumatic for most of the patients and often require good counseling. Psychological counselling with instilling of self confidence in such patients can possibly reduce their suffering and help them improve their quality of life.

REFERENCES

1. Korf BR: Plexiform neurofibromas. Am J Med Genet 1999; 89: 31-37.

2. Zanca A, Zanca A: Antique illustrations of neurofibromatosis. Int J Dermatol 1980; 19: 55-58.

3. von Recklinghausen FD: Ueber die multiplen Fibrome der Haut and ihre Beziehung zu den multiplen Neuromen. Berlin: Hirschwald; 1882.

4. Shen MH, Harper PS, Upadhyaya M: Molecular genetics of neurofibromatosis type1 (NF 1). J Med Genet 1996; 33: 2-17.
5. Wigler MH: Oncoproteins. GAP's in understanding Ras. Nature 1990; 346: 696-697.
6. Tsao H: Neurofibromatosis and tuberous sclerosis. In: Bolognia JL, Jorizzo JL, Rapini RP: Editors: Dermatology. Vol 1. Edinburg: Mosby, 2003: P 853-867.
7. Neurofibromatosis: Conference statement. National Institute of Health Consensus Development Conference. Arch Neurol 1998; 45: 575-578.
8. Khachemoune A, Al Aboud K, Al Hawsawi K: Diffuse plexiform neurofibroma in a 13 –year old girl. Dermatol Online J 2003; 9: 23.
9. Cunha KS, Barboza EP, Dias EP, Oliveria FM: Neurofibromatosis type 1 with periodontal manifestation. A case report and literature review. Br Dent J 2005; 196: 457-602.
10. D' Ambrosio JA, Langlais RP, Young RS: Jaw and skull changes in neurofibromatosis. Oral Surg Oral Med Oral Pathol 1998; 66: 391-396.
11. Neville BW, Damm DD, Allen CM, Bouquot JE: Oral and maxillofacial pathology. 2nd ed- Elsevier: Philadelphia; 2002. P. 457-461.
12. Frosch MP, Anthony DC, De Girolami UI: The central nervous system. In: Kumar V, Abbas AK, Fausto N, editors. Robbins and Cotran. Pathologic basis of disease. 7th ed. Elsevier: Philadelphia; 2004. 1412-1413.

Copyright by *Iffat Hassan, et al.* This is an open access article distributed under the terms of the Creative Commons Attribution License, which permits unrestricted use, distribution, and reproduction in any medium, provided the original author and source are credited.

FACIAL PLEXIFORM NEUROFIBROMATOSIS IN A PATIENT WITH NEUROFIBROMATOSIS TYPE1: A CASE REPORT

Iffat Hassan, Abid Keen, Parvaiz Ahmad Shah

Dr. Daisuke Tsuruta PhD, Dr. Takashi Hashimoto

Our Dermatol Online. 2012; 3(1): 28 Date of submission: 12.12.2011 / acceptance: 15.12.2011
Conflicts of interest: None

The two major types of neurofibromatosis are neurofibromatosis type 1 (NF-1) and neurofibromatosis type 2 (NF-2) [1,2]. NF-1 is characterized clinically by multiple café-au-lait spots associated with discrete neurofibromas along peripheral nerves, while NF-2 is characterized clinically by acoustic neuromas associated with various tumors of the nervous system~~s~~, particularly meningiomas [1,2]. NF-1 is a synonym for von Recklinghausen's disease, named after its first publication by von Recklinghausen in 1882 [3]. The diagnosis of NF-1 is made according to the list already mentioned in the text of Hassan et al [4]. Major findings found in NF-1 other than Café-au-lait spots and discrete neurofibromas are intertriginous freckling, optic pathway tumors, Lisch nodules, plexiform neurofibromas, oral lesions, osseous lesions, skeletal abnormalities, vasculopathy, endocrine disturbances, urinary symptoms, neurological manifestations, sarcomatous changes of neurofibromas and other malignant diseases [2,5]. Among these, Café-au-lait spots and freckling should be the earliest manifestations of NF-1 [2,5]. However, clinicians often have difficulty in diagnosing NF-1 when patients show minimum numbers of Café-au-lait spots or freckling in childhood cases. In such cases in the early diagnosis of NF-1, a knowledge of plexiform neurofibromas may be extremely helpful, as the association of plexiform neurofibromas in NF-1 is less common than that of discrete, classic neurofibromas and as it is noticeable by the age of 2 years [2,4,5].

Plexiform neurofibroma is histologically similar to discrete neurofibroma, and is a diffuse elongated fibromatous tumor involving the trigeminal or upper cervical nerves [5,6]. As plexiform neurofibromas occur at an early age with cosmetically disfiguring miserable features, it affects the patient both physically and mentally [4]. Therefore, elucidation of the pathogenesis and the development of a treatment for plexiform neurofibromas are highly essential. Surgical resection of plexiform neurofibroma should be the first choice, but offers no favorable results in patients with huge extensive lesions like Hassan's case [4]. Currently, chemotherapeutic options for the management of plexiform neurofibromas are ~~is~~ under way, including retinoic acid, angiogenesis inhibitors such as pegylated interferon α-2b and thalidomide, farnesyl protein transferase inhibitors or cytokine modulators, as mentioned in Hassan's report [4]. In addition, pirfenidone, an antifibrotic agent that decreases proliferation of fibroblasts and collagen matrix synthesis, and conventional chemotherapy including a combination of methotrexate and vinblastine were also applied to this horrible disease of NF-1 [5]. Hassan et al. had reported a typical, but extremely huge lesion of plexiform neurofibromas with best quality figures.

REFERENCES

1. Riccardi VM: Neurofibromatosis: clinical heterogeneity. Curr Probl Cancer 1982; 7: 1-3.
2. Irvine AD, Mellerio JE: Genetics and Genoermatoses. Burns T, Breathnach S, Cox N, Griffiths C (eds). In Rook's Textbook of Dermatology. 8th edition. Chapter 15, pp. 15.15, 2010, Wiley-Blackwell, West Sussex, UK.
3. Von Recklinghausen FD: Ueber die multiplen Fibrome der Haut and ihre Beziehung zu den multiplen Neuromen. Berlin: Hirschwald; 1882.
4. Hassan I, Keen A, Shah PA: Facal plexiform neurofibromatosis in a patient with neurofibromatosis type 1: a case report. Our Dermatol Online 2012; 5: 1-4.
5. Listernick R, Charrow J: The neurofibromatosis. Wolff K, Goldsmith LA, Katz SI, Gilchrest BA, Paller AS, Leffell DJ (eds). In Fitzpatrick's Dermatology in General Medicine. 7th edition. Chapter 142, pp. 1331-1338, 2008, McGraw Hill, New York.
6. Khachemoune A, Al Aboud K, Al Hawsawi K: Diffuse plexiform neurofibroma in a 13-year old girl. Dermatol Online J 2003; 9: 23.

Department of Dermatology, Kurume University School of Medicine, and Kurume University Institute of Cutaneous Cell Biology, Japan

Correspondence:
Takashi Hashimoto, MD
E-mail. hashimot@med.kurume-u.ac.jp

Copyright *Daisuke Tsuruta, et al.* This is an open access article distributed under the terms of the Creative Commons Attribution License, which permits unrestricted use, distribution, and reproduction in any medium, provided the original author and source are credited.

NASZA DERMATOLOGIA Online
OUR DERMATOLOGY Online

MILIARY OSTEOMA CUTIS OF THE FACE
ROZSIANY KOSTNIAK SKÓRY TWARZY

Saadia Bouraoui[1], Mona Mlika[1], Rim Kort[2], Fayka Cherif[2], Ahlem Lahmar[1], Sabeh Mzabi-Regaya[1]

[1]*Department of Anatomopathology, El Mongi Slim hospital, Tunis, Tunisia*
[2]*Department of Dermatology, Ben Arous hospital, Tunis, Tunisia*

***Corresponding author**:* Dr. Mlika Mona *mlika.zorgati.mona@hotmail.com*

Our Dermatol Online. 2012; 3(1): 29-32 Date of submission: 19.08.2011 / acceptance: 21.10.2011
Conflicts of interest: None

Abstract
Introduction: Miliary osteoma cutis (OC) of the face is a rare benign extra skeletal bone formation. For our knowledge, only 23 cases have been reported in the English literature. These lesions may be primary or secondary. They cause diagnostic, therapeutic and cosmetic concern especially in women who are usually concerned. Our purpose is to present a case which is completely documented with the clinical, histological and radiological findings. We also report a possible pathogenic theory according to our histologic findings.
Case Report: We report a case of a multiple miliary OC of the face in a 45-year-old woman which suffered from gravidarum acne. These lesions were treated by focal surgical treatment.
Conclusions: Based on our histological findings, an osteoblastic metaplasia seems to be a possible pathogenic theory. This metaplasia seems to be secondary to a chronic inflammation. Concerning therapeutic procedures, they are non consensual and debated and are based on surgical or medical treatment. More reports are needed in order to assess the therapeutic management of this disease and its inducing factors.

Streszczenie
Wstęp: Rozsiany kostniak skóry twarzy (KS) to rzadki przypadek pozaszkieletowego kostnienia. Zgodnie z naszą wiedzą, w czasopismach anglojęzycznych opisano do tej pory tylko 23 przypadki. Zmiany tego typu mogą być pierwotne lub wtórne. Powodują one trudności diagnostyczne, terapeutyczne i kosmetyczne - zwłaszcza u kobiet. Celem niniejszej pracy było przedstawienie całkowicie udokumentowanego (pod kątem badań klinicznych, histologicznych i obrazowych) przypadku tego schorzenia (przyp. red.). Informujemy w niej także, na podstawie naszych badań histologicznych, o możliwej patogenezie (tego typu zmian-przy. red.).
Opis Przypadku: Opisujemy przypadek 45-letniej kobiety z licznymi zmianami rozsianymi typu kostniaków na skórze twarzy, która cierpiała na ciężką postać trądzika. Zmiany te były leczone za pomocą miejscowych wycięć.
Podsumowanie: Na podstawie przeprowadzonych badań histologicznych metaplazja osteoblastyczna wydaje się najbardziej możliwą teorią patogenetyczną. Taka metaplazja jest prawdopodobnie wtórna do stanu przewlekłego zapalenia. Wciąż trwają dyskusje nad jednolitymi standardami procedur terapeutycznych, obecne leczenie polega na chirurgicznym wycięciu lub terapii lekami.

Key words: osteoma cutis; face; surgical treatment
Słowa klucze: osteoma cutis; twarz; leczenie chirurgiczne

Introduction

Miliary osteoma cutis (OC) of the face represents a primary extra-skeletal bone formation that arises within the skin of the face. It was first described by Wilekens in 1858 [1]. A few punctual cases have been subsequently reported in order to assess the diagnosis and the treatment of this benign disease which causes cosmetic concern.

Case report

We report the case of a 45-year-old woman with skin type III who suffered from gravidarum acne 20 years ago and was addicted to cosmetic products and skin cleansing. She hadn't a particular gynecologic history, especially no metrorrhagia or endometriosis. No special drug intake was mentioned. She presented in 2003 with multiple and asymptomatic small papular lesions of the brow and the forehead. The lesions have been progressively increased during a 3-year period and achieved the temples. These lesions were as hard as bone. They ulcerate spontaneously secondary to the use of a gomage solution. The patient reported the elimination of rice-like grains. Facial examination revealed numerous skin-coloured papules ranging from 1 to 4 mm, localized on the brow, the forehead and the temples (Fig. 1a). Physical examination didn't reveal

osteo-articular pain or any other abnormalities. Because of the multiplicity of the lesions and the esthetical concern, the patient received initially an inefficient local antiviral treatment due to the suspicion of a verrucous disease. She secondary received a local 0,005% topical retinoin without improvement of the lesions. The diagnoses of cutaneous sarcoidosis and miliary lupus were suspected. In order to assess the diagnosis, a punch biopsy specimen of the largest and the long-lasting lesion was performed and revealed dermal nodules of lamellar mineralized bone. Between the concentrically arranged bone lamellae, medullar spaces contained foci of adipose tissue without hematopoiesis. The bone lamellae were surrounded by a fibrotic tissue without osteoblasts which were seen along the medullar spaces (Fig. 1b). A small nodule, corresponding to a recent lesion, was surrounded by fibroblasts (Fig. 1c). Some of these fibroblasts showed vacuolated nuclei (Fig. 1d).

The adjacent dermis didn't show any inflammation and the epidermis was normal. A CT–scan of the face showed frontal sub-cutaneous hydroxyapatite-containing lesions which were independent from the frontal bone (Fig. 1e,1f). The diagnosis of miliary osteoma cutis of the face was retained. In order to assess its primary or secondary origin, laboratory examinations were performed. They showed normal levels of calcium, inorganic phosphorus, parathyroid hormone and vitamin D. The past medical history of gravidarum acne leads to the diagnosis of a secondary miliary facial osteoma. The patient refused needle microincisions with curettage of the lesions. She underwent a technique consisting in a standard scalpel incisions and excision of the biggest and the most inaesthetical lesions leading to their disappearance without recurrence.

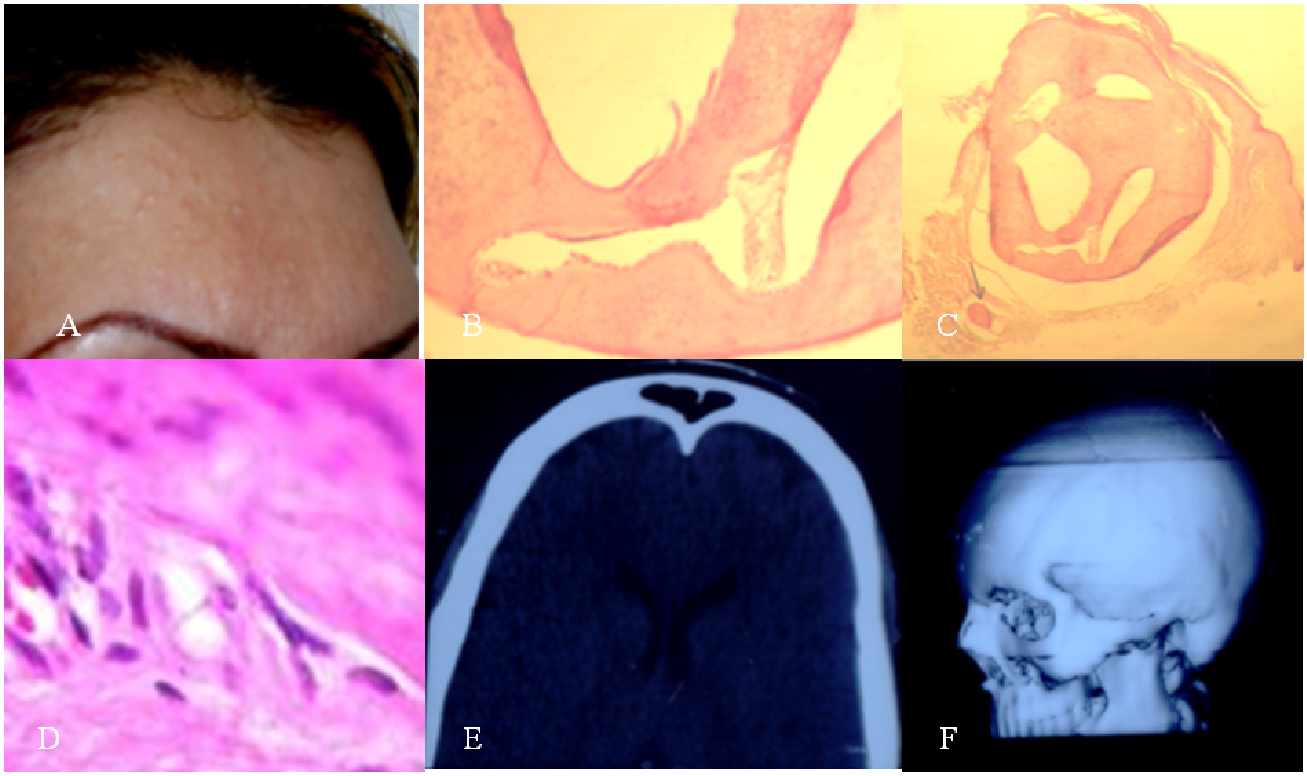

Figure 1. a/ Multiple small bumps on the brow. b/ osteoblasts are seen along the medullary spaces of a bone lesion (HEX400). c/ A small dermal nodule corresponding to a recent osseous lesion associated to a bigger nodule corresponding to a long-lasting lesion (HEX250). d/ Fibroblasts with vacuolated nuclei surrounding an osseous lesion (HEX400). e/ Axial CT-scan showing calcified lesions independent from the frontal bone. f/ Three dimensional CT-scan showing calcified lesions independent from the frontal bone

Discussion

Miliary OC of the face is a rare disease with about 23 cases reported in the Pubmed database (Tab. I). These lesions are secondary or primary. Secondary OC may be due to many disorders involving nevi, scleroderma, pilomatricoma, dermatomyositis, basal cell carcinoma, scars, inflammation, trauma, calcification, fibrous proliferations and venous stasis. Primary osteoma can't be retained unless all the previous causes are excluded [11]. Some authors reported extensive endometriosis, metrorrhagia and osteoarthritis affections in association with this disease [8]. Most cases have been reported in women with no evidence of the implication of the hormonal status. There are 4 main syndromes in which OC can be observed: Albright's hereditary osteodystrophy, fibrodysplasia ossificans progressive, progressive osseous heteroplasia and plate-like OC [11]. The patient described in our case suffered from gravidarum acne. Her lesions are therefore best characterized as a secondary miliary OC.

Authors	Year of publication	Manuscript's title
Essing M [1]	1985	Osteoma cutis of the forehead
Schrallhammer K et al [2]	1988	Primary osteoma cutis
Collina G et al [3]	1991	Cellular blue naevus associated with osteoma cutis
Moritz DL et al [4]	1991	Pigmented postacne osteoma cutis in a patient treated with minocycline : report and review of the literature.
Goldminz D et al [5]	1991	Multiple miliary osteoma cutis
Schuhmachers G et al [6]	1992	Osteoma cutis. Pathogenesis and therapeutic possibilities
Boehncke WH et al [7]	1993	Multiple miliary osteoma of the face
Ward M et al [8]	1993	Cas pour diagnostic
Levell NJ [9]	1994	Multiple papules on the face
Ratnavell RC [10]	1994	Osteoma cutis as a sequel of acne.
Altman JF et al [11]	2001	Treatment of primary miliary osteoma cutis with incision, curettage and primary closure
Bowman PH et al [12]	2001	Primary multiple miliary osteoma cutis and exogeneous ochronosis
Cohen AD et al [13]	2001	Treatment of multiple miliary osteoma cutis of the face with local application of tretinoin: a case report and review of the literature
Stockel S et al [14]	2002	Multiple miliary osteomas of the face
Bergonse FN et al [15]	2002	Miliary osteoma of the face : a report of 4 cases and review of the literature
Stanke S et al [16]	2003	Multiple miliary osteomas of the face
Thielen AM et al [17]	2006	Multiple cutaneous osteomas of the face associated with chronic inflammatory acne
Cohen PR et al [18]	2006	Isolated primary osteoma cutis of the head : Case report
Baskan EB et al [19]	2007	Miliary osteoma cutis of the face: treatment with the needle microincision-extirpation method
Haro R et al [20]	2009	Plaque-like osteoma cutis with transepidermal elimination

Table I. The different reported cases of miliary osteoma cutis of the face

These lesions are typically asymptomatic and usually appear as skin coloured papules in the scalp, the face as well as the trunk, the breast, the extremities and the buttocks. In cases with chronic acne, the differentiation from microcomedones and macrocomedones may be challenging [17]. In some cases, like in our patient, the diagnosis may be dismissed and the diagnosis of verrucous disease may be suspected. The diagnosis of OC may be suspected by the different size and consistence of the lesions and their radiological appearance but it can be retained only based on histologic examination. Histologic findings consist in a lamellar bone. Osetocytes and osteoblasts are embedded within the bone and are usually best seen along the periphery where mineralized and condensed collagen is still present. Osteoclasts and marrow elements may also be seen but are rare [11]. In our case, the osteoblasts were seen only along the lamellar bone's medullary spaces, the periphery was fibrotic.

The pathogenesis of this disease is mandatory to know in order to prevent its occurrence but it remains debated. Montgomery regarded the osteomas as hamartomas or nervoid tumours [21]. Burgdorf and Nasemann reported two possible processes. One theory assumes a disordered embryologic process, whereby primitive mesenchymal cells differentiate normally into osteoblasts but migrate to the wrong location. However, this remains speculative. The second theory, which appears more plausible and compatible with our histological findings, interprets the presence of bone as a result of osteoblastic metaplasia of mesenchymal cells, such as fibroblasts [22]. Levell reported that a long standing inflammation may cause mesenchymal cells differentiation into osteoblasts [9]. In fact, in our case, the gravidarum acne may have resulted in a fibrous scar and an osteoblastic metaplasia. According to our case, Thielen and coworkers reported an association of miliary osteoma cutis and chronic inflammatory acne [17]. This ultimate scar stage may represent a scarring phase, that's why no inflammatory lesions are seen. All these phenomenon are documented by the figure n°1C which shows a big ossified lesion surrounded by a fibrotic tissue and corresponding to a long lasting lesion. Below this lesion, a small ossified nodule without surrounding osteoblasts or inflammatory cells is seen. Fibroblasts that are adjacent to this nodule and shown in the figure n°1D have a vacuolated nucleus. This transformation could be interpreted as a stage of osteoblastic metaplasia. This nodule corresponded to a recent lesion. All these histological lesions were secondary to inflammatory lesions.

The procedures of treatment of this disease aren't consensual. Some authors advocate the medical treatments based on topical retinoin which are reported to enable the transepidermal elimination of the bone formation [4,5,23,24]. Several authors reported successful surgical techniques. Ratnavel, Burrows and Pye, used standard scalpel excision to remove multiple

miliary cutaneous osteomas [10]. This treatment was used in our case for some biggest and inaesthetical lesions, because of the inefficiency of the medical treatment, and induced their disappearance. Filton used dermabrasion combined with punch biopsies [25]. Dermabrasion was used to improve acne scarring and minimize post operative pigmentary changes. Baskan et al used needle microincision-extirpation method [19]. Oschendorf and Kaufmann used successfully the erbium: YAG laser to ablate the epidermis and upper dermis overlying the cutaneous osteomas [23]. A similar approach using the carbon dioxide laser was employed by Baginskin and Arpey [26]. Recenly, Ayaviri and coworkers reported the efficiency of the association medical and surgical treatment [18].

Conclusion

OC is a rare disease whose pathogenic origin remains debated. According to the past medical history of our patient and the progression of the histological lesions, we can suppose that the chronic inflammatory gravidarum acne induced osteoblastic metaplasia.

REFERENCES

1. Essing M: Osteoma cutis of the forehead. HNO. 1985; 33: 548-590.
2. Schrallhammer K, Landthaler M, Braun-Falco O: Primary osteoma cutis. Hautarzt. 1988; 39: 509-513.
3. Collina G, Annessi G, Di Gregorio C: Cellular blue naevus associated with osteoma cutis. Histopathology. 1991; 19: 473-475.
4. Moritz DL, Elewski B: Pigmented postacne osteoma cutis in a patient treated with minocycline : report and review of the literature. J AM Acad Dermatol. 1991; 24: 851-853.
5. Goldminz D, Greenberg RD: Multiple miliary osteoma cutis. J Am Acad Dermatol. 1991; 24: 878-881.
6. Schulmachers G, Worret WI: Osteoma cutis. Pathogenesis and therapeutic possibilities. Hautarzt. 1992; 43: 422-425.
7. Boehncke WH, Kaufmann R, Weber L, Sterry W: Multiple miliary osteoma of the face. Hautarzt. 1993; 44: 245-247.
8. Ward M, Viraben R: Cas pour diagnostic. Ann Dermatol Venereol. 1993; 120: 713-714.
9. Levell NJ, Lawrence CM: Multiple papules on the face. Arch Dermatol. 1994; 130: 373-374.
10. Ratnavel RC, Burrows NP, Pye RJ: Osteoma cutis as a sequel of acne. J R Soc Med. 1994; 87: 107-109.
11. Altman JF, Nehal KS, Busam KJ, Halpern AC: Treatment of primary miliary osteoma cutis with incision, curettage and primary closure. J Am Acad Dermatol. 2001; 44: 96-99.
12. Bowman PH, Lesher JL: Primary multiple miliary osteoma cutis and exogeneous ochronosis. Cutis. 2001; 68: 103-106.
13. Cohen AD, Chetov T, Cagnano E, Naimer S, Vardy DA: Treatment of multiple miliary osteoma cutis of the face with local application of tretinoin: a case report and review of the literature. J Dermatol Treat. 2001; 12: 171-173.
14. Stockel S, Eppinger S, Stein A, Meurer M: Multiple miliary osteomas of the face. Hautarzt. 2002; 53: 37-41.
15. Bergonse FN, Nico MM, Kavamura MI, Sotto MN: Miliary osteoma of the face: a report of 4 cases and review of the literature. Cutis. 2002; 69: 383-386.
16. Stanke S, Wessling-Assmann K, Metze D: Multiple miliary osteomas of the face. J Dtsch Dermatol Ges. 2003; 1: 131-133.
17. Thielen AM, Stucki L, Braun RP, Masouyé I, Germanier L, Harms M, et al: Multiple cutaneous osteomas of the face associated with chronic inflammatory acne. J Eur Acad Dermatol Venereol. 2006; 20: 321-326.
18. Ayaviri NA, Nahas FX, Barbosa MV, Farah AB, De Arimatéia Mendes J, Ferreira LM: Isolated primary osteoma cutis of the head: Case report. Can J Plast Surg. 2006; 14: 33-36.
19. Baskan EB, Turan H, Tunali S, Toker SC, Adim SB, Bolca N: Miliary osteoma cutis of the face: treatment with the needle microincision-extirpation method. J Dermatolog Treat. 2007; 18: 252-254.
20. Haro R, Revelles JM, Angulo J, Farina Mdel C, Martin L, Requena L: Plaque-like osteoma cutis with transepidermal elimination. J Clin Pathol. 2009; 36: 591-593.
21. Montgomery H: Dermatopathology, p1131. New York, Paul B. Hoeber, 1967.
22. Burgdorf W, Nasemann T: Cutaneous osteomas: a clinical and histopathologic review. Arch Fur Dermatol Forschung. 1977; 260: 121-135.
23. Ochsendorf FR, Kaufmann R: Erbium: YAG laser-associated treatment of miliary osteoma cutis. Br J dermatol. 1998; 138: 371-372.
24. Smith CG, Glaser DA: Treatment of multiple miliary osteoma cutis with retinoin gel. J Am Acad Dermatol. 1999; 1: 500.
25. Fulton JE: Dermabrasion-loop-punch-excision technique for the treatment of acne-induced osteoma cutis. J Dermatol Surg Oncol. 1987; 13: 655-659.
26. Baginski D, Arpey C: Management of multiple miliary osteoma cutis. Dermatol Surg. 1999; 25: 233-235.

Copyright by *Mlika Mona, et al.* This is an open access article distributed under the terms of the Creative Commons Attribution License, which permits unrestricted use, distribution, and reproduction in any medium, provided the original author and source are credited.

NASZA DERMATOLOGIA Online
OUR DERMATOLOGY Online

SEBACEOUS NAEVUS LOCATED IN NASAL CAVITY – A UNIQUE CASE

ZNAMIĘ ŁOJOTOKOWE ZLOKALIZOWANE W OBRĘBIE JAMY NOSOWEJ – RZADKI PRZYPADEK

Iffat Hassan, Mashkoor Ahmad, Shazia Jeelani

Deptament of Dermatology, STD & Leprosy Govt. Medical College & Associated SMHS Hospital, Srinagar-Kashmir, India

***Corresponding author**:* Dr. Iffat Hassan hassaniffat@gmail.com

Our Dermatol Online. 2012; 3(1): 33-35 Date of submission: 27.08.2011 / acceptance: 26.10.2011
Conflicts of interest: None

Abstract
Sebaceous naevi are congenital hamartomas comprising of sebaceous glands. They usually present at birth or may appear later as single lesion. The morphology of the lesion changes around puberty when it becomes thickened and nodular. Sebaceous naevus has definite potential for malignant transformation in later life therefore prophylactic surgical excision is recommended in childhood. The common sites of occurrence of naevus sebaceus are scalp and face. Involvement of mucus membrane is extremely rare in naevus sebaceous. We report this unusual case of naevus sebaceous located in nasal cavity involving nasal mucosa.

Streszczenie
Znamiona łojotokowe są wrodzonymi zmianami typu hamartoma, składającymi się z gruczołów łojowych. Zwykle obecne są już przy narodzeniu, lecz mogą pojawiać się także później jako zmiany pojedyncze. Ich morfologia zmienia się w okresie dojrzewania płciowego, kiedy to stają się grubsze i guzkowate. Zmiany tego typu mają stwierdzony potencjał transformacji nowotworowej w późniejszym okresie życia, dlatego też ich profilaktyczne, chirurgiczne usunięcie jest rekomendowane jeszcze w wieku dziecięcym. Najczęstsze miejsca występowania znamion łojowych to skóra głowy i twarzy. Zajęcie błon śluzowych jest bardzo rzadkie w tego typu zmianach. Opisujemy niecodzienny przypadek znamiona łojowego zlokalizowanego w obrębie błony śluzowej jamy nosowej.

Key words: mucus membrane; nasal cavity; naevus sebaceus
Słowa klucze: błona śluzowa; jama nosowa; znamię łojowe

Introduction

Sebaceous naevus or naevus sebaceus is a circumscribed hamartomatous lesion comprised predominantly of sebaceous glands. Majority of the sebaceous naevi occur sporadically but there are reports of familial cases [1]. The lesion usually starts as single plaque at birth or may develop later and remains unchanged until puberty when it becomes thickened and more elevated under the influence of sex hormones [2]. Malignant transformation is a well established complication of sebaceous naevi, however the life time risk is estimated to be less than 5% [3,4]. The majority of sebaceous naevi occur on head and neck favouring scalp, ears, forehead and skin of central part of the face. We report a case of sebaceous naevus located in nasal cavity involving nasal mucus membrane, an unusual site of occurrence.

Case report

A 14 year old boy presented with a six month history of an asymptomatic raised lesion at lower part of left nostril. History revealed that there was a yellowish spot at the site of lesion since the age of 3 years which remained unchanged till six month back when it started increasing in size. There was no history of other skin or systemic diseases. Examination revealed a whitish grey plaque (1.5cm x 0.5cm) on medial wall of left nasal cavity extending from outer border of columella into anterior part of mucus membrane of cartilaginous septum (Fig. 1). The surface of outer part of the plaque was micronodular and verrucoid and that of inner part of covered by mucus membrane was smooth. Rest of the examination of oral and nasal cavities was normal. General physical and systemic examination were within normal limits. Neurological, ophthalmological and musculoskeletal examination were normal.

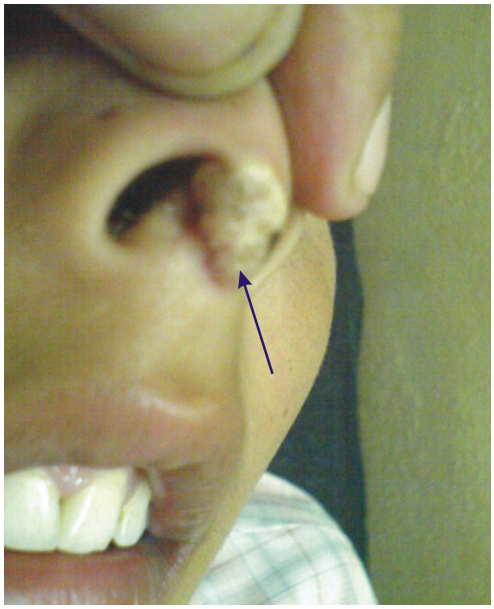

Figure 1. Verrucous micronodular plaque involving Columella and nasal septum

X-ray of facial bones and chest x-ray were normal. A full depth skin biopsy was taken from the outer part of the lesion with a 4mm disposable skin biopsy punch and subjected to histopathology. The histopathology revealed papillomatous hyperplasia of the epidermis and numerous mature and immature sebaceous glands and apocrin glands in dermis (Fig. 2). On the basis of history, clinical examination and histopathology, a diagnosis of sebaceous naevus was entertained and surgical excision of the lesion was done in one sitting. There was no recurrence after 8 months of follow up (Fig. 3).

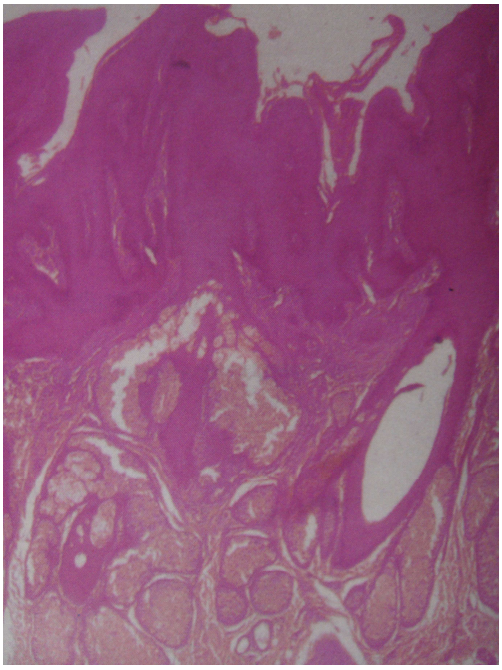

Figure 2. Histopathology showing Papillomatosis of Epidermis. Dermis shows mature and Immature sebaceous glands and apocrine glands (H&E, 100X)

Figure 3. Eight months after surgical excision

Discussion

The term sebaceous naevus was first described by Jadassohn in 1895 to describe congenital hamartomatous lesion composed predominantly of sebaceous glands. Naevus sebaceus occurs with equal frequency in males and females of all races and are seen in an estimated 0.3% of neonates [5]. The natural history of naevus sebaceus has 3 clinically distinct stages. At birth or in early infancy it appears as hairless, solitary, slightly raised pinkish, yellow, orange or tan plaque. At puberty, the lesion becomes verruceous and nodular and in later life, some lesion may develop various neoplastic changes [6]. The commonest benign tumour developing in naevus sebaceus is syringocystadenoma papilliferum and basal cell carcinoma (BCC) is the commonest malignancy reported [7,8]. In our case histopathology did not show any neoplastic changes.

Naevus sebaceus has predilection for scalp and less commonly occurs on face, neck or on trunk. Naevus sebaceus occurring exclusively in the oral cavity has also been reported [9]. The location of naevus sebaceus in the nasal cavity is a unique presentation in our case and to the best our knowledge it is the first case report of solitary naevus sebaceus involving nasal mucosa. The other differential diagnosis in our case were nasal papilloma, inverted papilloma and fibroma and these were ruled out on the basis of clinical examination and histological findings. The extensive linear form of naevus sebaceus is sometimes associated with neurological, ophthalmological and musculo-skeletal abnormalities and is called linear sebaceous naevus syndrome or organoid naevus syndrome [10]. There was no systemic pathology in our patient.

To conclude we report a unique case of naevus sebaceous located in nasal cavity and thus it should be kept in the differential diagnosis of intranasal lesions.

REFERENCES

1. Sahl WJ: Familial nevus sebaceous of Jadassohn: occurrence in three generations. J Am Acad Dermatol 1990; 22: 853-854.

2. Hamilton KS, Johnson S, Smoller BR: The role of androgen receptors in the clinical course of nevus sebaceous of Jadassohn. Mod Pathol. June 2001; 14: 539-542.
3. Kumar K, Garg RK: Naevus sebaceus of Jadassohn. Indian J Dermatol Venereol Leprol 1973; 39: 5-9.
4. Goldstein GD, Whitaker DC, Argenyi ZB, Bardach J: Basal cell carcinoma arising in naevus sebaceus during childhood. J Am Acad Dermatol 1988; 18: 429-430.
5. Alper J, Holmes LB, Mihm MC: Birthmarks with serious medical significance: nevocellular nevi, sebaceous nevi and multiple café-au-lait spots. J Pediatr 1979; 95: 696-700.
6. Chen MJ, Chan HL, Kuan YZ: Nevus sebaceous – a clinicopathological study of 104 cases. Chang Keng I Hsueh Tsa Chih 1990; 13: 199-207.
7. Cribier B, Scrivener Y, Grosshans E: Tumors arising in naevus sebaceus: A study of 596 cases. J Am Acad Dermatol 2000; 42: 263-268.
8. Baykal C, Buyukbabani N, Yazganoglu KD, Saglik E: Tumors associated with naevus sebaceus. J Dtsch Dermatol Ges 2006; 4: 28-31.
9. Warnke PH, Russo PA, Schimmelpenning GW, Happle R, Härle F, Hauschild A, et al: Linear intra-oral lesion in the sebaceous naevus syndrome. J Am Acad Dermatol 2005; 52: 62-64.
10. Moody BR, Hurt MA: Surgical management of cutaneous manifestations of linear naevus sebaceous syndrome. Plast Reconstr Surg 2004; 113: 799-800.

Copyright by *Iffat Hassan, et al.* This is an open access article distributed under the terms of the Creative Commons Attribution License, which permits unrestricted use, distribution, and reproduction in any medium, provided the original author and source are credited.

NASZA DERMATOLOGIA Online
OUR DERMATOLOGY Online

IMMUNOFLUORESCENCE IN MULTIPLE TISSUES UTILIZING SERUM FROM A PATIENT AFFECTED BY SYSTEMIC LUPUS ERYTHEMATOSUS

IMMUNOFLUORESCENCJA W WIELU TKANKACH Z WYKORZYSTANIEM SERUM OD PACJENTA Z TOCZNIEM RUMIENIOWATYM UKŁADOWYM

Ana Maria Abreu Velez[1], Michael S. Howard[1], Piotr Brzezinski[2]

[1]*Georgia Dermatopathology Associates, Atlanta, Georgia, USA*
[2]*Dermatological Clinic, 6th Military Support Unit, Ustka, Poland*

***Corresponding author**:* Ana Maria Abreu-Velez, MD PhD abreuvelez@yahoo.com

Our Dermatol Online. 2012; 3(1): 36-42 Date of submission: 08.10.2011 / acceptance: 08.12.2011
Conflicts of interest: None

Abstract
Introduction: Lupus erythematosus is a chronic, inflammatory autoimmune disease that can affect multiple organs. Lupus can affect many parts of the body, especially in systemic lupus erythematosus (SLE); affected tissues may include the joints, skin, kidneys, heart, lungs, blood vessels, and brain. **Case report:** A 46-year-old female presented with pruritus, photosensitivity and edema of the cheeks of about 2 years duration, and was evaluated by a dermatologist. On examination, multiple telangiectasias were present on the cheeks, with erythema, edema and a malar rash observed. A review of systems documented breathing difficulty and pleuitic pain, joint pain and joint edema, photosensitivity, cardiac dysrhythmia, and periodic pain in the back close to the kidneys. **Methods:** Skin biopsies for hematoxylin and eosin testing, as well for direct and indirect immunofluorescence were performed, in addition to multiple diagnostic blood tests, chest radiography and directed immunologic testing. **Results:** The blood testing showed elevated C-reactive protein. Direct and indirect immunofluorescence testing utilizing monkey esophagus, mouse and pig heart and kidney, normal human eyelid skin and veal brain demonstrated strong reactivity to several components of smooth muscle, nerves, blood vessels, skin basement membrane zone and sweat gland ducts and skin meibomian glands. Anti-endomysium antibodies were detected as well as others, especially using FITC conjugated Complement/C1q, FITC conjugated anti-human immunoglobulin IgG and FITC conjugated anti-human fibrinogen. **Conclusions:** We conclude that both direct and indirect immunofluorescence using several substrates can unveil previously undocumented autoantibodies in multiple organs in lupus erythematosus, and that these findings could be utilized to complement existing diagnostic testing for this disorder.

Streszczenie
Wstęp: Toczeń rumieniowaty jest przewlekłą, zapalną chorobą autoimmunologiczną, która może mieć wpływ na wiele narządów. Choroba może oddziaływać na cały organizm, zwłaszcza toczeń rumieniowaty układowy (SLE) może wpływać na stawy, skórę, nerki, serce, płuca, naczynia krwionośne i mózg. **Opis przypadku**: 46-letnia kobieta ze świądem, nadwrażliwością i obrzękiem policzków od około 2 lata została przebadana przez dermatologa. W badaniu obserwowano obecność teleangiektazji na policzkach, z rumieniem i obrzękiem. Stwierdzono ponadto udokumentowane trudności w oddychaniu i ból opłucnej, ból stawów i obrzęk stawów, nadwrażliwość na światło, zaburzenia rytmu serca, i okresowy ból pleców w okolicy nerek. **Metody**: Wykonywano biopsję skóry w barwieniu hematoksyliną i eozyną, jak również bezpośrednią i pośrednią immunofluorescencję, oprócz wielu badań diagnostycznych krwi, RTG klatki piersiowej i ukierunkowanych testów immunologicznych. **Wyniki:** Badania krwi wykazały podwyższony poziom białka C-reaktywnego. Bezpośrednia i pośrednia immunofluorescencja z wykorzystaniem przełyku małpy, serca myszy i świń oraz nerek, normalnej ludzkiej skóry powiek i cielęcego mózgu wykazały silną reaktywność kilku komponentów mięśni gładkich, nerwów, naczyń krwionośnych, zony warstwy podstawnej skóry i błony przewodów gruczołów potowych skóry oraz gruczołów tarczkowych. Wykryto przeciwciało przeciwko endomysium, a także inne, zwłaszcza za pomocą sprzężonego z FITC Complement/C1q, sprzężoną z FITC anty-ludzką immunoglobulinę IgG, skoniugowaną z FITC oraz anty-ludzki fibrynogen. **Wnioski:** Możemy stwierdzić, że bezpośrednia i pośrednia immunofluorescencja przy użyciu kilku substratów może ujawnić wcześniej nieudokumentowane autoprzeciwciała w wielu organach w przebiegu tocznia rumieniowatego układowego, oraz że te wyniki mogą być wykorzystane do uzupełnienia istniejących badań diagnostycznych w tym zaburzeniu.

Key words: Systemic lupus erythematosus; smooth muscle antibodies; monkey esophagus; direct and indirect immunofluorescence; autoantibodies
Słowa klucze: układowy rumieniowaty; przeciwciała mięśni gładkich; przełyk małpy; bezpośrednia i pośrednia immunofluorescencja; autoprzeciwciała

 © Our Dermatol Online 1.2012

Abbreviations: Systemic lupus erythematosus (SLE), antinuclear antibodies (ANA), subacute cutaneous LE (SCLE), basement membrane zone (BMZ), chronic discoid LE (DLE), direct immunofluorescence (DIF), indirect immunofluorescence (IIF), 4',6-diamidino-2-phenylindole (DAPI), American College of Rheumatology Criteria (ACRC).

Introduction

Systemic lupus erythematosus (SLE) is a chronic, potentially fatal autoimmune disease characterized by immune dysregulation; the dysregulation results in the production of antinuclear antibodies (ANAs), generation of circulating immune complexes, and activation of the complement system. The disease often manifests unpredictable exacerbations and remissions, and unpredictable clinical manifestations [1-5]. In SLE, there is an elevated probability for clinical involvement of the joints, kidney, brain, lung, heart, serosa and gastrointestinal tract [1-5]. Women and minorities are disproportionately affected; SLE is most common in women of child-bearing age, although it has been reported in extremes of life (e.g., in infants and through the tenth decade of life) [1-5]. The prevalence of lupus erythematosus in the United States has been estimated from approximately 250,000 patients to as high as 2,000,000. The pathologic hallmark of the disease is recurrent, widespread, and diverse vascular lesions [1-5]. In the 60% of SLE patients who experience the onset of their disease between puberty and the fourth decade of life, the female to male ratio is 9:1. Lupus is three times more frequent in African Americans than in American Caucasians [1-5]. The ethnic group at greatest risk is African Caribbean blacks. The annual incidence of SLE ranges from six to 30 new cases per 100,000 population in relatively low-risk to high-risk groups [1-5]. The American College of Rheumatology Criteria (ACRC) for lupus erythematosus were developed to nosologically define patients with this disorder [6]. The ACRC represent 11 criteria to establish a diagnosis of this disease. A patient must present four or more of the criteria to be classified as having lupus. These criteria are also utilized to insure the appropriateness of subjects for epidemiological or research studies. Although many patients do not fulfill the diagnostic criteria at first encounter, many do so when followed over time [6].

Case report

A 46 year old female visited the dermatologist for a two year history of skin tightening with pruritis and marked light hypersensitivity, especially on the skin of the face. On examination, erythematous, edematous areas were present on the cheeks, with multiple telangiectasis also noted. The patient's C-reactive protein value was 21.3 mg/l (normal limits to 4.0 mg/l); her white blood cell count (WBC) at 9.6 x10^3ul (4.0-10 x10^3ul normal value), with basophils at 0.5% (0.1-1.6% normal value), eosinophils at 0.7% (0,1-0.6% normal value), neutrophils at 6.6% (2.9-6.2% normal value), lymphocytes at 1.6% (1.8-8.4% normal values), and monocytes at 0.5% (0.15-1.3% normal value). Thyroid testing values were within normal limits. Other laboratory tests, including total peripheral blood protein, albumin, alkaline phosphatase, aspartate aminotransferase, alanine aminotransferase, and total and direct bilirubin were within normal limits. Antinuclear antibodies (ANA) were positive, at 1:160 with a homogeneous pattern (up to 1:80 normal value). Anti-cyclic citrullinated peptide antibodies (aCCP) were present at 9 EliA U/ml(normal limits: 7-10 EliA U/ml), and after 1 month increased to 10 EliA U/ml. No oral ulcers or neurological disorders were documented. Anti-DNA antibodies were negative; a Venereal Disease Research Laboratory test (VDRL) was also negative, and kidney function was normal. On physical exam, a sensitive area was present on the back in the area of the kidneys. The EKG demonstrated showed some cardiac dysrhythmia. The patient also related periodic chest pain, and pleuritic pain was detected on examination. Other physical examination findings included knee and elbow pain, edema and erythema; small cysts of the left ulna and of the ossa metacarpi were also detected. A thickening of the pleura on one right lung lobe was observed by chest radiography. Following workup, the patient was diagnosed with systemic lupus erythematosus (SLE), and prednisone (5mg per day) was prescribed for 2 months plus Niacin™ (200mg daily) and Rantydyne™ (300mg daily). Following this treatment, the patient did not show skin lesion improvement. Thus, these medications were discontinued and topical tacrolimus and metronidazole cream was initiated on the facial lesions**.**

Materials and Methods

A punch biopsy of the skin was performed for hematoxylin and eosin (H&E) analysis, as well as for multicolor direct and indirect immunofluorescence (DIF, IIF) utilizing multiple antigen tissues as substrates including monkey esophagus, porcine and murine heart and kidney, human eyelid and others. The tests were performed ultilizing previously described techniques and antibodies [7-13].

Results

Hematoxylin and Eosin staining

H&E staining displayed histologic features of a mild interface dermatitis, including hydropic degeneration of the basal cell layer. An associated superficial, perivascular dermal infiltrate of lymphocytes and histiocytes was present; upper dermal edema and perivascular extravasation of erythrocytes was also observed. The H&E, DIF and IIF results are summarized in the Figures 1-3.

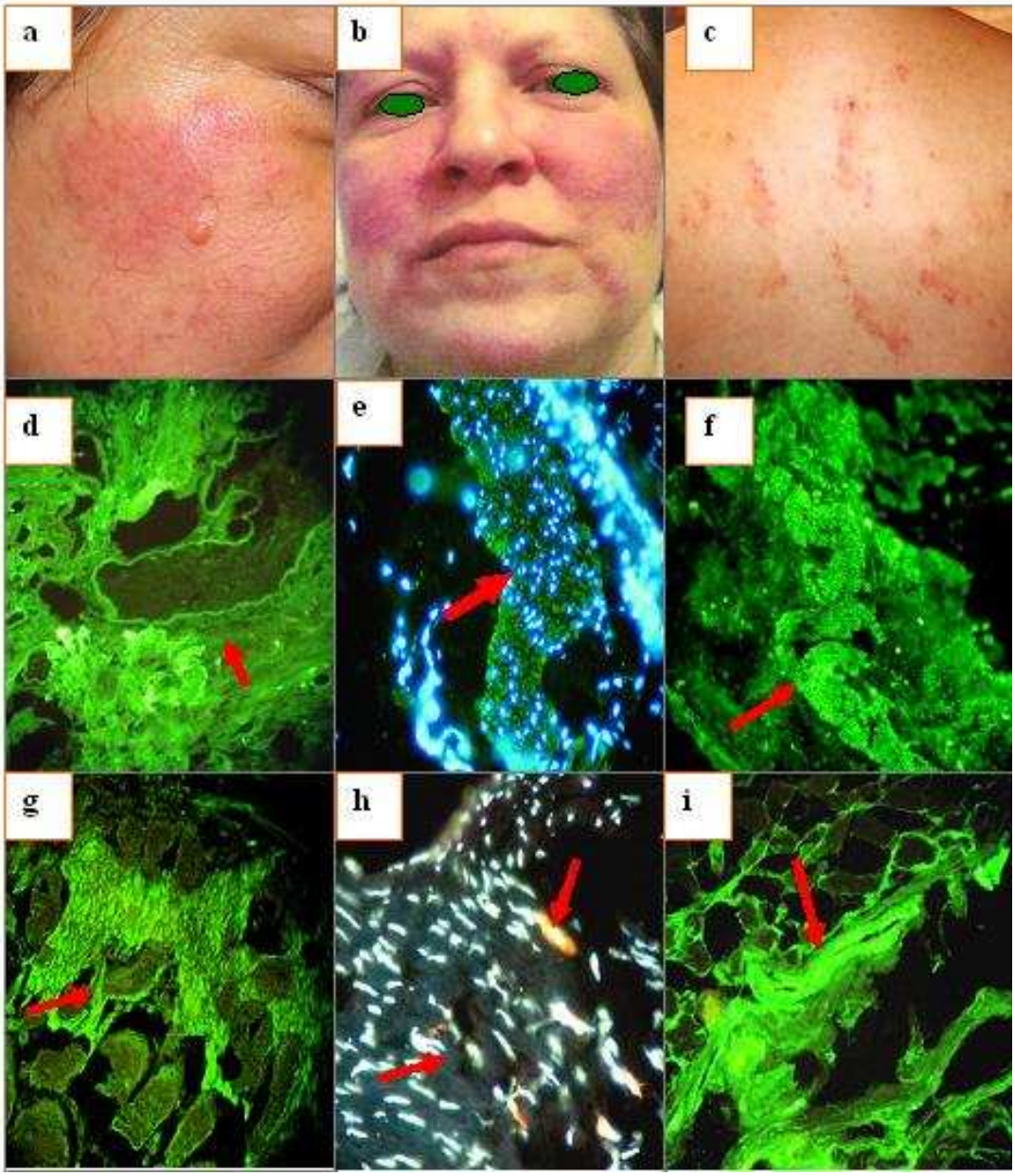

Figure 1. a through **c,** clinical pictures demonstrating erythematous, edematous plaques on the cheeks with fine telangiectasias. **d**. DIF demonstrating linear FITC conjugated Complement/C3 deposits along the BMZ of the hair follicle (yellow staining; red arrow). **e**. IIF on monkey esophagus substrate, demonstrating positive staining of the endomysium utilizing FITC conjugated anti-human Complement/C1q(green staining; red arrow); the nuclei of the substrate cells are counterstained in blue using DAPI. **f.** Similar to **e**, but without nuclear counterstaining. **g**. IIF on monkey esophagus substrate, demonstrating positive staining against smooth muscle utilizing FITC conjugated anti-human Complement/C1Qq(green staining; red arrow). **h**. IIF on monkey esophagus substrate, demonstrating positiviy against small blood vessels utilizing Alexa Fluor 647 conjugated anti-human IgG(orange staining; red arrows). **i.** IIF on monkey esophagus substrate, demonstrating positivity against larger blood vessels utilizing FITC conjugated anti-human fibrinogen (green staining; red arrow)

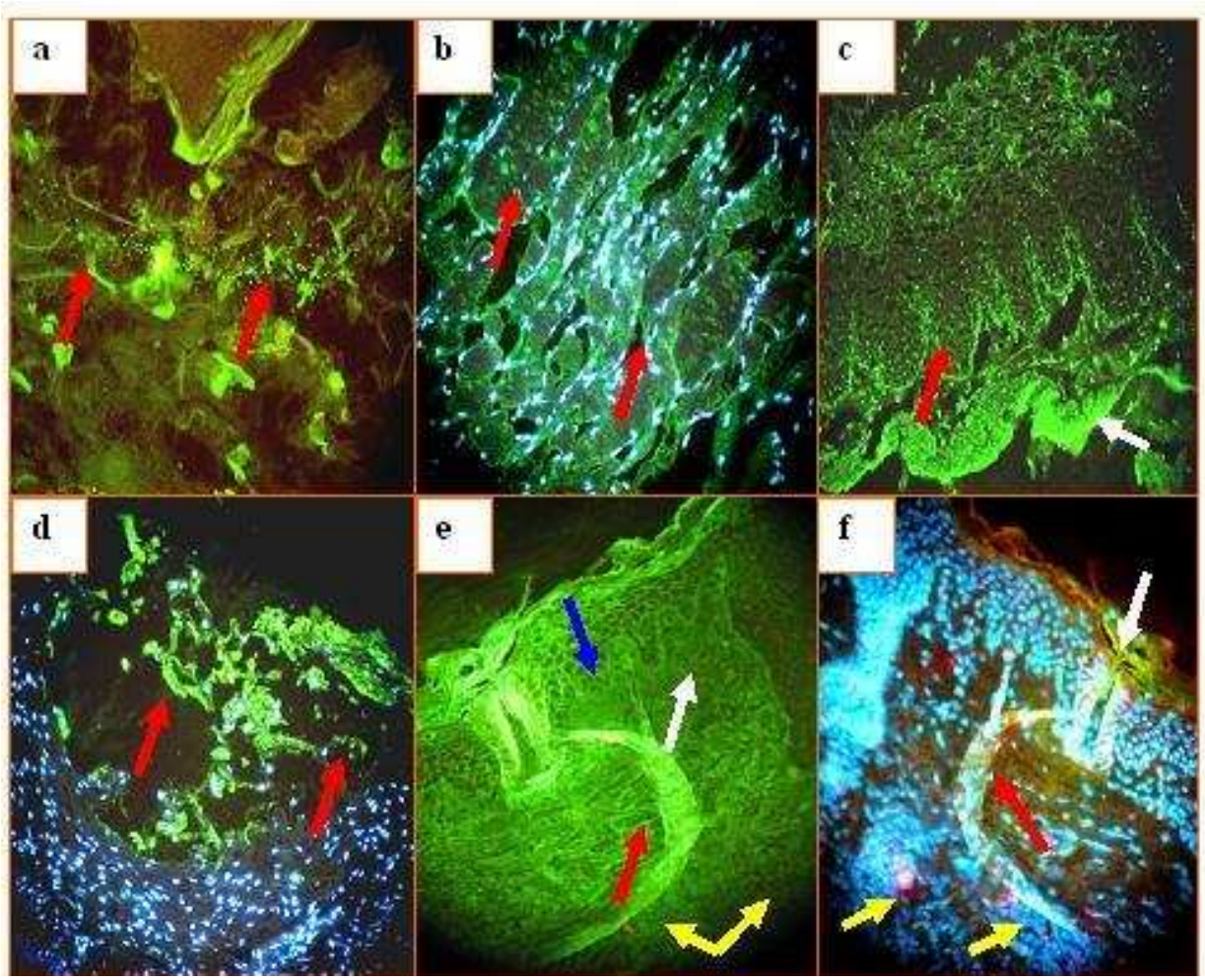

Figure 2. a. IIF on monkey esophagus substrate, demonstrating positivity against a large nerve utilizing FITC conjugated anti-human Complement/C1q(green staining; red arrows). **b**. IIF on monkey esophagus substrate, demonstrating positivity against several smooth muscle bundles utilizing FITC conjugated anti-human albumin (green staining; red arrows). Muscle cell nuclei are counterstained with DAPI in blue. **c.** IIF on monkey esophagus substrate, demonstrating linear positivity against the BMZ (light green staining; red arrow) using FITC conjugated anti-human Complement/C1q FITC and against the endomysium (white arrow). **d**. IIF on monkey esophagus substrate, displaying positivity against the internal layer of the esophagus resembling a pattern of anti-fibrillagrin antibodies, using FITC conjugated anti-human Complement/C3 (green staining; red arrows). The nuclei of the cells are counterstained with DAPI(blue staining). **e**. DIF of skin demonstrating positivity against an eccrine sweat gland ductus using FITC conjugated anti-human IgG (red arrow), against the BMZ (white arrow), and some intercellular staining in some patches of the epidermal stratum spinosum (blue arrow). Finally, note the orange staining against small blood vessels using Alexa Fluor 647 conjugated anti-human IgG(yellow arrows). **f.** Similar to **e,** but in this case we counterstained the nuclei with Dapi (blue staining). The white arrow shows reactivity against the acrosyringium, the yellow arrows against the blood vessels and the red arrow against a sweat gland ductus

Discussion

The precise etiology of SLE remains unidentified. A genetic predisposition, sex hormones, and environmental trigger(s) likely result in the dysregulated immune response that typifies the disease [1-5]. A role for genetics and environmental factors is suggested by the increased incidence of the disease in selected families and geographic regions [1-5].

A clinical cutaneous presentation of lupus erythematosus might include some SLE findings with findings of other variants, such as chronic discoid or subacute cutaneous lupus. However, the most common skin lesions seen in SLE are those of the acute type (including a malar rash with photosensitivity and telangiectasias), as demonstrated in this case [14-19]. DIF and IIF studies on skin samples for lupus have classically shown granular and/or linear deposits of IgG, IgA and IgM along the basement membrane zone of the skin, and selected immunoreactants present surrounding dermal blood vessels [14-18]. However, deposits of immunoglobulins and complement have been also recently documented to dermal sweat glands, sebaceous glands and nerves [7,8,10-12].

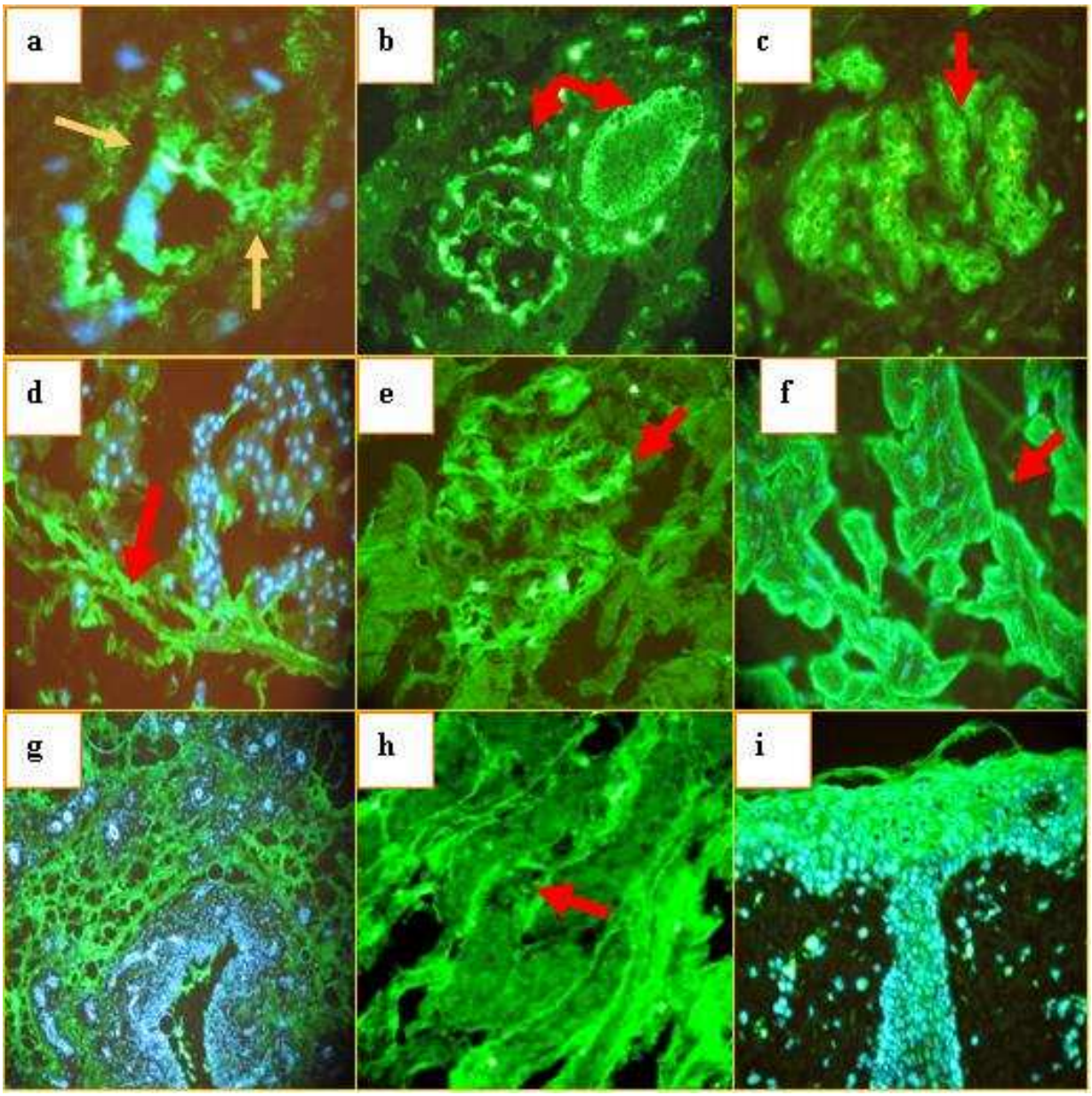

Figure 3. a. IIF utilizing veal brain shows immunoreactivity to several vessels using FITC conjugated anti-human fibrinogen (green staining, yellow arrows). The nuclei were counterstained with DAPI(blue). **b.** IIF utilizing normal human skin from an eyelid cosmetic surgery, and utilizing FITC conjugated anti-human Complement/C1q antibodies directed against the meibomian glands and their ducts (green staining, red arrows). **c.** Same tissue and antibody as in **b**; in this case, the antibodies recognized the modified sweat glands of the eyelids(green staining; red arrow). **d.** IIF utilizing murine kidney shows immunoreactivity to the capsule of the kidney using FITC conjugated anti-human fibrinogen(green staining; red arrow). The nuclei were counterstained with DAPI(blue). **e**. Similar to **d**, but in this case the positivity is against renal glomeruli(green staining; red arrow). **f.** IIF using porcine heart demonstrates immunoreactivity to several cardiomyocytes using FITC conjugated anti-human-IgG FITC(green staining, red arrow). The nuclei were again counterstained with DAPI in blue. **g.** IIF utilizing porcine instestine demonstrates immunoreactivity to several cells using FITC conjugated anti-human-IgG FITC(green staining, red arrow). The nuclei were counterstained with DAPI. **h.** IIF using murine kidney shows immunoreactivity to a kidney tubule utilizing FITC conjugated anti-human fibrinogen(green staining, red arrow). **i**. IIF utilizing normal human eyelid skin from cosmetic surgery using FITC conjugated anti-human Complement/C1q antibodies directed against epidermal keratinocytes in a perinuclear fashion (green staining). Keratinocyte nuclei are counterstained in blue with DAPI

The origin of autoantibody production in SLE is uncertain; suggested possibilities have included an antigen driven process, spontaneous B-cell hyper-responsiveness, or impaired immune regulation. Regardless of the etiology of autoantibody production, SLE is associated with impaired clearance of circulating immune complexes [1-5]. More is known about the pathogenic cellular and molecular events which are responsible for the vascular lesions in SLE than regarding the precise origins of the autoimmunity [1-5]. Disease manifestations result from recurrent vascular injury due to immune complex deposition, leukothrombosis, or thrombosis [1-5]. Additionally, cytotoxic antibodies can mediate autoimmune hemolytic anemia and thrombocytopenia, while antibodies to specific cellular antigens can disrupt cellular function. An example of the latter is the association between anti-neuronal antibodies and neuropsychiatric SLE [1-5]. In our study, our DIF and IIF results and the patient review of the systems directed us to search for damage in other organs, especially antibodies to smooth muscle and blood vessels. This patient was found to have pleuritis; some authors have also described pleuitic antibodies to be present in cases of SLE [20,21].

Our findings are of interest, because tests other than classical antibody testing may be of value in the diagnosis of SLE. Recently, murine liver and kidney, and epithelial cell lines obtained from human laryngeal carcinoma (including Hep-2) have been explored as substrates for ANA testing. Such ANA testing has high diagnostic sensitivity, and most ANAs are of IgG isotype [23]. Other autoantibodies routinely tested for lupus and anti-cytoplasmic antibodies (such as anti-Ro/SSA and anti–t-RNA synthetases) are not always readily detected on these substrates due to scarcity of the antigen in Hep-2 cells, and/or antigen leaching and denaturation secondary to fixation procedures [23]. At present, of the approximately 40 types of possible diagnostic fluoroscopic patterns identified in one pertinent study, only 19 are directly associated with clinical diagnoses; moreover, for many autoantibodies, the target autoantigen has not been identified with certainty [23].

We thus conclude that there are several patterns of autoantibodies that have not been well elucidated, and could assist in the laboratory diagnosis of SLE.

REFERENCES

1. Hochberg MC: Systemic lupus erythematosus. Rheum Dis Clin North Am. 1990; 16: 617-639.
2. Arnold HL Jr: Systemic lupus erythematosus.AMA Arch Derm Syphilol. 1950; 62: 632-634.
3. Aringer M, Hiepe F: Systemic lupus erythematosus.Z Rheumatol. 2011; 70: 313-323.
4. Chang C, Gershwin ME: Drug-induced lupus erythematosus: incidence, management and prevention.Drug Saf. 2011; 34: 357-374.
5. Tebbe B, Mansmann U, Wollina U, Auer-Grumbach P, Licht-Mbalyohere A, Arensmeier M, Orfanos CE: Markers in cutaneous lupus erythematosus indicating systemic involvement. A multicenter study on 296 patients. Acta Derm Venereol. 1997; 77: 305-308.
6. Tan EM, Cohen AS, Fries JF, Masi AT, McShane DJ, Rothfield NF, et al: The 1982 revised criteria for the classification of systemic lupus erythematosus. Arthritis Rheum. 1982; 25: 1271-1277.
7. Abreu-Velez AM, Smith JG Jr, Howard MS: Activation of the signaling cascade in response to T lymphocyte receptor stimulation and prostanoids in a case of cutaneous lupus. North Am J Med Sci. 2011; 3: 251-254.
8. Abreu Velez AM, Smith JG Jr, Howard MS: Cutaneous lupus erythematosus with autoantibodies colocalizing with glial fibrillary acidic protein. N Dermatol Online. 2011; 2: 8-11.
9. Howard MS, Yepes MM, Maldonado JG, Villa E, Jaramillo A, Botero J, et al: Broad histopathologic patterns of non-glabrous skin and glabrous skin from patients with a new variant of endemic pemphigus foliaceus (part 1). J Cutan Pathol. 2010; 37: 222-230.
10. Abreu Velez AM, Smith JG Jr, Howard MS: Vimentin compartamentalization in discoid lupus. North Am J Med Sci. 2010; 2: 106-110.
11. Abreu Velez AM, Howard MS, Loebl AM: Autoreactivity to sweat and sebaceous glands and skin homing T cells in lupus profundus. Clin Immunol. 2009; 132: 420-424.
12. Abreu Velez AM, Girard JG, Howard MS J: Antigen presenting cells in a patient with hair loss of and systemic lupus erythematosus. North Am J Med Sci. 2009; 1: 205-210.
13. Abreu Velez AM, Smith JG Jr, Howard MS: Neutrophil extracellular traps (NETS), IgD, myeloperoxidase (MPO) and antineutrophil cytoplasmic antibody (ANCA) associated vasculitides. North Am J Med Sci. 2009; 1: 309-313.
14. Watanabe T, Tsuchida T: Classification of lupus erythematosus based upon cutaneous manifestations. Dermatological, systemic and laboratory findings in 191 patients. Dermatology. 1995; 190: 277-283.
15. Grönhagen CM, Fored CM, Granath F, Nyberg F: Cutaneous lupus erythematosus and the association with systemic lupus erythematosus: a population-based cohort of 1088 patients in Sweden. Br J Dermatol. 2011; 164: 1335-1341.
16. Tebbe B: Clinical course and prognosis of cutaneous lupus erythematosus. Clin Dermatol. 2004; 22: 121-124.
17. Cardinali C, Caproni M, Bernacchi E, Amato L, Fabbri P: The spectrum of cutaneous manifestations in lupus erythematosus--the Italian experience.Lupus. 2000; 9: 417-423.

18. Vera-Recabarren MA, García-Carrasco M, Ramos-Casals M, Herrero C: Comparative analysis of subacute cutaneous lupus erythematosus and chronic cutaneous lupus erythematosus: clinical and immunological study of 270 patients. Br J Dermatol. 2010; 162: 91-101.
19. Kuhn A, Schuppe HC, Ruzicka T, Lehman P: Rare cutaneous manifestations of lupus erythematosus. A clinical overview. Hautarzt. 2000; 51: 818-825.
20. Velthuis PJ, Kater L, van der Tweel I, de la Faille HB, van Vloten WA: Immunofluorescence microscopy of healthy skin from patients with systemic lupus erythematosus: more than just the lupus band. Ann Rheum Dis. 1992; 51: 720–725.
21. Guo H, Leung JC, Chan LY, Chan TM, Lai KN: The pathogenetic role of immunoglobulin G from patients with systemic lupus erythematosus in the development of lupus pleuritis. Rheumatology (Oxford). 2004; 43: 286-293.
22. Ngian GS, Naidoo P, Morand EF, Hoi AY: Smooth muscle myopathy as an underrecognized manifestation of active systemic lupus erythematosus. Intern Med J. 2011; 41: 495-498.
23. Tozzoli R, Bizzaro N, Tonutti E, Villalta D, Bassetti D, Manoni F, et al: Italian Society of Laboratory Medicine Study Group on the Diagnosis of Autoimmune Diseases. Guidelines for the laboratory use of autoantibody tests in the diagnosis and monitoring of autoimmune rheumatic diseases. Am J Clin Pathol. 2002; 117: 316-324.

Funding source: Georgia Dermatopathology Associates, Atlanta, Georgia, USA

Copyright *Ana Maria Abreu Velez et al.* This is an open access article distributed under the terms of the Creative Commons Attribution License, which permits unrestricted use, distribution, and reproduction in any medium, provided the original author and source are credited.

NASZA DERMATOLOGIA Online
OUR DERMATOLOGY Online

POROID HIDRADENOMA: A CASE REPORT

POROID HIDRADENOMA: OPIS PRZYPADKU

Mona Mlika[1], Beya Chelly[1], Aida Ayadi-Kaddour[1], Sadok Boudaya[2], Tarek Kilani[2], Faouzi El Mezni[1]

[1]*Department of Pathology, Abderrahman-Mami Hospital – Ariana, University of Medicine El Manar, Tunis. Tunisia*
[2]*Department of Cardio-Thoracic Surgery, Abderrahman-Mami Hospital – Ariana, Tunis, Tunisia*

***Corresponding author**:* Dr. Mona Mlika *mlika.zorgati.mona@hotmail.com*

Our Dermatol Online. 2012; 3(1): 43-45 Date of submission: 22.10.2011 / acceptance: 25.11.2011
Conflicts of interest: None

Abstract
Introduction: Poroid hidradenoma is a variant of the eccrine poroma that belongs to the group of poroid neoplasm. It presents architectural features of hidradenoma and cytologic features of poroid neoplasm. To date, very few cases of this entity have been reported in the literature.
Case presentation: An eighty-one-year-old man whose past medical history was consistent for a Parkinson's disease presented with a presternal nodular mass. Physical examination revealed a 6 cm, painless, and pedunculated presternal tumefaction. Chest Ultrasound examination revealed a heterogeneous tumor with anechoic areas and cystic component. CT-scan showed a presternal subcutaneous mass presenting a dual component sloid and cystic with stigmates of recent bleeding. A total surgical excision was performed and histologic examination concluded to a poroid hidredenoma.
Conclusion: Poroid hidradenoma is the newest variant added to poroid neoplasm. Histologic characteristics may be challenging necessitating a thorough sampling. Treatment is based on surgical resection in order to to prevent from a possible recurrence or malignant transformation.

Streszczenie
Wstęp: Poroid hidradenoma jest wariantem poroma eccrine, który należy do grupy „poroid neoplasm". Przedstawia cechy architektoniczne hidradenoma i cytologiczne cechy „poroid neoplasm". Do tej pory przedstawiono w literaturze bardzo niewiele przypadków tej jednostki chorobowej.
Opis przypadku: 81-letni mężczyzna, z chorobą Parkinsona prezentował masy guzowate w okolicy przedmostkowej. Badanie fizykalne ujawniło 6 cm, bezbolesne i szypułowate, przedmostkowe obrzmienie. Badanie USG klatki piersiowej ujawniło heterogenicznego guza z bezechowym obszarem i torbielowatym komponentem. CT-scan wykazał przedmostkowe podskórne masy prezentujące dwuskładnikowy lity komponent i torbiel z obecnością świeżego krwawienia. Wykonano całkowite chirurgiczne wycięcie, a badanie histologiczne wykazało cechy poroid hidredenoma.
Wniosek: Poroid hidradenoma to najnowszy wariant „poroid neoplasm". Cechy histologiczne mogą być wyzwaniem wymagającym dokładnego pobierania próbek. Leczenie polega na resekcji w celu uniknięcia ewentualnego nawrotu lub transformacji złośliwej.

Key words: poroid hidradenoma; eccrine poroma; surgical resection
Słowa klucze: poroid hidradenoma; eccrine poroma; chirurgiczne usunięcie

Introduction

Eccrine gland-derived lesions make up a large and relatively common group of adnexal tumors. Hidroacanthoma simplex, dermal duct tumor and eccrine poroma form a fairly homogeneous family derived from eccrine duct and pore. They belong to the poroid neoplasm group that represents 10% of sudoriferous tumors. Poroid hidradenoma is a recently recognized variant of poroid neoplasm that should be differentiated from apocrine hidradenoma [1]. It is a benign neoplasm with eccrine differentiation, originally described by Abenoza and Ackerman in 1990. Since then, less than 20 cases of poroid hidradenoma have been reported in the literature.

Case report

An eighty-one-year-old man whose past medical history was consistent for a Parkinson's disease, consulted for a pre-sternal lesion which appeared few years ago and has been growing gradually.

Physical examination revealed a 6 cm and painless, pedunculated, presternal tumefaction with a hard consistency. Chest-X-ray was normal. Chest ultrasound examination revealed a heterogeneous tumor with anechoic areas and a cystic component. CT-scan showed a presternal subcutaneous mass presenting two components cystic and massive with stigmate of recent bleeding (Fig. 1a). Facing the radiologic findings, the diagnosis of a vascular tumor was initially suspected. A radical surgical excision was performed. On gross examination, we received a 6-centimeter mass with both solid and cystic components (Fig. 1b). Microscopic examination revealed a well demarcated and symmetrical tumor with eccrine differentiation situated in the dermis without connection to the overlying epidermis (Fig. 1c). This tumor presented architectural features of hidradenoma with tumor cells confined entirely within the dermis in both solid and cystic components and cytological features of a poroid neoplasm with poroid and cuticular cells showing ductal differentiation (Fig. 1d,e). At higher magnification, poroid cells had scanty cytoplasm and an oval to round nucleus with inconspicuous nucleoli. Cuticular cells had abundant and eosinophilic cytoplasm in which a larger nucleus was present (Fig. 1f). Neither atypical cells nor necrotic changes were observed. The patient was discharged few days later with no complications reported. The surgical wound healed in 2 weeks with normal scarring.

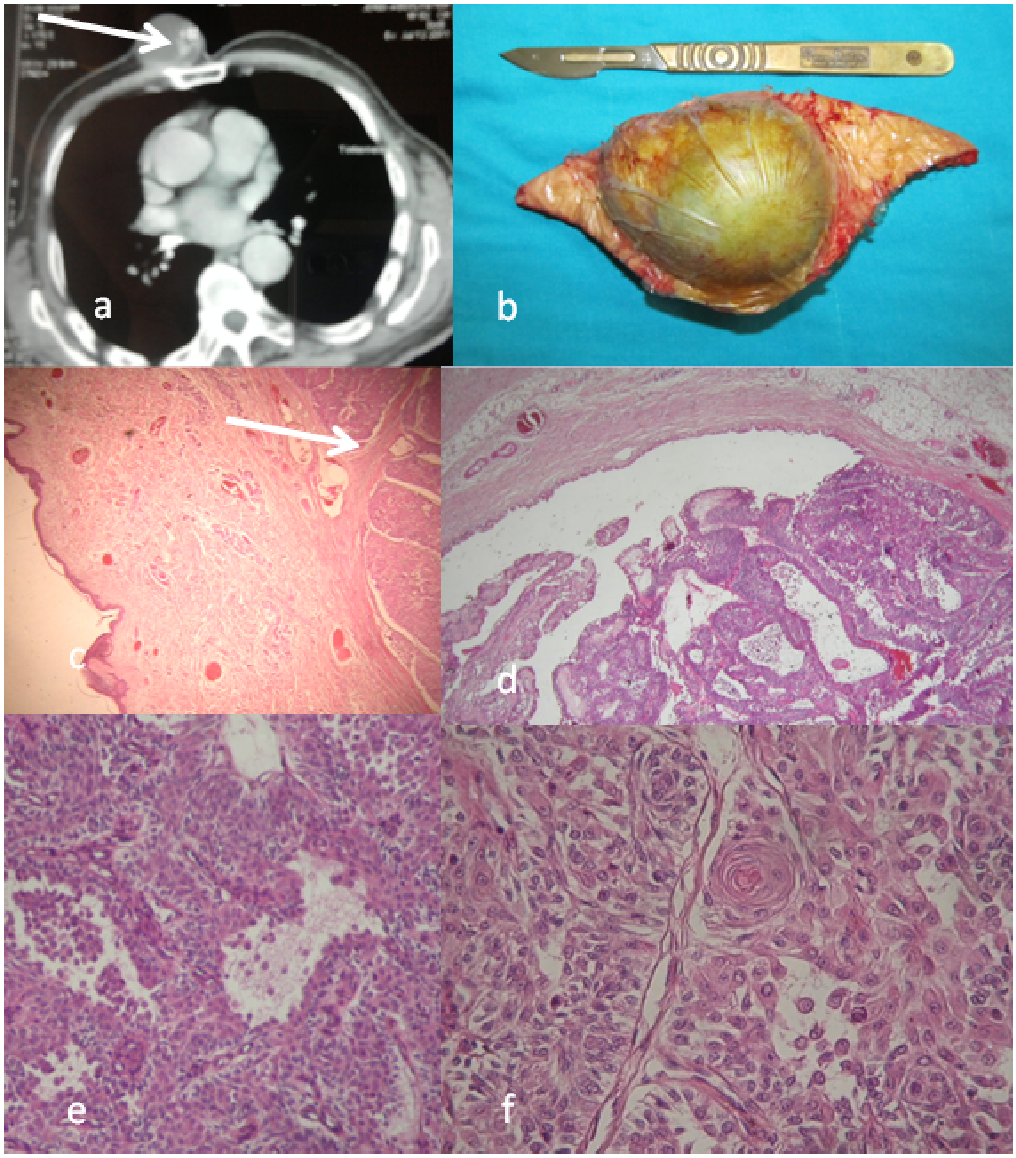

Figure 1 a: CT-scan showing a pre-sternal mass presenting two components cystic and massive. **b:** Gross features of a 6-centimeter sub-cutaneous mass with both solid and cystic components. **c:** Microscopic findings of a sub-cutaneous mass (HE x 250). **d:** Microscopic findings of a sub-cutaneous mass confined entirely within the dermis with both solid and cystic components (HE x 250). **e:** Microscopic findings showing a poroid neoplasm with poroid and cuticular cells showing ductal differentiation (HE x 400). **f:** Poroid cells had scanty cytoplasm and an oval to round nucleus with inconspicuous nucleoli. Cuticular cells had abundant and eosinophilic cytoplasm in which a larger nucleus is present (HE x 400)

Discussion

Poromas are benign neoplasms composed of poroid and cuticular cells. Four histopathologic variants are identified according to the architectural features of the neoplasm: hidradenoma simplex or intraepidermal poroma, eccrine poroma, dermal duct tumor and poroid hidradenoma [2].

Poroid hidradenoma is an uncommon variant of the eccrine poroma described by Abenoza and Ackerman in 1990. It is usually a solitary asymptomatic neoplasm that rarely becomes malignant in less than 1% of cases. The age of presentation varies from 28 to 77 years, with a peak of incidence in the seventh decade [3]. Its incidence is approximately equal in male and female patients. There is no predilection as to where the solitary lesion might occur. Typically poroid hidradenoma presents as a solitary, tender papule or nodule, well circumscribed and wholly intra-dermal, with a diameter ranging from 1 to 2 cm. It appears slightly reddish but the presence of cystic parts may confer a blue color on the lesion caused by the Tyndall phenomenon [1]. This was the case in our observation. In fact, the tumor contained two components: one solid and one cystic. Histologic examination showed that this neoplasm presents architectural features of hidradenoma, with solid and cystic areas and tumor cells restricted to the dermis (without connection to the epidermis), and cytological features of poroid neoplasm such as poroid and cuticular cells [4]. It is composed of cells similar to those in the uppermost segment of the intradermal eccrine duct and in the lower segment of the intraepidermal (acrosyringeal) eccrine duct. The poroid cells had scanty cytoplasm and an oval to round nucleus with inconspicuous nucleoli. Cuticular cells had voluminous and eosinophilic cytoplasm in which a larger nucleus with occasional multinucleation, resembling cuticles of eccrine duct [5]. Immunohistochemical study based on the keratin revealed that the neoplastic cells in eccrine poromas are considered to be closely related to the cells of dermal sweat ducts. Also the cuticular cells are considered to occupy an intermediate spectrum between the inner and outer cells of the dermal ducts [6].

The diagnosis of poroid hidradenoma is based on histologic examination of tissue samples; however, fine needle aspiration cytology (FNAC) can be useful in the diagnosis of cutaneous lesions especially in cases with cyst formation [5].

The differential diagnosis include other poromas such as hidroacanthoma simplex which is characterized by nests of round cells within the normal epidermal cells; dermal duct tumor which have histopathologic features of hidroacanthoma simplex but with the tumor cells located in the dermis; and eccrine poroma which is a lesion characterized by a clear margin between normal epidermal keratinocytes and a population of smaller cuboidal cells usually with darker nuclei protruding down into the underlying dermis. Apocrine hidradenomas are also considered as possible differential diagnoses. They account for 95% of all hidradenomas and have apocrine differentiation and. They are characterized by mucinous, polygonal and clear cells with areas of tubular differentiation. Some benign subcutaneous connective neoplasms such as fibroma, fibrolipoma, dermatofibroma, hemangioma, pyogenic granuloma, epidermal inclusion cyst, basal cell epithelioma and malignant eccrine poroma may also be challenging and may cause confusion with poroid hidradenoma [1]. The treatment of poroid hidradenoma is surgical including total excision of the lesion in order to prevent its recurrence. The prognosis of poroid hidradenoma is fairly good, and recurrence has been reported in only one case [5]. It is a benign tumor that can be easily misdiagnosed as a malignant neoplasm. This fact makes the thourough sampling and histologic examination mandatory in order to establish the diagnosis.

Conclusion

Poroid hidradenoma is the newest addition to the group of poromas. It is rarely reported in the literature. The diagnosis is made based on histologic findings. It is usually a benign neoplasm which needs surgical treatment consisting in total excision of the lesion in order to prevent recurrence and possible malignant transformation.

REFERENCES

1. Delfino S, Toto V, Brunetti B, Di Marino MP, Baldi A, Persichetti P: Poroid hidradenoma: A case report. In vivo 2007; 21: 905-908.
2. Rutten A, Requena L, Requena C: Clear-cell porocarcinoma in situ: a cytologic variant of porocarcinoma in situ. Am J Dermatopathol. 2002; 24: 59-62.
3. López V, Santonja N, Calduch-Rodríguez L, Jordá E: Poroid hidradenoma in a child: An unusual presentation. Pediatric Dermatology. 2011; 28: 1.
4. Requena L, Sanchez M: Poroid hidradenoma: a light microscopic and immunohistochemical study. Hautarzt. 1991; 42: 692-699.
5. Hoshida Y, Hanai J, Matsushita N, Yonekawa M, Kobayashi Y, Kawakami H, et al: Poroid hidradenoma: Report of a case with cytologic findings on fine needle aspiration. Acta Cytol 1999; 43: 471-474.
6. Yamamoto O, Hisaoka M, Yasuda H, Kasai T, Hashimoto H: Cytokeratin expression of apocrine and eccrine poromas with special reference to its expression in cuticular cells. J Cutan Pathol. 2000; 27: 367-373.

Copyright *Mona Mlika et al.* This is an open access article distributed under the terms of the Creative Commons Attribution License, which permits unrestricted use, distribution, and reproduction in any medium, provided the original author and source are credited.

NASZA DERMATOLOGIA Online
OUR DERMATOLOGY Online

TUMOR CUTÁNEO DE CÉLULAS GRANULARES. DESCRIPCIÓN DE TRES CASOS Y REVISIÓN DE LA LITERATURA

CUTANEOUS GRANULAR CELL TUMOR. REPORT OF THREE CASES AND REVIEW OF THE LITERATURE

GUZ Z KOMÓREK ZIARNISTYCH. RAPORT TRZECH PRZYPADKÓW I PRZEGLĄD PIŚMIENNICTWA

Beatriz Di Martino Ortiz[1], Ana Soskin Reidman[2]

[1]*Cátedra de Dermatología. Hospital de Clínicas de la Facultad de Ciencias Médicas de la Universidad Nacional de Asunción. Paraguay*
[2]*Servicio de Anatomía Patológica. Hospital Nacional, Itauguá, Paraguay*

***Corresponding author**:* Dr. Beatriz Di Martino Ortiz beatrizdimartino@gmail.com

Our Dermatol Online. 2012; 3(1): 46-51 Date of submission: 31.10.2011 / acceptance: 05.12.2011
Conflicts of interest: None

Resumen
El tumor de células granulares (TCG) es una neoplasia benigna de diferenciación distintiva a la microscopía de luz caracterizada por la presencia de células con citoplasma eosinofílico abundante y granular. Se presentan tres casos clínicos donde el estudio histológico muestra una lesión tumoral no encapsulada formada por células de gran tamaño de abundante citoplasma ocupado por gránulos eosinofílicos y núcleos de localización central en todos los casos. Se realiza estudio inmunohistoquímico en uno de los casos que señala positividad para S100. Se indica como tratamiento la escisión quirúrgica local conservadora.

Abstract
Granular cell tumors (GCT) are benign neoplasms of distinctive differentiation when observed by light microscopy, which are characterized by the presence of cells with abundant granular eosinophilic cytoplasm. We present three clinical cases were histological study revealed a non-encapsulated tumorous lesion formed by large cells, organized in groupings of abundant cytoplasm containing eosinophilic granules and small, centrally located nuclei. Immunohistochemical study was performed in one case and demonstrated the presence of S100. The indicated treatment was local conservative surgical excision.

Streszczenie
Guzy z komórek ziarnistych (GKZ) są łagodnymi nowotworami wykazującymi charakterystyczne zróżnicowanie gdy obserwowane są w mikroskopie świetlnym, charakteryzują się obecnością komórek z obfitą, ziarnistą, eozynofilową cytoplazmą. Prezentujemy trzy przypadki kliniczne, u których badanie histologiczne wykazało nieotorbione, nowotworowe zmiany z dużych komórek, zorganizowane w grupy obfitej cytoplazmy, zawierające granulki eozynofilowe i małe, położone w centrum jądra. Badanie immunohistochemiczne przeprowadzono w jednym przypadku i wykazało ono obecność S100. Zalecanym leczeniem było zachowawcze chirurgiczne usunięcie zmiany.

Palabras clave: tumor de células granulares; tumor de Abrikossoff; cuerpos pústulo-ovoides de Milian; tumor cutáneo neural
Key words: granular cell tumou;, Abrikossoff tumour; pustulo-ovoid bodies of Milian; cutaneous neural tumor
Słowa klucze: guz z komórek ziarnistych; guz Abrikossoffa; ciałka Miliana; guz skórno-nerwowy

Introducción

El TCG es una neoplasia benigna rara. Atrae gran interés debido a que no existe una contrapartida de célula normal conocida [1]. Fue descrito en 1926 por Abrikossoff, quien nombró a este tumor “mioblastoma de células granulares”, debido a que pensó que derivaba de células musculares (mioblastos en respuesta a trauma o inflamación). Si bien se han sugerido hipótesis diversas sobre su origen (histiocitos que almacenan metabolitos, fibroblastos perineurales, etc.) en el año 1962 Fisher y Wechsler, con la microscopía electrónica, demostraron que este tumor surge de la diferenciación de la célula de

Schwann y es esta hipótesis la aceptada en la actualidad. Su incidencia es variable y si bien para algunos autores es una neoplasia común es rara vez reportado por otros.

Casos Clínicos

Caso 1:

Escolar, masculino, 11 años, con lesión nodular sobre-elevada en la espalda de 6 meses de evolución levemente pruriginosa, no dolorosa, que crece progresivamente. Proviene de medio urbano del Paraguay (zona no endémica para Leishmanias). Sin antecedentes personales o familiares de interés.

Examen físico: lesión nodular sobre-elevada en región escapular derecha, bordes bien definidos, límites netos, levemente eritematosa, con depresión central cubierta por costra queratinosa, de 1.5 cm. de eje mayor (Fig. 1A), móvil, no dolorosa y no adherida a planos profundos. Resto del examen físico normal.

Auxiliares del diagnóstico: IDR de Montenegro e IFI para Leishmanias negativas. HMG con leve anemia. Resto de los parámetros hematológicos normales.

Se realiza extirpación quirúrgica de la lesión en cuña de 3 X 2.5 x 1.5 cm., centrada por una lesión nodular sobre-elevada de 1.5 cm. de diámetro mayor, con buenos márgenes de seguridad, sin complicaciones.

Se remite la pieza de resección quirúrgica a anatomía patológica.

Anatomía Patológica: Formación nodular que asienta en dermis, bien delimitada no encapsulada, de coloración amarilla, sólida, homogénea (Fig. 1B). Histológicamente se trata de una proliferación celular que ocupa la dermis en su totalidad hasta el límite con la hipodermis, bien delimitada no encapsulada, constituida por células de amplios citoplasmas eosinófilos ocupados por gránulos PAS positivos (Fig. 2A), entre los que se observan otros de mayor tamaño (1-10/10HPF) rodeados de halo claro (cuerpos pústulo ovoides de Milian-POBM). Núcleos centralmente dispuestos de pequeña a mediana talla, no atípicos, entre hipercromáticos a vesiculosos. No se observa pleomorfismo nuclear, ni siquiera focal. No se observan figuras de mitosis. La tumoración no infiltra planos profundos. No se observan áreas de necrosis ni afectación anexial. La epidermis muestra hiperplasia epitelial pseudoepiteliomatosa (Fig. 2B).

Estudios inmunohistoquímicos: S100+ (citoplasmática y nuclear), CD68+, HMB45- (Fig. 3).

Diagnóstico final: *tumor cutáneo de células granulares.*

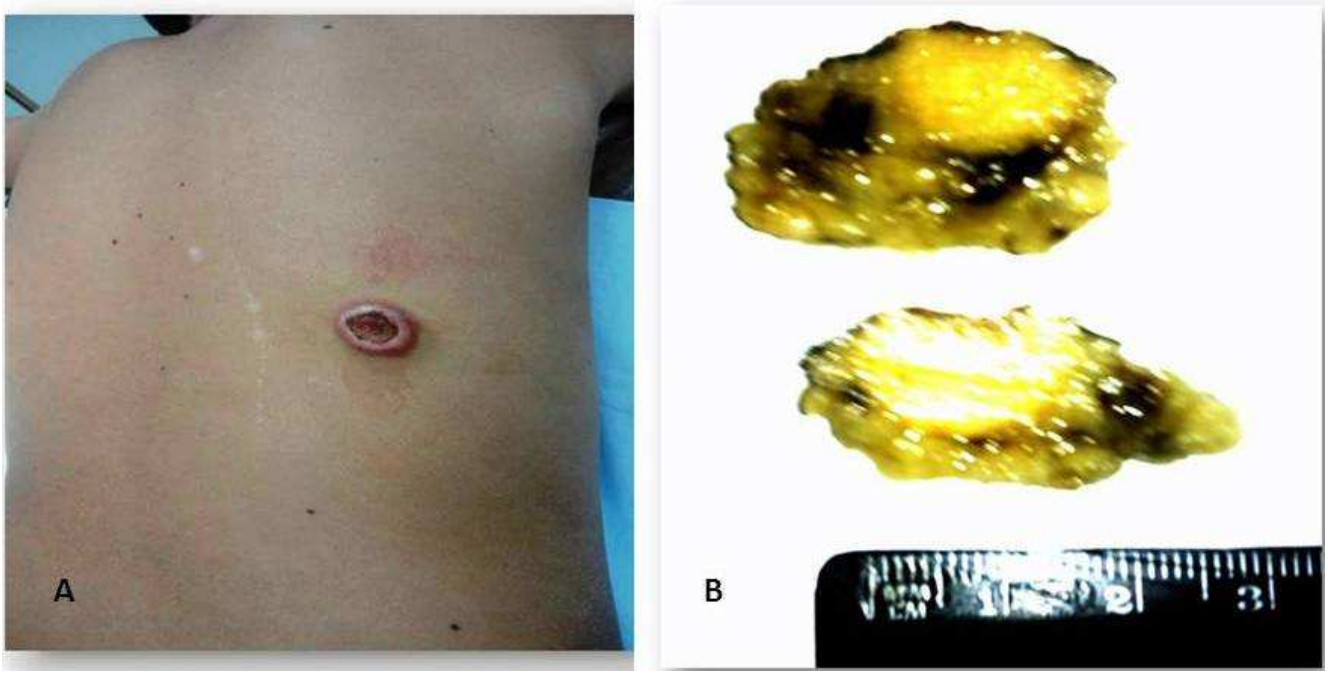

Figura 1. Caso 1. A. Clínica. Lesión nodular sobre-elevada en región escapular derecha, bordes bien definidos, límites netos, levemente eritematosa, con depresión central cubierta por costra queratinosa, de 1.5 cm. de eje mayor. **B. Macroscopía.** Formación nodular que asienta en dermis, bien delimitada no encapsulada, de coloración amarilla, sólida, homogénea, sin áreas de necrosis, hemorragia o degeneración quística

Figure 1. Case 1. A. Clinic. Nodular lesion in the right scapular region, well-defined borders, net limits, slightly erythematous with central depression covered by keratinous crusts, 1.5 cm. major axis. **B. Macroscopy.** showns a well-circumscribed non-encapsulated lesion, sits in dermis, yellow-colored, solid, homogeneous without areas of necrosis, hemorrhage or cystic degeneration

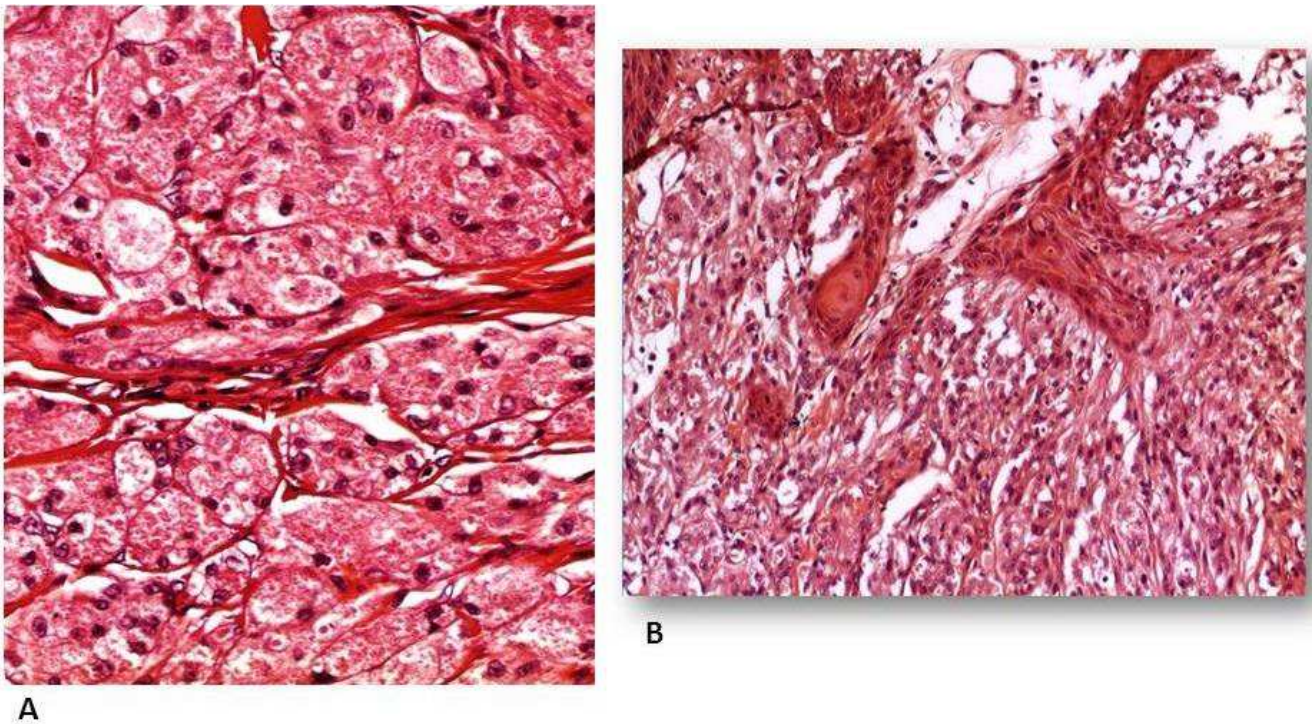

Figura 2. Caso 1. Histopatología. A. Proliferación celular que ocupa la dermis en su totalidad hasta el límite con la hipodermis, bien delimitada no encapsulada, constituida por células de amplios citoplasmas eosinófilos ocupados por pequeños gránulos, entre los que se observan otros de mayor tamaño (al menos 2/CGA) rodeados de halo claro (cuerpos pústulo ovoides de Milian). **B.** Hiperplasia epitelial pseudoepiteliomatosa de la epidermis

Figure 2. Case 1. Histopathology. A. Proliferation in full dermis, well-circumscribed non-encapsulated composed of large eosinophilic cytoplasm filled cells, small granules and larger ones (at least 2/CGA) surrounded by a clear halo (POBM). **B.** Pseudoepitheliomatous epithelial hyperplasia of the epidermis

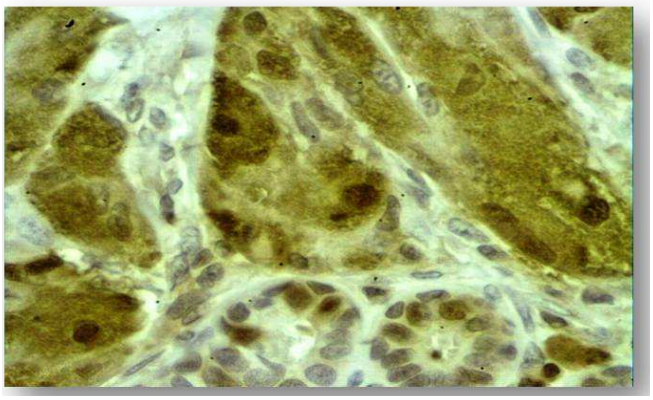

Figura 3. Caso 1. Inmunohistoquímica. Positividad para S100 en células tumorales

Figure 3. Case 1. Immunohistochemical stain. Positivity for S100 in tumor cells

Caso 2:
Mujer, 32 años de edad, con lesión nodular sobre-elevada en cuero cabelludo, asintomática, se desconoce el tiempo de evolución. Proviene de medio rural del Paraguay.

Anatomía Patológica: Se remite resección cutánea en forma de cuña que mide 2.6 x 1.8 x 1 cm. de ejes mayores centrada por una formación nodular sobre-elevada de 1.5 cm. de diámetro. Histopatológicamente se trata de una lesión que asienta en dermis, bien delimitada no encapsulada, constituida por células de amplios citoplasmas eosinófilos (Fig. 4A) ocupados por gránulos PAS positivos (Fig. 4B), con <10/10HPF POBM. Núcleos centralmente dispuestos de pequeña a mediana talla, no atípicos, entre hipercromáticos a vesiculosos. No se observa pleomorfismo nuclear, ni siquiera focal. No se observan figuras de mitosis. La tumoración no infiltra planos profundos. No se observan áreas de necrosis ni afectación anexial. La epidermis muestra hiperplasia epitelial pseudoepiteliomatosa.

Diagnóstico final: *tumor cutáneo de células granulares.*

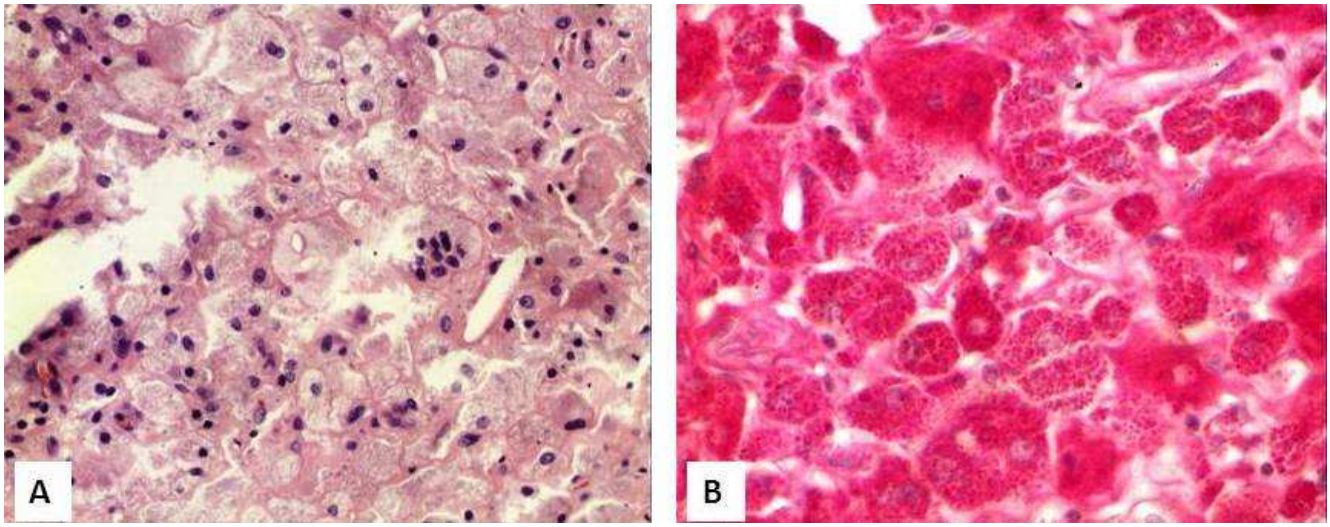

Figura 4. Caso 2. Histopatología. A. Proliferación de células granulares en dermis reticular. **B.** Coloración de PAS + en gránulos intracitoplasmáticos

Figure 4. Case 2. Histopathology. A. Proliferation of granule cells in reticular dermis. **B.** PAS staining of intracytoplasmic granules

Caso 3:
Mujer, 46 años de edad, proveniente del área rural del Paraguay con lesión nodular en región vulvar, labio mayor, que se desconoce el tiempo de evolución.
Anatomía Patológica: Se recibe una resección cutánea con forma de cuña que mide 2.8 x 1.5 x 0.7 cm, de ejes mayores, con una lesión central de 1.3 cm de diámetro, de color blanquecino amarillento. Microscópicamente se observa una lesión dérmica, bien delimitada, pero no encapsulada, constituida por grupos de células dispuestos entre haces gruesos de fibras de colágeno (Fig. 5). Las células muestran citoplasma amplio, eosinófilo con gránulos PAS positivos, con <10/10HPF POBM. Los núcleos son centrales, pequeños, vesiculosos, sin atipias. No se observan figuras mitóticas. La epidermis no muestra hiperplasia epitelial pseudoepiteliomatosa (Fig. 6).
Diagnóstico final: *tumor cutáneo de células granulares*

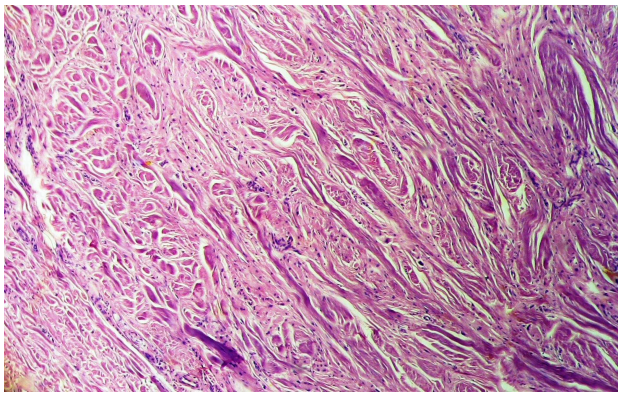

Figura 5. Caso 3. Histopatología. Proliferación de células granulares entre los haces gruesos de colágeno

Figure 5. Case 3. Histopathology. Granule cell proliferation between thick collagen bundles

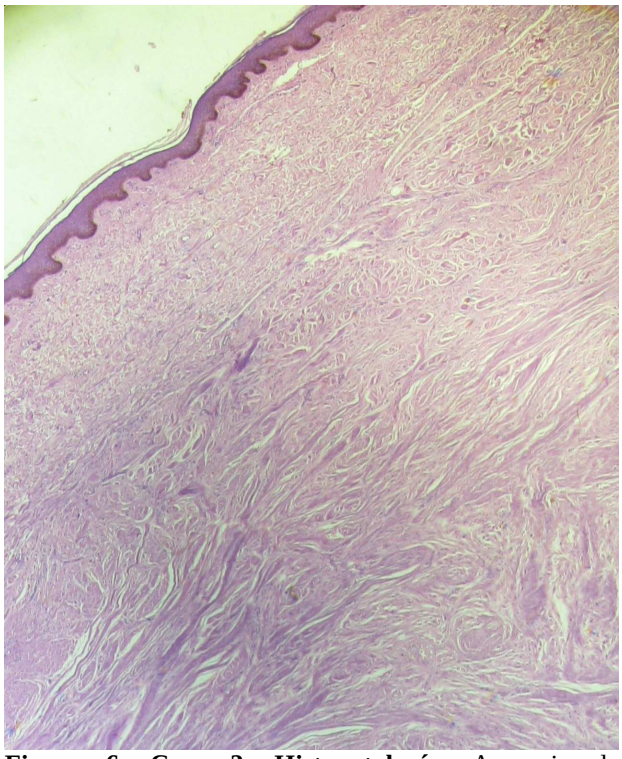

Figura 6. Caso 3. Histopatología. Ausencia de hiperplasia epitelial pseudoepiteliomatosa

Figure 6. Case 3. Histopathology. Absence of epithelial hyperplasia pseudoepitheliomatous

El resumen general de hallazgos clínico-patológicos se muestra en la tabla I.

Caso	Edad (años)	Sexo	Localización	Delimitación	Nivel de afectación	POBM (10/HPF)	PEH	Citología	Mitosis	S100
1	11	V	Espalda	Si	Dermis reticular	1-10	Si	No atipia	No	+
2	32	M	Cuero cabelludo	Si	Dermis reticular	<10	Si	No atipia	No	ND
3	46	M	Vulva	Si	Dermis reticular	<10	No	No atipia	No	ND

Tabla I. Características clínico-patológicas de los pacientes examinados
Table I. Clinical and pathological characteristics of the patients examined
Abreviaturas: V: varón; M: mujer; POBM: cuerpos pústulo ovoides de Milian; HPF: campo microscópico de gran aumento; PEH: hiperplasia epitelial pseudoepiteliomatosa; ND: no determinado.

Conclusiones

El tumor de células granulares (TCG) es una neoplasia benigna rara, comúnmente de la cavidad oral de adultos.

Se han descrito casos en niños y formas congénitas. Los casos familiares son raros.

La edad promedio de presentación, está entre los 20 y 40 años. Los reportes en niños son extremadamente raros (0.017-0.029%) [2,3]. Es más común en mujeres [1-4].

Su naturaleza neoplásica y su origen han sido puestos en duda. Hoy existe certeza de que se trata de una lesión tumoral que se origina en la célula de Schwann. El perfil inmunohistoquímico confirma esta observación ya que son células fuertemente positivas para S100 [5]. Aunque los TCG neurales expresan S100 existe un grupo de TCG no neurales descritos por Philip LeBoit y cols [5,7]. que son S100 negativos y presentan morfología polipoide. Los mismos se designan como *tumores polipoides primitivos o tumores de células granulares no neurales*, que se caracterizan por los siguientes rasgos: estructura polipoide, tienen afectación de dermis superficial, collarete epidérmico, buena delimitación, mínima o ninguna hiperplasia epitelial pseudoepiteliomatosa, atipia citológica y actividad mitótica incrementada y son S100 negativos. Sin embargo estos tumores son benignos y tienen un buen pronóstico.

Tienen predilección por ubicarse en la cavidad oral, especialmente en lengua, y en piel y tejido subcutáneo. Se describen en las paredes anterior y posterior del tórax, miembros superiores, mama y miembros inferiores [4,8,9].

Clínicamente son nódulos solitarios. Se describen forman múltiples (hasta en 25% de casos). Las presentaciones múltiples en la infancia se han descrito en asociación con síndromes polimalformativos, síndrome de Noonan, neurofibromatosis, etc [2]. Las lesiones son móviles, no dolorosas, aunque a veces se presenta un leve prurito [4].

Los nódulos están localizados en dermis o tejido celular subcutáneo, y menos frecuentemente en mucosa, músculo liso o estriado. Las localizaciones viscerales más frecuentes son el aparato respiratorio (laringe, bronquios), tracto digestivo (estómago, ductos biliares), vulva y región anogenital.

Desde el punto de vista anatomopatológico son masas cutáneas o subcutáneas nodulares no encapsuladas, con engrosamiento verrugoso de la superficie epidérmica y de corte amarillento y que microscópicamente presentan nidos, cordones o fascículos, de células con citoplasma finamente granular PAS+, núcleos redondos, pequeños, hipercromáticos a vesiculosos. Recientemente se han descrito los *cuerpos pústulo ovoides de Milian* (POBM) [10] que son gránulos intracitoplasmáticos eosinófilos más grandes (de 4-5µm), redondeados, rodeados de un halo claro pero su significado y frecuencia en este tumor están poco claros. Se cree que su número se incrementa con la edad de la lesión. Existen pocos estudios histológicos que documenten su frecuencia en los TCG [10].

En este estudio medimos la frecuencia de POBM dentro del tumor basándonos en las observaciones de Epstein y cols [10], contándolos en 10 campos microscópicos de gran aumento (10HPF) y dividiéndolos en las siguientes categorías: <10, entre 10-30, entre 30-50 y >50. Los mismos están presentes en el 100% de los TCG y su frecuencia es en alto porcentaje de casos es >10/10HPF. Representan la heterogeneidad de los lisosomas dando la apariencia de gránulos grandes que se desprenden del citoplasma y son fácilmente reconocibles como componentes del TCG.

La epidermis que tapiza estos tumores muestra hiperplasia epitelial pseudoepiteliomatosa (PEH) de manera muy frecuente y puede ser tan extensa que simula una verruga o un CEC bien diferenciado, sobre todo cuando la resección ha sido superficial e insuficiente [4]. Se describe afectación de la unión dermo-epidérmica lo que puede simular una neoplasia melanocítica. La inmunomarcación juega aquí un rol muy importante, ya que tanto el melanoma como el TCG serán S100+, pero el TCG es negativo para HMB45 [11].

En cuanto al inmunofenotipo los TCG neurales expresan marcadores neurales (proteína S100, ENS, laminina, calretinina, inhibina, CD57, etc.) e histiocíticos (CD68, α-1-AT). Las células tumorales son positivas para vimentina y negativas para GFAP, marcadores epiteliales así como para RE y RP. La positividad para CD68 es atribuida a la acumulación citoplasmática de lisosomas y no refeleja naturaleza histiocítica de la proliferación. El Ki-67 es positivo en el 10% de estos tumores y su positividad es un factor pronóstico predictivo individual de curso desfavorable [5].

La recurrencia local es común por resección incompleta.

Las variantes malignas son raras (1-2%), agresivas y suelen tener numerosas recidivas locales antes de la propagación a distancia. Su pronóstico es pobre, con metástasis en 2 años (promedio entre 3-37 meses) y 60% de mortalidad en 3 años. Las metástasis afectan a

ganglios, hígado, pulmón y hueso. No se han descrito variantes malignas en niños.
Por la posibilidad de recurrencia y la superposición morfológica entre formas benignas y malignas, se recomienda la extirpación completa.
Los tumores con un tamaño tumoral >4 cm., infiltración en estructuras vecinas, localización en planos profundos, velocidad de crecimiento elevada, rápida recurrencia, necrosis, mitosis >5/10 CGA, núcleo vesicular con nucléolo prominente, pleomorfismo marcado, y tendencia a formas fusiformes, deben ser denominados *tumores con probable potencial maligno*, ya que el diagnóstico de certeza de malignidad solo se realiza cuando aparecen lesiones a distancia con igual histología al tumor primario (metástasis). Las lesiones con estas características atípicas necesitan estudio por imagen (TAC y/o RMN) para detectar metástasis ocultas [8]. La invasión vascular no se ha descrito como un hallazgo histopatológico en formas potencialmente malignas o malignas, de hecho, su hallazgo puede ser demostrado como un fenómeno común en formas benignas [13].
El diagnóstico diferencial debe realizarse con xantomas, la variante granular del carcinoma de células renales metastásico, hibernoma, neoplasias sebáceas, hidradenoma de células claras, siringoma de células claras, fibroxantoma atípico y melanoma maligno de células balónicas.
Los cambios granulares en las células no son enteramente específicos del TCG ya que pueden ser vistos como cambios degenerativos en otros tumores (CBC, fibroxantoma atípico, dermatofibroma, nevus melanocítico, rabdomioma, etc.) pero estos hallazgos afectarán solo a parte del tumor. Los cambios reactivos asociados a heridas quirúrgicas también pueden simular un TCG. El épulis de células granulares congénito, tumor del reborde alveolar que recuerda histomorfológicamente a un tumor de células granulares del adulto, se caracteriza por su negatividad frente a S100 [14].
En conclusión, presentamos tres casos de TCG, de diferentes características clínico-epidemiológicas y similares rasgos histomorfológicos. Si bien siempre se ha considerado un tumor de histogénesis controversial e incierta, los estudios IHQ y de ME muestran que la célula de Schwann es la que da origen a los tumores en piel. Es un tumor de difícil diagnóstico clínico y casi nunca se piensa en él, salvo que se sitúe en la lengua.

BIBLIOGRAFÍA

1. Oliver M, Pichardo R, Angulo J, Chopite M: Tumor de células granulares: a propósito de un caso y revisión de la literatura. Dermatología venezolana 1996; 34: 139-143.
2. Marice El Achkar, Susana Giraldi, Leide Marinoni, Kerstin Abagge, José Fillus Neto, Betina Werner: Tumor de células granulares: caso en la niñez. Dermatol Pediatr Lat 2005; 3: 230-233.
3. Apisarnthanarax P: Granular cell tumor. An analysis of 16 cases and review of the literature. J Am Acad Dermatol. 1981; 5: 171-182.
4. Torrijos-Aguilar A, Alegre-de Miquel V, Pitarch-Bort G, Mercader-García P, Fortea-Baixauli JM: Cutaneous Granular Cell Tumor: A Clinical and Pathologic Analysis of 34 Cases. Actas Dermosifiliogr. 2009; 100: 126-132.
5. Suciu C, Cimpean AM, Raica M: Neural granular cell tumor. A case report. Romanian Journal of Morphology and Embryology 2008; 49: 111–114.
6. LeBoit PE, Barr RJ, Burrall S, Metcalf JS, Yen TS, Wick MR: Primitive polypoid granular cell tumour and other cutaneous granular cell neoplasms of apparent nonneural origin. Am J Surg Pathol, 1991; 15: 48–58.
7. Chaundry IH, Calonje E: Dermal non-neural granular cell tumour (so-called primitive polypoid granular cell tumour): a distinctive entity further delineated in a clinicopathological study of 11 cases. Histopathology 2005; 47: 179–185.
8. Budiño Carbonero S, Navarro Vergara P, Rodríguez Ruiz JA, Modelo Sánchez A, Torres Garzón L, Rendón Infante JI, et al: Tumor de células granulosas: Revisión de los parámetros que determinan su posible malignidad. Med Oral 2003; 8: 294-298.
9. Eguia A, Uribarri A, Escoda CG, Crovetto MA, Martínez-Conde R, Aguirre JM: Tumor de células granulares: Presentación de 8 casos con localización intraoral. Med Oral Patol Oral Cir Bucal 2006; 11: 425-458.
10.Epstein DS, Pashaei S, Hunt E Jr, Fitzpatrick JE, Golitz LE: Pustulo-ovoid bodies of Milian in granular cell tumors. J Cutan Pathol. 2007; 34: 405-409.
11. Ray S, Jukic DM: Cutaneous granular cell tumor with epidermal involvement. A potencial mimic of melanocytic neoplasia. J Cutan Pathol. 2007; 34: 188-194.
12. Lahmam Bennani Z, Boussofara L, Saidi W, Bayou F, Ghariani N, Belajouza C, et al: Childhood cutaneous Abrikossoff tumor. Arch Pediatr 2011; 18: 778-782.
13. Cserni G, Bori R, Sejben I: Vascular invasion demonstrated by elastic stain—a common phenomenon in benign granular cell tumors. Virchows Arch 2009; 454: 211-215.
14. Vered M, Dobriyan A, Buchner A: Congenital granular cell epulis presents an immunohistochemical profile that distinguishes it from the granular cell tumor of the adult. Virchows Arch 2009; 454: 303-310.

Copyright *Beatriz Di Martino Ortiz, et al.* This is an open access article distributed under the terms of the Creative Commons Attribution License, which permits unrestricted use, distribution, and reproduction in any medium, provided the original author and source are credited.

NASZA DERMATOLOGIA Online
OUR DERMATOLOGY Online

SEBORRHEIC DERMATITIS EYE LID INVOLVEMENT (SEBORRHEIC BLEPHARITIS) IN CHILDREN NOT A RARE CLINICAL OBSERVATION

ŁOJOTOKOWE ZAPALENIE SKÓRY POWIEK (SEBORRHEIC BLEPHARITIS), NIE RZADKIE OBSERWACJE U DZIECI

Anca Chiriac[1], Anca E. Chiriac[2], Alina Murgu[3], Liliana Foia[4]

[1]*CMI Dermatology, Iasi-Romania*
[2]*Univ. of Medicine Gr T Popa Iasi-Romania*
[3]*Univ. Hospital of Pediatrics Sf Maria, Iasi, Romania*
[4]*Univ. of Medicine Gr T Popa, Biochemistry Department, Iasi-Romania*

***Corresponding author**:* Anca Chiriac, MD, PhD *ancachiriac@yahoo.com*

Our Dermatol Online. 2012; 3(1): 52-53 Date of submission: 01.11.2011 / acceptance: 21.11.2011
Conflicts of interest: None

Abstract
We present a typical case of seborrheic dermatitis, with no cutaneous manifestations, rarely reported in children, frequently misdiagnosed (especially by ophthalmologists), simply confirmed by microscopic examination of scales and with wonderful therapeutic results with antifungal agents (topical and/or systemic treatments).

Streszczenie
Prezentujemy typowy przypadek łojotokowego zapalenia skóry, bez skórnej manifestacji zmian, rzadko opisywany u dzieci, często błędnie diagnozowany (zwłaszcza przez okulistów), łatwo potwierdzony przez badanie mikroskopowe i dający wspaniałe wyniki leczenia po zastosowaniu leków przeciwgrzybiczych (miejscowych i / lub systemowych).

Key words: seborrheic dermatitis; Malasezia spp; Ketoconazole
Słowa klucze: seborrheic dermatitis; Malasezia spp; Ketoconazol

Introduction

Seborrheic dermatitis is a chronic inflammatory disease that mainly affects seborrheic areas of skin. An inflammatory response to the yeast *Pityrosporum ovale* has been thought to be important in the etiology of the condition. Not very rare, especially in children, there is a seborrheic blepharitis, often misdiagnosed. We present a case of a child with typical eye lid involvment of seborrheic dermatitis without skin manifestations.

Case Report

A 5-year-old boy, with no significant past medical history, presented with a 1-year history of mild erythema, scaling and pruritus on the eye lid, without any other manifestations on the skin and ocular area. He was in very good health state, with no medication and without an allergy history.
He has received many different medications so far: antibiotics (Oxacillin, Metronidazole), antihytamins, topical corticosteroids, with no improvment.
We diagnosed him with seborrheic blepharitis, he received Ketoconazole orally 10 days and topical imidazole, with complete disapearance of the lesions.
The diagnosis was confirmed with microscopic examination of scales soaked in 10%-15% potassium hydroxide (KOH): characteristic thick-walled spherical or oval yeast forms and coarse septate mycelium, often broken up into short filaments.

 © Our Dermatol Online 1.2012

Figure 1. Discrete scaling on the eyelid margin

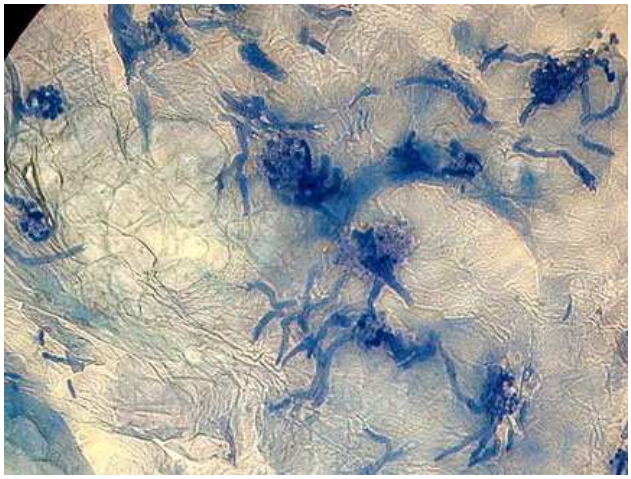

Figure 3. Clear adhesive tape were pressed to collect hyphae and spores. The tape was then lightly pressed onto a glass slide, and a drop of methylene blue was placed at the edge of the tape. The spores and hyphae easily are seen against a background clustter of keratinocytes and glue

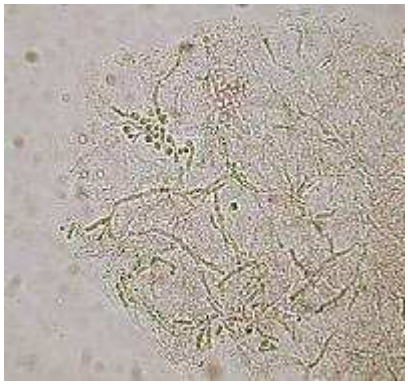

Figure 2. Combination of mycelium strands and numerous spores is commonly referred to as "spaghetti and meatballs"

Discussion

Blepharitis is a chronic inflammatory process of the eyelid margin. It is a common eye disorder throughout the world and can affect any age group.

Common symptoms associated with blepharitis are burning sensation, irritation, tearing, photophobia, blurred vision and red eyes. Seborrheic blepharitis is rarely reported, especially in children, although we believe it is misdiagnosed.

Although the pathophysiology of seborrheic blepharitis is not completely understood, correlation of flares with proliferation of *Malassezia species* ***(****spp****)*** and clinical response to antifungal agents (i.e., ketoconazole, ciclopirox) have led many researchers and clinicians to believe that Malassezia spp play a role in its pathogenesis.

The frequency of bathing, use of skin care products, lubricants and use of any occlusive agents have all been associated with colonization of infantile skin with *Malassezia spp****.***

We describe a very subtle clinical aspect of seborrheic blepharitis, with a great impact on normal life of a child, despite its minimal manifestations, with very simple treatment and an overlooked diagnosis.

REFERENCES

1. Folia Zisova LG: Folia Medica Treatment of malassezia species associated seborrheic blepharitis with fluconazole (Plovdiv). 2009; 51: 57-9.
2. Bernardes TF, Bonfioli AA: Blepharitis, Seminars in Ophthalmology. 2010; 25: 79-83.
3. Bruce Sylvester: Ketoconazole 2% foam effective and safe for Seborrheic Dermatitis: Presented at AAD meeting 2009.

Copyright *Anca Chiriac et al.* This is an open access article distributed under the terms of the Creative Commons Attribution License, which permits unrestricted use, distribution, and reproduction in any medium, provided the original author and source are credited.

SEBORRHEIC DERMATITIS EYE LID INVOLVEMENT (SEBORRHEIC BLEPHARITIS) IN CHILDREN NOT A RARE CLINICAL OBSERVATION

Anca Chiriac, Anca E. Chiriac, Alina Murgu, Liliana Foia

Dr. Shahbaz Janjua

Our Dermatol Online. 2012; 3(1): 54

Date of submission: 02.12.2011 / acceptance: 06.12.2011
Conflicts of interest: None

Seborrheic blepharitis is a chronic inflammation of the lid margins which may compromise the eyelid function up to some extent. It results from immunologic factors and is commonly associated with scalp seborrheic dermatitis, facial seborrheic dermatitis, and acne rosacea. A yellowish greasy crust with morning exacerbations associated with stinging and burning are the usual clinical features. The symptoms can be controlled with good lid hygiene. The above article about seborrheic dermatitis in pediatric age group is quite comprehensive and nicely written..

Ayza Skin & Research Center, Pakistan

Correspondence:
E-mail: shahbaz.janjua@telederm.org

Copyright *Shahbaz Janjua*. This is an open access article distributed under the terms of the Creative Commons Attribution License, which permits unrestricted use, distribution, and reproduction in any medium, provided the original author and source are credited.

NASZA DERMATOLOGIA Online
OUR DERMATOLOGY Online

GILBERT OMENN AND HIS SYNDROME

GILBERT OMENN I OPISANY PRZEZ NIEGO ZESPÓŁ CHOROBOWY

Ahmad Al Aboud[1] Khalid Al Aboud[2]

[1]*Dermatology Department, King Abdullah Medical City, Makkah, Saudi Arabia*
[2]*Dermatology Department, King Faisal Hospital, Makkah, Saudi Arabia*

***Corresponding author**:* Dr. Khalid Al Aboud amoa65@hotmail.com

Our Dermatol Online. 2012; 3(1): 55-56 Date of submission: 22.10.2011 / acceptance: 18.11.2011
Conflicts of interest: None

Abstract
Gilbert Omenn is a well-known American Geneticist. In the 1965, He reported a rare genetic disorder —later known as Omenn syndrome. This syndrome is a variant of severe combined immunodeficiency which is associated with hypereosinophilia. It is one of the differential diagnoses of neonatal erythroderma.
This concise report sheds light on Gilbert Omenn and the syndrome that bears his name.

Streszczenie
Gilbert Omenn jest znanym amerykańskim genetykiem. W 1965 r. opisał rzadką genetyczną chorobę, znaną później jako zespół Omenna. Ten zespół jest wariantem ciężkiego, złożonego niedoboru odporności, związanego z eozynofilią. Jest jednym z rozpoznań różnicowych noworodków erytrodermii.
Ten zwięzły raport rzuca światło na Gilberta Omenna i zespół chorobowy, który nosi jego imię

Key words: dermatology; erythroderma; Omenn syndrome
Słowa klucze: dermatologia; erytrodermia; zespół Omenna

Introduction

Gilbert Omenn (Fig. 1) is currently, a Director of Center for Computational Medicine and Bioinformatics and Professor of Internal Medicine, Human Genetics, & Public Health, at University of Michigan, Ann Arbor, MI, USA [1].
He is a world-renowned geneticist. Among his great medical contributions, he is credited for describing a reticuloendotheliosis with eosinophilia in several individuals in related sibships from an inbred American family of Irish extraction [2], later known as Omenn syndrome (OS) [3-6].

Omenn syndrome

OS (OMIM #603554) is a rare autosomal recessive genetic disorder and presents symptoms of severe combined immunodeficiency (SCID). It is characterized by erythrodermia, eosinophilia, hepatosplenomegaly, lymphadenopathy, alopecia and elevated serum IgE levels.
Similar to other patients with SCID, patients with OS present early in infancy with viral or fungal pneumonitis, chronic diarrhea, and failure to thrive. Unlike typical SCID, patients with OS have enlarged lymphoid tissue, severe erythroderma, increased IgE levels, and eosinophilia [5].

Figure 1. Gilbert Omenn

OS is also known as Reticuloendotheliosis, familial with eosinophilia, and also known as severe combined immunodeficiency with hypereosinophilia [3].
The syndrome is reported from different places in the world but large series of patients were reported from Middle East.
Some authors [6] performed literature search, for Omenn syndrome, using Medline, encompassing the period 1965-1999. They collected 68 cases and they founded that median age at onset of symptoms, in this disorder, was 4 weeks. Key symptoms were erythematous rash (98%), hepatosplenomegaly (88%), and lymphadenopathy (80%), often accompanied by recurrent infections (72%) and alopecia (57%). An elevated WBC (55%) was frequently observed, due to eosinophilia and/or lymphocytosis. B-cell counts were significantly decreased whereas T-cell counts were elevated. A high serum IgE was another frequent finding (91%). Therapeutic options, which were used in the reviewed patients, include bone marrow transplantation or cord blood stem cell transplantation; however, the mortality was 46%. The authors concluded that, Omenn syndrome is a fatal disease if untreated. They believed that, the mortality may be reduced when diagnosis is established early and treatment is initiated rapidly by using early compatible bone marrow transplantation or cord blood stem cell transplantation [6].
The syndrome can be caused by mutation in the recombination activating genes (RAG1 and RAG2) genes on chromosome 11p and the Artemis gene (DCLRE1C) on chromosome 10p [3].
In this disorder, there is a peculiar severe T-cell immune deficiency associated with autoimmunelike manifestations. Dysregulations of the central and peripheral immune tolerance, mediated by the protein autoimmune regulator (AIRE) and regulatory T cells, respectively, were proposed as possible mechanisms of this aberrant inflammatory process.
Erythroderma is one of the main features of this syndrome. The rash may be present at birth or evolve over the first few weeks of life. There is also lymphadenopathy, particularly of the axillary and inguinal nodes, as well as increased serum IgE levels with a marked eosinophilia and combined immunodeficiency [4]. Children usually present in early infancy but atypical forms may present later in the first year of life. Children usually suffer diarrhea, failure to thrive and persistent infection, as seen in other forms of SCID [4].

The clinical picture may resemble SCID with maternofetal engraftment, when maternal T lymphocytes crossing the placenta cause a graft-versus-host disease-like reaction in an immunoincompetent patient [4].
Histology of the skin shows a dense, dermal perivascular lymphohistiocytic infiltrate, comprising activated T lymphocytes, with numerous eosinophils. S100-staining Langerhans' cells are usually absent, and there is no epidermotropism.
In the older literature this condition has been confused with Langerhans' cell histiocytosis (Letterer–Siwe disease) [4].
It is proved that both HLA-identical and haploidentical allogenic bone marrow transplant (BMT) can cure Omenn syndrome, provided that parenteral nutrition and immunosuppressive therapy are given before transplantation [3].

Gilbert Omenn

Gilbert Omenn was born 30-Aug-1941, in Chester, PA, USA. He received his education and served in several institutes in USA. He describes Omenn syndrome while he was a medical student in Harvard.
Gilbert Omenn published more than 400 papers and he authored and edited more than 15 books. He holds various scientific assignments inside and outside USA. He is active in many cultural and educational organizations. He has won several honors and awards.
This short report can not encompass his impressive career which can be read online in many internet websites [1]. Music and Tennis is among Dr Omenn extra scientific interests.
His research interests include clinical informatics, databases and computing, medical and translational research, and proteomics [1].
Dr. Omenn's research focuses on cancer proteomics and informatics. He leads the Proteomics Alliance for Cancer Research, the HUPO Plasma Proteome Project, the Driving Biological Problems Core of the National Center for Integrative Biomedical Informatics, and the Center for Computational Medicine and Bioinformatics [1].
He has long-standing interests in mechanisms of genetic predispositions to risks from environmental and occupational exposures, pharmacogenetics and pharmacogenomics, and science-based risk analyses [1]. He was, also, the principal investigator for many years of the Beta-Carotene and Retinol Efficacy Trial (CARET) for chemoprevention of lung cancers and heart disease.

REFERENCES

1. Gilbert S. Omenn: [A page on the Internet]. From; University of Michigan. Available at: http://www.ccmb.med.umich.edu/omenn
2. Omenn GS: Familial reticuloendotheliosis with eosinophilia. New Eng. J. Med 1965; 273: 427-432.
3. Omenn syndrome. [A page on the Internet].From OMIM, Online Mendelian Inheritance in Man. Copyright (c) 1966-2011 Johns Hopkins University. Available at: http://omim.org/entry/603554
4. Paige DG, Gennery AR, Cant AJ : The neonate. In: Burns T, Breathnach S, Cox S, Griffiths C, eds. Rook’s Textbook of Dermatology. Vol 1. 8th ed. Oxford, UK: Wiley-Blackwell; 2010: 17 : 8–9.
5. Villa A, Notarangelo LD, Roifman CM : Omenn syndrome: inflammation in leaky severe combined immunodeficiency. J Allergy Clin Immunol. 2008 ;122: 1082-1086.
6. Aleman K, Noordzij JG, de Groot R, van Dongen JJ, Hartwig NG : Reviewing Omenn syndrome. Eur J Pediatr. 2001; 160: 718-725.

Copyright *Ahmad Al Aboud, et al.* This is an open access article distributed under the terms of the Creative Commons Attribution License, which permits unrestricted use, distribution, and reproduction in any medium, provided the original author and source are credited.

NASZA DERMATOLOGIA Online
OUR DERMATOLOGY Online

DORSAL UNGUAL PTERYGIUM

DORSAL UNGUAL PTERYGIUM

Patricia Chang

Dermatologist Hospital General de Enfermedades IGSS y Hospital Ángeles Guatemala pchang2622@gmail.com

Our Dermatol Online. 2012; 3(1): 57-60 Date of submission: 20.02.2011 / acceptance: 22.04.2011
Conflicts of interest: None

Pterygium unguis also known as Dorsal pterygium [1] forms as a result of scarring between the proximal nail fold and matrix, with the classic example being lichen planus, though it has been reported to occur as a result of sarcoidosis and Hansen's disease [2]. Is a wing-shapes scar and always irreversible, consist of a gradual extension of the proximal nail fold over the nail plate which becomes fissurated because of the fusion of the proximal nail fold epidermis to the nail bed, its split portions progressively decrease in size as the pterygium widens, leaving two small nail remmants if the pterygium is central but when the involvement of the matrix and nail bed is complete produces onychatrophy. The causes of dorsal pterygium are: congenital, bullous dermatosis (cicatricial pempghigoid, Stevens Johnson syndrome), burns, dyskeratosis congenital, graf-versus host disease, lichen planus, onychotillomany, radiodermitis, Raynaud´s disease and peripheral vascular disease. Lichen planus is the most common cause of dorsal pterygium [3]. Can affect finger and toenails, the most common affected are the big toenails.

Figure 1. Dorsal ungual pterygium

Figure 2. Dorsal ungual pterygium

Figure 3-8. Dorsal ungual pterygium

Figure 9-11. Dorsal ungual pterygium

Figure 12,13. Dorsal ungual pterygium

REFERENCES

1. Freedberg: Fitzpatrick's Dermatology in General Medicine. (6th ed.), McGraw-Hill 2003.
2. James, William, Berger, Timothy, Elston, Dirk: Andrews' Diseases of the Skin: Clinical Dermatology. (10th ed.). Saunders 2005.
3. Baran R, Dawber RPR, Tosti A, Haneke E: A text Atlas of nail disorders Martin Dunitz London 2001:84-87.

Copyright *Patricia Chang.* This is an open access article distributed under the terms of the Creative Commons Attribution License, which permits unrestricted use, distribution, and reproduction in any medium, provided the original author and source are credited.

NASZA DERMATOLOGIA Online
OUR DERMATOLOGY Online

ASSESSMENT OF PSYCHIATRIC DISORDERS IN VITILIGO. CONSIDERATIONS FOR OUR DAILY PRACTICE

OCENA ZABURZEŃ PSYCHICZNYCH W BIELACTWIE. POSTĘPOWANIE W NASZEJ CODZIENNEJ PRAKTYCE

Marina Rodríguez-Martín[1], Desiré Díaz Melián[2], Miguel Sáez Rodríguez[1], Antonio Noda Cabrera[1], Marta García Bustínduy[1]

[1]*Dermatology Department, University Hospital of Canary Islands, University of La Laguna 38320, La Laguna, Santa Cruz de Tenerife, Spain*
[2]*Psychiatry Department, University Hospital of Canary Islands, University of La Laguna 38320, La Laguna, Santa Cruz de Tenerife, Spain*

***Corresponding author**:* Marina Rodríguez-Martín MD, PhD marinarm@gmail.com

Our Dermatol Online. 2012; 3(1): 61-62 Date of submission: 09.11.2011 / acceptance: 24.11.2011
Conflicts of interest: None

Sir,

Vitiligo is a frequent disorder of unknown aetiology, affecting 1-2% of the general population, regardless of age, sex or ethnicity [1]. Clinical dermatologists are used to the influence of psychological factors in the onset or exacerbation of several cutaneous condition. Furthermore, secondary psychiatric disorders could be caused by disfiguring conditions like vitiligo. In this study we assessed psychiatric morbidity in vitiligo patients and its relation with clinical and demographic characteristics.

It was a cohort study bearing on 180 outpatients with vitiligo examined in the Department of Dermatology of the University Hospital of Canary Islands. Patients completed a questionaire that included personal and demographic data. A complete medical history including psychiatric conditions was also recorded for each patient. We did not conduct any standarized psychiatric evaluation, but we recorded previous psychatric diagnoses already stablished by Psychiatrist or Physiscian using DSM-IV. Affected body surface area (BSA) was calculated by considering the surface of palm as 1%. Parametric variables were analysed using student´s t-test. SPSS 15.0 statistical package was used.

One hundred and eighty consecutive patients (100 women, 80 men) with a mean age of 36,18±18 years (Range: 3-74) were included in the study. A clinic prevalence of 48,33% of psychiatric morbidity was found among vitiligo patients. The most common diagnosis was chronic insomnia (33,33%) and anxiety disorder (21,66%). Depression was present in 11,11% of the sample. Other psychiatric diagnoses presented in the sample are reffered in Table I. Regarding to sex, psychiatric morbidities were more frequent in women than men (53% vs 41.25%, p=0.13). Prevalences of mental disorders in our sample regarding to gender are recorded in Table II.

Diagnoses	Frequency (%)
General Psychiatric morbidity	48,33
Drug abuse	0,55
Anxiety disorder	21,66
Bullimia	1,11
Depression	11,11
Insomnia	33,33
Obsesive-Compulsive disorder	0,55
Trichotillomania	0,55

Table I. Prevalence of psychiatric conditions in the sample

Both anxiety and depression were more prevalent in patients ranging from 31-50 years-old. Nor Insomnia, depression or anxiety could be correlated to the age of vitiligo onset or severity of the disease (measured by BSA). Psychiatric drugs intake was present in 47,8% of the sample. 28,3% reported ansiolitic drug intake and 20.11% medication for insomnia. Psychiatric drugs

intake was more prevalent among women than men ($p<0.05$). Sedatives intake was correlated to severity of the disease, measured by BSA (ρ-correlation factor=0.18, p=0.017).

Diagnoses	Female prevalence (%)	Male prevalence (%)
General Psychiatric morbidity	53	41,25
Drug abuse	0	1,25
Anxiety disorder	38	18,75
Bullimia	2	0
Depression	16	5
Insomnia	40	25
Trichotillomania	0	1,25
Behaviour disorder	0	1,25
Suicidal ideation	1	1,25

Table II. Psychiatric diagnosis in the sample regarding to gender

Given the common ectodermal origins of the skin and nervous system, it has been suggested that some dermatologic and psychiatric conditions could share a common basis [1,2]. Our rate of psychiatric conditions was higher than the mean prevalence reported in other european vitiligo samples [2,4]. The profile of diagnosis obtained in our sample was comparable to other studies, with a predominance of anxiety and depression [2-5]. However, Sleeping disorders (Chronic insomnia) showed in our sample the highest rate (33.3%). Other studies have also found that sleeping disturbances are the most frequent diagnosis, but in a lower rate (20%) [5]. No significant correlation was found between severity of the disease and psichiatric morbidity in our sample. Similar results have been observed in other european studies [2].

The high frequency of psychiatric comorbidity observed in our patients highlights the need of a global approach in this condition. Not only cutaneous therapies and follow-up, but also specific measures of psycholgical variables and investigation of psychiatric morbidity (mainly sleeping disorders, anxiety and depression) should be included in our daily practice with vitiligo patients.

REFERENCES

1. Mattoo SK, Handa S, Kaur I, Gupta N, Malhotra R: Psychiatric morbidity in vitiligo: prevalence and correlates in India. J Eur Acad Dermatol 2002; 16: 573-578.
2. Picardi A, Abeni D, Melchi CF, Puddu P, Pasquini D: Psychiatric morbidity in dermatological outpatients: an issue to be recognized. Br J Dermatol 2000; 143: 983-991.
3. Kent G, AlÁbadie M: Psychologic effects of vitiligo: a critical incident analysis. J Am Acad Dermatol 1996; 35: 895-898.
4. Hughes JE, Barra Clough BM, Hamblin LG, White JE: Psychiatric symptoms in Dermatology patients. Int J Psychiatry 1983; 14: 51-54.
5. Sharma N, Koranne RV, Singh RK: Psychiatric morbidity in psoriasis and vitiligo: a comparative study. J Dermatol 2001; 28: 419-423.

Copyright *Marina Rodríguez-Martín et al.* This is an open access article distributed under the terms of the Creative Commons Attribution License, which permits unrestricted use, distribution, and reproduction in any medium, provided the original author and source are credited.

ASSESSMENT OF PSYCHIATRIC DISORDERS IN VITILIGO. CONSIDERATIONS FOR OUR DAILY PRACTICE

Marina Rodríguez-Martín, Desiré Díaz Melián, Miguel Sáez Rodríguez, Antonio Noda Cabrera, Marta García Bustínduy

Dr. Hari Kishan Kumar Yadalla, MD(DVL)

Our Dermatol Online. 2012; 3(1): 63 Date of submission: 22.12.2011 / acceptance: 23.12.2011
Conflicts of interest: None

Sir,

Firstly, I would like to congratulate the authors for an excellent work-up and compilation of the data in patients affected with vitiligo and their psychiatric co-morbidity. Skin is the most visible organ which determines to a great extent our appearance and plays a major function in social communication and sexual attractiveness. Thus, the skin condition may have a considerable impact on the patient's well being. The relationship between psychological factors and dermatological diseases has long been noticed e.g. stress can precipitate or exacerbate a skin disease through psychosomatic mechanisms.

Significant psychiatric and psychological morbidity is present in at least 30% of dermatological patients. Diseases involved in such context include acne, psoriasis, vitiligo, atopic dermatitis, urticaria and angioedema. Regardless of psychiatric morbidity, skin diseases can greatly affect patient's quality of life (QOL). Thus, patient oriented QOL measures are also particularly beneficial in chronic diseases as they assess how the diseases affect a person socially, psychologically and physically.

Patients with vitiligo treated at dermatology clinics should be assessed in terms of psychiatric disorders and psychiatric interventions may become necessary in the course of illness, underlining the multidisciplinary therapeutic approach including the psychotherapeutic approach.

Asst. Prof in Dermatology
MVJ Medical College & Research Hospital
Consultant Dermatologist & Cosmetologist
`Skin Care Clinic`, RR Nagar, Bangalore, India

Correspondence:
E-mail: drkishanyadalla@indiatimes.com

Copyright *Hari Kishan Kumar Yadalla.* This is an open access article distributed under the terms of the Creative Commons Attribution License, which permits unrestricted use, distribution, and reproduction in any medium, provided the original author and source are credited.

NASZA DERMATOLOGIA Online
OUR DERMATOLOGY Online

SEPARATING "BART'S" APART IN DERMATOLOGY EPONYMS

NIEZALEŻNE WYSTĘPOWANIE „BART'S" W EPONIMACH DERMATOLOGICZNYCH

Ahmad Al Aboud[1], Khalid Al Aboud[2]

[1]*Dermatology Department, King Abdullah Medical City, Makkah, Saudi Arabia*
[2]*Dermatology Department, King Faisal Hospital, Makkah, Saudi Arabia*

***Corresponding author**:* Dr. Khalid Al Aboud amoa65@hotmail.com

Our Dermatol Online. 2012; 3(1): 64-65 Date of submission: 04.11.2011 / acceptance: 21.11.2011
Conflicts of interest: None

There are 2 famous diseases in dermatology with the name "Bart", as a part of their eponyms.
These are Bart syndrome and Bart-Pumphrey syndrome. This short letter is to give a brief account on these eponyms.

Bart syndrome

Bart syndrome, cited in the Online Mendelian Inheritance in Man [1], as Epidermolysis bullosa with congenital localized absence of skin and deformity of nails also as Epidermolysis bullosa dystrophica, Bart type (OMIM 132000).
Bart syndrome is a rare inherited condition characterized by epidermolysis bullosa and congenital absence of skin. It has been associated with other anomalies including pyloric atresia. The genetic abnormality has been linked to chromosome 3, with an autosomal dominant pattern of inheritance [2].
The mutant gene is COL7A1, located on 3p21.31 [1]. It is first reported by Bart and his colleagues in 1966 [3]. The disease is named after Bruce J Bart.
Dr Bruce J Bart (Fig.1) was born on April 6, 1936 in Minneapolis, Minnesota; USA. He is an academic dermatologist, working currently, as a Chair of the Dermatology department t at Hennepin County Medical Center and Professor of Dermatology at the University of Minnesota, USA.
In 1962 Dr Bart saw a 5 year old girl who had aplasia, blistering and nail abnormalities at birth and studied many members of her extended family with the same syndrome and published his work in 1966.
He subsequently studied the family and demonstrated that the syndrome was a form of dominant dystrophic EB.
In recent years many have discouraged the use of "Bart's Syndrome", favoring "a variation of DEB".



Figure 1. Dr Bruce J Bart

Bart-Pumphrey syndrome (BPS) or Schwann syndrome

This syndrome is characterized by knuckle pads, leukonychia, palmoplanter keratoderma (PPK) and sensorineural deafness. However, this syndrome has a considerable phenotypic variability. It is cited in the Online Mendelian Inheritance in Man [1], as knuckle pads, leukonychia, and sensorineural deafness (OMIM 149200) [4].
There is extensive overlap between the different forms of palmoplantar keratoderma (PPK) associated with hearing loss (HL) caused by GJB (Cx26) mutations (and they are

each quite rare). Therefore, some scientists thought that, it is worthwhile considering lumping them together under a title like 'GJB2 related PPK/HL'.

This syndrome is first described by Dr Schwann, from Poland and appeared later in English literature by Robert S. Bart (Dermatologist) and Robert E. Pumphrey (Otolaryngologist); both from USA [4].

Dr Robert S Bart (Fig. 2) reported this syndrome, in 1967, while he was working as an assistant professor of clinical dermatology, New York University School of Medicine and Post-Graduate Medical School [5].

In addition to the above syndrome, Dr Robert S Bart, had several other important publications.

In 1968, Bart et al [6] described 10 cases of an uncommon acquired skin growth that, they name it "acquired digital fibrokeratoma" (ADFK).

In their earlier description, the authors stated that the lesions resemble a "rudimentary supernumerary digit".

ADFK was once known eponymously as" Bart-Andrade acquired digital fibrokeratoma " [7], but this name is not of use any more and the disease is just known as acquired digital fibrokeratoma.

Figure 2. Robert Bart, Image courtesy of The Archives of the Frederick L. Ehrman Medical Library, available online at http://archives.med.nyu.edu/resources/imagedb/detail.php?recordID=35090002763282

REFERENCES

1. Epidermolysis bullosa with congenital localized absence of skin and deformity of nails. From OMIM, Online Mendelian Inheritance in Man. Copyright (c) 1966-2011 Johns Hopkins University. Available at: http://omim.org/entry/132000

2. Bart BJ, Lussky RC: Bart syndrome with associated anomalies. Am J Perinatol. 2005; 22: 365-369.

3. Bart BJ, Gorlin RJ, Anderson VE, Lynch FW: Congenital localized absence of skin and associated abnormalities resembling epidermolysis bullosa. A new syndrome. Arch Dermatol. 1966; 93: 296-304.

4. Al Aboud K: Jadwiga Schwann and her syndrome. Our Dermatol Online 2011; 2: 224-225.

5. Bart RS, Pumphrey RE: Knuckle pads, leukonychia and deafness. A dominantly inherited syndrome.N Engl J Med. 1967; 276: 202-207.

6.Bart RS, Andrade R, Kopf AW, Leider M: Acquired digital fibrokeratomas. Arch Dermatol. 1968; 97: 120-129.

7. de Sablet M, Bernard I: Bart-Andrade acquired digital fibrokeratoma. Bull Soc Fr Dermatol Syphiligr. 1969; 76: 836-837.

Copyright *Ahmad Al Aboud et al.* This is an open access article distributed under the terms of the Creative Commons Attribution License, which permits unrestricted use, distribution, and reproduction in any medium, provided the original author and source are credited.

NASZA DERMATOLOGIA Online
OUR DERMATOLOGY Online

DERMATOLOGY EPONYMS – PHENOMEN / SIGN – LEXICON (F)

Piotr Brzeziński[1], Elena Godoy Gijón[2], José López-López[3], Takao Toyokawa[4], Nevin S. Scrimshaw[5], Olivier Malard[6], Cesar Bimbi[7]

[1]*Dermatological Clinic, 6th Military Support Unit, Ustka, Poland* brzezoo77@yahoo.com
[2]*Servicio de Dermatología, Hospital Clínico de Salamanca, Salamanca, Spain* dra.e.godoy@gmail.com
[3]*Department of Stomatology, School of Dentistry, University of Barcelona, Catalonia, Spain* 18575jll@gmail.com
[4]*Division of General Internal Medicine and Infectious Diseases, Okinawa Prefectural Southern Medical Center and Children's Medical Center, Okinawa, Japan* toyokawa_takao@hosp.pref.okinawa.jp
[5]*International Nutrition Foundation, Boston, USA* nscrimshaw@inffoundation.org
[6]*Department of ENT and Face & Neck Surgery, Nantes University Hospital, 44093 Nantes Cedex, France* omalard@chu-nantes.fr
[7]*Brazilian Society of Dermatology* cbimbi@terra.com.br

Our Dermatol Online. 2012; 3(1): 66-78 Date of submission: 10.10.2011 / acceptance: 14.11.2011
Conflicts of interest: None

Abstract
Eponyms are used almost daily in the clinical practice of dermatology. And yet, information about the person behind the eponyms is difficult to find. Indeed, who is? What is this person's nationality? Is this person alive or dead? How can one find the paper in which this person first described the disease? Eponyms are used to describe not only disease, but also clinical signs, surgical procedures, staining techniques, pharmacological formulations, and even pieces of equipment. In this article we present the symptoms starting with (F). The symptoms and their synonyms, and those who have described this symptom or phenomenon.

Streszczenie
Eponimy stosowane są niemal codziennie w praktyce w klinicznej dermatologii. A jednak informacja na temat osoby związanej z danym eponimem jest trudna do znalezienia. Kto to jest? Jakie jest jego obywatelstwo? Czy jeszcze żyje, jeśli nie to kiedy zmarł? Jak można znaleźć artykuł, w którym osoba ta po raz pierwszy opisała chorobę? Eponimy są używane do opisywania nie tylko choroby, ale również objawu klinicznego, zabiegu chirurgicznego, technik barwienia, preparatów farmakologicznych, a nawet elementów wyposażenia. W tym artykule prezentujemy objawy zaczynające się na literę F. Objawy i ich synonimy oraz tych, którzy opisali ten objaw lub zjawisko.

Key words: eponyms; skin diseases; sign; phenomen
Słowa klucze: eponimy; choroby skóry; objaw; fenomen

FALL-AND-RISE SIGN

The drop in the number of bacteria that occurs at the beginning of drug treatment and the gradual rise follows phenomenon, even while treatment continues.

OBJAW SPADKU I WZROSTU

Spadek liczby bakterii, który występuje na początku leczenia i następnie zjawisko stopniowego wzrostu, nawet podczas kontynuowania leczenia.

FARMER'S SKIN SIGN

Synonym: Cutis rhomboidalis nuchae

OBJAW SKÓRY FARMERA

Synonim: Cutis rhomboidalis nuchae

Figure 1. Farmer's skin sign

FECAL PLACENTAL SIGN

If the placenta has a fecal odor, there is a possible infection with *Fusobacterium necrophorum* or *Bacteroides frugalis*.

OBJAW ŁOŻYSKA O ZAPACHU KAŁU

Jeżeli łożysko ma zapach kału, to istnieje możliwość zakażenia *Fusobacterium necrophorum* lub *Bacteroides fragilis*.

FIBULA SIGN

Thickening of the lateral peroneal nerve around the fibula. A sign of tuberculoid leprosy.

OBJAW KOŚCI SKRZAŁKOWEJ

Pogrubienie boczne nerwu strzałkowego wokół kości strzałkowej. Objaw trądu tuberkuloidowego.

FERNANDEZ REACTION (lepromin test)

An intraepidermal injection of 0,1 ml of lepromin is read at 48 hours for erythema used in classifying leprosy into the various subtypes. Negative in lepromatosus leprosy, and positive in tuberculoid leprosy.

REAKCJA FERNANDEZA (test z leprominą)

Występowanie rumienia 48 godzin po śródskórnym wstrzyknięciu 0,1 ml leprominy; stosowane w klasyfikacji trądu różnych podtypów. Negatywne w trądzie lepromatycznym i pozytywne w trądzie tuberkuloidowym.

J.M.M. FERNANDEZ

Brazilian dermatologist. Fernandez in 19391 suggested that B.C.G. vaccination might confer some protection because of the possible existence of a common antigen in B.C.G. and *Mycobacterium leprae*. Fernandez reported that Mitsuda-negative children were converted to Mitsuda-positivity after injections of BCG, the world almost evenly divided itself into two currents of opinion that fiercely combated with each other:
1. the BCG "converters" - very enthusiastic about the possibility of vaccination, and 2. the skeptical "non-converters", who either could not duplicate Fernandez's observations or attributed eventual conversions to a kind of "maturation" or to the Mitsuda tests routinely performed before and after BCG.

Brazylijski dermatolog. Fernandez w 1939 zasugerował, że szczepionka B.C.G. może stanowć pewną ochronę w trądzie ze względu na możliwe istnienie wspólnego antygenu w B.C.G. i *Mycobacterium leprae*. Fernandez poinformował, że ujemne testy Mitsudy wykonane u dzieci zostały zamienione na wyniki dodatnie po zastosowaniu szczepionek z BCG; świat niemal równo podzielił się na dwa nurty opinii.
1.BCG "konwertery"- bardzo entuzjastyczne nastawieni do możliwości szczepienia i 2. sceptyczny "non-konwertery", ci którzy albo nie mogli podzielać uwagi Fernandeza albo przypisywali ewentualne konwersje do rodzaju "dojrzewania" lub do testów Mitsudy rutynowo wykonywanych przed i po BCG.

FIEDLER'S SIGN

Severe leptospirosis; also called Weil's sign, Fiedler's disease, Landouzy's disease, Mathieu's disease, Vasiliev's syndrome, Larrey's disease.

Figure 2. Fiedler's sign

OBJAW FIEDLERA

Ciężka leptospiroza; zwana także objawem Weila, chorobą Fiedlera, chorobą Landouzy, chorobą Mathieu, zespołem Vasilieva, choroba Larreya.

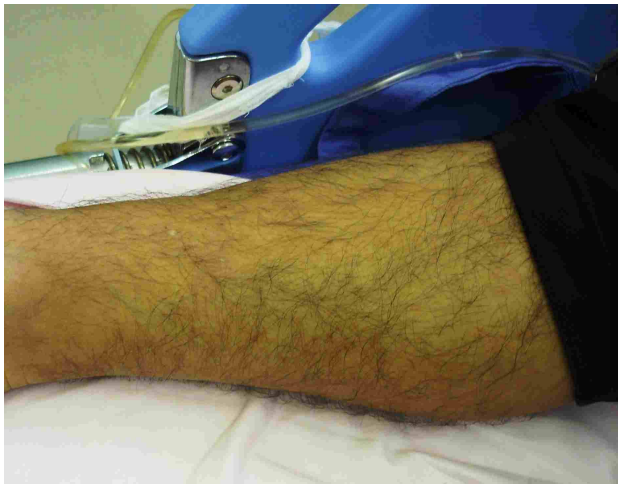

Figure 3. Fiedler's sign

CARL LUDWIG ALFRED FIEDLER

German physician, 1835-1921. Studied in Leipzig, as a student of Karl Reinhold August Wunderlich (1815-1877). He received his doctorate in 1859, was assistant physician at the medical clinic at Rostock, and from 1868 chief physician at the municipal hospital – the Stadtkrankenhaus - in Dresden. He became professor, and was also privy medical counsellor and royal life physician.



Figure 4. Carl Ludwig Alfred Fiedler

Niemiecki lekarz, 1835-1921. Studiował w Lipsku, jako uczeń Karla Reinhold Augusta Wunderlich (1815/77). Doktorat otrzymał w 1859 roku, był asystentem lekarza w przychodni w Rostocku, a od 1868 naczelnym lekarzem szpitala miejskiego - Stadtkrankenhaus - w Dreźnie. Był profesorem oraz wtajemniczonym doradcą medycznym i lekarzem królewskim.

FILATOV SIGN

1. Occurrence of circumoral parllor in scarlet fever. 2. Infectious mononucleosis.

Figure 5. Filatov sign

OBJAW FILATOWA

1. Obecność bladej skóry wokół ust i nosa w szkarlatynie. 2. Mononukleoza zakaźna.

NICOLAI FEODOROVICH FILATOV

Russian pediatrician (1847-1902). Father of Russian Pediatrics. After graduating from the University of Moscow he returned to his district to practise as a country doctor. Undertook further training in Vienna, Paris, Berlin and in Prague. After two years he returned to Moscow and began working and teaching in the Old Children's Hospital in 1876. In 1891 he was appointed professor of paediatrics. In 1892 the Moscow Paediatric Society was founded and Filatov was appointed as its president.

Figure 6. Nicolai Feodorovich Filatov

Rosyjski pediatra (1847-1902). Ojciec Pediatrii rosyjskiej. Po ukończeniu Uniwersytetu Moskiewskiego powrócił do wykonywania zawodu lekarza. Podjął dalsze kształcenie w Wiedniu, Paryżu, Berlinie, w Pradze. Po dwóch latach wrócił do Moskwy i rozpoczął pracę w Old Children's Hospital w 1876 roku. W 1891 roku został mianowany profesorem pediatrii. W 1892 roku powstało Moskiewskie Towarzystwo Pediatryczne, a Filatov został powołany na stanowisko jej przewodniczącego.

FILATOV-DUKE'S SIGN

An alleged exanthematosus contagious disease resembling rubella, scarlatina, and measles. It is marked by lamellar desquamation of the skin. Also called fourth disease, rubeola scarlatinea, Dukes disease, Dukes-Fiłatow disease.

OBJAW FILATOWA-DUKESA

Rzekoma wysypka w przebiegu choroby zakaźnej przypominająca różyczkę, szkarlatynę i odrę. Cechują ją lamelarne złuszczanie skóry. Objaw zwany również czwartą chorobą, rubeola scarlatinea, chorobą Dukesa, chorobą Dukesa-Fiłatowa.

CLEMENT DUKES

English physician, (1845-1925). In 1871 was appointed medical officer at Rugby school, a position he held until 1908. At Rugby he won world-wide renown for his books and articles on schoolboy health and health care. In the 80s Nineteenth century provided a description of the epidemic in Rugb (known English private school). Never subsequently described in other cases, the fourth disease. In 1900 he published an article entitled «On the confusion of two diseases under the name of rubella (Rose Rash).

Angielski lekarz, (1845-1925). W 1871 został powołany na stanowisko lekarza w szkole Rugby, stanowisko to piastował aż do 1908 roku. Na Rugby zdobył światową sławę za jego książki i artykuły dla uczniów i opieki zdrowotnej. W latach 80. XIX wieku przedstawił opis epidemii w Rugb (znana angielska szkoła prywatna). Nigdy później nie opisano innych przypadków czwartej choroby. W 1900 roku opublikował artykuł zatytułowany "Na pomieszanie dwóch chorób pod nazwą różyczka (Różowa wysypka).

FILIPOVITCH'S SIGN

Yellow discoloration of prominent parts of the palms and soles. A sign of typhoid fever. Also known as palmoplantar sign.

OBJAW FILIPOVITCHA

Żółte przebarwienia widoczne na dłoniach i stopach. Objaw duru brzusznego. Znany również jako objaw dłoniowo-podeszwowy.

CASMIR FILIPOVITCH (FILIPOWICZ)

Polish physician, botanist, (1845-1891).

Polski lekarz, botanik, (1845-1891).

FILTH SIGN, DISEASE

Described as: a disease due to dirt and unclean habits. Has been associated with immune mediated responses and zoonotic disease transmissions from humans sharing sleeping quarters and bed linens with animals. These habits place in prolonged direct contact with allergenic pet hair and dander, that also contain embryonic (eggs) and adult forms of fleas, mites, ticks, lice, and multiple related mange conditions; the pathogenic bacteria, worms, viruses.

OBJAW BRUDU, CHOROBA

Opisany jako: choroba z powodu brudu i nieczystych zwyczajów. Była związana z odpowiedzią immunologiczną za pośrednictwem transmisji chorób odzwierzęcych od ludzi śpiących ze zwierzętami. Te miejscowe nawyki przedłużały bezpośredni kontakt z alergenami sierść zwierząt oraz alergenami, które zawierają również zarodniki (jaja) i dorosłe formy pcheł, roztocza, kleszcze, wszy i wiele innych powiązanych ze sobą czynników; bakterie chorobotwórcze, robaki, wirusy.

EDWARD HEADLAM GREENHOW

English physician, 1814-1888. Physician, epidemiologist, sanitarian, statistician, clinician and lecturer. He studied medicine at Edinburgh and Montpelier. In 1855 he was appointed lecturer on public health at St. Thomas's Hospital. Dr. Greenhow was engaged to undertake inquiries into diphtheria (1859) and pulmonary disease among operatives (miners, grinders, flax-dressers, etc.). He was a zealous and successful teacher and investigator, and an excellent and thorough-going man of business. Greenhow wrote i.a.: 'On Diphtheria,' 1860. 'On Addison's Disease,' 1866.



Figure 7. Edward Headlam Greenhow

Angielski lekarz, 1814-1888. Lekarz, epidemiolog, higienista, statystyk, klinicysta i wykładowca. Studiował medycynę w Edynburgu i Montpelier. W 1855 roku został mianowany wykładowcą zdrowia publicznego w

szpitalu St Thomas. Dr Greenhow został zaangażowany do przeprowadzenia dochodzenia w sprawie błonicy (1859) i chorób płuc wśród zawodów (górnik, szlifierz, obrabiający len, itp.). Był gorliwym i skutecznym nauczycielem i badaczem, a także wspaniałym i gruntownym człowiekiem biznesu. Greenhow napisał m.in.: 'On Diphtheria,' 1860. 'On Addison's Disease,' 1866.

FISHERMAN'S SIGN

A zoonotic skin or systemic cellulitis disease caused *Erysipelothrix rhusiopathiae.* The bacterium is found in fish, swine, turkeys, marine mammels, and pigeons.

OBJAW RYBAKA

Odzwierzęca, skórna i systemowa choroba tkanki łącznej spowodowana przez *Erysipelothrix rhusiopathiae*. Bakteria występuje w rybach, u świń, indyków, ssaków morskich i gołębi.

FISH-SKIN SIGN

Synonym: ichthyosis.

OBJAW SKÓRY RYBY

Synonim: ichthyosis.

FITZPATRICK SIGN

Sign in dermatofibroma. Lateral pressure produces a with an overlying depression in the center of the papule. A central depression or dimple elicited within a lesion when it is squeezed along its margins. Also knowns as Dimple sign.

Figure 8. Fitzpatrick sign

OBJAW FITZPATRICKA

Objaw w dermatofibroma. Ciśnienie boczne wytwarza depresję leżącej w centrum grudki. Wgłębienie lub dołek wywołany rozprężeniem zmiany wzdłuż jej brzegów. Zwany również objawem dołka lub guzika

THOMAS BERNARD FITZPATRICK

American dermatologist, 1920-2003. Often proclaimed as one of the world's leading dermatologist. He was the Professor and Chairman of the Department of Dermatology at Harvard Medical School and Chief of the Massachusetts General Hospital Dermatology Service from 1959 to 1987. Fitzpatrick graduated from the University of Wisconsin (AB), Harvard Medical School (MD), and University of Minnesota (PhD). During World War II he served in the Army Chemical Center, where he met Aaron B. Lerner, MD, PhD, and began a historical collaboration to explain pigmentation of skin. In 1971 Fitzpatrick published the first multiauthor dermatology textbook in the United States and served as organizer and senior editor for 4 subsequent editions of this seminal book about skin and skin disease for dermatologists and nondermatologist physicians.Fitzpatrick described cutaneous markers of certain neurological disorders and many other markers and skin signs of systematic illness. He was one of the first to apply electron microscopy to study of the skin, and with colleagues discovered and named the melanosome, the basic subcellular organelle of pigmentation. He helped in defining and profiling the clinical and microscopic characteristics of early melanoma. He and his colleagues invented oral psoralen photochemotherapy (PUVA).



Figure 9. Thomas Bernard Fitzpatrick

Amerykański dermatolog, 1920-2003. Ogłoszony jako jeden z wiodących na świecie dermatologów. Był profesorem i przewodniczącym Wydziału Dermatologii na Harvard Medical School i dyrektorem Massachusetts General Hospital Dermatology Service 1959/87. Fitzpatrick jest absolwentem Uniwersytetu Wisconsin (AB), Harvard Medical School (MD) i Uniwersytetu Minnesota (PhD). Podczas II wojny światowej służył w Army Chemical Center, gdzie spotkał się z Aaronem B. Lerner, MD, PhD, i rozpoczął historyczną współpracę w wyjaśnianiu pigmentacji skóry. W 1971 Fitzpatrick opublikował pierwszy z udziałem wielu autorów

podręcznik dermatologii w Stanach Zjednoczonych i był organizatorem i redaktorem 4 kolejnych wydań tej przełomowej książki o skórze i chorobach skóry dla dermatologów. Fitzpatrick opisał skórne markery niektórych zaburzeń neurologicznych i wielu innych markerów i objawów skórnych chorób systemowych. Był jednym z pierwszych, który zastosował mikroskopię elektronową do badania skóry, z kolegami odkrył i nazwał melanosomy, podstawowe wewnątrzkomórkowe organella pigmentacji. Pomagał w definiowaniu i profilowaniu klinicznym i mikroskopowym wczesnego czerniaka. On i jego koledzy wymyślili leczenie łuszczycy doustnym psoralenem z naświetlaniem UV (PUVA).

FLAG SIGN

Dyspigmentation of the hair occurring as a band of light hair. may be accompanied by (hyperthyroidism, hypothyroidism, use of certain medications (anti malarial), nutritional deficiencies; kwashiorkor. The person first describing "flag sign" was Dr. Antonio Pena Chaivsrria, Director San Juan de Dios Children's Hospital in San Jose, Costa Rica under the name "Signo de Bandera".



Figure 10. Flag sign

OBJAW FLAGI

Pasmo jasno zabarwionych włosów na skórze głowy, może towarzyszyć (nadczynności, niedoczynności tarczycy, stosowaniu niektórych leków (p/malarycznych), niedoborów żywieniowych; kwashiorkor. Osobą, która po raz pierwszy opisała "objaw flagi" był dr Antonio Pena Chaivsrria, dyrektor San Juan de Dios Children's Hospital w San Jose, z Kostaryki pod nazwą "Signo de Bandera".

ANTONIO PEÑA CHAVARRÍA

P Director San Juan de Dios Children's Hospital in San Jose, Costa Rica.

Dyrektor San Juan de Dios Children's Hospital w San Jose w Kostaryce.

FORDYCE'S SIGN

Numerous small, faint yellow granules occurring in the buccal mucosa and lip. Also called Fordyce granules. Oral contraceptives have been linked to an increase in incidence.

Figure 11. Fordyce's sign

OBJAW FORDYCE

Liczne małe, blado-żółte granulki występujące na błonie śluzowej jamy ustnej i warg. Zwany także granulkami Fordyce. Doustne środki antykoncepcyjne są związane ze wzrostem częstości występowania objawu.

JOHN ADDISON FORDYCE

American dermatologist, 1858-1925. His name is associated with Fordyce's spot, Brooke–Fordyce trichoepithelioma, Fordyce's disease, Fordyce's lesion, and Fox-Fordyce disease. Fordyce graduated in 1881 with a degree in Medicine from the Chicago Medical College. He began his career in Hot Springs, Arkansas, but would travel to Europe in 1886. There he studied dermatology in Vienna and Paris. He returned to the States and settled down in New York, where he was a specialist in dermatology and syphilis. From 1889 to 1893 he taught at the New York Polyclinic, and later he served as a professor at the Bellevue Hospital College and the Columbia University College of Physicians and Surgeons.

Amerykański dermatolog, 1858-1925. Nazwisko wiąże się z takimi schorzeniami jak Plamki Fordyce'a, trichoepithelioma Brooke–Fordyce'a, choroba Fordyce'a, zmiany Fordyce'a, choroba Foxa-Fordyce'a. Fordyce w 1881 uzyskał dyplom medycyny z School of Medicine w Chicago. Swoją karierę rozpoczął w Hot Springs w stanie Arkansas, skąd w 1886 przeniósł się do Europy, gdzie studiował dermatologię w Wiedniu i Paryżu. Po powrocie do USA osiedlił się w Nowym Jorku, gdzie był specjalistą dermatologii i kiły. Od 1889 do 1893 uczył na Poliklinice Nowojorskiej, później był profesorem Bellevue Hospital College i College of Physicians and Surgeons.



Figure 12. John Addison Fordyce

FORDYCE'S LESION

Synonym: Angiokeratoma.

Figure 13. Fordyce's lesion

ZMIANY FORDYCE

Synonim: Angiokeratoma.

FOREHEAD SIGN

Smooth forehead due to changes in the center of the frontalis muscle and loss of the eyebrows and eyelashes. An indication of leprosy.

OBJAW CZOŁA

Gładkie czoło w związku ze zmianami w centrum mięśni czołowych oraz utratę brwi i rzęs. Objaw trądu.

FORSCHHEIMER SIGN

Small, red spots (petechiae) on the soft palate in 20% of patients with rubella. They precede or accompany the skin rash of rubella.

Figure 14. Forschheimer sign

OBJAW FORSCHHEIMERA

Małe, czerwone plamki (wybroczyny) na podniebieniu miękkim u 20% pacjentów z różyczką. Mogą poprzedzać lub towarzyszyć wysypce na skórze.

FREDERICK FORSCHHEIMER

American pediatrician known for describing Forchheimer spots. He became an instructor at the Medical College of Ohio in 1875, and founded one of the first clinics for children in the United States. He became professor of diseases of children, and published Diseases of the Mouth in Children in 1892 in which he described his eponymous sign. He became president of the Association of American Physicians in 1911 and was given an honorary Doctor of Science degree by Harvard University.

Figure 15. Frederick Forschheimer

Amerykański pediatra, znany z opisu plamek Forchheimera. Był instruktorem w Medical College of Ohio w 1875 roku i założył jedną z pierwszych klinik dla dzieci w Stanach Zjednoczonych. Został profesorem chorób dzieci i opublikował książkę o chorobach jamy ustnej u dzieci w 1892 roku, w której opisał jego tytułowy objaw. Został prezesem amerykańskiego towarzystwa lekarzy w roku 1911 i otrzymał honorowy doktorat z nauki przyznany przez Harvard University.

FOTHERGILL'S SIGN

1. Facial pain brought on by the gentlest touch. A sign of trigeminal neuralgia. Also called trifacial neuralgia.
2. Scarlatiana anginosa.

OBJAW FOTHERGILLA

1. Ból twarzy spowodowany przez delikatny dotyk. Objaw neuralgii nerwu trójdzielnego. Zwany także jako trifacial neuralgia. 2. Anginosa Scarlatiana.

JOHN FOTHERGILL

English physician and botanist, 1712-1780. He was the first to give an accurate description of migraine and trigeminal neuralgia. He used artificial respiration as early as 1744 and believed in the medicinal properties of coffee. A keen botanist, he kept a botanical garden with thousands of tropical plants in hothouses. He was the first to describe the Fothergilla shrub. He also campaigned for the abolition of slavery, the registration of births and deaths and the widening of London's streets.

Figure 16. John Fothergill

Angielski lekarz i botanik, 1712-1780. Był pierwszym, który przedstawił dokładny opis migreny i neuralgii nerwu trójdzielnego. Zastosował sztuczne oddychanie już w 1744r. i wierzył w lecznicze właściwości kawy. Zapalony botanik, trzymał w ogrodzie botanicznym tysiące tropikalnych roślin w szklarniach. Był pierwszym, który opisał krzew Fothergilla. Prowadził kampanię na rzecz zniesienia niewolnictwa, rejestracji urodzeń i zgonów oraz poszerzenia ulic w Londynie.

FOUNTAIN OF YOUTH SIGN (Mexico)

The patient's wrinkles have smoothed out and their face has been restored to a youthful appearance. Indicates infection with a diffuse type of leprosy.

OBJAW MŁODZIEŃCZEJ FONTANNY

Wygładzenie zmarszczek i przywrócenie twarzy do młodego wyglądu. Wskazuje na rozsiany typu trądu.

FOURNIER SIGN

1. The sharp delimitation characteristic of a syphilitic skin lesion and Scars on the mouth following the healing of lesions in congenital syphilis.
2. Anterior bowing of the tibia, seen in some children with congenital syphilis. Saber shin.

Figure 17. Fournier sign

OBJAW FOURNIERA

1.Ostre charakterystyczne rozgraniczenia syfilitycznych zmian skórnych oraz blizny na ustach po wygojeniu zmian we wrodzonej kile.
2. Przodozgięcie kości piszczelowej, u niektórych dzieci z wrodzoną kiłą. Szablowate podudzia.

JEAN ALFRED FOURNIER

French dermatologist, 1832-1914. He specialized in the study of venereal diseases. In 1876 he was appointed chef de service at the Hôpital Saint-Louis, and in 1880 became a member of the Académie de Médecine. His main contribution to medical science was the study of congenital syphilis, of which he provided a description of in 1883. In his numerous publications he stressed the importance of syphilis being the cause of degenerative diseases. His name is associated with the following three medical terms:
Fournier's gangrene: Gangrene caused by infection of the scrotum and usually associated with diabetes. Although the condition is named after Fournier, it was first described by a physician named Baurienne in 1764.
Fournier's sign, Fournier's tibia.



Figure 18. Jean Alfred Fournier

Francuski dermatolog, 1832-1914. Specjalizował się w badaniach chorób wenerycznych. W 1876 roku został mianowany Kierownikiem w Hôpital Saint-Louis, a w roku 1880 został członkiem Académie de Medecine. Jego głównym wkładem do nauk medycznych było badanie wrodzonej kiły, którego wynikiem był opis w 1883 roku. W swoich licznych publikacjach podkreślał znaczenie kiły, jako przyczyny chorób degeneracyjnych. Jego nazwisko wiąże się z trzema następującymi kategoriami medycznymi:
Zgorzel Fourniera: Gangrena spowodowana przez zakażenie moszny i zazwyczaj związana z cukrzycą. Chociaż zmiana nosi nazwę Fourniera, po raz pierwszy opisana została przez Baurienne w 1764 roku. Objaw Fourniera, piszczel Fourniera.

FOURTH SIGN

See: Filatov-Duke's sign.

OBJAW CZWARTY

Patrz: objaw Filatowa-Dukesa.

FRANCIS SIGN

Painful skin lesions, pneumonia, pharyngitis. Infection caused by a zoonotiic tularemia disease. Forms of this bacterium are viable biological weapons. Also called deel-fly fever, rabbit fever, and Ohara fever.

OBJAW FRANCISA

Bolesne zmiany skórne, zapalenie płuc, zapalenie gardła. Infekcja spowodowane przez odzwierzęcą chorobę-tularemię. Formy tej bakterii są zdolne do użycia jako broń biologiczna. Zwany także jako deel-fly fever, gorączka królicza, gorączka Ohara.

EDWARD FRANCIS

American microbiologist, (1872-1957). Francis studied at the Ohio State University and at the University of Cincinnati, where he received his medical degree in 1897. In 1922 the Francis first recognized tularemia in humans and *Francisella tularensis* as the cause of the disease. In 1928 the American Medical Association awarded Francis its Gold Medal for his contributions to the knowledge of tularaemia. He received honorary degrees from Miami University and Ohio State University. Besides tularaemia, Francis also wrote on yellow fever, pellagra, tetanus, filariasis and febris undulans (brucellosis).

Figure 19. Edward Francis

Amerykański mikrobiolog, (1872-1957). Francis studiował na Ohio State University oraz w University of Cincinnati, gdzie otrzymał dyplom lekarza w 1897 roku. W 1922 r. Francis po raz pierwszy opisał tularemię u ludzi, a *Francisellę tularensis* jako przyczynę choroby. W 1928 roku American Medical Association przyznało mu Złoty Medal za jego wkład do wiedzy o tularemii. Otrzymał doktorat honoris causa Uniwersytetu Miami i Ohio State University. Poza tularemią, Francis opisał również żółtą febrę, pellagrę, tężec, filariozy i febris undulans (brucellosis).

FRANK SIGN

Diagonal crease on the ear lobe of an adult, associated with increased risk of coronary artery disease.

OBJAW FRANKA

Ukośny fałd na płatku ucha dorosłego człowieka, związanu ze zwiększonym ryzykiem choroby wieńcowej.

Figure 20. Frank sign

SANDERS T. FRANK

American pulmonologist, born in 1938; known for describing Frank's sign. He has worked as director of respiratory medicine at the Garfield Medical Centre, Monterey Park, California.

Amerykański pulmunolog, urodzony w 1938r.; znany z opisu objawu Franka. Pracował jako dyrektor ds. chorób układu oddechowego w Garfield Centrum Medyczne, Monterey Park, Kalifornia.

FRÄNKEL'S SIGN

The diminished tonicity of the hip joint muscles. A sign of tabes dorsalis.

OBJAW FRÄNKELA

Zmniejsza napięcie mięśniowego mięśni stawu biodrowego. Objaw tabes dorsalis.

ALBERT FRÄNKEL

German physician, 1848-1916. Helped establish Streptococcus pneumoniae as a cause of bacterial pneumonia and championed intravenous ouabain for use in heart failure. The Albert-Fraenkel-Plakette (Albert Fraenkel award) is given to German-speaking cardiologists who have excelled in the field. He studied medicine in Munich and Strasbourg in the 1880s. He initially practiced internal medicine and obstetrics, but turned to studying diseases of the lungs after suffering from tuberculosis. He established a tuberculosis sanatorium at Badenweiler in the Black Forest. Fraenkel also first used g-Strophanthin (ouabain) in heart failure, a practice which continues to be advocated by some practitioners in Germany.

Niemiecki lekarz, 1848-1916. Jako pierwszy wskazał na Streptococcus pneumoniae jako przyczynę bakteryjnego zapalenia płuc. Nagrodę Alberta Fränkela (Albert Fränkel Plakette) przyznaje się niemieckojęzycznym kardiologom w uznaniu zasług na tym polu. Studiował medycynę w Monachium i Strasburgu w 1880 roku. Początkowo praktykował medycynę wewnętrzną i położnictwo, ale zwrócił się w kierunku chorób płuc i chorych na gruźlicę. Założył sanatorium przeciwgruźlicze w Badenweiler w Schwarzwaldzie. Fränkel również po raz pierwszy użył g-Strophanthin (ouabain) w niewydolności serca, praktyki, która nadal jest zalecane przez niektórych lekarzy w Niemczech.



Figure 21. Albert Fränkel

FRÈDÈRICQ'S SIGN

A red line on the gingival in tuberculous and certain pulmonary affections.

OBJAW FRÈDÈRICQ

Czerwona linia na dziąsłach w gruźlicy płuc i niektórych schorzeń płuc.

LOUIS AUGUST FRÈDÈRICQ

Belgian physician, 1815-1853.

Belgijski lekarz, 1815-1853.

FRENCH SIGN

Syphilis. Also called morbus gallicus or the French disease.

OBJAW FRANCUSKI

Kiła. Zwany także chorobą galicyjską lub chorobą francuską.

HIERONYMUS FRACASTORIUS

Physician, astronomer, a naturalist, a poet and a philosopher, 1483-1553. The poem Syphilis sive morbus gallicus was published by Fracastor in 1530. It is written in excellent Latin and gives a valuable description of the symptomatology of this venereal disease. In De morbis contagiosis, printed in Venice in 1546, Fracastor describes the cause of syphilis and appears as a precursor of bacteriology. Fracastor was born in 1483 within a well-known medical family. He studied the Fine Arts, Mathematics and Medicine in Padova.

Figure 22. Hieronymus Fracastorius

Lekarz, astronom, przyrodnik, poeta i filozof, 1483-1553. Poemat o kile, chorobie galicyjskiej Fracastor opublikował w 1530 roku. Jest napisany w doskonałej łacinie i zawiera opis objawów choroby wenerycznej. W De morbis contagiosis, drukowanej w Wenecji w 1546, Fracastor opisuje przyczyny kiły i pojawia się tu jako prekursor bakteriologii. Fracastor urodził się w 1483 w znanej rodziny lekarskiej. Studiował Sztuki Piękne, matematykę i medycynę w Padwie.

FRENCHIFY'D SIGN

An english term translated as: a person with veneral disease.

OBJAW SFRANCUŻENIA

Angielskie słowo tłumaczone jako: osoba z chorobą weneryczną.

FREUND SIGN

A brownish to reddish discoloration of the neck and sometimes the arms due to applying perfume or cologne to the skin and subsequent exposure to sunlight. Sometimes the skin first turns red pefore changing to a brownish color. Many perfumes and colognes contain oil of bergamot. Synonym: Bergamot disease, Freund dermatitis, berloque dermatitis, eau de cologne dermatitis, photodermatitis pigmentaria, Pigmentation en coulée, breloque en collier, toilet water dermatitis.

OBJAW FREUNDA

Od brązowego do czerwonawego przebarwienia na szyi, a czasami i na rękach z powodu stosowania perfum lub wody kolońskiej na skórę i późniejszej ekspozycji na światło słoneczne. Na początku skóra może mieć kolor czerwony, z czasem przybierze kolor brązowy. Wywołany przez wiele perfum i wód kolońskich zawierających olejek bergamotki, ekstrakt skórki pomarańczowej. Synonim: choroba bergamotki, zapalenie skóry Freunda, berloque dermatitis, eau de cologne dermatitis, photodermatitis pigmentaria, pigmentation en coulée, breloque en collier, toilet water dermatitis.

EMANULE FREUND

Italian physician, 1869-1940.

Włoski lekarz, 1869-1940.

FRITOS SIGN

(Fritos is the name of a brand of corn chips made by Frito-Lay). The corn chip or tortilla odor sometimes associated with beta-hemolytic *Streptococcus pyogenes.*

OBJAW FRITOS

(Fritos jest nazwą marki płatków kukurydzianych produkowanych przez Frito-Lay). Zapach płatków kukurydzianych lub tortilli jest czasami związany z beta-hemolizującymi *Streptococcus pyogenes*.

FROG'S NECK SIGN / FROG'S SIGN

Cystic hygroma; remarkable translucent swelling of the neck / lessions in the oral cavity.

Figure 23. Frog's neck sign

Figure 24. Frog's sign

OBJAW ŻABIEJ SZYI / ŻABI OBJAW

Cystic hygroma; niezwykle przezroczysty obrzęk szyi / zmiany w jamie ustnej.

FUTCHER'S LINE

Sharp, linear demarcation between dark and light skin, most commonly seen on the anterolateral aspect of the upper arm and posteromedial leg. They occur in 75% of black individuals, 10% if Caucasians, and 4% of Japanese individuals. Also known as type A lines, Voigt's lines, pigmentary demarcation lines.

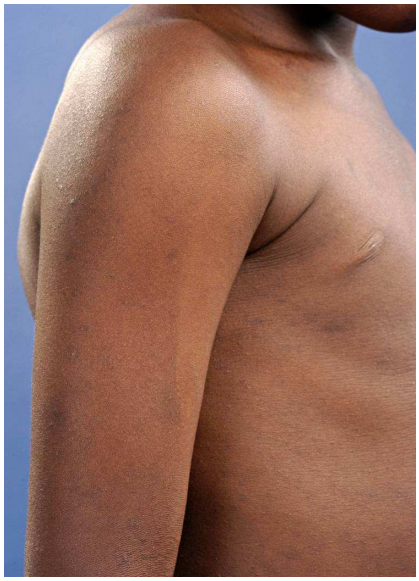

Figure 25. Futcher's line

LINIE FUTCHERA

Ostro przebiegające, linie demarkacyjne pomiędzy skórą ciemniejszą i jaśniejszą, najczęściej postrzegane w przednio-bocznej części ramienia i tylno-pośrodkowej powierzchni nóg. Występują u 75% czarnoskórych osób, 10% u rasy kaukaskiej i u 4% japończyków. Znany również jako linie typu A, linie Voigta, pigmentacyjne linie demarkacyji.

HOWARD PALMER FUTCHER

American-Canadian physician, 1910-2004. fformer member of the faculty of the Johns Hopkins University School of Medicine, executive director of the American Board of Internal Medicine. Palmer graduated from Harvard College and in 1936 earned his medical degree from Johns Hopkins. After Pearl Harbor to join the Navy in 1942. After discharge from the Navy in 1946 he taught medicine at Washington University and became certified in internal medicine in 1947. Palmer loved sailing, fishing, and bird watching.

Amerykańsko-kanadyjski lekarz, 1910-2004. Członek Wydziału na Johns Hopkins University School of Medicine, dyrektor wykonawczy American Board of Internal Medicine. Palmer ukończył Harvard College w 1936 roku i zdobył dyplom w zakresie medycyny w Johns Hopkins. Po ataku na Pearl Harbor wstąpił do Marynarki Wojennej w 1942 roku. Po ukończeniu służby wojskowej w 1946 roku uczył medycyny na Washington University, a w 1947 roku został certyfikowany w zakresie chorób wewnętrznych. Kochał żeglarstwo, wędkarstwo i obserwację ptaków.

Figure 26. Howard Palmer Futcher

REFERENCES

1. Hammett CJ, Stewart PJ, Atherton JJ: The fall and rise of drug-eluting stents. Med J Aust. 2011; 195: 110-101.
2. Ormea F, Depaoli M: [On the relations between nodular cutaneous elasteidosis with cysts and comedones (Favre-Racouchot disease) and cutis rhomboidalis nuchae]. Minerva Dermatol. 1963; 38: 170-176.
3. Griesinger G, Saleh L, Bauer S, Husslein P, Knöfler M: Production of pro- and anti-inflammatory cytokines of human placental trophoblasts in response to pathogenic bacteria. J Soc Gynecol Investig. 2001; 8: 334-340.
4. de Freitas MR, Nascimento OJ, de Freitas MR, Hahn MD: Isolated superficial peroneal nerve lesion in pure neural leprosy: case report. Arq Neuropsiquiatr. 2004; 62: 535-539.
5. Arruda MS, Arruda OS, Astolfi CS, Opromolla DVA: [Fernandez and Mitsuda reactions in patients with leprosy and their contacts]. Hansenol Int. 1985;10: 23-31.
6. Fernandez JMM: Estodio comparativo de la reacción de Mitsuda con las reacciones tuberculinicas. Rev. Argent. Dermatosif. 1939; 23: 425-453.
7. Fernandez JMM: The early reaction induced by lepromin. Int. J. Lepr. 1940; 8: 1-14.

8. Daher EF, Silva GB Jún, Lima RS, Mota RM, Rocha HA, de Abreu KL, et al: Different Patterns in a Cohort of Patients with Severe Leptospirosis (Weil Syndrome): Effects of an Educational Program in an Endemic Area. Am J Trop Med Hyg. 2011; 85: 479-484.
9. Lamden KH: An outbreak of scarlet fever in a primary school. Arch Dis Child. 2011; 96: 394-397.
10. Brzeziński P, Wollina U, Poklękowska K, Khamesipour A, Herrero Gonzalez J.E, Bimbi C, et al: Dermatology eponyms – phenomen / sign –Lexicon (D). N Dermatol Online. 2011; 2: 158-170.
11. World Health Organization WHO. Food and Nutrition Programme. Food Safety Unit. Contaminated food: a major cause of diarrhoea and associated malnutrition among infants and young children. Facts Infant Feed. 1993; 3: 1-4.
12. Reeve LF: Cellulitis, due to infection by Erysipelothrix rhusiopathiae. Nurs Mirror Midwives J. 1950; 91: 313.
13. Parrish JA: Thomas B. Fitzpatrick, MD, PhD (1919-2003). Arch Dermatol 2003; 139:1613.
14. Peña Chavarría A, Goldman L, Saénz-Herrera C, Cordero-Carvajal E: Canities and alopecia in children associated with avitaminosis. JAMA 1946;132: 570-572.
15. Baeder FM, Pelino JE, de Almeida ER, Duarte DA, Santos MT: High-power diode laser use on Fordyce granule excision: a case report. J Cosmet Dermatol. 2010; 9: 321-324.
16. MacKee GM: John Addison Fordyce. Bull N Y Acad Med. 1925; 1: 204–206.
17. Fogagnolo L, Cintra ML, Velho PE: Angiokeratoma of the vulva. An Bras Dermatol. 2011; 86: 333-335.
18. Banerjee S: Reconstruction of facial deformities in leprosy patients. J Indian Med Assoc. 2004; 102: 700-701.
19. Dyer JA: Childhood viral exanthems. Pediatr Ann. 2007; 36: 21-29.
20. Firkin BG, Whitworth JA: Dictionary of Medical Eponyms, second edition, page 127. Parthenon Publishing Group 1996.
21. Scholz H: [When does angina come from scarlet fever?]. Med Monatsschr Pharm. 2007; 30: 343-344.
22. Plaut GS: Dr John Fothergill and eighteenth-century medicine. J Med Biogr. 1999; 7:192-196.
23. Rea TH, Jerskey RS: Clinical and histologic variations among thirty patients with Lucio's phenomenon and pure and primitive diffuse lepromatosis (Latapi's lepromatosis). Int J Lepr Other Mycobact Dis. 2005; 73: 169-188.
24. Rothschild BM, Heathcote GM: Characterization of the skeletal manifestations of the treponemal disease yaws as a population phenomenon. Clin Infect Dis. 1993; 17: 198-203.
25. Hass L: Jean Alfred Fournier (1832-1914). J Neurol Neurosurg Psychiatry. 1998; 65: 373.
26. Gürcan S: [Francisella tularensis and tularemia in Turkey]. Mikrobiyol Bul. 2007; 41: 621-636.
27. Cerný Z: [Tularemia--history, epidemiology, clinical aspects, diagnosis and therapy]. Cas Lek Cesk. 2002; 141: 270-275.
28. Francis E: Landmark article April 25, 1925: Tularemia. By Edward Francis. JAMA. 1983; 250: 3216-3224.
29. Friedlander AH, Scully C: Diagonal ear lobe crease and atherosclerosis: a review of the medical literature and oral and maxillofacial implications. J Oral Maxillofac Surg. 2010; 68: 3043-3050.
30. Scholz-Janotte I, Berndt H: [In memory of Albert Fraenkel (1848-1916)]. Z Arztl Fortbild (Jena). 1992; 86: 67-69.
31. Thyresson N: [Girolamo Fracastoro and the poem Syphilis sive morbus gallicus]. Sydsven Medicinhist Sallsk Arsskr. 1992; 29: 63-75.
32. Banerjee AK: Hieronymus Fracastorius 1483-1553. J R Coll Physicians Lond. 1988; 22: 144.
33. Gibbs NF: What is your diagnosis? Berloque dermatitis. Cutis. 2004 Mar; 156: 181-182.
34. Ronchese S: Standard nomenclature: berlock dermatitis. Arch Dermatol. 1961; 84: 514.
35. Kapoor S, Ghosh V, Dhua A, Aggarwal SK: Cystic hygroma and hirsutism in a child with Catel-Manzke syndrome. Clin Dysmorphol. 2011; 20: 117-120.
36. Mintz S, Velez I: Pigmentary demarcation lines (Futcher lines): an orofacial case. Quintessence Int. 2010; 41: 873-875.
37. Benson JA Jr: Palmer Howard Futcher, M.D. (1910-2004). Trans Am Clin Climatol Assoc. 2005; 116: li-liii.

Copyright by *Brzezinski Piotr et al.* This is an open access article distributed under the terms of the Creative Commons Attribution License, which permits unrestricted use, distribution, and reproduction in any medium, provided the original author and source are credited.