

# Hair breakage caused by straightening products in a young female

Jihad Kassel, Hanane Baybay, Chaymae Jroundi, Sara Elloudi, Zakia Douhi, Fatima-Zahra Mernissi

Department of Dermatology, University Hospital Hassan II, Fes, Morocco

**Corresponding author:** Jihad Kassel, MD, E-mail: kassel.jihad@gmail.com

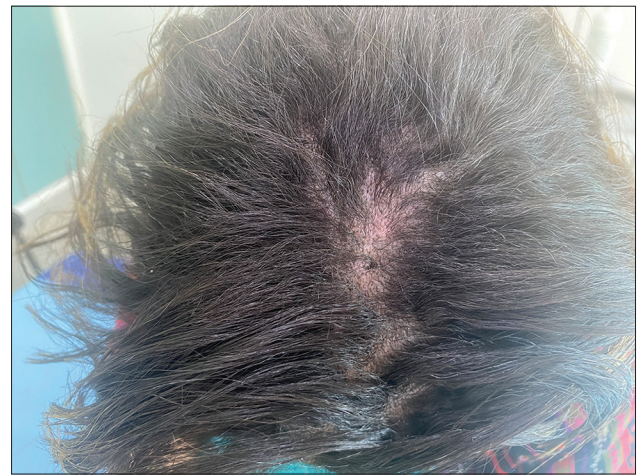In almost all civilizations, the hair bears special importance: it is a synonym of beauty and strength. Having smooth and easy-to-style hair is a constant demand of women and also men. Hair straighteners are highly popular around the world, although they may cause great damage to the hair [1], such as breakage, falling, burns, and eczema [2]. The manifestations of hair breakage caused by straightening may be heterogeneous, ranging from poor hair growth to patchy alopecia. A dermoscopic examination of hairs obtained by a pull test allowed us to diagnose hair breakage in all cases. The hair fragments had no roots, yet rather brush-like tips and swelling along the shaft caused by trichorrhexis nodosa. Central trichoptilosis (longitudinal split in the central part of the shaft) was another common finding [3].

Herein, we report the case of a 34-year-old female patient with no notable pathological history who consulted us for hair loss and pruritus on the scalp three days after the application of a straightening product. On examination, the traction sign was positive in some places, and we also noted erythema on the scalp (Fig. 1) with small vesicles on the frontal edge. A dermoscopic examination revealed an erythematous background with broken, bent hairs on the entirety of the hair (Figs. 2a and 2b). Our patient was administered a shampoo based on corticoids.

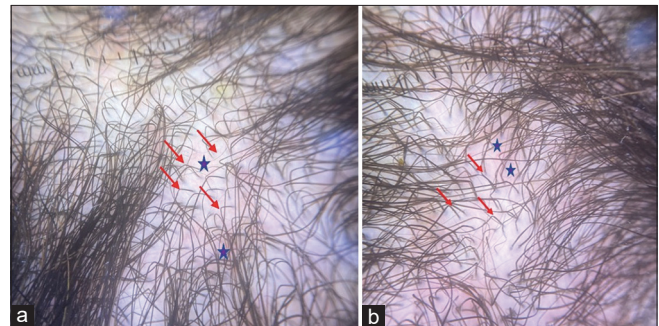
## Consent

The examination of the patient was conducted according to the principles of the Declaration of Helsinki.

The authors certify that they have obtained all appropriate patient consent forms, in which the patients gave their consent for images



**Figure 1:** Clinical picture showing erythema on the scalp.



**Figure 2:** (a) Dermoscopic picture showing an erythematous background (purple asterisk), with broken, bent hairs on the entirety of the hair (red arrows) at the frontal level. (b) Dermoscopic picture showing an erythematous background (purple asterisk), with broken, bent hairs on the entirety of the hair (red arrows) at the vertex.

and other clinical information to be included in the journal. The patients understand that their names and initials will not be published and due effort will be made to conceal their identity, but that anonymity cannot be guaranteed.

**How to cite this article:** Kassel J, Baybay H, Jroundi C, Elloudi S, Douhi Z, Mernissi FZ. Hair breakage caused by straightening products in a young female. Our Dermatol Online. 2023;14(e):e41.

**Submission:** 10.01.2022; **Acceptance:** 03.03.2022

**DOI:** 10.7241/ourd.ourd.2023e.41

## REFERENCES

1. Barreto T, Weffort F, Frattini S, Pinto G, Damasco P, Melo D. Straight to the point: What do we know so far on hair straightening? *Skin Appendage Disord.* 2021;7:265-71.
2. Tennstedt D, Herman A, Lachapelle JM. Adverse effects of hair care in users. *Ann Dermatol Venereol.* 2018;145:521-31.
3. Quaresma MV, Martinez Velasco MA, Tosti A. Dermoscopic diagnosis of hair breakage caused by styling procedures in patients of African descent. *J Am Acad Dermatol.* 2015;72(1 Suppl):S39-S40.

Copyright by Jihad Kassel, et al. This is an open-access article distributed under the terms of the Creative Commons Attribution License, which permits unrestricted use, distribution, and reproduction in any medium, provided the original author and source are credited.

**Source of Support:** Nil, **Conflict of Interest:** None declared.