Case Letter

Acquired non-scarring vertex alopecia in three women revealing trichotillomania: Diagnostic accuracy of trichoscopy

Basma Karrakchou, Amani Fliti, Soumaya Hamich, Nadia Ismaili, Laila Benzekri, Mariame Meziane, Karima Senouci

Dermatology and Venereology Department, Ibn Sina Hospital, Mohammed V University of Rabat, Morocco

Corresponding author: Basma Karrakchou, MD, E-mail: karrakchou.basma@gmail.com

Sir,

Trichotillomania is an obsessive-compulsive disorder affecting generally young women who often deny hair manipulation. It is responsible for polymorphic non-scarring alopecia, causing a diagnostic wavering. Herein, we report three cases of trichotillomania and determine the place of trichoscopy in the diagnosis.

Observation 1: An 18-year-old female consulted for vertex hair loss developing for three months during exams. A physical examination revealed decreased vertex hair density (Fig. 1a) and a negative pull test. Dermoscopy revealed thick hairs irregularly broken at different lengths, flame hairs, black dots, and hair powder (Fig. 1b). The biological assessment was normal (hemoglobin, ferritin, vitamin D, thyroid function, and antithyroid antibodies). Hair manipulation was denied by the patient yet confirmed by her mother. A diagnosis of trichotillomania was established and the patient was referred to psychiatry.

Observation 2: A 20-year-old young female consulted for a ten-year history of vertex hair loss leading to a large patch of alopecia with geometrical borders and variable hair length (Fig. 2a). The scalp palpation was rough as a consequence of short, thick, broken hairs, and the pull test was negative. Trichoscopy revealed several broken hairs with a normal hair diameter, hemorrhagic crusts, coiled hairs, hooked hairs, trichoptilosis, flame hairs, V-sign, black dots, and hair powder (Fig. 2b). The blood assessment was normal. A diagnosis of trichotillomania was established and confirmed by the mother. The patient was referred to psychiatry.

Observation 3: A 58-year-old, postmenopausal female presented with acute alopecia of the vertex occurring one month after scalp surgery. A clinical examination found a large, asymmetric patch of alopecia accentuated on the dominant hand side (Fig. 3a) and with a positive pull test. Dermoscopy, on the one hand, revealed broken hairs at different levels, hemorrhagic crusts, black dots, hair powder, coiled and hook hairs and, on the other, anisotrichia, perifollicular hyperpigmentation, and one hair per pilosebaceous unit (Fig. 3b). The blood assessment was normal. The diagnosis was trichotillomania associated with androgenetic alopecia. The patient was put on local minoxidil while waiting for the trichotillomania to be healed.

Trichoscopy in trichotillomania shows patterns resulting from compulsive hair pulling [1]. Stretching of the hair shafts is responsible for totally or partially curled hairs (coiled and hook hairs). Depending on the strength and direction of hair pulling, we see irregularly broken hairs, some with darker ends (tulip hairs), flame hairs, and split ends (trichoptilosis). Hair shafts fracture at different levels and are responsible for black dots (scalp level of break) and the V-sign (two hair shafts from the same pilosebaceous unit break at the same level). Residual destroyed hair shafts appear as hair powder. Peripilar hemorrhages reveal scalp trauma.

These features establish the diagnosis of trichotillomania when seen together. However, they are not always

How to cite this article: Karrakchou B, Fliti A, Hamich S, Ismaili N, Benzekri L, Meziane M, Senouci K. Acquired non-scarring vertex alopecia in three women revealing trichotillomania: Diagnostic accuracy of trichoscopy. Our Dermatol Online. 2023;14(2):228-229.

Submission: 26.11.2022; **Acceptance:** 31.12.2022

DOI: 10.7241/ourd.20232.29

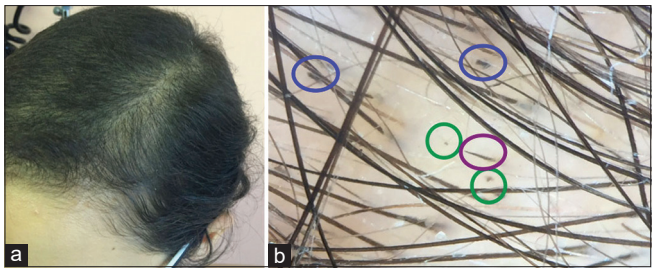

Figure 1: (a) Clinical aspect: diffuse, decreased vertex hair density (patient 1). (b) Trichoscopic aspect: broken hairs (blue circle), flame hair (purple circle), black dots, and hair powder (green circle) with a normal hair diameter and healthy underlying skin.

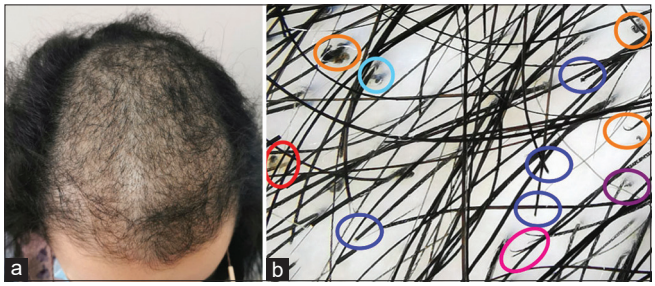

Figure 2: (a) Clinical aspect: large vertex patch of alopecia with geometrical borders and a variable hair length (patient 2). (b) Trichoscopic aspect: irregularly broken hairs (dark blue circle), a hemorrhagic crust (red circle), the V-sign (light blue circle), trichoptilosis (pink circle), a flame hair (purple circle), coiled and hook hairs (orange circle) with thick hairs and normal skin.

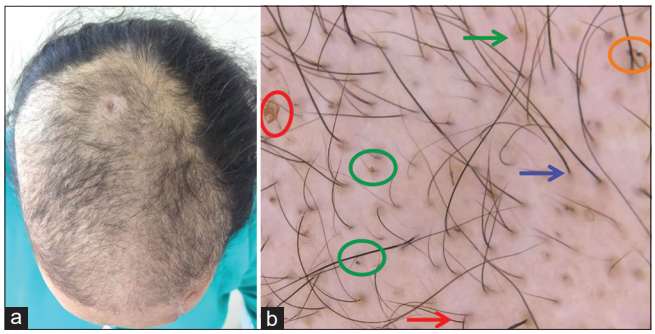

Figure 3: (a) Clinical aspect: large, asymmetrical vertex patch of alopecia more pronounced on the right side, with sharp borders and variability in hair length. A post-surgical scar for a trichilemmal cyst (patient 3). (b) Trichoscopic aspect: a hemorrhagic crust (red circle), coiled hairs (orange circle), black dots, and hair powder (green circle). Patterns of androgenetic alopecia seen: anisotrichia (red arrow), one hair per pilosebaceous unit (blue arrow), and peripilar hyperpigmentation (green arrow).

present simultaneously, nor are they specific [2]. Some are shared with other non-scarring types of alopecia, such as black dots, broken hairs, flame hairs, and tulip hairs in alopecia areata [3]; broken hairs, black dots, and the V-sign in tinea capitis [3]. The diagnosis is then rectified by a negative pull test associated with the five most characteristic trichoscopic signs (hemorrhages, V-sign, hook and coiled hairs, trichoptilosis, and hair powder) [3,4].

Trichotillomania may also be associated with other hair disorders, and the pull test is then positive. It should be considered facing treatment failure in a non-scarring alopecia, and the main trichoscopic patterns should be sought, especially microhemorrhages [4].

Trichoscopy is, thus, a sufficient tool in diagnosing trichotillomania when it shows the five most characteristic patterns associated with a negative pull test. It is also a reliable tool in detecting an added trichotillomania in other hair disorders and should then be systematically performed in alopecia.

Consent

The examination of the patient was conducted according to the principles of the Declaration of Helsinki.

The authors certify that they have obtained all appropriate patient consent forms, in which the patients gave their consent for images and other clinical information to be included in the journal. The patients understand that their names and initials will not be published and due effort will be made to conceal their identity, but that anonymity cannot be guaranteed.

REFERENCES

1. Martín JM, Montesinos E, Cordero P, Gonzalez V, Ramon D. Trichoscopy features of trichotillomania. Pediatr Dermatol. 2019;36:265-7.
2. Kaczorowska A, Rudnicka L, Stefanato CM, Waskiel-Burnat A, Warszawik-Hendzel O, Olszewska M, et al. Diagnostic accuracy of trichoscopy in trichotillomania: A systematic review. Acta Derm Venereol. 2021;101:adv00565.
3. Kinoshita-Ise M, Sachdeva M. Update on trichoscopy: Integration of the terminology by systematic approach and a proposal of a diagnostic flowchart. J Dermatol. 2022;49:4-18.
4. Ise M, Amagai M, Ohyama M. Follicular microhemorrhage: A unique dermoscopic sign for the detection of coexisting trichotillomania in alopecia areata. J Dermatol. 2014;41:518-20.

Source of Support: This article has no funding source,
Conflict of Interest: The authors have no conflict of interest to declare.