Case Report

Acute generalized exanthematous pustulosis due to insect bites: Moroccan observation

Siham Boularbah[1], Meryem Soughi[1], Sabrina Oujdi[1], Kaoutar El Fid[1], Zakia Douhi[1], Sara Elloudi[1], Hanane Bay Bay[1], Fatima Zahra Mernissi[1], Imane Gouzi[2], Layla Tahiri Elousrouti[2], Chbani Laila[2]

[1]Department of Dermatology and Venerology, University Hospital Hassan II, Fez, Morocco, [2]Laboratory of Pathological Anatomy and Cytology, CHU Hassan II, Fez, Morocco

Corresponding author: Siham Boularbah, MD, E-mail: sihamboularbah1902@gmail.com

ABSTRACT

Acute generalized exanthematous pustulosis (AGEP) is the most common generalized pustular rash. It is a delayed immunological reaction involving cellular immunity and is characterized by the sudden, simultaneous onset of high fever and scarlatiniform sheet erythema, which, in several hours, is covered with numerous pustules with a lactescent content, non-follicular, sterile, predominant on the face, trunk, and folds. It regresses in less than fifteen days after stopping the causative agent giving way to diffuse desquamation. Several incriminating factors in the triggering of this reaction, in particular, at the top of the list, taking medication, a viral (enterovirus) or bacterial (streptococcal) infection, yet its occurrence following an insect bite has been exceptionally reported in the literature. The diagnosis is established according to clinical and histological criteria. Herein, we report the case of a young Moroccan female with generalized AGEP related to insect bites.

Key words: Acute Generalized Exanthematous Pustulosis; EuroSCAR; Insect Bites

INTRODUCTION

Acute generalized exanthematous pustulosis is a severe drug eruption, often occurring after delayed drug-induced sensitization [1,2]. It is more rarely linked to a viral infection, a toxin, or a food allergen. Its occurrence following an insect bite has exceptionally been reported in the literature. Herein, we report an observation of PEAG appearing in a Moroccan female, a victim of an insect bite.

CASE REPORT

A thirty-year-old female patient with no particular history, from a rural area, was hospitalized at the dermatology department in July for an acute rash with pinhead-sized pustules.

On questioning, the patient reported an insect bite sensation 24 hours before the eruption and reported the presence of insects in her habitat. No oral or topical medication was reported.

A clinical examination revealed pinhead-sized pustules on an erythematous, edematous base with a predominance in the folds (axillary, inguinal, and submammary areas) and the trunk and limbs (axillary, inguinal, and submammary areas) (Figs. 1a and 1b), a skin surface of 60%, and a well-rounded detachment on the left side of the neck in relation to the site of the insect bite (Fig. 1c). The rest of the somatic examination was normal, apart from a fever at 38.5°C. A complete blood count revealed neutrophilic polynucleosis at 14,000/mm^3 and hypereosinophilia at 900/mm^3. Bacteriological samples were negative.

How to cite this article: Boularbah S, Soughi M, El Fid K, Oujidi S, Douhi Z, Elloudi S, Bay Bay H, Mernissi FZ, Gouzi I, Elousrouti LT, Laila C. Acute generalized exanthematous pustulosis due to insect bites: Moroccan observation. Our Dermatol Online. 2023;14(2):184-186.

Submission: 07.09.2022; **Acceptance:** 10.12.2022

DOI: 10.7241/ourd.20232.12

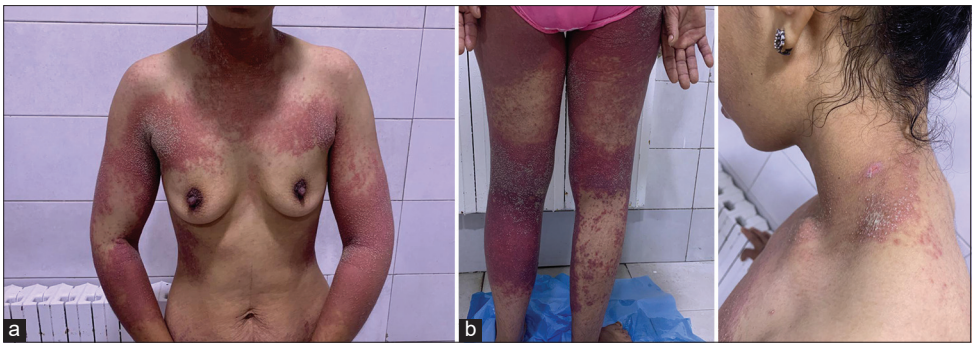

Figure 1: (a-b) An erythematous, edematous rash covered with pinhead pustules involving the trunk and major folds. (c) A well-rounded detachment on the left side of the neck in relation to the site of the insect bite.

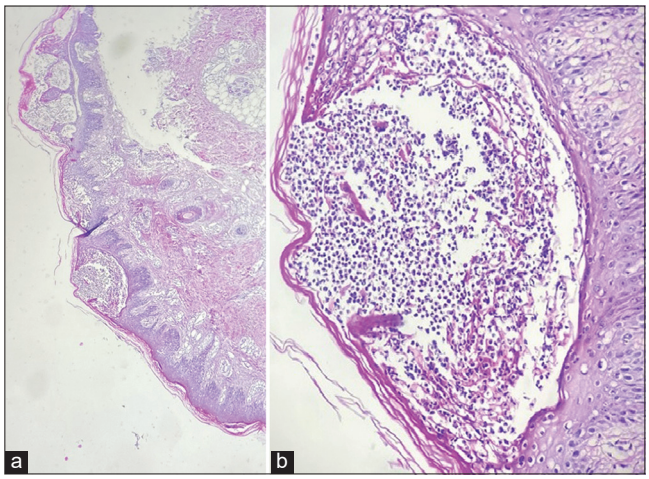

Figure 2: Histological image: H&E staining on the left (a) (G x 40) and on the right (b) (G x 200) of the skin biopsy. Multilocular subcorneal pustules associated with an inflammatory infiltrate made from PNN.

A biopsy from a pustule was taken, returning in favor of intraepidermal or subcorneal pustules accompanied by dermal edema, and neutrophilic and/or perivascular, eosinophilic infiltrate (Figs. 2a and 2b). The patient was bathed daily with surgras soap and an antihistamine. The evolution was marked by desquamation in two days, with a normalization of the complete blood formula. The diagnosis of PEAG was retained.

DISCUSSION

Acute generalized exanthematous pustulosis is an acute pustular rash, the usual causes of which are the ingestion of medications and/or infection [3,4]. Cases of AGEP secondary to insect bites are exceptionally reported, probably because of the difficulty in establishing a causal relationship. These are isolated observations of several cases of localized PEAG, such as localized acute exanthematous pustulosis after a mosquito bite in a patient treated for breast cancer [5] or a small series of two or three patients with generalized PEAG following a spider bite [6], whose diagnosis was retained according to the EuroSCAR criteria and the presence of the insect bite site with the absence of other etiologies.

In our observation, the diagnosis of AGEP was also certain according to the EuroSCAR criteria. Indeed, the onset was brutal and the clinical picture was typical. The fever was constant, accompanied by asthenia. The evolution was marked by post-pustular desquamation with rapid healing. Arguments in favor of AGEP secondary to an insect bite included the presence of a lesion characteristic of an insect bite, the 24-to-48-hour delay between the bite and the eruption, and the absence of other classic causes of AGEP.

The insect bite generally occurs in the evening, during sleep in the hot season, it may sometimes be responsible for fatal envenomation explained by the blood diffusion of venom [7].

Faced with the usual spontaneous regression of AGEP, no treatment was recommended other than local care in order to avoid infection of cutaneous origin, in particular, at the level of the bite. Local or systemic corticosteroid therapy could reduce inflammatory signs yet there is no established consensus on its use [8].

CONCLUSION

In conclusion, these clinical cases and the rare cases reported in the literature suggest adding insect bites to the list of possible etiologies of AGPE. The immunopathological mechanisms involved in this reaction remain to be determined.

Consent

The examination of the patient was conducted according to the principles of the Declaration of Helsinki.

The authors certify that they have obtained all appropriate patient consent forms, in which the patients gave their consent for images and other clinical information to be included in the journal. The patients understand that their names and initials will not be published and due effort will be made to conceal their identity, but that anonymity cannot be guaranteed.

REFERENCES

1. Bhat YJ, Akhtar S, Muzaffar A, Iffat H, Rohi W. Etiopathological and clinical study of acute generalized exanthematous pustulosis: Experience from a tertiary care hospital in north India. Indian Dermatol Online J. 2020;11:391-7.
2. Jinwoo L, Alyson E, Kanade S. Acute generalized exanthematous pustulosis. JAMA Dermatol. 2021;157:589.
3. Kouotou EA, Maff o N, Degboe B, Mendouga Menye CR, Défo D, Kouassi A, et al. Acute generalized exanthematous pustulosis due to Phloroglucinol (Spasfon®): A case at the Teaching Hospital of Yaounde, Cameroon. Our Dermatol Online. 2021;12(Supp. 2):6-10.
4. Maghfour S, Youssef M, Hadhri R, Lahouel I, Soua Y, Korbi M, et al. Acute localized exanthematous pustulosis: A novel side effect of piroxicam. Our Dermatol Online. 2022;13:65-6.
5. El Mabrouk S, Mohamed M, Hadhri R, Zili JE. An acute localized reaction following a mosquito bite in a breast cancer treated patient. Clin Case Rep. 2022;10:e5954.
6. Lahouel M, Mokni S, Denguezli M. Acute localized exanthematous pustulosis induced by a spider bite. Am J Trop Med Hyg. 2020;103:937-8.
7. Stoevesandt J, Sturm GJ, Bonadonna P, Oude Elberink JNG, Trautmann A. Risk factors and indicators of severe systemic insect sting reactions. Allergy. 2020;75:535-45.
8. Safa I, Ines L, Noureddine L, Meriem J, Manel N, Belhajali H, et al. Acute localized exanthematous pustulosis: Clinical features, pathophysiology, and therapy. Dermatol Ther. 2021;34:e15087.

Source of Support: This article has no funding source.

Conflict of Interest: The authors have no conflict of interest to declare.