Clinical Image

Primary squamous cell carcinoma of the axilla: An exceptional location

Dassouli Ryme[1], Sara Elloudi[1], Jroundi Chaymae[1], Hanane Baybay[1], Zakia Douhi[1], Khaoula Abdellaoui[2], Laila Chbani[2], Laila Tahiri[2], Nawal Hammas[2], Hinde Elfatemi[2], Fatima Zahra Mernissi[1]

[1]Department of Dermatology, University Hospital Hassan II, Fes, Morocco, [2]Department of Anatomopathology, University Hospital Hassan II, Fes, Morocco

Corresponding author: Dassouli Ryme, MD, E-mail: dassouliryme@gmail.com

An 83-year-old female presented with a two-year history of a slowly growing, cauliflower-like tumor in the right axilla, limiting the mobility of the right arm. The patient denied any type of trauma or chronic inflammation in this area. A physical examination revealed an exophytic, ulcerating tumor with an infiltrated base, approx. 8 cm in diameter. The surface of the tumor was covered with hemorrhagic crusts and scales with a foul-smelling discharge (Fig. 1). The lymph node areas were free. No other anomalies were detected during the somatic examination. An anatomopathological study revealed a well-differentiated, keratinizing squamous cell carcinoma (Fig. 2). There was no metastasis on lymph node ultrasound, no primary SCC on fibroscopy, and no breast tumor on echomammography. An injection scan showed no visceral tumors. The patient underwent surgical resection with 1 cm margins. After a three-year follow-up period, no recurrence was observed.

Figure 1: Clinical picture showing axillary, ulcerating, cauliflower-like tumor with crusts and scales.

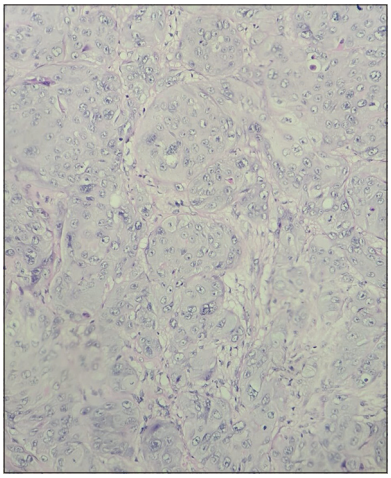

Figure 2: Tumor proliferation of large, irregular, polygonal cells with cytonuclear atypia and signs of keratinization.

Cutaneous squamous cell carcinoma (cSCC) represents the second most frequent skin tumor. It accounts for 20% of skin cancers and results in one million cases [1]. CECs may be responsible for local, regional, or distant metastases, leading to death. Lymphatic dissemination is responsible for 80% of metastatic localizations. cSCC presents itself as a red, scaly plaque or ulcerating tumor usually in sun-exposed areas, often in the hands, chest, or face. We highlight that the axillary area suggests the secondary localization of a visceral, digestive, breast, or another epidermoid carcinoma, requiring a search for the

How to cite this article: Ryme D, Elloudi S, Chaymae J, Baybay H, Douhi Z, Abdellaoui K, Chbani L, Tahiri L, Hammas N, Elfatemi H, Mernissi FZ. Primary squamous cell carcinoma of the axilla: An exceptional location. Our Dermatol Online. 2022;13(e):e8.

Submission: 13.08.2021; **Acceptance:** 23.01.2022

DOI:10.7241/ourd.2022e.8

primary tumor [2,3]. We report the first case of primary axillar cSSC with no other primitive tumor.

Consent

The examination of the patient was conducted according to the principles of the Declaration of Helsinki.

The authors certify that they have obtained all appropriate patient consent forms, in which the patients gave their consent for images and other clinical information to be included in the journal. The patients understand that their names and initials will not be published and due effort will be made to conceal their identity, but that anonymity cannot be guaranteed.

REFERENCES

1. Waldman A, Schmults C. Cutaneous squamous cell carcinoma. Hematol Oncol Clin North Am. 2019;33:1-12.
2. Assaf C, Steinhoff M, Petrov I, Geilen CC, de Villiers EM, Schultz-Ehrenburg U, et al. Verrucous carcinoma of the axilla: Case report and review. J Cutan Pathol. 2004;31:199-204.
3. Goh A, Howle J, Hughes M, Veness MJ. Managing patients with cutaneous squamous cell carcinoma metastatic to the axilla or groin lymph nodes. Australas J Dermatol. 2010;51:113-7.

Source of Support: Nil, **Conflict of Interest:** None declared.