

A giant skin tag of the buttock

Samia Mrabat¹, Hanane Baybay¹, Aida Oulehri¹, Zakia Douhi¹, Sara Elloudi¹, Fatima Zahra Mernissi¹, Amal Douida², Layla Tahri Elousrouti², Hinde El Fatemi²

¹Department of Dermatology, University Hospital Hassan II, Fes, Morocco, ²Department of Anatomopathology, University Hospital Hassan II, Fes, Morocco

Corresponding author: Samia Mrabat, MD, E-mail: samiamrabat91@gmail.com

Skin tags, also called acrochordon, are one of the most common benign skin tumors. They present as small, soft, skin-colored to dark brown, sessile or pedunculated papilloma [1]. They are most commonly seen on the head and neck, with few reports in other locations [2]. Skin tags range in size from several millimeters to, rarely, many centimeters. Unless irritated or infarcted, skin tags are more of a cosmetic issue than a clinical concern and can easily be removed by excision, electrodesiccation or cryosurgery [3]. We report the case of a diabetic woman who had a giant skin tag on her right buttock.

A 45-year-old woman presented with a painless mass on the buttock area, which developed to large proportion over 10 years (Fig. 1). The lesion became slightly painful a couple of months ago. Clinical examination found a soft, pedunculated mass, of 7cm/ 6 cm with an inflamed base. She received a surgery to excise the huge mass completely because of the aesthetic demand as well as the discomfort. Histopathology examination showed hyperkeratosis, acanthosis and loosely arranged collagen fibres (Fig. 2). Based on the clinical manifestations and histopathological description, the final diagnosis was giant skin tag of the buttock. No recurrence was seen after.

Consent

The examination of the patient was conducted according to the principles of the Declaration of Helsinki.

The authors certify that they have obtained all appropriate patient consent forms, in which the patients gave their consent for images

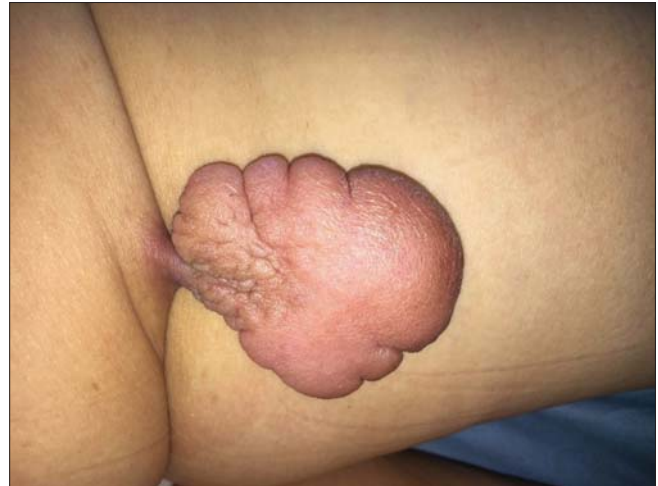

Figure 1: An erythematous pedunculated mass with an inflamed base in the buttock measuring 7 cm/6 cm.

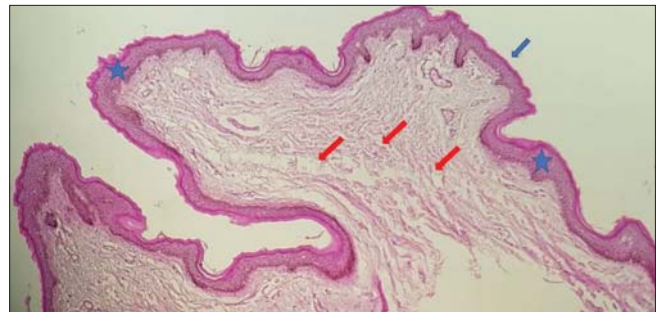


Figure 2: Histology showing hyperkeratosis (Blue arrow) ; acanthosis (Blue star) and loosely arranged collagen fibres (Red arrows).

and other clinical information to be included in the journal. The patients understand that their names and initials will not be published and due effort will be made to conceal their identity, but that anonymity cannot be guaranteed.

How to cite this article: Mrabat S, Baybay H, Oulehri A, Douhi Z, Elloudi S, Mernissi FZ, Douida A, Elousrouti LT, El Fatemi H. A giant skin tag of the buttock. Our Dermatol Online. 2021;12(e):e32.

Submission: 10.12.2020; **Acceptance:** 09.03.2021

DOI: 10.7241/ourd.2021e.32

REFERENCES

1. Yuksel ME, Tamer F. A giant skin tag of the scrotum and verruca anogenitalis. *Our Dermatol Online*. 2017;8:239-40.
2. Mohamed M, Korbi M, Hadhri R, Akkari H, Hajjaji A, Youssef M, et al. A huge fibro epithelial polyp of the vulva with myxoid stroma in Tunisian nulliparous woman. *Our Dermatol Online*. 2014;5:409-11.
3. Ghosh SK, Bandyopadhyay D, Chatterjee G, Bar C. Giant skin tags on unusual locations. *J Eur Acad Dermatol Venereol*. 2009;23:233.

Copyright by XXXXXXXXXXXX, et al. This is an open access article distributed under the terms of the Creative Commons Attribution License, which permits unrestricted use, distribution, and reproduction in any medium, provided the original author and source are credited.
Source of Support: Nil, **Conflict of Interest:** None declared.