

Subungual exostosis associated with an acquired digital fibrokeratoma of the thumb

Maouni Safae, Lakhmiri Myriam, Meziane Mariame, Ismaili Nadia, Senouci Karima

Department of Dermatology-Venereology, Ibn Sina University Hospital, Mohammed V University, Rabat, Morocco

Corresponding author: Dr. Maouni Safae, E-mail: maouni.safae88@gmail.com

Sir,

Subungual exostosis is a benign osteocartilaginous tumor that occurs in 70 to 80% of cases in the big toe of teenager or young adult. First described by Dupuytren in 1847. Its appearance varies according to its location and age.

A 52 year-old-man, follow-up for neurofibromatosis type 1, presented with a painless periungual nodule of the right thumb, gradually increasing in size over several years (Fig. 1). In dermoscopy, a proximal white area and yellow distal appearance with hyperkeratosis were visible (Fig. 2). X- Ray examination of the right thumb showed a bone outgrowth of distal phalanx (Fig. 3). Surgical removal of the tumour has been performed and histologic examination was consistent with fibrokeratoma, showing an epidermal hyperkeratosis with dermal fibroblasts and collagen bundles.

Cases of subungual exostosis of the fingers are uncommon and described essentially on the thumb of the dominant hand. They are about 1.5 times more in women than in men. Unlike other exostoses, they appear and continue to grow after skeletal maturity (50% of cases in the second or third decade). The etiology is unknown even if a phenomenon of enchondral ossification or peri-ungual soft tissue, secondary to trauma or chronic inflammation is mentioned. Starnes et al. reported several cases involving a balanced translocation t (X; 6).

The association of digital fibrokeratoma and subungual exostosis is unusual, it has been described by Cogrel in 2016 [1]. Both situations may be occur as a periungual

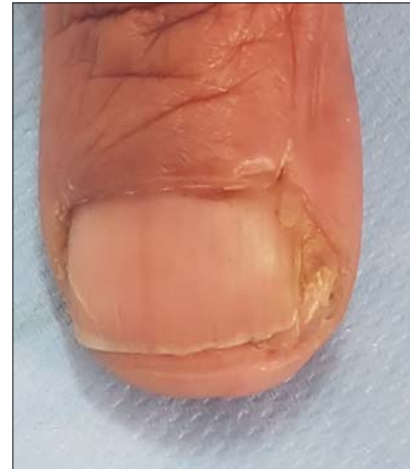

Figure 1: Periungual nodule of the right thumb.

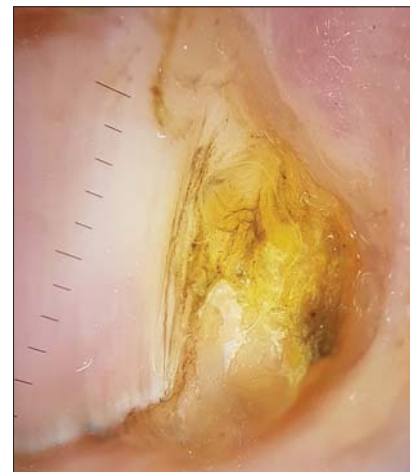


Figure 2: Dermoscopy showing a proximal white area and yellow distal appearance with hyperkeratosis ((DermLite DL4, polarized; original magnification: $\times 10$).

nodule and can be favoured by trauma [2], which explains the usual location on the right toenail. In dermoscopy, hyperkeratosis and yellow appearance have

How to cite this article: Safae M, Myriam L, Mariame M, Nadia I, Karima S. Subungual exostosis associated with an acquired digital fibrokeratoma of the thumb. Our Dermatol Online. 2020;11(e):e177.1-e177.2.

Submission: 11.12.2019; **Acceptance:** 17.02.2020

DOI: 10.7241/ourd.2020e.177

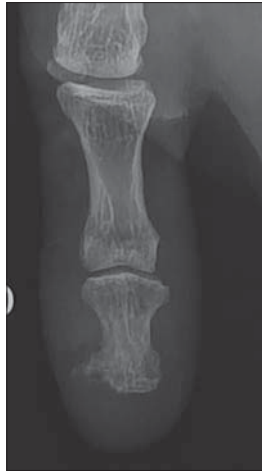

Figure 3: X- Ray examination of the right thumb showing the exostosis.

been described in both conditions [3], corresponding to epidermal hyperkeratosis in histology, the proximal white area observed in fibrokeratoma represent the dermal fibroblasts with collagen bundles.

The particularity of our observation lies in the association of two benign tumours on a specific genetic field of neurofibromatosis type I. Dermoscopy as a non-invasive technique can guide the diagnosis in these doubtful cases.

Consent

The examination of the patient was conducted according to the Declaration of Helsinki principles.

The authors certify that they have obtained all appropriate patient consent forms. In the form the patient(s) has/have given his/her/their consent for his/her/their images and other clinical information to be reported in the journal. The patients understand that their names and initials will not be published and due efforts will be made to conceal their identity, but anonymity cannot be guaranteed.

REFERENCES

1. Cogrel O. Excision of a subungual exostosis associated with a fibrokeratoma of the proximal nail matrix of the thumb. *Ann Dermatol Venercol.* 2016;143:492-3
2. Cohen H, Frank S et al. Subungual exostoses. *Arch Dermatol.* 1973;107:431-2
3. Salim S, El Meknassi I, Znati K, Meziane M. Acquired unguinal fibrokeratoma simulating supernumerary digit: dermoscopic analysis of three cases. *J Clin Exp Dermatol.* 2019;10:493.

Copyright by Maouni Safae, et al. This is an open access article distributed under the terms of the Creative Commons Attribution License, which permits unrestricted use, distribution, and reproduction in any medium, provided the original author and source are credited.
Source of Support: Nil, **Conflict of Interest:** None declared.