Volume 10, Number 4 October 2019
p. 325 - 416
Issue online since Thursday October 03, 2019

ISSN: 2081-9390
DOI: 10.7241/ourd

Our Dermatology Online

www.odermatol.com

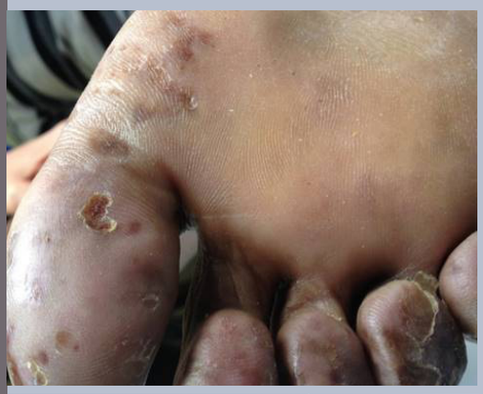

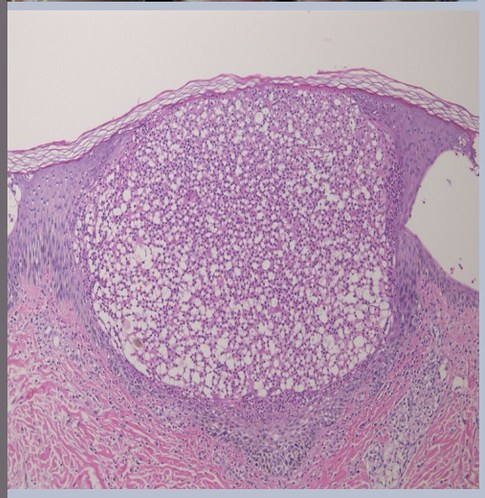

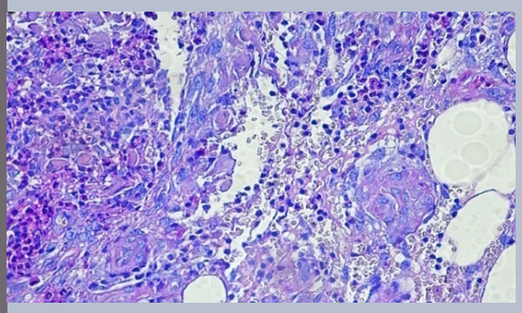

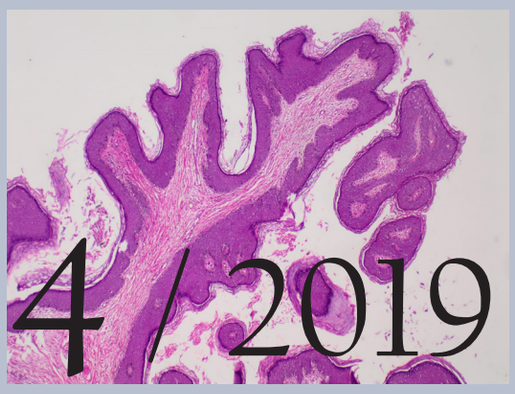

4 / 2019

Editorial Pages

e-ISSN: 2081-9390
DOI: 10.7241/ourd

Quarterly
Our Dermatol Online

published since 01/06/2010 years

www.odermatol.com

Indexed in:

Universal Impact Factor for year 2012 is = 0.7319
system of opinion of scientific periodicals INDEX COPERNICUS (8,69)
(Academic Search) EBSCO
(Academic Search Premier) EBSCO
MNiSW (kbn)-Ministerstwo Nauki i Szkolnictwa Wyższego (7.00)
DOAJ (Directory of Open Acces Journals)
Geneva Foundation for Medical Education and Research (GFMER), Google Scholar, Open J-Gate, NewJour,
International Committee of Medical Journal Editors (ICMJE), Genamics JournalSeek, Hinari,
Bielefeld Academic Search Engine (BASE), WorldCat, e -journal, WorldWideScience.org, National Science Library,
LibSearch, Sciencegate, Virtual Science Library (VSL), Wanfang Data, COnnecting REpositories (CORE),
CAB Abstracts, Global Health, Journal Indexed in Directory of Research Journals Indexing,
OAIster: The Open Access Initiative, OAJSE - Open Access Journals Search Engine, Scirus

Previous website:	issue 1.2010	www.ndermatol.like.pl
	since issue 2.2010 to issue 3.2011	www.odermatol.like.pl
	since issue 4.2011	www.odermatol.com
Previous shortcut:	since issue 1.2010 to issue 3.2011	N Dermatol Online
	since issue 4.2011	Our Dermatol Online

Editorial Board

Contents

Contents

Original Article

Nail alterations in patients affected by endemic pemphigus foliaceus in el Bagre, Colombia

Ana Maria Abreu Velez[1], Yulieth Alexandra Upegui-Zapata[2], Carlos Andres Valencia-Yepes[3], Eduardo Upegui-Quiceño[4], Alejandra Maria Jiménez-Echavarria[4], César Daniel Niño-Pulido[5], Bruce R Smoller[6,7], Michael S. Howard[1]

[1]Georgia Dermatopathology Associates, Atlanta, Georgia, USA, [2]PECET, PhD Student Pharmaceutical Sciences, Medical Research Institute, School of Medicine, University of Antioquia, Medellin, Colombia, South America, [3]Master student, Department of Education, University of Antioquia, Medellin, Colombia, South America, [4]Pecet Group, University of Antioquia, Medellin, Colombia, South America, [5]Cardiology Resident, CES University, Medellin, Colombia, South America, [6]Department of Pathology and Laboratory Medicine, NY 14642, USA, [7]Department of Dermatology, University of Rochester School of Medicine and Dentistry, NY 14642, USA

Corresponding author: Ana Maria Abreu Velez, MD PhD, E-mail: abreuvelez@yahoo.com

ABSTRACT

Background: We have characterized a new variant of endemic pemphigus foliaceus in El Bagre (El Bagre-EPF) (AKA pemphigus Abreu-Manu) and surrounding municipalities. Herein, we describe nail alterations in several patients affected by this disease. In the pre-steroid era, patients with endemic pemphigus foliaceus (EPF), especially in Brazil where the disease is known as fogo selvagem (FS), were described to have some nails changes including the Viera's sign (yellowish of the nail). In this study, we have attempted to describe a range of nail alterations in patients affected by El Bagre-EPF. **Methods:** A case-controlled study was conducted where 40 cases and 40 controls were evaluated for nail changes. A clinical exam was performed in the cases and in a series of control patients from the same geographic region who were matched by age, gender and work activities. Gram stains and cells cultures for fungus and bacteria were done on affected nails. **Results:** In 25 chronic patients (affected for more than two decades) presented with toenail alterations. These changes included change of color nail (yellowish) (Viera sign), atrophy, dystrophy, chronic paronychia, onycholysis, nail bed erosion, subungual hyperkeratosis and trachyonychia. All of these findings were over-represented in patients compared with control population ($p < 0.05$). Cell cultures and gram stains were negative in all study participants. **Discussion:** Chronic patients have nail damage, maybe due to the presence of chronic inflammatory process affecting the nail bed cell, matrix, and/or the nail fold cells junctions.

Key words: Nails; Endemic pemphigus foliaceus in El Bagre; Autoimmunity

INTRODUCTION

Pemphigus foliaceus (PF) is an autoimmune skin disorder characterized by the loss of intercellular adhesion of keratinocytes in the upper parts of the epidermis (acantholysis), resulting in the formation of superficial blisters [1,2]. It has an endemic forms, and previously, we described a new variant of endemic pemphigus foliaceus (EPF) in El Bagre, Colombia (El Bagre-EPF), (AKA pemphigus Abreu-Manu). It is an autoimmune disease presenting in a circumscribed geographic area with genetic and environmental factors influencing its pathogenesis [1]. This new variant, El Bagre-EPF, occurs in a gold-mining region; it predominantly affects males between 30 and 60 years of age, as well as a few post-menopausal females [1-8]. El Bagre-EPF patients demonstrate complex clinical, epidemiological and immunopathologic features, differing from Fogo selvagem and the Tunisian EPF [1-8]. El Bagre-EPF patients have polyclonal

How to cite this article: Abreu Velez AM, Upegui-Zapata YA, Valencia-Yepes CA, Upegui-Quiceño E, Jiménez-Echavarria AM, Niño-Pulido CD, Smoller BR, Howard MS. Nail alterations in patients affected by endemic pemphigus foliaceus in el Bagre, Colombia. Our Dermatol Online. 2019;10(4):325-328.

Submission: 02.05.2019; **Acceptance:** 05.07.2019

DOI: 10.7241/ourd.20194.1

autoantibodies directed not only to epidermal cell junctions, but also to the cell junctions in the skin appendices, their neurovascular bundles and to mesenchymal-endothelial cell junctions [1-8]. The main laboratory findings found in El Bagre-EPF patients include autoantibodies to multiple cell junctions in the skin, and in one third of the patients against cells junctions in multiple organs [1-8]. A subclinical oral involvement [9], and in about one third of the patients, we discovered autoantibodies that appeared to be directed against the optic nerve envelope and its cell junctions [10], to cutaneous nerves and receptors [11], to the cell junctions of the cardiovascular system including its conductive system [12-14], and to cell junctions within the kidney [15]. In this study, we investigated nail abnormalities in patients affected by El Bagre-EPF as reported in the old Portuguese literature in patients affected by FS.

METHODS

The study was approved by a human quality assurance review board at the hospital in El Bagre, and all participants provided signed informed consent. We performed a case–controlled study of 40 patients with El Bagre-EPF and 40 healthy controls from the endemic area, matched by age, gender, race, demographics, comorbidities, and living and work activities. All subjects were evaluated clinically for the presence of nail alterations. The clinical examination was done independently by two board-certified dermatologists. Bacteriological and mycological studies were performed.

The majority of these patients were not included in our initial description of EPF [1-9]. Only four of the patients originally studied were still alive at the time of this study. Each year, there is a prevalence of around 4–6 new patients, but also 3–4 deaths/year, creating a steady prevalence of the disease endemicity [1-9].

We included only patients who fulfilled the complete diagnostic criteria for El Bagre-EPF: including: clinical and epidemiological features as previously described [1-9], residence in the endemic area[1-9], serum displaying intercellular staining between keratinocytes by direct immunofluorescence (DIF) and to the basement membrane zone (BMZ) of the skin by either DIF or by indirect immunofluorescence (IIF), using fluorescein isothiocyanate (FITC) conjugated monoclonal antibodies to IgG and/or to IgG4, as described previously [1-9]. The patients also must have serum reactivity against desmoglein 1 (Dsg1) and plakin molecules using immunoblotting (IB) [7,8]. The patient's serum should also immunoprecipitated a Concanavalin A affinity-purified 45 kDa fragment of Dsg1 [1-9]. The final diagnostic criteria are that the patients must show positive for autoantibodies to pemphigus foliaceus antigens by ELISA [9]. All the patients and controls from the endemic area were tested by the same techniques.

For ethical reasons, we did not take biopsies because the patients have to walk in the jungles, and work inside dirty rivers and creeks and biopsies with open shoes and a biopsy would increase their risk for overt infection especially, in the toenails of the lower limbs.

Direct Microscopy, Nail Stain and Mycology as Well Bacterial Studies

Before obtaining a specimen, the nails were clipped and cleansed with an alcohol swab to remove bacteria and debris. We studied for the presence of dermatophytes such as *Trichophyton rubrum* (T. rubrum), T. *interdigitale* (tinea unguium), for yeasts infections such as *Candida albicans* and for molds, especially *Scopulariopsis brevicaulis* and Fusarium species. We test for them using the standard 20% potassium hydroxide solution (KOH) technique. We clipped the nails from crumbling tissue at the end of the nail. The discolored surface of the nails was also scraped off. The nail debris was scooped out from under the nails for the culture.

Statistical Analysis

We used the Fisher exact test to compare two nominal variables (e.g. positive and negative presence of any nail alteration). We also compared the differences between patient cases and controls. $p < 0.05$ with 95% CI (or better) was considered statistically significant. For all statistical analyses, we used the software GraphPad QuickCalcs (GraphPad Software Inc., La Jolla, CA, USA).

RESULTS

The toenails were involved in 25/40 El Bagre-EPF and the changes in the nails were seen in patients with the chronic form of the disease ($p < 0.05$). Acute patients suffering El Bagre-EPF for less than six months showed no alterations. No patients hand finger

nails were affected ($p < 0.05$). The more common nail alterations included change of color yellowish (Viera's sign) (25/40) ($p < 0.05$). This yellowish stain resembles the one seen as if dipped in iodine, Vieira's sign). None of the controls presented with the Viera's sign. Subungual hyperkeratosis was also very common 20/40) (Fig. 1), and was often associated with distal onycholysis (18/40) ($p < 0.05$). In 2/40 controls that had psoriasis, distal onycholysis was also observed (Fig. 1). Other toenails alterations included paronychia, onychorrhexis, onychatrophia in some areas of the area near the nail cuticle, and onychomadesis (most were often seen together) (18/40) in El Bagre-EPF patients, and no such changes were seen in controls. Onychogryphosis (nail thickening and scaling under the nail), common in the elderly, was seen equally in cases and controls (10/40) (Fig 1).

Direct Microscopy, Nail Stain and Mycology as Well Bacterial Studies

Direct microscopy, bacterial and fungal cultures were negative, except in one El Bagre-EPF patient who presented T rubrum in his foot toe nail and was treated accordingly.

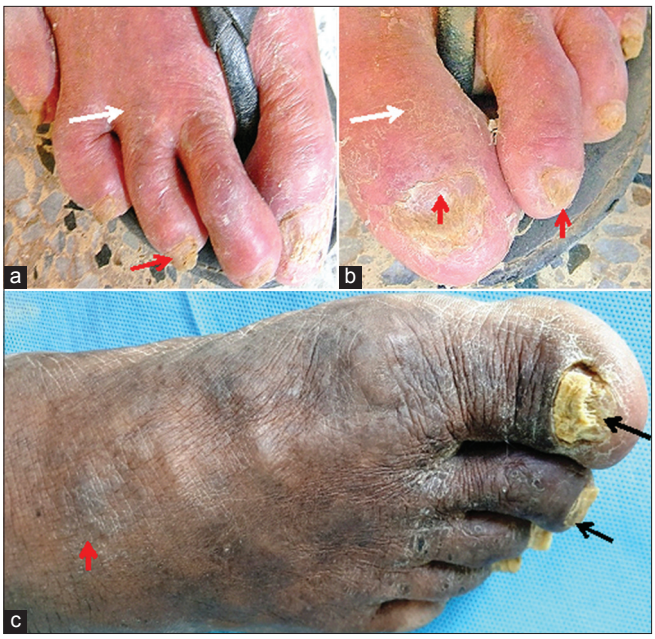

Figure 1: (a-c) Distal onycholysis, in b, onychatrophia in the area near the nail cuticle resembling alterations seen in nail-patella syndrome; c, distal subungual onychomycosis of the great toe nail and dystrophic alterations with ridges, pits, and/or triangular lunulae, subungual hyperkeratosis, with some dystrophy. (In Figure 1a, and 1b the white arrows pointed to a healed blister with some desquamation. The red toe nail arrow in a, shows abnormal growth of the small nail; In figure 1b, pointed in the large toe to a proximal depression of the nail, possibly due to the subcorneal blisters).

DISCUSSION

Involvement of the nail unit in pemphigus is believed to be uncommon, especially in pemphigus foliaceus (PF) [16-18]. In this study, we found that in patients with a chronic El Bagre-EPF variant, the toenails are altered as described by the old Portuguese literature in patients affected by FS. We speculate that the cell junctions are targets within the nails in El Bagre-EPF patients, and are likely damaged by the autoantibodies; however, this is just speculation because for ethical reasons we did not perform biopsies. The can speculate that the toenails were affected because the continue trauma that these nails embrace due to the outside working activities of these patients often using open shoes. The autoantibodies, the continue inflammation and the trauma can make the toenails more prone for the clinical findings we observed. We were not able to determine the cause of the Viera's sign in this study.

With regards to the putative cause of the chronic paronychia we can speculate it to be a result of acantholysis of the lateral nail fold and the chronic inflammation in the adjacent dermis. With regards to the onychomadesis, we hypothesize that this may be the result of inhibition of normal nail plate growth and development; alternatively, the formation of blisters underneath the nail may result in detachment of the nail plate.

Unknown etiologies, predisposing factors and discrepancies evident in the current literature suggest that further investigation of endemic pemphigus foliaceus of the nail may result in additional clinical findings and may contribute to our understanding of the extent of the disease.

CONCLUSION

Our findings indicate that patients affected by El Bagre-EPF demonstrate significant toenail findings, especially in chronic cases. We suggest that the nails in the patients affected by other variants of EPF including FS and the Tunisian EPF need to be study.

Abbreviations

Endemic pemphigus foliaceus (EPF), endemic pemphigus foliaceus in El Bagre (El Bagre-EPF), fogo selvagem (FS), hematoxylin and eosin (H&E), direct and indirect immunofluorescence, (DIF, IIF), base

membrane zone (BMZ), intercellular stain between keratinocytes (ICS), fluorescein isothiocyanate (FITC), 4',6-diamidino-2-phenylindole (DAPI), desmoglein 1 (Dsg1).

Statement of Human and Animal Rights

None animal studies were perform.

Statement of Informed Consent

Informed consent was obtained from all patients for being included in the study. All procedures followed were in accordance with the ethical standards of the responsible committee on human experimentation (institutional and national) and with the Helsinki Declaration of 1975, as revised in 2008.

REFERENCES

1. Abreu-Velez AM, Valencia-Yepes CA, Upegui-Zapata YA, Upegui-Quiceno E, Mesa-Herrera NR, Velazquez-Velez JE, Howard MS. Patients with a new variant of endemic pemphigus foliaceus have autoantibodies against arrector pili muscle, colocalizing with MYZAP, p0071, desmoplakins 1 and 2 and ARVCF. Clin Exp Dermatol. 2017;42:874-80.
2. Abreu Velez AM, Yi H, Googe PB Jr, Mihm MC Jr, Howard MS. Autoantibodies to melanocytes and characterization of melanophages in patients affected by a new variant of endemic pemphigus foliaceus. J Cutan Pathol. 2011;38: 710-19.
3. Abreu Velez AM, Howard MS, Restrepo-Isaza M, Smoller B. Formalin deposition as artifact in biopsies from patients affected by a new variant of endemic pemphigus foliaceus in El Bagre, Colombia, South America. J Cutan Pathol. 2010;37:835-42.
4. Abreu Velez AM, Howard MS, Hashimoto T. Palm tissue displaying a polyclonal autoimmune response in patients affected by a new variant of endemic pemphigus foliaceus in Colombia, South America. Eur J Dermatol. 2010;20:74-81.
5. Howard MS, Yepes MM, Maldonado-Estrada JG, Villa-Robles E, Jaramillo A, Botero JH, Patiño PJ, Hashimoto T, Abreu-Velez AM. Broad histopathologic patterns of non-glabrous skin and glabrous skin from patients with a new variant of endemic pemphigus foliaceus-part 1. J Cutan Pathol. 2010;37:222-30.
6. Abreu-Velez AM, Howard MS, Hashimoto T, Grossniklaus HE. Human eyelid meibomian glands and tarsal muscle are recognized by autoantibodies from patients affected by a new variant of endemic pemphigus foliaceus in El-Bagre, Colombia, South America. J Am Acad Dermatol. 2010;62:437-47.
7. Abreu-Velez AM, Howard MS, Hashimoto K, Hashimoto T. Autoantibodies to sweat glands detected by different methods in serum and in tissue from patients affected by a new variant of endemic pemphigus foliaceus. Arch Dermatol Res. 2009,301;11-718.
8. Abreu Velez AM, Yi H, Gao W, Smoller BR, Grossniklaus HE, Howard MS. Antibodies to pilosebaceous units along their neurovascular supply routes in a new variant of endemic pemphigus foliaceus in Colombia, South America. Eur J Dermatol. 2011;21;371-75.
9. Abreu-Velez AM, Howard MS, Padilla HJL, Tobon-Arroyave S. Subclinical oral involvement in patients with endemic pemphigus foliaceus. Dermatol Pract Concept. 2018;8:252-261.
10. Abreu-Velez AM, Gao W, Howard MS. Patients affected by endemic pemphigus foliaceus in Colombia, South America exhibit autoantibodies to optic nerve sheath envelope cell junctions. Dermatol Pract Concept. 2018; 8:1-6.
11. Abreu-Velez AM, Howard MS, Yi H, Gao W, Hashimoto T, Grossniklaus HE. Neural system antigens are recognized by autoantibodies from patients affected by a new variant of endemic pemphigus foliaceus in Colombia. J Clin Immunol. 2011;31:356-68.
12. Abreu-Velez AM, Howard MS, Jiao Z, Gao W, Yi H, Grossniklaus HE, et al. Cardiac autoantibodies from patients affected by a new variant of endemic pemphigus foliaceus in Colombia, South America. J Clin Immunol. 2011;31:985-97.
13. Abreu Velez AM, Howard MS, Velazquez-Velez JE. Cardiac rhythm and pacemaking abnormalities in patients affected by endemic pemphigus in Colombia may be the result of deposition of autoantibodies, complement, fibrinogen, and other molecules. Heart Rhythm. 2018;15:725-31.
14. Abreu Velez AM, Yi H, Warfvinge G, Howard MS. Autoantibodies to full body vascular cell junctions colocalize with MYZAP, ARVCF, desmoplakins I and II and p0071 in endemic pemphigus in Colombia, South America. Int J Dermatol. 2018;57:291-98.
15. Abreu-Velez AM, Howard MS, Yi H, Florez-Vargas AA. Patients affected by a new variant of endemic pemphigus foliaceus have autoantibodies colocalizing with MYZAP, p0071, desmoplakins 1-2 and ARVCF, causing renal damage. Clin Exp Dermatol. 2018;43:692-02.
16. Gopal V, Shenoy MM, Bejai V, Nargist T. Nail changes in autoimmune blistering disorders: A case-control study. Indian J Dermatol Venereol Leprol. 2018;84:373.
17. Aoki V, Sousa JX Jr, Diaz LA, Cooperative Group on Fogo Selvagem Research. Pathogenesis of endemic pemphigus foliaceus. Dermatol Clin. 2011;29:413-18.
18. Aoki V, Rivitti EA, Diaz LA, Cooperative Group on Fogo Selvagem Research. Update on fogo selvagem, an endemic form of pemphigus foliaceus. J Dermatol. 2015;42:18-26.

Source of Support: This work was funded by Georgia Dermatopathology Associates; Mineros SA, Medellin, Colombia; Hospital Nuestra Señora del Carmen, El Bagre, Colombia; The Embassy of Japan in Colombia and the El Bagre Mayoral Office. All authors have reported that they have no relationships relevant to the contents of this paper to disclose. **Conflict of Interest:** None declared.

Original Article

Should patients with anogenital warts be tested for genital herpes? Initial results of a pilot study

Funda Tamer[1], Mehmet Eren Yuksel[2], Emine Avcı[3]

[1]Ufuk University School of Medicine, Department of Dermatology, Ankara, Turkey, [2]Aksaray University School of Medicine, Department of General Surgery, Aksaray, Turkey, [3]General Directorate of Public Health, Department of Infectious Diseases, Ankara, Turkey

Corresponding author: Dr. Funda Tamer, E-mail: fundatmr@yahoo.com

ABSTRACT

Background: Genital warts are manifestations of a disease caused by human papillomavirus. Genital warts usually present as multiple, asymmetric, polymorphic papular lesions on the anogenital skin and mucous membranes. Patients with genital warts may have coexisting sexually transmitted diseases. Appropriate screening is crucial to prevent the spread of these infections for public health. **Materials and Methods:** The study included 20 patients with anogenital warts and 20 healthy individuals within the control group. Laboratory tests including serum levels of hepatitis B surface antigen, antibody to hepatitis B surface antigen, hepatitis C antibody, anti human immunodeficiency virus antibody, herpes simplex virus type-1 IgG and herpes simplex virus type-2 IgG were evaluated in each participant. Venereal Disease Research Laboratory test was also evaluated in the patient group. **Results:** Serum levels of hepatitis B surface antigen, hepatitis C antibody and anti human immunodeficiency virus antibody were negative in all patients and healthy individuals. Serum levels of antibody to hepatitis B surface antigen were positive in 15(75%) patients and in 14(70%) healthy individuals (p=1). Venereal Disease Research Laboratory test was non-reactive in all patients with anogenital warts. Serum herpes simplex virus type-1 IgG levels were positive in 14(70%) patients and in 11(55%) healthy individuals (p=0.51). Serum herpes simplex virus type-2 IgG levels were positive in 4(20%) patients while all the healthy individuals had negative serum herpes simplex virus type-2 IgG levels (p=0.03). **Conclusions:** Positive serum herpes simplex virus type-2 IgG levels were significantly more frequent in patients with anogenital warts compared to healthy individuals. Therefore, we suggest that all the patients with anogenital warts should be tested for genital herpes. Hereby, the preliminary results of laboratory tests for the evaluation of patients with anogenital warts have been reported.

Key words: Condylomata Acuminata; Genital; Herpes Simplex; Human Papillomavirus; Warts

INTRODUCTION

Sexually transmitted diseases like genital wart, genital herpes, syphilis, human immunodeficiency virus (HIV) infection remain a worldwide public health problem [1]. Hepatitis B has also been regarded as a sexually transmitted infection for years. Hepatitis C virus can be transmitted sexually especially in HIV positive patients [2]. Sexually transmitted diseases affect both men and women during the reproductive years. Most of the patients with sexually transmitted diseases (86%) are between the ages of 15 to 29 [1].

Genital warts are caused by human papillomavirus (HPV) which is the most common sexually transmitted virus worldwide. More than 200 types of HPV have been described yet and for about 40 types of HPV can lead to benign or malign lesions in the genital area [3]. It has been suggested that over 99.7% patients with cervical cancer had positive HPV test results [4]. Genital warts may coexist with other sexually transmitted diseases. Therefore, appropriate screening for sexually transmitted diseases is recommended in all patients presenting with genital warts [4].

How to cite this article: Tamer F, Yuksel ME, Avcı E. Should patients with anogenital warts be tested for genital herpes? Initial results of a pilot study. Our Dermatol Online. 2019;10(4):329-332.

Submission: 07.12.2018; **Acceptance:** 10.02.2019

DOI: 10.7241/ourd.20194.2

Genital herpes is the most common genital ulcerative disorder primarily caused by herpes simplex virus type-2 (HSV2) or herpes simplex virus type-1 (HSV1) [5]. Herpes simplex virus type-2 is shed in the genital tract asymptomatically. Transmission of the virus usually occurs during periods of asymptomatic viral shedding [6].

Interaction between HPV and HSV has been associated with cervical carcinogenesis. Herpes simplex virus infection and replication may induce cytopathic effects in HPV-positive tissues [7]. Herpes simplex virus type-2 infection is considered as a facilitative factor in cancer development [8]. Sexually transmitted disease prevention and treatment programs are crucial to reduce the transmission of these infections [9].

MATERIALS AND METHODS

The study included 20 patients with genital warts and 20 healthy individuals within the control group. Medical records of the participants were reviewed retrospectively between May 2017 and May 2018. The exclusion criteria were pregnancy, immunosuppression, malignancy and conditions which require regular blood transfusions like anemia, thrombocytopenia, hemophilia and chronic kidney disease.

Laboratory tests including serum levels of hepatitis B surface antigen (HBsAg), antibody to hepatitis B surface antigen (anti-HBs), hepatitis C antibody (anti-HCV), anti human immunodeficiency virus antibody (anti-HIV), herpes simplex virus type-1 (HSV1) IgG and herpes simplex virus type-2 (HSV2) IgG were evaluated in each participant. Venereal Disease Research Laboratory (VDRL) test results were evaluated in patient group.

All patients with genital warts were treated with cryotherapy. The therapy was performed every three weeks, for a maximum of five treatment sessions. The patients were adviced to use mupirocin 2% cream twice daily, after the cryotherapy treatment.

Data were analyzed using SPSS 20.0 Statistical Package Program. Descriptive statistics were presented as number and percentage for classified data, and as mean ± standard deviation or median (minimum; maximum) for numerical values. The chi-square test was used to compare categorical variables between patient group and healthy individuals. As the numerical variables were not normally distributed, groups were compared using non-parametric tests. Differences between two independent groups were tested with Mann Whitney U test. The p-value <0.05 was considered significant.

RESULTS

The study included 20 patients with genital warts and 20 healthy individuals within the control group. Each group consisted of 17 (85%) male and 3 (15%) female participants. The mean age of the patients was 30.8±8.2 (range: 20-52). The mean age of the healthy individuals was 31.6±9.7 (range: 19-58) (p=0.9).

The mean disease duration of the patients with genital warts was 6.6±6.5 months (range: 1-24 months). Twelve (60%) patients did not receive any treatment previously. One (5%) patient used topical imiquimod 5% cream (Aldara®) three times per week for two months. Seven (35%) patients were treated with 1 to 5 sessions of cryotherapy twice monthly.

Venereal Disease Research Laboratory test was non-reactive in all patients with anogenital warts (Table 1).

The mean serum HBsAg level was 0.32±0.15 S/CO in patients (range: negative <1, positive>1 S/CO). The mean serum HBsAg level was 0.23±0.04 S/CO in healthy individuals (p=0.03). Serum HBsAg levels were negative in all patients and healthy individuals.

The mean serum anti-HBs level was 305.44±391.64 mIU/mL in patients (range: negative: 0-10, positive: 10-1000 mIU/mL). The mean serum anti-HBs level was 83.88±99.82 mIU/mL in healthy individuals (p=0.29). Serum anti-HBs levels were positive in 15(75%) patients and negative in 5(25%) patients. Serum anti-HBs levels were positive in

Table 1: Laboratory test results of the patients with genital warts and healthy individuals

Positive test results	Patients (n=20)	Healthy individuals (n=20)	p-value
VDRL	0	-	
HBsAg	0	0	
Anti-HBs	15 (75%)	14 (70%)	1
Anti-HCV	0	0	
Anti-HIV	0	0	
HSV1IgG	14 (70%)	11 (55%)	0.51
HSV2IgG	4 (20%)	0	0.03

Serum levels of HBsAg, anti-HCV and anti-HIV were all negative in patients and healthy individuals. Serum VDRL test results were negative in patient group. Frequency of positive serum levels of anti-HBs and HSV1IgG were similar in both groups. However, positive HSV2IgG levels were significantly more prevalent in patients with genital warts compared to healthy individuals (p=0.03).

14(70%) healthy individuals and negative in 6(30%) healthy individuals (p=1).

The mean serum anti-HCV level was 0.06±0.02 S/CO in patients (range: negative: 0-1, positive: 1.45-1000 S/CO). The mean serum anti-HCV level was 0.05±0.02 S/CO in healthy individuals (p=0.78). Serum anti-HCV levels were negative in all patients and healthy individuals.

The mean serum anti-HIV level was 0.16±0.13 S/CO in patients (range: negative: 0.01-1, positive: 1-1000 S/CO). The mean serum anti-HIV level was 0.12±0.04 S/CO in healthy individuals (p=0.62). Serum anti-HIV levels were negative in all patients and healthy individuals.

The mean serum herpes simplex virus type-1 IgG (HSV1IgG) level was 104.99±76.77 RU/mL in patients (range: negative<16, positive>22 RU/mL). The mean serum HSV1IgG level was 90.34±83.49 RU/Ml in healthy individuals (p=0.62). Serum HSV1IgG levels were positive in 14(70%) patients and negative in 6(30%) patients. Serum HSV1IgG levels were positive in 11(55%) healthy individuals and negative in 9(45%) healthy individuals (p=0.51).

The mean serum herpes simplex virus type-2 IgG (HSV2IgG) level was 16.21±41.10 RU/mL in patients (range: negative<16, positive>22 RU/mL). The mean serum HSV2IgG level was 2.30±2.47 RU/mL in healthy individuals (p=0.73). Serum HSV2IgG levels were positive in 4(20%) patients and negative in 16(80%) patients. All of the healthy individuals had negative serum HSV2IgG levels (p=0.03).

DISCUSSION

Genital warts (condylomata acuminata) are manifestations of a sexually transmitted disease usually caused by HPV type 6 and 11. Genital warts are more common in men than in women. They usually present as multiple, asymmetric, exophytic lesions, plane papules or cauliflower-like growths in the anogenital region [10]. In addition, genital warts may occur as a giant mass which is called Buschke-Loewenstein tumor [11]. The diagnosis of genital wart is usually made based on clinical findings. However, a biopsy should be performed to painful, bleeding, ulcerated and therapy-resistant lesions in order to reach a definitive diagnosis [10]. The differential diagnosis should include verrucous cancer of the vulva, condyloma lata, skin tag, lichen planus, sebaceous cyst and pearly penile papules [10,12]. Treatment of choice includes topical use of podophyllotoxin, imiquimod and trichloroacetic acid, electrocauterization, cryotherapy, laser therapy and surgical excision [13]. Cryotherapy is one of the most commonly used and effective method with low complication rates [14]. However, surgical excision is needed for large and resistant warts, also for lesions suspicious for malignancy, and for warts which cause obstruction [15].

Genital warts may also be the manifestations of high-risk HPV types (HPV 16, 18, 31, 33, 35, 39, 45, 51, 52) which are associated with low/high grade squamous intraepithelial lesions and invasive cancer. The relationship between HPV infection and cervical cancer has been well established. Moreover, oncogenic strains of HPV play role in the development of anal cancer. Genital warts can be localized both externally and internally within the anal canal and lower rectum. Therefore, cervical pap smear, anoscopy and proctosigmoidoscopy are essential in the management of patients with anogenital warts [16].

Patients with genital warts should be screened for coinfections with other sexually transmitted diseases [17]. Casillas-Vega et al. reported that HIV positive patients were more likely to have HPV infection and HSV2 positive patients were more likely to be infected with *Mycoplasma genitalium*. Moreover, patients infected with *Trichomonas vaginalis* were more likely to have syphilis and infections with HPV, HIV, HSV1 and also *Mycoplasma genitalium* [18]. Alberts et al. reported that HPV prevalence was higher in HSV-2 seropositive men than in HSV-2 seronegative men [19]. Peters et al. evaluated 66 patients with symptoms of sexually transmitted diseases. Coinfection rates of HSV in syphilis and HIV positives were 40.6% and 42.9% respectively [20]. Agyemang-Yeboah et al. reported that the prevalence of HSV1 and HSV2 infection among HPV positive women were 98.6% and 80.4%, respectively [21].

Within this study, none of the patients with genital warts had syphilis, active hepatitis B, active hepatitis C or HIV infection. Moreover, the frequency of positive serum HSV1IgG levels were similar in patients with genital warts and healthy individuals.

Herpes simplex virus type-2 plays a synergetic role with HPV in the development of malignant changes in HPV-positive tissues [7,22]. Transmission of HSV2

to an uninfected individual usually occurs during asymptomatic reactivation of the virus. Antiviral treatment may decrease the incidence of HSV2 infection by preventing HSV2 shedding [6]. Within this study, detection of positive serum HSV2IgG levels were statistically more frequent in patients with genital warts compared to healthy individuals. These results suggest that screening of patients with genital warts for genital herpes may be helpful in the management of HSV2 spreads and cytopathic effects of co-infection of HSV2 and HPV.

Hereby, the preliminary results of laboratory tests for the evaluation of patients with anogenital warts have been reported. Further studies with larger sample size are required to confirm our data.

Statement of Human and Animal Rights

All procedures followed were in accordance with the ethical standards of the responsible committee on human experimentation (institutional and national) and with the Helsinki Declaration of 1975, as revised in 2008.

Statement of Informed Consent

Informed consent was obtained from all patients for being included in the study.

REFERENCES

1. Puri N, Kumari P. A study on sexually transmitted diseases in patients in a STD clinic in a district hospital in North India. Our Dermatol Online. 2014;5:240-4.
2. Brook MG. Sexually acquired hepatitis. Sex Transm Inf. 2002;78:235-40.
3. Suligoi B, Vittori G, Salfa MC, Timelli L, Corsini D, Fattorini G, et al. Prevalence and incidence of external genital warts in a sample of Italian general female population. BMC Infect Dis. 2017;17:126.
4. Ooi C. Testing for sexually transmitted infections. Aust Prescr. 2007;30:8–13.
5. Parajuli S, Acharya Y, Rathi SB, Paudel U. Chronic ulcerating genital herpes simplex virus infection: a diagnosis mislead by HIV infection. Our Dermatol Online. 2014;5:285-6.
6. Schiffer JT, Mayer BT, Fong Y, Swan DA, Wald A. Herpes simplex virus-2 transmission probability estimates based on quantity of viral shedding. J R Soc Interface. 2014;11:20140160.
7. Meyers C, Andreansky SS, Courtney RJ. Replication and interaction of herpes simplex virus and human papillomavirus in differentiating host epithelial tissue. Virology. 2003;315:43-55.
8. Yun H, Park J, Choi I, Kee M, Choi B, Kim S. Prevalence of human papillomavirus and herpes simplex virus type 2 infection in Korean commercial sex workers. J Microbiol Biotechnol. 2008;18:350-4.
9. Yared N, Horvath K, Fashanu O, Zhao R, Baker J, Kulasingam S. Optimizing screening for sexually transmitted infections in men using self-collected swabs: a systematic review. Sex Transm Dis. 2018;45:294-300.
10. Steben M, Garland SM. Genital warts. Best Pract Res Clin Obstet Gynaecol. 2014;28:1063-73.
11. Al Aboud K, Al Aboud A. Eponyms in dermatology literature linked to genital skin disorders. Our Dermatol Online. 2013;4:243-6.
12. Puri N, Puri A. A study on non-venereal genital dermatoses in north India. Our Dermatol Online. 2013;4:304-7.
13. Wiley DJ, Douglas J, Beutner K, Cox T, Fife K, Moscicki AB, et al. External genital warts: diagnosis, treatment, and prevention. Clin Infect Dis. 2002;35:210-24.
14. Thapa DP, Jha AK, Shrestha S, Joshi S. Cryosurgery in a dermatology setup: a hospital based study. Our Dermatol Online. 2018;9:137-9.
15. Yanofsky VR, Patel RV, Goldenberg G. Genital warts: a comprehensive review. J Clin Aesthet Dermatol. 2012;5:25-36.
16. Chang GJ, Welton ML. Human papillomavirus, condylomata acuminata, and anal neoplasia. Clin Colon Rectal Surg. 2004;17:221-30.
17. Carne CA, Dockerty G. Genital warts: need to screen for coinfection. BMJ. 1990;300:459.
18. Casillas-Vega N, Morfín-Otero R, García S, Llaca-Díaz J, Rodríguez-Noriega E, Camacho-Ortiz A, et al. Sexually transmitted pathogens, coinfections and risk factors in patients attending obstetrics and gynecology clinics in Jalisco, Mexico. Salud Publica Mex. 2016;58:437-45.
19. Alberts CJ, Schim van der Loeff MF, Papenfuss MR, da Silva RJ, Villa LL, Lazcano-Ponce E, et al. Association of Chlamydia trachomatis infection and herpes simplex virus type 2 serostatus with genital human papillomavirus infection in men: the HPV in men study. Sex Transm Dis. 2013;40:508-15.
20. Peters BP, Rastogi VL, Monica, Nirwan PS. Coinfection of HSV with other sexually transmitted diseases. Indian J Med Microbiol. 2005;23:143-4.
21. Agyemang-Yeboah F, Debrah O, Donkoh ET, Asmah HR, Seini MM. Co-infection prevalence of herpes simplex virus types 1 and 2 with human papillomavirus and associated risk factors among asymptomatic women in Ghana. Int J Inf Dis Ther. 2018;3:45-51.
22. Raju K. Virus and cervical cancer: role and implication: a review. Biomed Res Ther. 2015;2:220-30.

Source of Support: Nil, **Conflict of Interest:** None declared.

Original Article

Frequency and clinico-topographic distribution patterns of pruritic papular eruption in HIV patients in a Nigerian Tertiary Hospital

Obioma Ekpe[1], Gerald Dafe Forae[2], Benson Okwara[3], Chimezie Godswill Okwuonu[1], Roli Cynthia Madubuko[3]

[1]Department of Medicine, Federal Medical Centre Umuahia, Abia State, Nigeria, [2]Department of Pathology, University of Benin Teaching Hospital, Benin City, Nigeria, [3]Department of Medicine, University of Benin Teaching Hospital, Benin City, Nigeria

Corresponding author: Dr. Obioma Ekpe, E-mail: uncleprinceo@gmail.com

ABSTRACT

Background: Pruritic papular eruption of HIV (PPE-HIV) has been well described in some sub-Saharan Africa countries and elsewhere, with varying geographical prevalence. **Aims:** To determine the frequency and the clinico-topographic distribution of these lesions as seen in the University of Benin Teaching Hospital, Benin-City, Nigeria and to compare our findings with those seen in other parts of the world. **Materials and Methods:** This study was carried out at the University of Benin Teaching Hospital (UBTH), Benin-City. University of Benin Teaching Hospital is an 800-bed Federal Government tertiary hospital which offers both in-patient and out-patient services. Specimen collection and analysis of the study lasted 18 months (January, 2015 to June, 2016). All HIV patients at presentation in clinic and wards with suspicion of PPE during the study period were interviewed examined. Qualitative variables were described in percentages and proportions. Continuous variables were summarized as mean and standard deviation when normally distributed. **Results:** A total of 106 patients were studied, there were 41 (38.7%) males and 65 (61.3%) females with a male to female ratio of 1:1.6. Their mean age was 40.2±10.4 years. Majority (79.3%) of patients had at least secondary education and males were slightly better educated than females. Most (33.0%) of the subjects were traders, the mean duration of diagnosis of PPE was 5.22±3.92 and 6.05±5.21 months for males and females respectively, while the overall mean duration of diagnosis of PPE was 5.73±4.75 months. The most commonly reported sites initially affected by PPE among the patients were lower limb (51.0%) and upper limb (39.6%). **Conclusion:** Majority of lesions of Pruritic papular eruptions (PPE) of HIV in this study were found in educated females. The mean age of distribution of PPE was found in the 4th decades. Furthermore PPE is distributed predominantly on the exposed parts of the body especially the upper and lower limbs.

Key words: Human Immmuno-deficency Virus; Pruritic papular eruption; clinic-topographic

INTRODUCTION

Pruritic papular eruption of human immunodeficiency virus (PPE-HIV) is one of the most common dermatologic disorders in untreated HIV-infected adults. Pruritic papular eruption of HIV (PPE-HIV) has been well described in some sub-Saharan Africa countries and elsewhere, with varying geographical prevalence.[1] Report of PPE emerged early in the course of the HIV epidemic as far back in 1983 in series of studies conducted in Democratic Republic of Congo [1], Mali [2], Nigeria [3], Tanzania [4], Togo [5], Zambia [6], and other Africa countries, where it was described as an extremely pruritic diffuse skin eruption occurring in HIV infected patient.

Studies have it that between 11% and 46% of HIV positive patients are affected with PPE, depending on the geographical location [7,8]. In Haiti it accounted for 46% [7], Thailand (33-37%) [8], in Zaire among

How to cite this article: Ekpe O, Forae GD, Okwara B, Okwuonu CG, Madubuko RC. Frequency and clinico-topographic distribution patterns of pruritic papular eruption in HIV patients in a Nigerian Tertiary Hospital. Our Dermatol Online. 2019;10(4):333-337.

Submission: 17.04.2019; **Acceptance:** 01.06.2019

DOI: 10.7241/ourd.20194.3

hospitalized patients (18%) [9], Kenya (5%) [10], and (16.7%) in Nigeria [11].

There are few reported cases of pruritic papular eruption of HIV in United States of America (USA), except in areas with high mosquito prevalence such as Southern Florida [12], where a PPE prevalence of 11% was reported by Goldstein et al [13].

Only few studies on Pruritic papular eruption of HIV have been done in Nigeria and as such there is the need to study PPE cases as they present to the University of Benin Teaching Hospital.

The main objective of this study is to determine the frequency and the clinic-topographic distribution of these lesions as seen in the University of Benin Teaching Hospital, Benin-City, Nigeria and to compare our findings with those seen in other parts of the world.

MATERIALS AND METHODS

Study Area

This study was carried out at the University of Benin Teaching Hospital (UBTH) Benin-City. UBTH is an 800-bed Federal Government tertiary hospital which offers both in-patient and out-patient services. It is located in Egor Local Government Area of Edo State, Nigeria. It receives referrals from Edo state and neighbouring States like Delta, Ondo, Anambra, Ekiti, Kogi, and Bayelsa.

Study Duration, Design and Population

Specimen collection and analysis of the study lasted 18 months (January, 2015 to June, 2016) after approval by the ethical committee. The study design was a cross-sectional descriptive study of confirmed HIV-infected patients with clinically active PPE lesions presenting at the Dermatology outpatient clinic, the HIV/ART clinic of the Dermatology and Infectious disease unit of Internal Medicine department of UBTH and those admitted as in-patients in the medical wards of the UBTH.

Sampling Method

All HIV patients at presentation in clinic and wards with suspicion of PPE during the study period were interviewed examined and skin biopsy sample taken and patients with histological evidence of PPE were consecutively recruited into the study until the required sample size was attained.

Data Analysis

Data generated from the study was entered into and analyzed using the Statistical Package of Social Science (SPSS) version 21. Qualitative variables were described in percentages and proportions. Continuous variables were summarized as mean and standard deviation when normally distributed. Non–normally distributed quantitative variables were summarized as median. The findings were presented in appropriate tables.

RESULTS

Social Demographic Characteristics of the Patients

A total of 106 patients were studied and their findings presented below. There were 41 (38.7%) males and 65 (61.3%) females with a male to female ratio of 1:1.6. Their mean age was 40.2±10.4 years. The males (mean=40.9±8.8 years) were slightly older than females (mean=39.7±11.4 years). Majority (79.3%) of patients had at least secondary education and males were slightly better educated than females. Thirty-eight (35.8%) of patients were single, 48 (45.3%) were married, 12 (11.3%) were widowed and 4 respondents each (3.8%) were divorced or separated. A higher proportion of males (48.8%) than females (43.1%) were married, while more females (38.5%; 13.9%) than males (31.7%; 7.3%) were single or widowed respectively. Most (33.0%) of the subjects were traders, while house-wives constituted the least (5.7%) based on occupational status - Table 1.

Duration of Diagnosis of PPE by Gender

Table 2 show the mean duration of diagnosis of PPE was 5.22±3.92 and 6.05±5.21 months for males and females respectively, while the overall mean duration of diagnosis of PPE was 5.73±4.75 months. A higher proportion of male subjects were diagnosed earlier (≤6 months) than the female, however there was no significant difference between the sexes by duration of diagnosis.

Initial (First) Part of the Body Affected by PPE Lesions according to Gender

The most commonly reported sites initially affected by PPE among the patients were lower limb (51.0%) and upper limb (39.6%), while the face is the least affected

initially among all the patients, and there was also no significant difference in the site first affected by gender as shown in Table 3.

Distribution of Patients with PPE according to BMI Class

Forty-four (41.5%) of the patients were underweight, 55 (51.9%) had normal weight and 7 (6.6%) of the participants were overweight as shown in Table 4:12. Overall mean BMI of all the patients was 19.2±3.5 kg/m^2. Mean BMI of the females – 19.8±3.8kg/m^2 was slightly higher than the mean BMI of the male - 18.3±2.8kg/m^2. (Table 4)

DISCUSSIONS

In this study majority of patients with pruritic papular eruption of HIV were women (61.3%). This was similar to the findings by Mawenzi et al [10] in Kenya where 70% of his study population were females. A similar observation was made by Resneck et al [14] who reported that 81% of PPE patients were females. Other studies in Kenya[10] also reported that 70% of patients with PPE were female. These were in contrast to a study from the Democratic Republic of Congo by Colebunder et al who stated that the frequency of PPE seen in male and female were approximately equal [9]. The reason for the disparity is unknown. Perhaps the greater susceptibility of female to HIV infection may explain the gender differences in HIV prevalence [15]. It may also mean that women are more skin health and cosmetically conscious and do seek treatment better than men as observed in Cameroon by Josephine et al [16]. and in Benin city, Edo state by Omuemu et al [17].

The mean age of the participants in this study was 40.2±10.4 years. This was comparable to a study done in Uganda where the mean age of participants was noted to be 35±8 years [18]. A study in India reported that the mean age of the PPE patients was 34.2±7.5 years [19]. Most of the patients with PPE in this study (68.8%) were less than 45 years old, in keeping with the age group more likely to be HIV infected as reported in similar studies in our environment [20,21].

Majority of patients (79.3%) in this study had at least secondary education and above. This was in keeping with a previous study by Egube et al in Benin City that corroborated to high literacy level among the inhabitants of Benin City and its environs [22].

Table 1: Socio-demographic Characteristics of the Patients by Gender

Characteristic	Male n=41 (%)	Female n=65 (%)	Total n=106 (%)
Age (in years)			
15-29	2 (4.9)	15 (23.1)	17 (16.0)
30-44	26 (63.4)	30 (46.2)	56 (52.8)
45-59	12 (29.3)	16 (24.6)	28 (26.4)
≥60	1 (2.4)	4 (6.2)	5 (4.7)
Mean±SD	40.9±8.6	39.7±11.4	40.2±10.4
Level of Education			
None	6 (14.6)	4 (6.2)	10 (9.4)
Primary	4 (9.8)	8 (12.3)	12 (11.3)
Secondary	17 (41.5)	28 (43.1)	45 (42.5)
Tertiary	19 (46.3)	20 (30.8)	39 (36.8)
Religion			
Christian	37 (90.2)	58 (89.2)	95 (89.6)
Islam	4 (9.8)	7 (10.8)	11 (11.4)
Marital Status			
Single	13 (31.7)	25 (38.5)	38 (35.8)
Married	20 (48.8)	28 (43.1)	48 (45.3)
Divorced	2 (4.9)	2 (3.1)	4 (3.8)
Widowed	3 (7.3)	9 (13.9)	12 (11.3)
Separated	3 (7.3)	1 (1.5)	4 (3.8)
Occupation			
Traders	14 (34.1)	21 (32.3)	35 (33.0)
Civil servants	11 (26.8)	13 (20.0)	24 (22.6)
Farmers/ Artisans	8 (19.5)	13 (20.0)	21 (19.8)
Student	8 (19.5)	12 (18.5)	20 (18.9)
House-wife	0 (0.0)	6 (9.2)	6 (5.7)

Table 2: Duration of diagnosis of PPE by Gender

Duration of diagnosis	Male n=41 (%)	Female n=65 (%)	Total n=106 (%)
≤6 months	34 (82.9)	49 (75.4)	83 (78.3)
7-12 months	6 (14.6)	13 (20.0)	19 (17.9)
>12 months	1 (2.4)	3 (4.6)	4 (3.8)
Mean±SD	5.22±3.92	6.05±5.21	5.73±4.75

Table 3: Initial (first) part of the body affected by PPE according to Gender

Part of the Body	Male n=41 (%)	Female n=65 (%)	Total n=106 (%)
Lower Limb	21 (51.2)	33 (50.8)	54 (51.0)
Upper Limb	16 (39.0)	26 (40.0)	42 (39.6)
Face	4 (9.8)	6 (9.2)	10 (9.4)

Table 4: Distribution of Patients with PPE according to BMI Class

BMI (kg/m^2)	Male n=41 (%)	Female n=65 (%)	Total n=106 (%)
Underweight (<18.5)	21 (51.2)	23 (35.4)	44 (41.5)
Normal Weight (18.5-24.9)	20 (48.8)	35 (53.8)	55 (51.9)
Overweight (25-29.9)	0 (0.0)	7 (10.8)	7 (6.6)
Mean±SD	18.3±2.8	19.8±3.8	19.2±3.5

The mean duration of PPE skin lesion as reported by participants before diagnosis was 5.73±4.75 months. This was comparable to the findings of Lakshmi et al [23] in India who reported mean PPE duration of 6.5 months at diagnosis. A study done in Uganda found out that majority (58%) of PPE patients had PPE for more than 6 months at diagnosis [24]. The time lag before patient presentation to the clinic and the intense pruritus could have been responsible for the secondary changes noticed in patients with this skin lesion.

In addition to its presence in large number of patient, PPE is often one of the early cutaneous manifestations of HIV. In a study done in Kenya by Mawenzi et al [10] on the epidemiology and clinical spectrum of cutaneous disease manifesting among newly diagnosed HIV seropositive adult in Kenya; it was reported that out of 394 cases 20 patients accounting for 5% had PPE. PPE is often one of the early cutaneous manifestations of HIV. Liautaud et al [25], in a study of PPE-HIV in Haitian patients, observed pruritic papular skin lesion as the initial symptom in 70% of patients and similar findings were described in Democratic Republic of Congo, by Colebunder et al [9], where 51% reported that the skin eruption was their initial manifestation of HIV.

Pruritic papular eruptions (PPE) are characterized by chronic pruritus and symmetric papular eruptions on the trunk and extremities, with absence of other definable causes of itching in an HIV-infected patient [15,26]. The face may be involved in some patients and the condition tends to wax and wane [16,23].

The review of body parts affected by the rash in this study showed that majority (98.1%) of the patients with Pruritic papular eruptions of HIV have the lesions on their extremities as shown in Figs 1 and 2. Other investigators have reported that the lesions of PPE were mostly located on the extremities [11,25,27].

The nutritional status of PPE patients were assessed using body mass index (BMI). It was noted in the study centre, that 41.5% of the study population were under-weight while 51.9% had normal weight. The reason for the under nutrition recorded in 41.5% of patients in this study could be due to advanced immunosuppression which could be associated with opportunistic infection. More so, it is documented that disease progression and viral load increments in HIV patients lead to overproduction of cytokines such as TNF that culminates in weight loss [28].

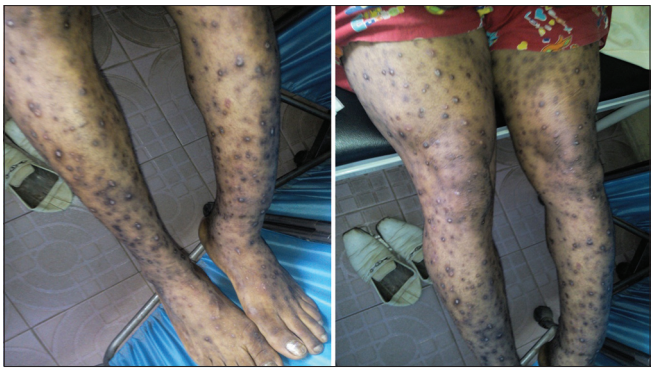

Figure 1: Lab Patient with Pruritic papular eruption of HIV affecting the lower limb.

Figure 2: Patient with Pruritic papular eruption -HIV affecting the upper limb.

CONCLUSION

In conclusion majority of lesions of Pruritic papular eruptions (PPE) of HIV in this study were found in females and were educated. The mean age of distribution of PPE was found in the 4th decades. Furthermore PPE is distributed predominantly on the exposed parts of the body especially the upper and lower limbs.

Statement of Human and Animal Rights

All procedures followed were in accordance with the ethical standards of the responsible committee on human experimentation (institutional and national) and with the Helsinki Declaration of 1975, as revised in 2008.

Statement of Informed Consent

Informed consent was obtained from all patients for being included in the study.

REFERENCES

1. Bason MM, Berger TG, Nesbitt LT Jr. Pruritic papular eruption of HIV-disease. Int J Dermatol. 1993;32:784-9.
2. Mahe A, Simon F, Coulibaly S. Predictive value of seborrheic dermatitis and other common dermatosis for HIV infection in Bamako, Mali. J Am Acad Dermatol. 1996;34:1084-6.
3. Olumide YM, Dada AJ, Sogbanmu IB, Ariuna GA. Seroprevalence study of HIV-1, HIV-II and HTLV-I among patients at the Dermato-venerology clinic of the Lagos University Teaching Hospital. Int J Dermatol. 1997;36:741-4.
4. Pallangyo KJ. Cutaneous findings associated with HIV disease including AIDS: experience from sub Saharan African. Trop Doct. 1992;22:35-41.
5. Pitche P, Tchangai- wallak, Napo-Koura G. Prevalence of skin manifestations in AIDS patient in the Lome-Tokoin University Hospital (Togo). Sante. 1995;5:349-52.
6. Hira SK, Wadhawan D, Kamanga J, Kavindel D, Macuacua R, Patil PS. et al. Cutaneous manifestations of human immunodeficiency virus in Lusaka, Zambia. J Am Acad Dermatol. 1988;19:451-7.
7. Liautaud B, Pape JW, DeHovitz JA, Thomas F, LaRoche AC, Verdier RI, et al. Pruritic skin lesions: A common initial presentation of acquired immunodeficiency syndrome. Arch Dermatol. 1989;125:629-32.
8. Sivayathorn A, Srihra B, Lasanguankul W. Prevalence of skin disease in patients infected with human immune deficiency virus Bangkok, Thailand: Ann Acad Med Singapore. 1995;24:528-33.
9. Colebunders R, Mann JM, Francis H, Bila K, Izaley L, Kakonde N, et al. Generalized pruritic papular eruption in African patients with HIV infection. AIDS. 1987;1:117-21.
10. Mawenzi LR, Oguttu RO, Williams CH, Joash A. Epidemiology and clinical spectrum of cutaneous diseases manifesting among newly diagnosed HIV seropositive adults in Nakuru County-kenya. Continental J Med Res. 2013;7:1-9.
11. Ukonu AB, Eze EU. Pattern of skin diseases at university of Benin Teaching Hospital, Benin City, Edo state, South-South Nigeria: a 12 month prospective study. Glob J Health Sci. 2012;4:148-57.
12. Hevia O, Jimenez-Acosta F, Ceballos PI, Gould EW, Pennys NS. Pruritic papular eruption of the acquired immunodeficiency syndrome: a clinicopathologic study. J Am Acad Dermatol. 1991;24:231-5.
13. Goldsteins B, Berman B, Sukenik E, Frankel SJ. Correlation of skin disorder with CD4 Lymphocyte count in patients with HIV/AIDS. J Am Acad Dermatol. 1997;36:262-4.
14. Resneck JS Jr, Van Beek M, Furmanski L, Oyugi J, LeBoit PE, Kambugu F, et al. Etiology of pruritic papular eruptions with HIV in Uganda. JAMA. 2004;292:2614-21.
15. Glynn JR, Corael M, Auvert B. Why do young women have a much higher prevalence of HIV than young men? A study in Kisumu Kenya and Ndola, Zambia. AID. 2001;15:551-60.
16. Josephine M, Issac E, George A, Ngole M, Albert SF. Pattern of skin manifestations and their relationship with CD4 counts among HIV/AIDS patients in Cameroon. Int. J Dermatol. 2006;45:280-4.
17. Omuemu VO, Okoje OH, Omuemu CE. Awareness of high blood pressure status, treatment and control in a rural community in Edo state. Niger J Clin Pract. 2007;10:2008-12.
18. Resneck JS Jr, Van Beek M, Furmanski L, Oyugi J, LeBoit PE, Kambugu F, et al. Etiology of pruritic papular eruptions with HIV in Uganda. JAMA. 2004;292:2614-21.
19. Farsani TT, Kore S, Nadole P, Ramam M, Thiemans S, Leslie K, et al. Etiology and risk factors associated with a pruritic papular eruption in people living with HIV in India. J. Int. AIDS Soc. 2013;16:25-6.
20. Gyar SD, Reuben CR, Haruna MS. Study on the Distribution of HIV/AIDS Infections among Age Group Attending General Hospital Toto, Central Nigeria. Int J Microbiol Immunol Res. 2014;3:38-42.
21. Olajubu FA, Osinupebi OA, Deji-Agboola M, Jagun EO. Seroprevalence of HIV Among Blood Donors, Antenetal women and other patients in a Tertiary Hospital in Nigeria. Braz J Inf Dis. 2009;13:280-3.
22. Egube BA, Ofili AN, Isara AR, Onakewhor JU. Neonatal jaundice and its management: Knowledge, attitude and practice among expectant mothers attending antenatal clinic at University of Benin Teaching Hospital, Benin City. Niger J Clin Pract. 2013;16:188-94.
23. Lakshmi SJ, Rao GR, Ramalakshmi, Satyasree, Rao KA, Prasad PG, Kumar YH. Pruritic papular eruptions of HIV: a clinicopathologic and therapeutic study. Indian J Dermatol Venereol Leprol. 2008;74:501-3.
24. Castelnuovo B, Byakwaga H, Menten J. Can response of a pruritic papular eruption to antiretroviral therapy be used as a clinical parameter to monitor virological outcome? AIDS. 2008;22:269-73.
25. Liautaud B, Pape JW, DeHovitz JA, Thomas F, LaRoche AC, Verdier RI, et al. Pruritic skin lesions: A common initial presentation of acquired immunodeficiency syndrome. Arch Dermatol. 1989;125:629-32
26. Fischer BK, Warner LC. Cutaneous manifestations of the acquired immunodeficiency syndrome. Intl J Dermatol. 1987;26:615-30.
27. Chua SL, Amerson EH, Leslies KS, McCalmount TH, Leboit PE, Martin JN, et al. Factors associated with pruritic papular eruption of human immunodeficiency virus infection in the antiretroviral therapy era. Br J Dermatol. 2014;170:832-9.
28. Jayakar T, Selva PSK, Manoharan D, Ashok KN, Cynthia S, Ashwak A. Papular Urticaria-An early marker of atopic march. Sudanese J Dermatol. 2010;8:2-3.

Source of Support: Nil, **Conflict of Interest:** None declared.

Brief Report

Efficacy of Rituximab in the treatment of pemphigus: experience of Moroccan population

Hanane Bay Bay, Ghita Senhaji, Sara Elloudi, Zakia Douhi, Fatima Zahra Mernissi

Department of Dermatology, UHC Hassan II, Fez, Morocco

Corresponding author: Dr. Hanane Bay Bay, E-mail: hananebaybay@gmail.com

ABSTRACT

Background: Pemphigus is a severe autoimmune blistering disease mediated by pathogenic anti-desmoglein antibodies leading to an inter keratinocyte disjunction. Rituximab is a monoclonal antibody that binds to the CD-20 antigen of B lymphocytes, which causes B-cell depletion and a subsequent reduction in pathogenic autoantibodies. Its therapeutic role in vulgaris and superficial pemphigus has been progressively growing with increasing evidence of successful outcomes. **Material and Methods:** It was a prospective study extending for two years in the dermatology department of the UHC Hassan II in Fez, dealing with patients with pemphigus who are severe or resistant to conventional treatments treated with Rituximab. We analyzed the efficacy and tolerance of Rituximab in the treatment of severe and refractory forms of our pemphigus population. **Results:** Patients treated by Rituximab were 13. Eleven cases of pemphigus vulgaris and two cases of superficial pemphigus In our series, Rituximab was used with satisfactory, indeed, 6 patients achieved complete remission, while 4 had partial remission. Side effects of Rituximab were infectious complications. **Conclusions:** We highlight the efficiency and safety of Rituximab in our series.

Key words: Vulgaris pemphigus; Superficial pemphigus; Morocco; Herpetic infection

INTRODUCTION

Pemphigus is a severe autoimmune blistering disease mediated by pathogenic anti-desmoglein antibodies leading to an inter keratinocyte disjunction [1,2]. Rituximab is a monoclonal antibody that binds to the CD-20 antigen of B lymphocytes, which causes B-cell depletion and a subsequent reduction in pathogenic autoantibodies [1,2]. Its therapeutic role in pemphigus has been progressively growing with increasing evidence of successful outcomes. It's an emerging therapy for severe pemphigus vulgaris and superficial pemphigus [1-4].

Objective

Our aim was to analyze the efficacy and tolerance of Rituximab in the treatment of severe and refractory forms of our pemphigus population.

MATERIAL AND METHODS

This is a prospective study extending from 2016 to 2018, in the dermatology department of the CHU Hassan II in Fez, dealing with patients with pemphigus who are severe or resistant to conventional treatments treated with Rituximab. Therapeutic response, duration of remission, therapeutic tolerance and side effects were assessed. All patients received a course of Rituximab at a dose of 375 mg/m2/week for 4 weeks combined with oral corticosteroid therapy at a dose of 0.5 mg/kg/day.

RESULTS

Patients treated by Rituximab were 13. The average age was 55 with extremes ranging from 34 to 75 years, with a clear female predominance with a percentage of 84%. There were 11 cases of pemphigus vulgaris and 2 cases of superficial pemphigus. Nikolski's sign was positive

How to cite this article: Bay Bay H, Senhaji G, Elloudi S, Douhi Z, Mernissi FZ. Efficacy of Rituximab in the treatment of pemphigus: experience of Moroccan population. Our Dermatol Online. 2019;10(4):338-340.

Submission: 27.05.2019; **Acceptance:** 23.07.2019

DOI: 10.7241/ourd.20194.4

in 8 patients. Cutaneous involvement was present in 11 patients. Mucosal involvement was found in 8 patients with erosions. Most patients had severe disease. All our patients had histological confirmation and IFD of their pathology. IFI was very high in all patients.

3 patients were initially treated by Rituximab while 10 others received their Rituximab treatment after failure of other therapies which were oral corticosteroid alone in 1 patient, associated with Azathioprine in 7 patients alone or followed by cyclophosphamide bolus in 3 patients or associated with DDS in 2 patients.

The average duration of follow-up was 6 months. The use of Rituximab was associated with a significant reduction in corticosteroid dose during follow-up. After 3 months, 6 patients achieved complete remission (Figs. 1 and 2), while 4 had partial remission (Figs. 3 and 4) with persistent endobuccal erosions. 2 patients had a relapse of their disease after 6 months of treatment. The relapses were taken care of by a new cure of Rituximab. The control IFI after 6 months had significantly decreased in all patients. No case of death was encountered.

Side effects of Rituximab were seen in 7 patients with delayed and infectious complications. 3 patients had bacterial and urinary cutaneous co-infection, 2 had had herpetic superinfections, while 1 patient had an episode of erysipelas.

DISCUSSION

Our study highlights the efficacy of Rituximab in treating severe and refractory forms of pemphigus to other treatments. Which joins the different studies already published [1-4].

We also demonstrate the interest of this molecule as a first-line treatment in our Moroccan context where

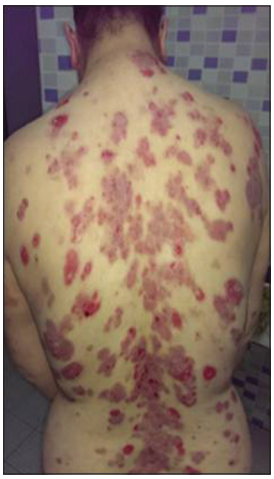

Figure 1: Vulgaris pemphigus before treatment.

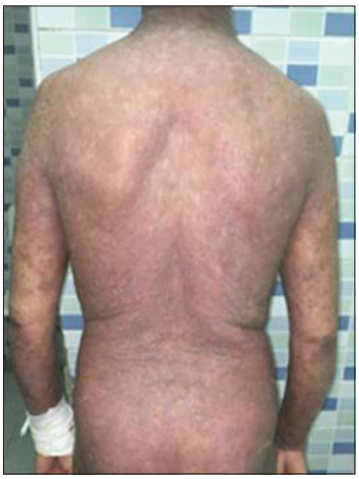

Figure 3: Superficial pemphigus before treatment.

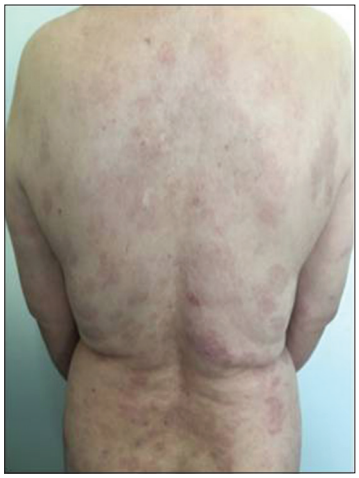

Figure 2: The same patient after 6 months of Rituximab.

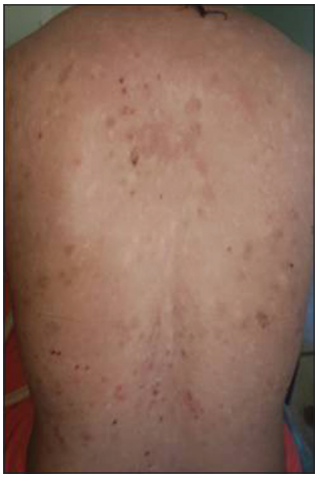

Figure 4: Superficial pemphigus after one month of Rituximab.

severe and extensive forms predominate. This is in perfect concordance with the new data from the literature. Use of Rituximab was beneficial in 77% of patients, leading to faster clinical improvement and longer long-term remission. This in patients who have already received conventional treatment with corticosteroids and immunosuppressants with therapeutic failure. The decline will allow us to assess whether the remissions will be extended. All cases demonstrated significant improvement or complete remission and most experienced no adverse events [4-8] Rituximab appears to be both well tolerated and efficacious for refractory juvenile pemphigus foliaceus [6]. Therefore, it may be considered for severe cases of PF to avoid side effects associated with conventional glucocorticoid therapy [5, 7-10]. This study reinforces the beneficial role of rituximab in pemphigus in our context. Pemphigus foliaceus patients required a higher total cumulative dose of prednisolone over a longer time to achieve remission and the remission lasted longer than that in pemphigus vulgaris [5, 11, 12].

CONCLUSIONS

Treatment with Rituximab is a safe and effective method for the treatment of severe forms of pemphigus and refractory to other treatments in our series. It allows rapid control with cortisone sparing. The main obstacle lies in the cost of this treatment and its support pending marketing authorization in Morocco.

ACKNOWLEDGEMENTS

We are indebted to all patients who participated in this study and gave their consent. We thank all volunteer investigators and the medical staff of the Department of Dermatology, and clinical epidemiology for their enormous help.

Statement of Human and Animal Rights

All procedures followed were in accordance with the ethical standards of the responsible committee on human experimentation (institutional and national) and with the Helsinki Declaration of 1975, as revised in 2008.

Statement of Informed Consent

Informed consent was obtained from all patients for being included in the study.

REFERENCES

1. Ahmed AR, Shetty S. A comprehensive analysis of treatment outcomes in patients with pemphigus vulgaris treated with rituximab. Autoimmun Rev. 2015;14:323-31.
2. Loh TY, Paravar T. Rituximab in the management of juvenile pemphigus foliaceus. Dermatol Online J. 2017; 23(6). pii:13030/qt0415n1r5.
3. Hebert V, Joly P. Rituximab in pemphigus. Immunotherapy. 2018;10:27-37.
4. Baum S, Gilboa S, Greenberger S, Pavlotsky F, Trau H, Barzilai A. Adjuvant rituximab therapy in pemphigus: a single-center experience of 18 cases. J Dermatol Treat. 2013;24:427–30.
5. De D, Bishnoi A, Handa S, Mahapatra T, Mahajan R. Effectiveness and safety analysis of rituximab in 146 Indian pemphigus patients: A retrospective single-center review of up to 68 months follow-up. Indian J Dermatol Venereol Leprol. 2019 May 9. doi: 10.4103/ijdvl.IJDVL_848_17. [Epub ahead of print]
6. Arduino PG, Broccoletti R, Carbone M, Gambino A, Sciannameo V, Conrotto D, et al. Long-term evaluation of pemphigus vulgaris: A retrospective consideration of 98 patients treated in an oral medicine unit in north-west Italy. J Oral Pathol Med. 2019; 48: 406-12.
7. Toosi R, Mahmoudi H, Balighi K, Teimourpour A, Alaeen H, Shaghaghi M, et al. Efficacy and Safety of Biosimilar Rituximab in Patients with Pemphigus Vulgaris: A Prospective Observational Study. J Dermatolog Treat. 201910:1-28.
8. Patsatsi A, Kyriakou A, Douma S, Kokolios M, Meltzanidou P, Lambropoulos A, et al. Non-endemic erythrodermic pemphigus foliaceus: a case with delayed diagnosis and response to rituximab. J Dtsch Dermatol Ges. 2019; 17: 537-9.
9. Kurihara Y, Yamagami J, Funakoshi T, Ishii M, Miyamoto J, Fujio Y, et al. Rituximab therapy for refractory autoimmune bullous diseases: A multicenter, open-label, single-arm, phase 1/2 study on 10 Japanese patients. J Dermatol. 2019; 46:124-30.
10. Kasperkiewicz M, Shimanovich I, Ludwig RJ, Rose C, Zillikens D, Schmidt E. Rituximab for treatment-refractory pemphigus and pemphigoid: a case series of 17 patients. J Am Acad Dermatol. 2011;65:552-8.
11. Kim MR, Kim HC, Kim SC. Long-term prognosis of pemphigus in Korea: retrospective analysis of 199 patients. Dermatology. 2011;223:182-8.
12. Nigam R, Levitt J. J Drugs Dermatol. Where does rituximab fit in the treatment of autoimmune mucocutaneous blistering skin disease? 2012;11:622-5.

Source of Support: Nil, **Conflict of Interest:** None declared.

Brief Report

Alternative topical therapy for post-Scabietic Mastocytoid nodules using pimecrolimus cream 1%

Khalifa E. Sharquie[1], Mohammed M. Shanshal[2]

[1]Department of Dermatology, College of Medicine, University of Baghdad, Iraqi and Arab Board for Dermatology and Venereology, Center of Dermatology and Venereology, Medical City, Baghdad, Iraq, [2]Center of Dermatology and Venereology, Medical City, Baghdad, Iraq

Corresponding author: Prof. Khalifa E. Sharquie, E-mail: ksharquie@ymail.com

ABSTRACT

Background: most recent review of the post-scabietic nodules clinical and histopathological features showed that the mast cells are the predominant cells in 63.63% either alone or admixed with eosinophils. Pimecrolimus cream 1% stabilizes the cell membranes and inhibits the release of histamine from mast cells and basophils and reduces the activation of eosinophils. **Objective:** to evaluate an alternative topical treatment of the post-scabietic nodules according to the histopathological findings. **Patients and methods:** Thirty-four patients with post-scabietic nodules were treated with pimecrolimus cream 1% applied to the lesions twice daily for one month. **Results:** The response after 4 weeks of continuous therapy showed that: A- Seventeen patients (50%) showed a complete response (complete disappearance of itching and the nodules at the end of the treatment period); B-Nine patients (26.47%) showed a partial response (partial reduction in the size and number of the nodules with reduction of itching); C- Eight patients (23.52%) showed no response to therapy (no changes in the size and number of the nodules and severity of itching) **Conclusion:** Pimecrolimus cream 1% is an alternative regimen of therapy for the post-scabietic nodules acting through its pharmacological action in the suppression of the inflammatory mediators in the post-scabietic nodules.

Key words: Scabies; Post-scabietic nodules; Histopathology; Pimecrolimus

INTRODUCTION

Post scabietic nodules are one of the commonest manifestations that are seen after the cure and recovery of scabies. A recent review by Sharquie et al showed that post scabietic nodules are non-excoriated, pigmented dusky red in color and had a tendency to occur in specific predilection areas like the scrotum and penile shaft. Darier sign similar to that observed in mastocytosis was reported in 8.82% and hence the term "post scabietic mastocytoid nodules" was recently applied [1].

The histopathology of post scabietic nodules is a dynamic reaction as the previous studies showed that the main cells in the inflammatory infiltrate are eosinophils and lymphocytes and hence the terms pseudolymphoma and eosinophilioma were used respectively in the past, however; no stain was carried out for the detection of the mast cells [2,3]. While a recent study that used H&E stain and Giemsa stains revealed that there were three patterns of the inflammatory infiltrate in the post scabietic nodules: eosinophils predominant variant in 36.36%, mast cells predominant variant in 27.27% and a mixed cellular variant of eosinophils and mast cells in 36.36% [1].

The already known modalities for the treatment of the post-scabietic nodules including the use of topical and oral corticosteroid, but the drawbacks of these treatments are the plenty side effects [4]. The current study applied pimecrolimus cream 1% as an alternative modality for the treatment of the post-scabietic nodules relying on its pharmacological actions through stabilizing the cell membranes, inhibiting the release of mediators from the mast cells and basophils and reducing the activation of eosinophils [5].

How to cite this article: Sharquie KE, Shanshal MM. Alternative topical therapy for post-Scabietic Mastocytoid nodules using pimecrolimus cream 1%. Our Dermatol Online. 2019;10(4):341-343.

Submission: 26.05.2019; **Acceptance:** 28.07.2019

DOI:10.7241/ourd.20194.5

MATERIALS AND METHODS

This observational therapeutic study was done in the center of Dermatology and Venereology -Baghdad Teaching Hospital, Medical City; Baghdad; Iraq during the period from April 2017- November 2019.

Thirty-four patients with post-scabietic nodules were included in this study, based on the medical history of scabies and clinical examination. Formal consent was taken from all enrolled patients after the nature of the current study was fully explained and ethical approval was performed by the Scientific Council of Dermatology and Venereology-Arab Board for Medical Specialization. The patients were treated with pimecrolimus cream 1% applied to the nodules twice daily for one month.

Assessment of the patient response to treatment was based on the clinical judgment (change in the itching subjectively by the patients, size and the number of the nodules objectively and by photograph assessment). The response was classified into A- *Complete response* (complete disappearance of the nodules and itching). B- *No response* (no change in the size, number of the nodules and the severity of itching).

C- *Partial response* (any response that is less than the complete response).

Ethics Statement

Formal consent was taken from all enrolled patients after the nature of the current study was fully explained and ethical approval was performed by the Scientific Council of Dermatology and Venereology-Arab Board for Medical Specialization

RESULTS

Following the four-week daily application of pimecrolimus cream 1% to the post scabietic nodules, the response of the patients was as the following:

a- Seventeen patients (50%) showed a complete response as there was complete disappearance of itching and the nodules at the end of the treatment period (Fig. 1).

b- Nine patients (26.47%) showed a partial response as there was partial reduction in the size, number of the nodules and itching (Fig. 2).

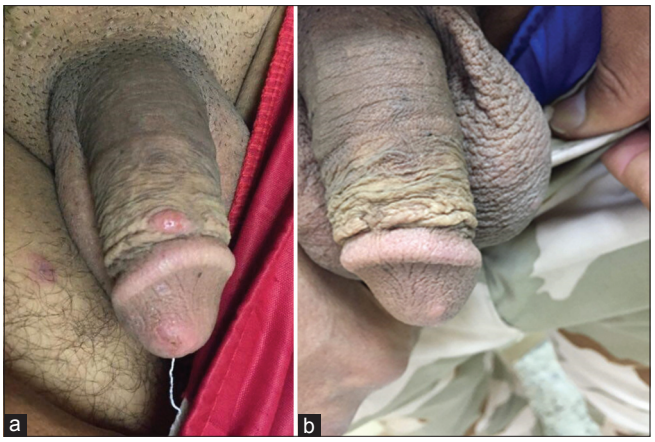

Figure 1: *Post-scabietic nodules* in thirty years old patient before (a) and after (b) the treatment with pimecrolimus cream, with *complete response*.

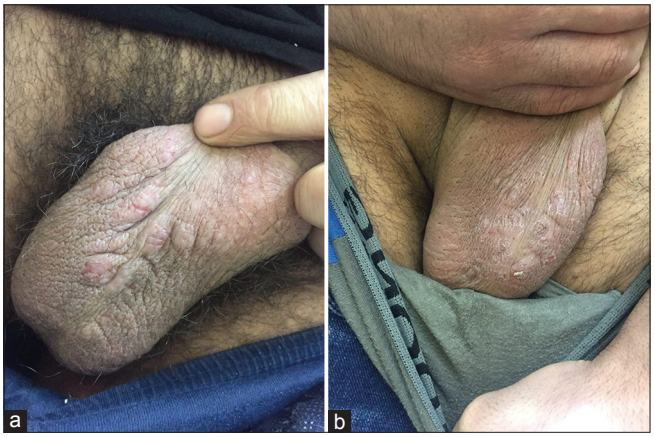

Figure 2: *Post-scabietic nodules* in twenty-five years old patient before (a) and after (b) the treatment with pimecrolimus cream, with *partial response*.

c- Eight patients (23.52%) showed no response as no change in the size and number of the nodules and in the severity of itching.

Side effects were not detected in any of the treated patients. Regarding the relapse rate after cessation of topical pimecrolimus, it could not be determined as the patients did not attend the follow-up visit after they got relief from their disease.

DISCUSSION

Treatment of post scabietic nodules is often problematic as they respond variably to topical, oral steroid +/- antihistamines that are usually followed by a high relapse rate after stopping the therapy [4].

Most recent histopathological evaluation of the post scabietic nodules have shown that the mast cells are

the predominant cells either alone or admixed with eosinophils in the inflammatory infiltrate of post-scabietic nodules. These findings have led us to the use of pimecrolimus cream 1%, a calcineurin inhibitor that has specific effects on the mast cells and eosinophils mainly by stabilizing the cell membrane and preventing their rupture and release of granules [5]. Two previous case reports have evaluated the use of tacrolimus ointment 0.1%, another calcineurin inhibitor, for the treatment of post-scabietic nodules, while only a single case report of successful use of pimecrolimus cream in a single case of steroid-resistant nodular scabies have been reported [6-8].

Hence we planned to use topical pimecrolimus 1% twice a day for one month as a therapy for these post-scabietic nodules and the results were encouraging as 50% of the patients had complete response with complete disappearance of itching and nodules and 26.47% had partial response with reduction in itching and nodular number and size while 23.52% had no response after one month of treatment. Notably, no side effects were reported during the treatment period.

Unfortunately, the limitation of the current study was the difficulty in assessing the relapse rate following the treatment cessation, as most of the treated patients were reluctant to attend the follow-up sessions.

CONCLUSION

The present work showed that pimecrolimus cream 1% is an effective alternative treatment for the post-scabietic mastocytoid nodules acting through its pharmacological action in the suppression of the inflammatory process in these nodules.

Statement of Human and Animal Rights

All procedures followed were in accordance with the ethical standards of the responsible committee on human experimentation (institutional and national) and with the Helsinki Declaration of 1975, as revised in 2008.

Statement of Informed Consent

Informed consent was obtained from all patients for being included in the study.

REFERENCES

1. Sharquie KE, Shanshal MM. Post-Scabietic Mastocytoid nodules: a Clinical and Histopathological Evaluation with new Pearls. Am J Dermatol Venereol. 2019;8:37-40.
2. Sharquie KE, Samer AD. Post-scabietic allergic nodules, Clinical and Histopathological study. J Pan Arab Leag Dermatol. 1997;8:29-35.
3. Sharquie KE, Al-Mashhadani SA, Noaimi AA, Katof WM. Clinical and Sequential Histopathological Study of Scabietic and Postscabietic Nodules. Iraqi Acad Scien J. 2013;12supplement):693-9.
4. Zawar V, Pawar M. Liquid nitrogen cryotherapy in the treatment of chronic, unresponsive nodular scabies. J Am Acad Dermatol. 2017;77:e43-4.
5. Gutfreund K, Bienias W, Szewczyk A, Kaszuba A. Topical calcineurin inhibitors in dermatology. Part I: Properties, method and effectiveness of drug use. Adv Dermatol Allergol. 2013;30:165.
6. Reddy DR, Reddy PR. Nodular scabies: a classical case report in an adolescent boy. J Parasitic Dis. 2015;39:581-3.
7. Mittal A, Garg A, Agarwal N, Gupta L, Khare AK. Treatment of nodular scabies with topical tacrolimus. Indian Dermatol Online J. 2013;4:52.
8. de Almeida HL. Treatment of steroid-resistant nodular scabies with topical pimecrolimus. J Am Acad Dermatol. 2005;53:357-8.

Source of Support: Nil, **Conflict of Interest:** None declared.

Brief Report

Quality of life assessment in males with androgenetic alopecia – a prospective study

Mrinal Gupta

Department of Dermatology, Treatwell Skin Centre, Jammu and Kashmir, India

Corresponding author: Dr. Mrinal Gupta, E-mail: drmrinalgupta@yahoo.com

ABSTRACT

Background: Androgenetic alopecia (AGA) is a common hair loss disorder with genetic predisposition seen commonly in men. Even though the condition is harmless, non-life threatening but it causes a significant amount of psychological stress and affects the individual's overall quality of life (QoL). **Objectives:** This study was carried out to assess the QoL in patients with AGA using the Dermatology Life Quality Index (DLQI) questionnaire. **Methods:** A total of 100 male AGA patients were enrolled in this study, and DLQI was used to evaluate the QoL of the patients. The DLQI uses 10 items regarding symptoms and feelings, daily activities, leisure, work and school, personal relationships, and treatment as dimensions of life, each scored on a 0–3 scale. The total DLQI score equals 0–30; higher scores showing greater impact on QoL. **Results:** The study population comprised of 100 males aged between 19 to 58 years with a mean age of 28.3±6.4 years. DLQI scores ranged from 2 to 21 with a mean score of 5.28. Higher DLQI scores were observed in younger patients and in patients with a long standing disease, as well as in patients with higher education and in unmarried population. Higher scores were obtained for questions pertaining to self image perception and social interaction impairment. **Conclusion:** Patients with AGA have a significantly decreased quality of life. A higher DLQI score was seen in younger age, long standing hair loss and in severe grades of alopecia. AGA is associated with a lowered self esteem.

Key words: Androgenetic alopecia, Quality of life; DLQI

INTRODUCTION

Androgenetic alopecia (AGA) is considered to be the most common type of baldness characterized by progressive hair loss in genetically predisposed individuals. The prevalence rates among general population have been shown to range from 14% to 58%, with a tendency to increase with age [1]. Although AGA is a relatively benign dermatological condition, but as hair is an important component of identity and self image, patients with AGA may experience a distorted body image and negative feelings. Various studies have demonstrated that AGA can have a significant negative impact on the quality of life of the affected persons and even clinically imperceptible hair loss has been correlated with a decreased quality of life [2,3]. One of the most important psychological aspects related to AGA is related to the true or imagined perceptions of others. Few studies have reported that the QoL of patients with hair loss was lower than that of patients with cardiovascular disease, diabetes, and cancer [4]. Therefore, it is very important to understand the impact of alopecia on the QoL of patients while assessing its severity.

This study was carried out to assess the QoL in patients with AGA and its association with duration, age of onset and severity.

MATERIALS AND METHODS

This was a prospective study carried out over a period of one year in our centre in which one hundred male patients aged >18 years with AGA were included. Patients with severe seborrheic dermatitis, alopecic disease, except for androgenic alopecia, and scalp

How to cite this article: Gupta M. Quality of life assessment in males with androgenetic alopecia – a prospective study. Our Dermatol Online. 2019;10(4):344-348.
Submission: 29.04.2018; **Acceptance:** 18.06.2018
DOI:10.7241/ourd.20194.6

disorders, such as scalp psoriasis and infection were excluded. All the patients were otherwise mentally and physically healthy and provided written informed consent before participation.

All the patients were evaluated and details like age of onset, duration of disease, severity grading of alopecia was done and details recorded in a structured proforma. The DLQI questionnaire consisted of 10 questions regarding symptoms and feelings, daily activities, leisure, work and school, personal relationships, and treatment as dimensions of life. Each item was scored on a scale of 0–3 points. Scores were added to yield a total DLQI of 0–30 points; higher scores indicated greater impact on the patient's QoL (Table 1).

The patient's alopecia severity was graded on the basis of Norwood's classification as mild (Grade I and II), moderate (Grade III and IV) and severe (Grade V, VI and VII) [5].

RESULTS

The study population comprised of 100 males aged between 19 to 58 years with a mean age of 28.3±6.4 years with 40 patients having mild, 32 having moderate and 28 having severe alopecia. Among the study population, the DLQI scores ranged from 2 to 21 with a mean score of 5.28. Hair loss had the maximum impact on the self esteem and social interaction as seen from the total DLQI scores which were much higher for Questions 2, 3 and 5 (Fig. 1). It was observed that the DLQI score was related to various clinical characteristics as a higher score was seen in younger patients and in patients with a long standing disease. DLQI scores were also related to the educational and marital status as higher scores were observed in patients with higher education and in unmarried population. The clinical characteristics of the study population are shown in Table 2. Patients with moderate or severe hair loss had significant impairment of self esteem as higher scores were observed in these groups in questions related to social interactions and self image perception (Fig. 2).

DISCUSSION

Hair has a significant role in the overall appearance of the person which has various social and interpersonal implications. In the sociocultural context, hair has been given a lot of importance and abundant hair has symbolized vitality, health, and virility, whereas loss or removal of hair can connote subjugation, loss of individuality, impotency, and/or decrepitude. Hair quality and appearance can be an indicator of attractiveness and sexuality for many people, and visible hair loss can have a major negative impact. Hair loss significantly impacts an individual's self image, and studies indicate that patients with hair loss may have significantly decreased quality of life. Quality of life is defined as the subjective perception of the impact on the health status and on the physical, psychological, and social functioning and well-being of the patients. Quality of life assessments help, in clinical practice, clinicians to make judgments about which aspects of daily life are most affected by the disease.

In our study, the mean DLQI score was 5.28 which are comparable to the score of 6.3±6.3 reported by Zhang et al in 178 patients of AGA [4]. Williamson et al also reported a mean score of 8.3±5.6 in 70 patients with alopecia [6]. Our study showed that AGA moderately affected the QoL, including feelings of loss of self-confidence and low self-esteem. In our study, higher scores were recorded for questions 2, 3 and 5 in the questionnaire which reflected the significant lowered self esteem and self perception of one's appearance due to hair loss and hence the impaired social well being of the patients. We observed higher DLQI scores in younger patients, patients with long standing hair loss and in higher grades of alopecia. These results are in accordance with the findings by Han et al who also reported that younger patients, patients with long standing and severe alopecia experienced more psychosocial impairment and substantial distress [7]. Zhang et al also reported higher DLQI scores in younger age group, long standing disease and in severe grades of alopecia [4].

Numerous studies have shown that women with hair loss experience increased self-consciousness, feelings of unattractiveness, social withdrawal, emotional stress, low

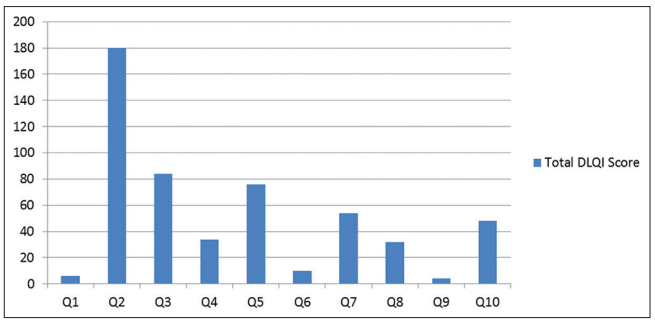

Figure 1 : Total DLQI score for the 10 questions. (DLQI - Dermatology Life Quality Index)

Table 1: The Dermatology Life Quality Index

DERMATOLOGY LIFE QUALITY INDEX			
Hospital No:	**Date:**		
Name:	**Score:**		
Address:	**Diagnosis:**		
The aim of this questionnaire is to measure how much your skin problem has affected your life OVER THE LAST WEEK. Please tick ✓ one box for each question			
1. Over the last week, how itchy, sore, painful or stinging has your skinbeen?	Very much	❒	
	A lot	❒	
	A little	❒	
	Not at all	❒	
2. Over the last week, how embarrassed or self conscious have you been because of your skin?	Very much	❒	
	A lot	❒	
	A little	❒	
	Not at all	❒	
3. Over the last week, how much has your skin interfered with you going shopping or looking after your home orgarden?	Very much	❒	
	A lot	❒	
	A little	❒	
	Not at all	❒	Not relevant ❒
4. Over the last week, how much has your skin influenced the clothes you wear?	Very much	❒	
	A lot	❒	
	A little	❒	
	Not at all	❒	Not relevant ❒
5. Over the last week, how much has your skin affected any social or leisure activities?	Very much	❒	
	A lot	❒	
	A little	❒	
	Not at all	❒	Not relevant ❒
6. Over the last week, how much has your skin made it difficult for you to do any sport?	Very much	❒	
	A lot	❒	
	A little	❒	
	Not at all	❒	Not relevant ❒
7. Over the last week, has your skin prevented you from working or studying?	Yes	❒	
	No		Not relevant ❒
If "No", over the last week how much has your skin been a problem at work or studying?	A lot	❒	
	A little	❒	
	Not at all	❒	
8. Over the last week, how much has your skin created problems with your partner or any of your close friendsor relatives?	Very much	❒	
	A lot		
	A little	❒	
	Not at all	❒	Not relevant ❒
9. Over the last week, how much has your skin caused any sexual difficulties?	Very much	❒	
	A lot	❒	
	A little	❒	
	Not at all	❒	Not relevant ❒

(Contd...)

Table 1: *(Continued)*

DERMATOLOGY LIFE QUALITY INDEX			
Hospital No:	**Date:**		
Name:	**Score:**		
Address:	**Diagnosis:**		
The aim of this questionnaire is to measure how much your skin problem has affected your life OVER THE LAST WEEK. Please tick ✓ one box for each question			
10. Over the last week, how much of a problem has the treatment for your skin been, for example by makingyour home messy, or by taking up time?	Very much	❒	
	A lot	❒	
	A little	❒	
	Not at all	❒	Not relevant ❒
		❒	
		❒	
Please check you have answered EVERY question. Thank you.			

Each question is answered "Very much" (score 3), "A lot" (score 2), "A little" (score 1), or "Not at all" (score 0). The first part of question 7 has the choices "Yes" (score 3), "No", or "Not relevant" (score 0). The maximum score (indicating highest possible impairment of quality of life) is 30 and the minimum 0.

Reproduced from Finlay AY, Khan GK. Dermatology Life Quality Index (DLQI) – a simple practical measure for routine clinical use. Clin Exp Dermatol. 1994;19(3):210–216.6 © Dermatology Life Quality Index. AY Finlay, GK Khan, April 1992.

Table 2 : Clinical characteristics of the study population.

Clinical characteristics	Number of cases	Mean DLQI score	Student's t test	P value
Age			0.216	0.424
<30 yrs	58	4.413		
>30 yrs	42	6.476		
Marital status			0.072	0.474
Single	47	5.957		
Married	53	4.566		
Education level			0.697	0.278
Up to high	26	3.769		
..school	74	5.81		
College or more				
Duration of hair			0.281	0.402
loss (months)	41	5.170		
<12 months	59	5.3559		
>12 months				
Alopecia severity			0.163	0.442
Mild	40	4.45		
Moderate	32	5.156		
Severe	28	6.607		

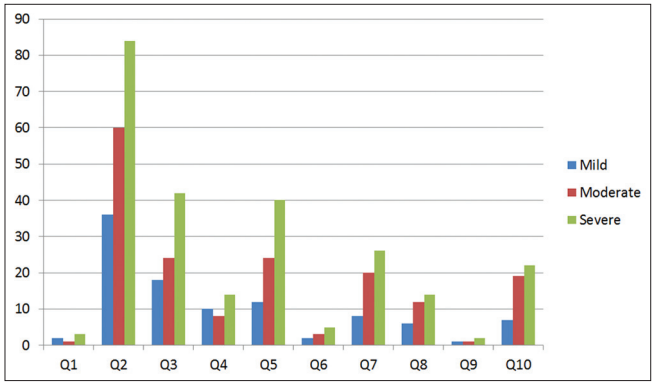

Figure 2: Total DLQI scores for different questions for different grades of hair loss. (DLQI - Dermatology Life Quality Index)

self esteem, and worry [8]. Recently, a number of studies have also verified the psychosocial difficulties experienced by men with hair loss where it was seen that men with hair loss are generally seen by others as being significantly older, less physically and socially attractive, weaker, duller, and less potent than their peers [7]. It has been revealed that men who had more profound hair loss were more dissatisfied with their appearance and were more concerned with their older look than those with minimal hair loss and had lower self esteem. This effect cut across all age groups but was more prominent in the younger individuals. Physical appearance is extremely important to most young men, and early onset of hair loss can have a definite negative effect on self-image and self-esteem. Low self-esteem can cause significant difficulty for males especially when finding life partners and employment. This appears to be a result of the emphasis and importance of physical appearance and body image in social settings.

The present study had several limitations. First, all the patients in our study were recruited in dermatology outpatient centre and selection bias may, therefore, have affected the results. Also, the study sample was relatively small.

CONCLUSION

Patients with AGA have a significantly decreased quality of life. A higher DLQI score was seen in younger age, long standing hair loss and in severe grades of alopecia. AGA is associated with a lowered self esteem which in turn leads to functional consequences in

societal and interpersonal interactions. It is important that physicians consider the psychosocial impact of AGA on different aspects of patient's lives.

Statement of Human and Animal Rights

All procedures followed were in accordance with the ethical standards of the responsible committee on human experimentation (institutional and national) and with the Helsinki Declaration of 1975, as revised in 2008.

Statement of Informed Consent

Informed consent was obtained from all patients for being included in the study.

REFERENCES

1. Kaliyadan F, Nambiar A, Vijayaraghavan S. Androgenetic alopecia: An update. Indian J Dermatol Venereol Leprol. 2013;79:613-25.
2. Hunt N, McHale S. The psychological impact of alopecia. BMJ: Br Med J. 2005;331:951.
3. Poot F. Psychological consequences of chronic hair diseases. Rev Med Brux. 2004;25:A286-8.
4. Zhang M, Zhang N. Quality of life assessment in patients with alopecia areata and androgenetic alopecia in the People's Republic of China. Patient Pref Adher. 2017;11:151.
5. Gupta M, Mysore V. Classifications of patterned hair loss: a review. J Cutan Aesthet Sur. 2016;9:3-12.
6. Williamson D, Gonzalez M, Finlay AY. The effect of hair loss on quality of life. J Eur Acad Dermatol Venereol. 2001;15:137–9.
7. Han SH, Byun JW, Lee WS, Kang H, Kye YC, Kim KH, et al. Quality of life assessment in male patients with androgenetic alopecia: result of a prospective, multicenter study. Ann Dermatol. 2012;24:311-8.
8. Williamson D, Gonzalez M, Finlay AY. The effect of hair loss on quality of life. J Eur Acad Dermatol Venereol. 2001;15:137-9.

Source of Support: Nil, **Conflict of Interest:** None declared.

Case Report

Atypical paraneoplastic pemphigus associated with pulmonary adenocarcinoma

Almamy Diabaté, Ali Naqi, Julien Pittoni, Romain Prud'homme, Assikar Safae, Iona Matei, Christophe Bedane

Unit of Dermatology, University Hospital of Dupuytren, and CNRMBAI, Limoges, France

Corresponding author: Dr. Almamy Diabaté, E-mail: docalmamy@yahoo.fr

ABSTRACT

Paraneoplastic pemphigus (PNP) is a muco-cutaneous autoimmune disease associated with several types of internal malignancy. We report a case of a 57-year-old male with an atypical form of PNP associated with pulmonary adenocarcinoma. There was no involvement of the mucous membranes. Although the macroscopic and histological appearances were typical of a pemphigus, the direct immunofluorescence was positive for the IgG staining and the C3 intercellular. Circulating antibodies were detected with envoplakin, periplakin and desmoplakins 1 and 2; but the Ac anti desmoglein 1 IgG and 3 IgG, BP 180 and BP 230 and auto Ac anti-epidermis were negative. The clinical evolvement was observed with a combination of systemic corticosteroids and radiotherapy associated with Cisplatin-Alimta chemotherapy.

Key words: Paraneoplastic pemphigus; Pulmonary adenocarcinoma

INTRODUCTION

Paraneoplastic pemphigus (PNP) is a distinct autoimmune disease that is associated with underlying malignancy including lymphoproliferative diseases and adenocarcinoma. The typical form of PNP occurs most often between 45 and 70 years of age, with floral lesions of the oral mucosa, a generalized polymorphic rash. His diagnosis is based on investigations including tumour identification, histopathological studies, immunofluorescence and serum immunological studies [1-3]. The atypical PNP has been rarely described in the literature [4]. We report a case of atypical PNP with no mucosal lesions associated with pulmonary adenocarcinoma in a 57-year-old male.

CASE REPORT

A 57-year-old patient of phenotype 2, active smoker (40 packs a year) consulted in the dermatology unit at Dupuytren Hospital in Limoges in January 2015 for a pustular palmoplantar rash associated with pruritus which was treated with dermo-corticoid and acitretin (SORIATANE 25) for a probable psoriasis. In his antecedents, he had a tonsillectomy in 2005, and he is allergic to aspirin. In September 2015, the pustular rash became widespread reaching the nails, palms of the hands (Fig. 1), and the sole of the foot, accompanied by impetiginization without mucosal involvement. The paraclinical investigation showed a biologically leukocytosis at 18.3 giga/L and Polynuclear Neutrophils at 11.16 giga/L. The platelet count, the blood ionogram, the hepatic and renal status, LDH, VS and CRP were normal. The electrophoresis of the proteins found a hypoalbuminemia without viewable monoclonal component. The viral serology for HIV, HBV and HCV were negative. The immunological investigation showed a negative indirect immunofluorescence for Ac anti desmoglein 1 IgG and 3 IgG, BP 180 and BP 230, an absence of auto Ac anti-epidermis and antibodies anti-envoplakin, anti-periplakin and desmoplakins 1 and 2 were positive. Histologically, there was a discrete spongiosis, no intra-epidermal vesicles in the epidermis, sub-epithelial detachment, (the bubble cavity filled with many inflammatory elements with Neurophile Polynuclear and Eosinophilic

How to cite this article: Diabaté A, Naqi A, Prud'homme R, Safae A, Matei I, Bedane C. Atypical paraneoplastic pemphigus associated with pulmonary adenocarcinoma. Our Dermatol Online. 2019;10(4):349-351.

Submission: 31.03.2019; **Acceptance:** 02.08.2019

DOI: 10.7241/ourd.20194.7

Polynuclear with Vacuolar alteration in the dermal-epidermal junction. In the superficial dermis, there were perivascular lymphocyte infiltrate, polymorphic inflammatory infiltrate (predominantly PNE) (Fig. 2). The direct IgA immunofluorescence was negative, IgG intracellular substance was strongly positive and the factor C3 complement of the intracellular substance was also positive for basal staining. Radiographically, the TAP scanner more cerebral showed a necrotic pathological pulmonary mediastinal and hilar mass. The pet scan confirmed the presence of right para-hilar tumour with ipsilateral mediastinal ganglia, under the coronary and retro-clavicular right wing (Fig. 3). The bronchial endoscopy with mediastinal ganglionic puncture showed the presence of carcinomatous groups, which were suggestive of adenocarcinoma. There was an absence of BRAF, KRAS, HER2 mutations. Considering this bundle of evidence, the diagnosis of a paraneoplastic pemphigus with pulmonary adenocarcinoma was retained. The treatment undertaken was for the pemphigus 0.5 mg/kg/day of prednisone or 40 mg/day and for the pulmonary adenocarcinoma, a radiotherapy and chemotherapy with Cisplatin-Alimta. After a six-month-post-treatment, the skin of the patient returned to normal with a recovery of four kilograms of weight, but there was a persistence of nail lesions of the feet.

Prior to the study, patient gave written consent to the examination and biopsy after having been informed about the procedure.

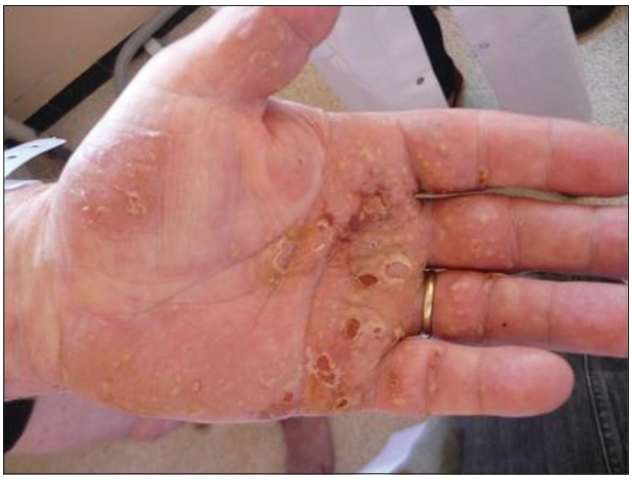

Figure 1: Palmar bullous eruption.

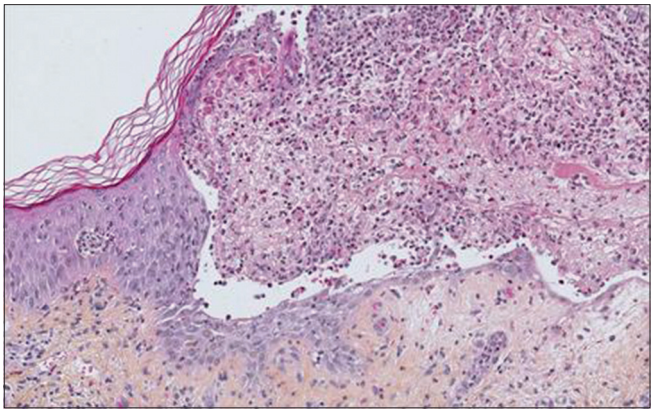

Figure 2: Histology of pemphigus paraneoplasia.

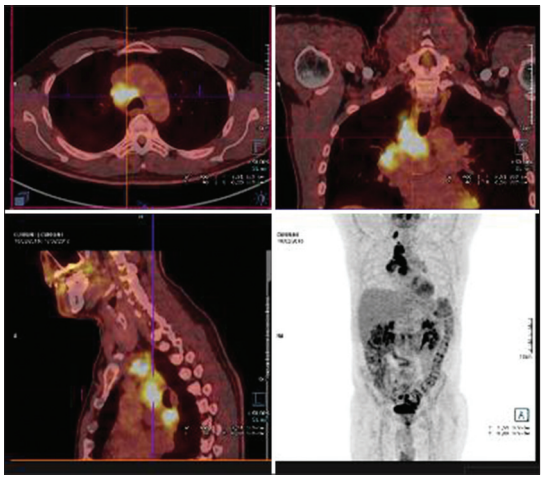

Figure 3: Pulmonary adenocarcinoma with PET scan.

DISCUSSION

The classic PNP described by Anhalt in 1990 in the 45-70 age group predominated in males and the associated diseases were lymphoproliferative diseases and adenocarcinomas. Clinically, erosive and ulcerative mucosal lesions are consistent signs of the disease and skin lesions are polymorphic [1-3]. Our observation is distinguished by the purely cutaneous involvement at the clinical level. This atypical form without mucosal involvement was described by Kennedy [4] in 2009 in a 78-year-old woman with recurrent endometrial cancer. The antibodies desmoglein 1 IgG and 3 IgG, BP 180 and BP 230 were negative; however, the direct immunofluorescence was positive for the inter-cellular IgG and C3 staining and the presence of antibodies anti-envoplakin, anti-periplakin and desmoplakin 1 and 2. This negativity of the indirect immunofluorescence was described by Wong [5]. According to Wong [5], these are modified criteria for the PNP. Moreover, this negation of antibodies anti-desmoglein IgG 1 and IgG 3 is not correlated with isolated mucosal involvement or muco-cutaneous involvement [6]. The tumour associated with the PNP is usually lymphoproliferative tumours [1,7-9]. Some authors [4,5,10] described the PNP with solid tumours as in our observation which

shows a pulmonary adenocarcinoma. The evolution of our patient was satisfactory under corticosteroid combined with radiotherapy coupled with Cisplatin-Alimta chemotherapy. Kennedy [4] in his case associated corticosteroids with resection of the tumour. In general, the prognosis is poor, not only because of the possible progression of malignant tumours, but also because the treatment often leads to infectious complications, which is the most common cause of death in PNP patients [3].

CONCLUSION

This observation presents an atypical form of PNP. This case suggests that, in addition to the typical form, other pauci-symptomatic forms may be involved in PNP. Nevertheless, it is the histological and immunological investigations that allow the diagnosis.

Consent

The examination of the patient was conducted according to the Declaration of Helsinki principles.

REFERENCES

1. Jiang Q, Zhang BH. Paraneoplastic pemphigus associated with chronic lymphocytic leukemia: A case report. Med (Baltimore). 2017;96:6184.
2. Yong AA, Tey HL. Paraneoplastic pemphigus. Australas J Dermatol. 2013;54:241-50.
3. Wieczorek M, Czernik A. Paraneoplastic pemphigus: a short review. Clin Cosmet Investig Dermatol. 2016;23:291-5.
4. Kennedy NA, Dawe S. Atypical paraneoplastic pemphigus secondary to endometrial carcinoma with no mucosal involvement. Clin Exp Dermatol. 2009;34:130-3.
5. Wong KC, Ho KK. Pemphigus with pemphigoid-like presentation, associated with squamous cell carcinoma of the tongue, Australas J Dermatol. 2000;41:178–80.
6. Ohyama M, Amagai M, Hashimoto T, Nousari HC, Anhalt GJ, Nishikawa T. Clinical phenotype and anti-desmoglein autoantibody profile in paraneoplastic pemphigus. J Am Acad Dermatol. 2001;44:593-8.
7. Taintor AR, Leiferman KM, Hashimoto T, Ishii N, Zone JJ, Hull CM. A novel case of IgA paraneoplastic pemphigus associated with chronic lymphocytic leukemia. J Am Acad Dermatol. 2007;56:S73-6.
8. Nikolskaia OV, Nousari CH, Anhalt GJ.Paraneoplastic pemphigus in association with Castleman's disease. Br J Dermatol. 2003;149:1143-51.
9. Mimouni D, Anhalt GJ, Lazarova Z, Aho S, Kazerounian S, Kouba DJ, et al. Paraneoplastic pemphigus in children and adolescents. Br J Dermatol. 2002;147:725-32.
10. Zheng S, Gaojie L, Jianping L, Tingfeng F, Yunjie Z, Huayao Z, et al. Paraneoplastic pemphigus associated with follicular dendritic cell sarcoma: report of a case and review of literature, Int J Clin Exp Pathol. 2015;8:11983–94.

Source of Support: Nil, **Conflict of Interest:** None declared.

Case Report

Atypical scleromyxedema improved by immunoglobulins intravenous

Hanane Baybay[1], Amina Lamouaffaq[1], Mounia Bennani[1], Ghita Senhaji[1], Zakia Douhi[1], Sara Elloud[1], Mounia Rimani[2], Fatima Zahra Mernissi[1]

[1]Department of Dermatology, University Hospital Hassan II, Fez, Morocco, [2]Hassan Center of Anatomo-Pathology, Rabat, Morocco

Corresponding author: Dr. Hanane Baybay, E-mail: Hananebaybay@gmail.com

ABSTRACT

Scleromyxedema is a rare condition that occurs in middle-aged people. The association with a monoclonal gammopathy is a main criterion for the diagnosis of typical forms. Its pathogenesis is poorly understood. Clinically characterized by a generalized papular eruption with firm papules of 2-3 mm in diameter, waxy in appearance, localised in the hands, forearms, head, neck, upper trunk and thighs. The most frequent extra-cutaneous manifestations include haematological, neurological, cardiac, digestive, rheumatologic and respiratory disorders. Histological findings show fibroblast proliferation, mucin deposition, and fibrosis. The low number of cases and the lack of randomized study make the therapeutic choice difficult. There is currently no formal consensus regarding its therapeutic management. Several therapeutic modalities have been reported such as steroids, retinoids, PUVA, interferon, plasmapheresis, chemotherapy, electrotherapy, thalidomide or immunoglobulins. The efficacy of immunoglobulins intravenous and their lower toxicity make them a treatment of choice for scleromyxedema. We report a case of isolated scleromyxedema with favorable evolution under immunoglobulins and Thalidomide.

Key words: Cleromyxedema; Histology; Immunoglobulins intravenous

INTRODUCTION

Scleromyxedema is a variant of papular mucinosis affecting the skin and internal organs that occurs in middle-aged people [1,2]. The different therapeutic approaches proposed for scleromyxoedema are still unsatisfactory. Intravenous immunoglobulin (IVIg) has been successfully employed in this dermatosis which the evolution is unpredictable [1,2]. The low number of cases and the lack of randomized study make the therapeutic choice difficult. There is currently no formal consensus regarding its therapeutic management [1]. We report a case of isolated scleromyxedema with favorable evolution under immunoglobulins maintained by synthetic antimalarials and Thalidomide.

CASE REPORT

This is a 62-year-old patient, with no pathological history, who presented about 20 days, small papules with normal skin color in some sites and ivory by others, about 2-3 mm in diameter, interesting the face, hands, forearms, neck, upper back as well as retro-auricular, followed by the installation of bilateral palpebral edema with palpebral occlusion, as well as hands and feet (Figs. 1-3). The patient had benefited from a biological assessment showing a negative proteinuria of 24 hours, the assessment in search of monoclonal gammopathy was negative, a correct thyroid assessment. Abdominal CT scan showing digestive thickening of D2 of inflammatory origin. Minimal pericardial effusion at transthoracic echography.

Cutaneous histology showed densified squamous collagen bundles, alcianophilous deposition with Alcian blue and metachromatic Toluidine blue, as well as proliferation of fibroblasts.

The diagnosis of diffuse scleromyxedema was retained and the patient was placed on intravenous immunoglobulin at a dose of 21 g/day for 5 days/month

How to cite this article: Baybay H, Lamouaffaq A, Bennani M, Senhaji G, Douhi Z, Elloud S, Rimani M, Mernissi FZ. Atypical scleromyxedema improved by immunoglobulins intravenous. Our Dermatol Online. 2019;10(4):352-354.

Submission: 08.11.2018; **Acceptance:** 06.01.2019

DOI: 10.7241/ourd.20194.8

for 6 months with good improvement after just two months. This regression was maintained by thalidomide at a dose of 100 mg/day combined with synthetic antimalarials at a dose of 200 mg/day (Figs. 4-6). The recoil without recurrence is two years.

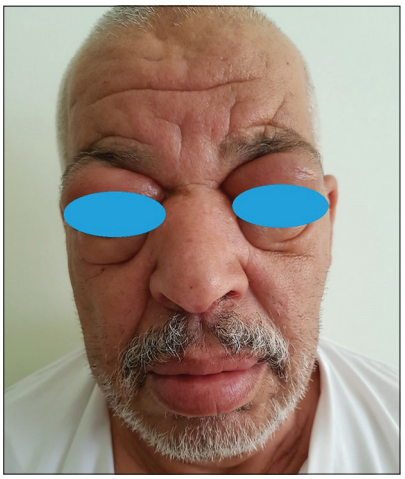

Figure 1: Pre-treatment patient with edema of the eyelids.

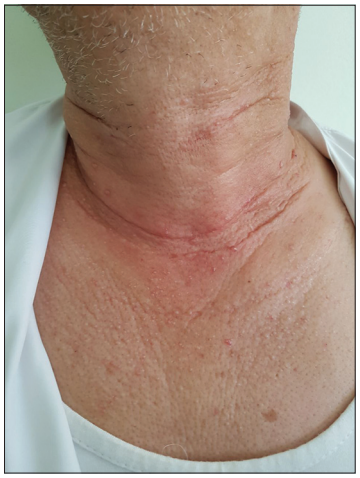

Figure 2: Pre-treatment patient with edema and papules normal skin and ivory color in the neck.

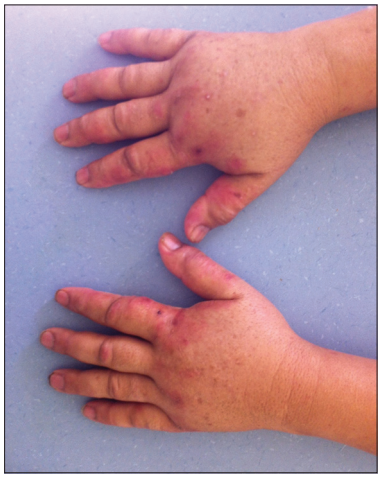

Figure 3: Pre-treatment patient with edema and papules normal skin and ivory color of the hands.

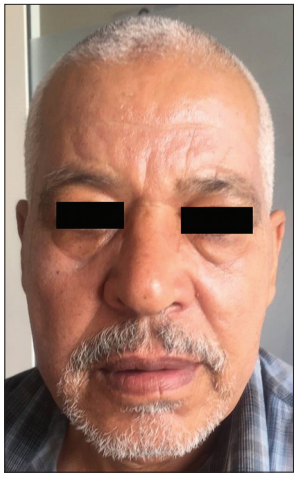

Figure 4: Patient after 2 courses of intravenous immunoglobulins: regression of edema of the eyelids.

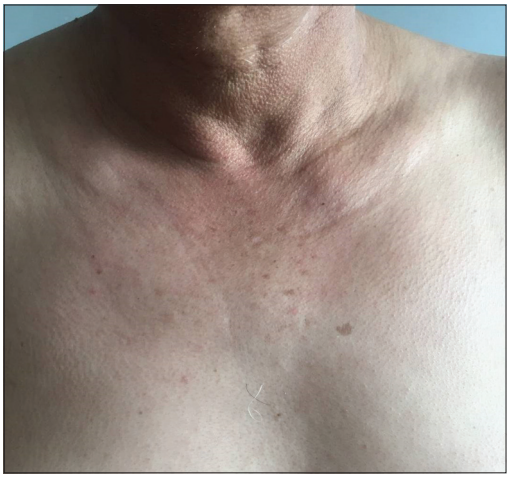

Figure 5: Patient after 2 courses of intravenous immunoglobulins: regression of edema and papules in the neck.

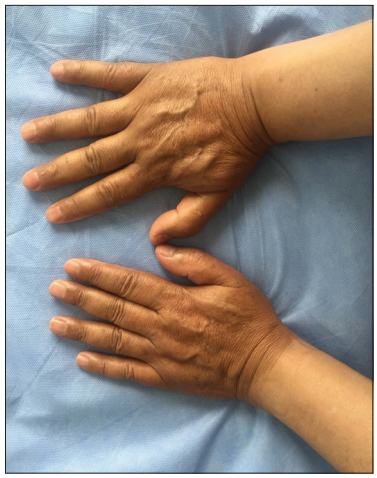

Figure 6: Patient after 2 courses of intravenous immunoglobulins: regression of edema and papules of the hands.

DISCUSSION

Scleromyxedema is a rare disease, that usually affects adults between the ages of 30 and 80 years with no race or gender predominance. The pathogenesis remains unclear, the main hypothesis is that circulating cytokines such as IL-1, TNF-alpha and TGF-beta, which are known to stimulate glycosaminoglycan synthesis and fibroblast proliferation in the skin, could play a role [3,4]. It belongs to the spectrum of cutaneous mucinoses and is characterized by a generalized papular eruption [4]. The rash, very often itchy, consists of firm papules of 2-3 mm in diameter, waxy in appearance [5], closely spaced, dome-shaped or flattopped papules involving the hands, forearms, head, neck, upper trunk and thighs. Papules are often arranged in a strikingly linear array, and the surrounding skin is shiny and indurate (sclerodermoid) in appearance [3]. Evolution is unpredictable. The entire skin can be reached with functional prognosis. The mucous membranes are spared [5]. Extracutaneous manifestations include neurological signs that can lead to coma and death. Cardiac, gastrointestinal, rheumatologic, muscular, vascular specially Raynaud's syndrome and respiratory manifestations are also described [1,4,5]. Hematologic involvement (monoclonal gammopathy) is very often associated. In 80% of cases, it is a IgG lambda monoclonal dysglobulinemia of undetermined significance, rarely evolving to a myeloma (less than 10%) [2,5]. Histological findings show fibroblast proliferation, mucin deposition, and fibrosis. Because of the rarity of the disorder, there are neither well-designed clinical trials nor consensus about an effective treatment [4].

The prognosis seems reserved with mortality around 30-40% at 2 years [1].

There is currently no formal consensus on therapeutic management, and the treatment is difficult despite the multiplicity of therapeutic possibilities: steroids, retinoids, PUVA, interferon, plasmapheresis, chemotherapy, electrotherapy, thalidomide or veinoglobulins [1,2]. Our patient has improved remarkably since the first treatment cure of immunoglobulins. The Thalidomide combined with synthetic antimalarials were interesting for maintenance treatment because of their immunomodulator and antiinflamatory effect.

CONCLUSION

Scleromyxedema remains a complex pathology that is difficult to treat. The initial efficacy with immunoglobulins is most often remarkable and the side effects are usually minor and transient. However, their use remains limited by their cost and availability. For maintenance treatment; Thalidomide and synthetic antimalarials sounds a good therapeutic modality.

Consent

The examination of the patient was conducted according to the Declaration of Helsinki principles.

REFERENCES

1. Garcia B, Lasek A, Modiano P. Évolution favorable d'un scléromyxœdème d'Arndt Gottron sous immunoglobulines polyvalentes. Rev Méd Intern. 2017;38;A110–A225.
2. Rongioletti F, Baldari M, Cozzani E, Parodi A. Traitement du scléromyxœdème par immunoglobulines intraveineuses, Ann Dermatol Venereol. 2005;132:9S280-9.
3. Knobler R, Moinzadeh P, Hunzelmann N et al. European dermatology forum S1-guideline on the diagnosis and treatment of sclerosing diseases of the skin, Part 2: Scleromyxedema, scleredema and nephrogenic systemic fibrosisn. J Eur Acad Dermatol Venereol. 2017;31:1581-94.
4. Guarenti I, Sebastiani V, Pinto G, Ricardo de Souza P, De Almeida H. Successful treatment of scleromyxedema with oral thalidomide. Int J Dermatol. 2013;52:631–44.
5. Sillard L, Passeron T, Cardot-Leccia N, Perrin C, Lacour J. P, Ortonne P. Efficacy of intravenous immunoglobulin in the treatment of scleromyxoedema. Ann Dermatol Vénéréol. 2010;137:48-52.

Source of Support: Nil, **Conflict of Interest:** None declared.

Case Report

Atrophoderma of Pasini and Pierini: An unusual presentation

Romita Bachaspatimayum, Nandita Bhattacharjee, Priyanka Das

Department of Dermatology, Venereology and Leprology, Regional Institute of Medical Sciences, Imphal, Manipur, India

Corresponding author: Dr. Nandita Bhattacharjee, E-mail: piyubhattacharjee@gmail.com

ABSTRACT

Atrophoderma of Pasini and Pierini is a rare variant of dermal atrophy with unknown etiology. It is characterised by one or more asymptomatic, bilaterally symmetrical, well defined, hyperpigmented, non sclerotic patches with an abrupt edge, distributed mostly over the trunk. We report here a 19 year old female presenting with single, asymptomatic, round, hypopigmented, non-indurated, slightly depressed patch over lateral aspect of left arm. The histopathological examination revealed orthokeratotic epidermis and degenerated loosely separated collagen bundles in the mid and reticular dermis. A diagnosis of atrophoderma of Pasini and Pierini was made. The patient was treated with oral hydroxychloroquine 200 mg twice daily. There was significant improvement after 2 months of treatment.

Key words: Atrophoderma of Pasini and Pierini; Hypopigmented patch; Hydroxychloroquine

INTRODUCTION

Atrophoderma of Pasini and Pierini is a rare disorder of idiopathic dermal atrophy. It was first reported by Pasini [1] in 1923 as progressive idiopathic atrophoderma and later defined by Pierini and Vivoli [2] in 1936. In 1958, Canizares et al.[3] evaluated the findings of Pierini and renamed it as idiopathic atrophoderma of Pasini and Pierini. They also believed that it differed adequately from morphea. It is characterized by asymptomatic, round to oval, bluish gray to brown, non-indurated patches with mild depression and "cliff drop" margin. Here we report a case of atrophoderma of Pasini and Pierini in a young female.

CASE REPORT

A 19 year old female presented with single asymptomatic, slowly progressive, hypopigmented, slightly depressed patch over left arm for last one year. There was no previous history of any trauma or tick bite. Her medical history was unremarkable. On clinical examination, single well defined, round, hypopigmented patch measuring 1 cm x 1 cm was present over lateral aspect of left arm (Fig. 1). The patch was slightly depressed than the level of surrounding skin with "cliff drop" margin. There was no tenderness or induration.

Laboratory investigations including complete blood count, random blood sugar, liver function test, renal function test and urine routine examination were all within normal limits, but her erythrocyte sedimentation rate was raised (45 mm/1st hour). Anti nuclear antibody and anti-ds DNA level were within normal limit. Histopathological examination from skin biopsy specimen showed orthokeratotic epidermis and degenerated loosely separated collagen bundles in the mid and reticular dermis (Fig. 2). Based on the clinical and histopathological findings, a diagnosis of atrophoderma of Pasini and Pierini was made. The patient was treated with oral hydroxychloroquine 200 mg twice daily. After 2 months of treatment, there was notable improvement in the depressed depth of the lesion (Fig. 3).

Prior to the study, patient gave written consent to the examination and biopsy after having been informed about the procedure.

How to cite this article: Bachaspatimayum R, Bhattacharjee N, Das P. Atrophoderma of Pasini and Pierini: An unusual presentation. Our Dermatol Online. 2019;10(4):355-357.

Submission: 31.01.2019; **Acceptance:** 30.03.2019

DOI:10.7241/ourd.20194.9

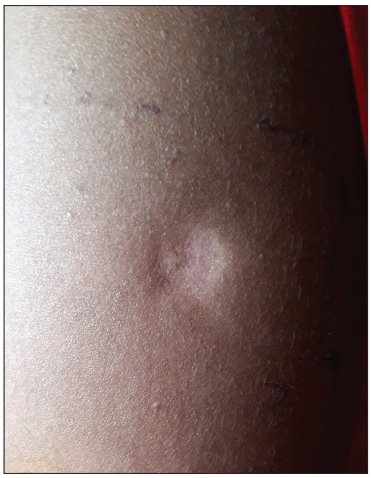

Figure 1: Single, well demarcated, hypopigmented, depressed patch over left arm.

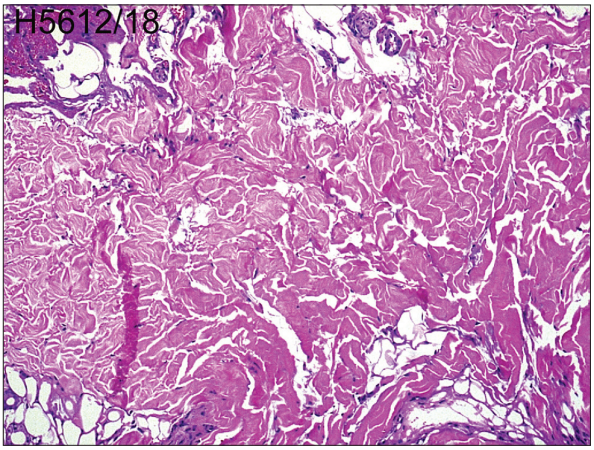

Figure 2: Degenerated loosely separated collagen bundles in the mid and reticular dermis (H & E, 40X).

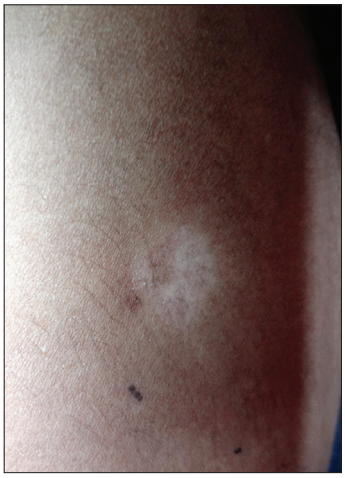

Figure 3: Significant improvement in term of depressed depth of the lesion after 2 months of treatment with oral hydroxychloroquine.

DISCUSSION

Atrophoderma of Pasini and Pierini is an uncommon form of dermal atrophy which usually follows a benign course. There is a female preponderance seen in various literatures [3,4]. Onset is insidious in adolescents and young adults, but few congenital cases are also reported [5,6].In our case, the patient was female with age of onset at 18 years. The etiopathogenesis of atrophoderma of Pasini and Pierini is puzzling. In most of the cases, it is considered as an idiopathic atrophy of dermis. The role of *Borrelia burgdorferi* infection in the pathogenesis had been suggested by some authors [7]. In our case, there was no history of mountain climbing or tick bite.

The lesions are usually asymptomatic, slowly progressive, either single or multiple, sharply demarcated patches of variable sizes and oriented along the cleavage lines. Frequently, these lesions are symmetrically and bilaterally distributed on the trunk and less commonly on the extremities. However, unilateral and zosteriform pattern has also been reported [3]. In our patient, single patch was present on left arm. Most commonly, the lesions are round to ovoid, bluish gray to hyperpigmented, soft, non-indurated and slightly depressed than the level of surrounding skin with an abrupt edge or "cliff-drop" border. These patches are classically described as "footprints in the snow" or "swiss-cheese like". In our patient, the patch was hypopigmented which is consistent with the finding of Saleh et al.[4] in which majority of the lesions were hypopigmented (56%).

The histopathological features of atrophoderma of Pasini and Pierini are often minimal and non-specific. The epidermis is usually normal or slightly atrophic. There may be presence of mild lymphocytic infiltration and normal or hyalinized collagen in dermis [5]. In our case, there was presence of degenerated loosely clumped collagen in mid and reticular dermis.

There is ongoing debate on whether atrophoderma of Pasini and Pierini is a variant of localized scleroderma or a distinct entity. However, in 1958 Canizares et al.[3] classified idiopathic atrophoderma of Pasini and Pierini as a separate entity based on the early onset, longer course, absence of induration and distinct histopathological features like absence of dermal sclerosis, inflammation and no loss of appendegeal structures as compared to morphea.

Till date, no effective treatment is available for atrophoderma of Pasini and Pierini. However, some patients may respond to phototherapy, oral antibiotic and oral hydroxychloroquine [8]. Our patient

responded significantly to oral hydroxychloroquine and there was no new lesion.

CONCLUSION

This case is reported due to the unusual presentation of hypopigmented patches. Although benign in nature, atrophoderma of Pasini and Pierini should be differentiated from morphea to reduce unnecessary treatment burden of the patients.

Consent

The examination of the patient was conducted according to the Declaration of Helsinki principles.

REFERENCES

1. Pasini A. Atrofodermiaidiopathicaprogressiva. G Ital Dermatol. 1923;58:785.
2. Pierini L, Vivoli D. Atrofodermiaidiopathicaprogressiva (Pasini). G Ital Dermatol 1936;77:403-9.
3. Canizares O, Sachs PM, Jaimovich L, Torres VM. Idiopathic atrophoderma of Pasini and Pierini. AMA Arch Derm 1958;77:42-58.
4. Saleh Z, Abbas O, Dahdah MJ, Kibbi AG, Zaynoun S, Ghosn S. Atrophoderma of Pasini and Pierini: a clinical and histopathological study. J CutanPathol. 2008;35:1108-14.
5. Orteu CH. Morphea and allied scarring and sclerosing inflammatory dermatoses. In: Griffiths C, Barker J, Bleiker T, Chalmers R, Creamer D, editors. Rook's Textbook of Dermatology. 9th ed. UK: Wiley- Blackwell; 2016. p. 57.1-57.29.
6. Handler MZ, Alshaiji JM, Shiman MI, Elgart GW, Schachner LA. Congenital idiopathic atrophoderma of Pasini and Pierini. Dermatol Online J. 2012;18:1-4.
7. Lee Y, Oh Y, Ahn SY, Park HY, Choi EH. A case of atrophoderma of Pasini and Pierini associated with Borrelia burgdorferi infection successfully treated with oral doxycycline. Ann Dermatol. 2011; 23:352-6.
8. Carter JD, Valeriano J, Vasey FB. Hydroxychloroquine as a treatment for atrophoderma of Pasini and Pierini. Int J Dermatol. 2006; 45:1255-6.

Source of Support: Nil, **Conflict of Interest:** None declared.

Case Report

Panniculitis in systemic diseases: A two cases report

Nouha Ghriss[1], Sameh Sayhi[1], Sameh Mezri[2], Nour Gueddiche[1], Nadia Ben Abdelhafidh[1], Faida Ajili[1], Bassem Louzir[1]

[1]*Internal Medicine Department, Research Unit Systemic diseases (RU17DN02). Military Hospital of Tunis, Tunis, Tunisia,*
[2]*ENT Department. Military Hospital of Tunis, Tunis, Tunisia*

Corresponding author: Dr. Sameh Sayhi, E-mail: sameh_sayhi@yahoo.fr

ABSTRACT

Panniculitis is an inflammatory disease of subcutaneous adipose tissue which is rarely associated with systemic diseases. In most cases, the evolution of panniculitis associated with these affections is favorable with corticosteroids and/or immunosuppressants. We report 2 cases of patients who were followed for systemic diseases associated with panniculitis. The first case concerned a patient followed for Behçet's disease and the second case was related to dermatomyositis diagnosed concomitantly with panniculitis. Many etiologies of panniculitis have been reported. It is an uncommon cutaneous manifestation of connective tissue diseases and vasculitis. The occurrence of panniculitis may precede or be concomitant with systemic diseases.

Key words: Panniculitis; Dermatomyositis; Behçet disease

INTRODUCTION

Panniculitis is a group of heterogeneous disease caused by inflammation of subcutaneous adipose tissue. Many etiologies including trauma, physical, infectious and sometimes systemic disease may be responsible for this condition.

In this work, we will report 2 cases of panniculitis occur during systemic diseases.

CASE REPORT

Case 1

We report the case of 53 year old patient with history of central diabetes insipidus, followed since April 2015 for abdominal pain, general signs (weight loss and fever) and mesenteric panniculitis. Infectious and neoplasic etiologies were eliminated. The patient was treated by corticosteroids (60m/day). He was readmitted in the internal medicine department after one month for motor deficit of lower limbs with installation of psychic manifestations when he was under 45 mg/day of corticosteroids.

Clinical examination objectified bilateral kinetic cerebellar syndrome, pyramidal syndrome and spinal cord syndrome. A series of exploration was conducted.

He had an inflammatory syndrome (CRP: 60mg/L and VS:100mmH1) and leukocytosis at 13400 cells/mm^3. The immunological tests were normal: antinuclear antibody, Anti-neutrophil cytoplasmic antibodies were negative, complement levels (C3 and C4) were normal. Electromyogram and Wallpaper eye were also normal.

A lumbar puncture was performed showing normal cytology and chemistry, negative culture and negative research of neoplastic cells and antibody antineuronals.

Body tomodensitometry showed abdominal and retroperitoneal panniculitis infiltration without adenomegaly. Pathological examination of the biopsy tissue panniculitis showed fibro adipose and

How to cite this article: Ghriss N, Sayhi S, Mezri S, Gueddiche N, Abdelhafidh NB, Ajili F, Louzir B. Panniculitis in systemic diseases: A two cases report. Our Dermatol Online. 2019;10(4):358-360.
Submission: 19.05.2019; **Acceptance:** 18.07.2019
DOI: 10.7241/ourd.20194.10

steatonecrosis lesions without signs of malignancy; with negative Immunohistochemistry: CD3 and CD20.

Brain MRI objectified diffuse signal abnormalities: at the posterior fossa white matter, gray matter, brain stem and periventricular. The bone marrow biopsy was normal.

The infectious including tuberculosis was ruled out at the lack of clinical arguments, the tuberculin skin test was negative and the evolution of a few months was against this diagnosis.

Lymphoma was reversed before the negativity of the immunohistochemical study and bone marrow biopsy was not in favor.

Neurobehçet was strongly suspected in the inaugural neurological involvement, achievement of the posterior fossa and the notion of oral an genital aphthosis with pseudofolliculitis in clinical examination.

The patient was treated by intravenous methylprednisolone 1g/day relayed by prednisone 1mg/kg/day associated with 1g of cyclophosphamide with partial improvement in muscle strength, and psychic signs.

When patient was readmitted for 3rd cure of cyclophosphamide, he presented a deep venous thrombosis of the left lower limb complicated by massive pulmonary embolism generating a cardio respiratory arrest not recovered by resuscitation.

Case 2

We report the case of 47 year old women who was hospitalized for myalgia, motor deficit and erythematous subcutaneous nodules appearing in upper and lower limbs (Fig. 1).

Clinical examination objectified proximal muscular weakness. Routine laboratory tests revealed slight increases in the serum levels of CRP and muscle enzymes (CPK at 2120UI/L). Full blood count was normal. Immunology work-up were negative. Skin biopsy with histological examination showed inflammatory adipose tissue infiltrated by polynuclear cells (Fig. 2) evoking panniculitis. Clinical and electromyogram findings concluded to dermatomyositis diagnosis associated to panniculitis. Patient was treated initially with non-steroidal anti-inflammatory drugs and methotrexate

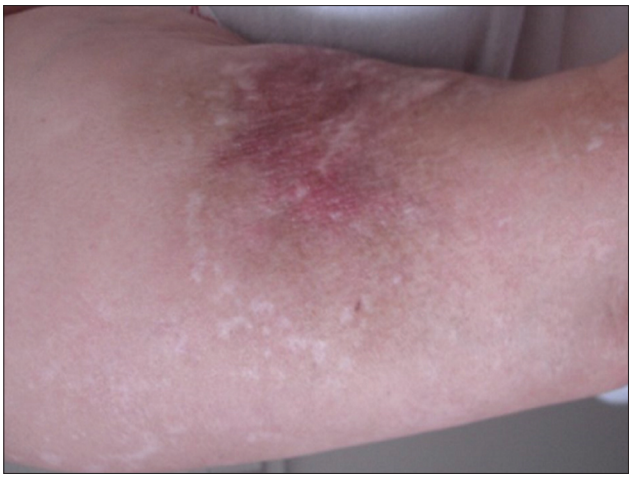

Figure 1: Erythematous dermo-hypodermic nodules of panniculitis in the arm in patient with dermatomyositis.

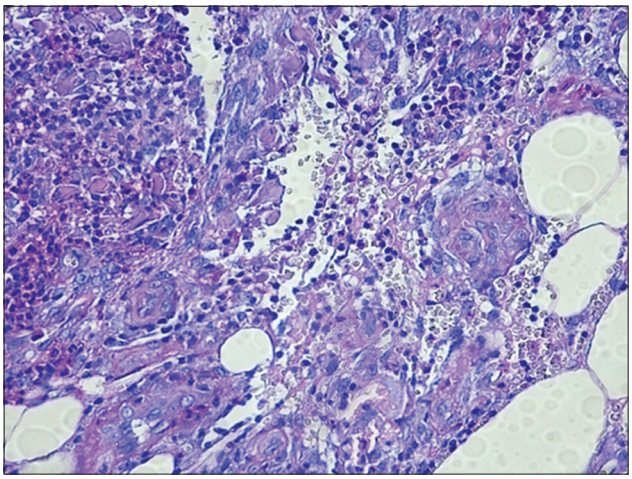

Figure 2: Inflammatory adipose tissue infiltrated by polynuclear cells in patient with dermatomyositis, HE x 400.

25mg/day with partial clinical response. Patient then received immunoglobulin 2g/kg/cure with favorable outcome.

DISCUSSION

The elementary lesion of panniculitis is a painful nodule with dermohypodermic extension. The main components of the hypodermis are lobules, septa and vessels. They will allow classifying panniculitis according to predominant inflammation of any of the three components.

Erythema nodosum is the most frequent septal panniculitis. It does not require biopsy in its typical clinical presentation. It is a painful dermohypodermal nodules, asymmetrically affecting the two legs and taking blue and yellowish contusiform aspects, always healing without sequelae in 10 to 15 days.

Lobular panniculitis most often occurs where the fat panniculus is thick. Unlike erythema nodosum, they can leave a very characteristic depressed scar.

The diagnosis is oriented by the distribution of cutaneous involvement, and also by the consistency, size and sensitivity of the lesions. In most common cases, the specific diagnosis based on histological data [1-3].

Many etiologies including trauma, physical, infectious and sometimes systemic disease may be responsible for this condition [4].

Dermatomyositis is an inflammatory autoimmune muscle disease. Panniculitis is rarely observed during dermatomyositis. The first case of dermatomyositis-panniculitis was described in 1924 by Weber and Gray in a 22-year-old woman and since then only about 20 sporadic cases have been reported since then including cases associated with juvenile dermatomyositis. Its pathogenesis remains obscure. Panniculitis can appear at the same time or before the other manifestations of dermatomyositis. its occurrence can be delayed up to 5 years after the diagnosis of dermatomyositis [5-7]. I our case, dermatomyositis was diagnosed concomitantly with panniculitis.

Behçet syndrome is a multisystemic vasculitis involving the skin, mucosa, eyes, joints, nervous, cardiovascular, and gastrointestinal system. Nodular lesions are rather common in Behçet syndrome [8]. Panniculitis is exceptional during Behçet's disease. the literature has reported only a few sporadic cases [9,10].

CONCLUSION

Panniculitis is a group of heterogeneous inflammatory diseases that involve the subcutaneous fat. A biopsy is needed to establish an accurate diagnosis. The subcutaneous fat may be involved secondarily in trauma, deep cutaneous fungal infections, and many malignancies. It also important to remember that panniculitis can occur in vasculitis and connective tissue diseases.

Consent

The examination of the patient was conducted according to the Declaration of Helsinki principles.

REFERENCES

1. Requena L, Yus ES. Panniculitis. Part I. Mostly septal panniculitis. J Am Acad Dermatol. 2001;45:163-86.
2. Joshi V. Panniculitis. Indian J Rheumatol. 2007;2:147-55.
3. Requena L, Yus ES. Panniculitis. Part II. Mostlylobularpanniculitis. J Am Acad Dermatol. 2001;45:325-64.
4. Wick MR. Panniculitis: A summary. Sem Diag Pathol. 2017;34:261-72.
5. Girouard SD, Velez NF, Penson RT, Massarotti EM, Vleugels RA. Panniculitis Associated with dermatomyositis and recurrent ovarian cancer. Arch Dermatol. 2012;148:740-4.
6. Abdelhafidh NB, Toujeni S, Kefi A, Bousetta N, Sayhi S, Gharsallah I, et al. Dermatomyosite et panniculite: place des immunoglobulines. Pan Afr Med J. 201629;23:262.
7. Calle A, Linos K, Sangueza O, Cerroni L, Carlson JA, Requena L, et al. Dermatomyositispanniculitis: A case series and review of the literature. J Am Acad Dermatol. 2018;79(3, Supplement 1):AB104.
8. Akdeniz N, Elmas ÖF, Karadağ AS. Behçetsyndrome: A greatimitator. Clinics in Dermatology [Internet]. 11 janv 2019 [cité 17 mai 2019]; Disponible sur: http://www.sciencedirect.com/science/article/pii/S0738081X1930001X
9. Demirkesen C, Tüzüner N, Mat C, Senocak M, Büyükbabani N, Tüzün Y, et al. Clinicopathologicevaluation of nodularcutaneouslesions of Behçet syndrome. Am J Clin Pathol. 2001;116:341-6.
10. Ohtake N, Kanekura T, Kawamura K, Kanzaki T. Unusualpolyp-like structures in lobularpanniculitis of a patient withBehçet'sdisease. Am J Dermatopathol. 1997;19:185-8.

Source of Support: Nil, **Conflict of Interest:** None declared.

Case Report

Recurrent unilateral linear capillaritis: A very rare variant of pigmented purpuric dermatosis

Fadime Kılınç[1], Akın Aktaş[2], Sibel Orhun Yavuz[3], Ayşe Akbaş[1], Sertaç Şener[1]

[1]Department of Dermatology, Ministry of Health, Ankara City Hospital, Ankara, Turkey, [2]Department of Dermatology, Yildirim Beyazit University Medical Faculty, Ankara, Turkey, [3]Department of Patology, Ministry of Health, Ankara City Hospital, Ankara, Turkey

Corresponding author: Dr. Fadime Kılınç, E-mail: fykilinc@yahoo.com

ABSTRACT

Pigmented purpuric dermatosis is a disease characterized with localized purpuric lesions. Six different clinical types have been described. There are also unclassified variants including rare granulomatous and unilateral linear capillaritis. Unilateral linear capillaritis is characterized by a very rare, unilateral linear or segmental purpuric macula. A 18-year-old female patient was presented with a linear purpuric and petechial patch and macules on the left arm. Unilateral linear capillaritis is characterized with benign, recurrent purpuric lesions in children and young adolescants that may be presented with spontaneous regression.

Key words: Linear; Pigmented; Unilateral

INTRODUCTION

Pigmented purpuric dermatosis (PPD) is usually characterized with localized purpuric lesions in the lower extremities, and it consists a group of dermatosis with similar histopathological findings caused by an unknown etiology [1-3]. Six different clinical types have been described: Progressive pigmented purpuric dermatosis (Schamberg's purpura), Purpura annularis telangiectoides (Majocchi purpura), lichen aureus, pigmented purpuric lichenoid dermatosis of Gougerot and Blum, itching purpura and eczematia-like purpura of Doucas and Kapetanakis. There are also unclassified variants including rare granulomatous and unilateral linear capillaritis [2]. Unilateral linear capillaritis (ULC), also known as segmental pigmented purpura or Quadrantik capillaropathy, is characterized by a very rare, unilateral linear or segmental purpuric macula. It is a benign condition presented with spontaneous regression [2,4-6]. As far as we know, 16 cases were reported so far [2]. Since its incidence is rare, our 18-year-old female patient is presented here.

CASE REPORT

A 18-year-old female patient was admitted to our outpatient clinic with complaints of redness on the left arm in November 2017. She had complaints for 3 years and it repeats every 2 months. The lesions were healing in 5-7 days. There were no pain, itching and burning. No family history. She has mitral valve prolapse and she has taken beta blockers (metoprolol) since 2012.

On dermatological examination, she had a linear pigmented rash on the left arm. The eruption consisted of linear purpuric and petechial patch and macules and did not blanch with pressure from a diascope (Figs. 1 and 2). Hemogram and biochemical tests were normal. The clinical diagnosis was felt to be unilateral linear capillaritis. The patient went on to have a 4mm punch biopsy from the left arm.

Histopathological examination revealed perivascular lymphocytic infiltrate and erythrocyte extravasation in the upper dermis (Fig. 3). Based on clinical and histological findings, the patient was diagnosed

How to cite this article: Kılınç F, Aktaş A, Yavuz SO, Akbaş A, Şener S. Recurrent unilateral linear capillaritis: A very rare variant of pigmented purpuric dermatosis. Our Dermatol Online. 2019;10(4):361-363.

Submission: 31.05.2019; **Acceptance:** 25.07.2019

DOI: 10.7241/ourd.20194.11

Figure 1: Linear pigmented purpuric rash on the left arm.

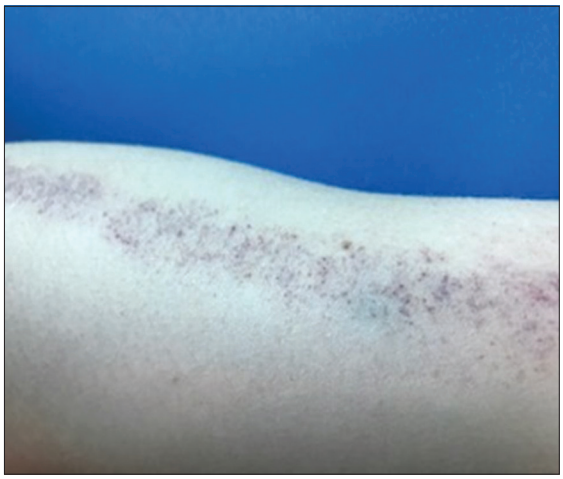

Figure 2: A closer view of the lesion.

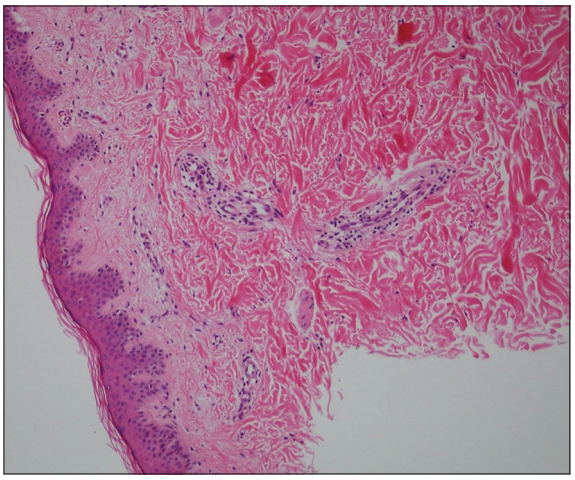

Figure 3: Under the epidermis, perivascular lymphocytes and extravascular erythrocytes.

as unilateral linear capillaritis. Treatment was not recommended because the symptoms spontaneously recovered in about 5 days. The patient was followed up.

DISCUSSION

Higgins et al. have identified a female patient with so-called quandrantic capillaropathy [5] in 1990, for the first time. Riordan reported 4 patients with so-called unilateral linear capillaritis in 1992 [7]. PPD is presented usually in middle and older ages, involving lower extremities symmetrical. ULC patients are younger and the lesions disappear spontaneously in about 3 years. The cause of the unilateral and linear involvement is unknown [8].

The suspected etiology include venous hypertension, exercise, capillary fragility, focal infections, alcohol drugs are implicated [9]. Aspirin, carbomal, thiamin, meprobamate, carbamazepine, reserpine, acetaminophen, glipizide, hydralazine are the suspected drugs [8]. The drugs are reported to be the trigger, especially for schamberg disease [1]. Only one of the reported ULC case had been associated with Aspirin [8]. Our patient uses beta-blockers but since she had spontaneous resolution, her condition was not found to be associated with the drugs histopathologically.

So far, 9 (56.25%) of the patients were male and 7 (43.75%) were female. Its incidence is more common in men, but the difference is not significant. The age of the patients range 5 - 48 years. Half of the patients are children. There are two peak ages: 5-15 years (mean 10.12 years) and 23-56 years (mean 35 years). It is usually asymptomatic, Mar reported mild pruritus in two patients [4]. Lower extremity involvement was observed in 11 (68.7%), upper extremity involvement was observed in 4 (25%) and body involvement was observed in 3 (18.7%) patients (1 patient had only body involvement and 2 patients had body involvement with lower extremity involvement). The lesions are usually in segmental configuration, with less linear involvement [2,10]. Since spontaneous regression is observed in a few months or years, generally treatment is not required. Topical steroids, hydroxychloroquine or PUVA may be given if required [8].

The differential diagnoses should include angioma serpiginosum, unilateral naevoid telangiectasia, and lichen aureus firstly [4,11]. Lichen aureus is differentiated by having no band-style lichenoid infiltration on dermis [11].

In conclusion, ULC is a pigmented purpuric dermatosis characterized with benign, recurrent purpuric lesions in children and young adolescants that may be presented

with spontaneous regression mostly involving lower extremities with segmental or linear lesions.

Consent

The examination of the patient was conducted according to the Declaration of Helsinki principles.

REFERENCES

1. Kim DH, Seo SH, Ahn HH, Kye YC, Choi JE. Characteristics and Clinical Manifestations of Pigmented Purpuric Dermatosis. Ann Dermatol. 2015;27:404-10.
2. Elshimy N, Walker B. Unilateral linear capillaritis: A case and summary of the literature 25 years on from its original description. Clin Case Rep Rev. 2017;3:1-3.
3. Aghaei S, Hooshmand F. Unilateral pigmented purpuric dermatosis in an adult patient. Am J Case Rep. 2011;12:181-3.
4. Mar A, Fergin P, Hogan P. Unilateral pigmented purpuric eruption. *Australas J Dermatol* 1999;40:211-4.
5. Higgins EM, Cox NH. A case of quadrantic capillaropathy. *Dermatologica*. 1990;180:93-5.
6. Pock L, Capkova S. Segmental Pigmented Purpura. *Paediatr Dermatol* 2002;19:517-9.
7. Riordan CA, Darley C, Markey AC, Murphy G, Wilkinson JD. Unilateral linear capillaritis. Clin Exp Dermatol. 1992;17:182-5.
8. Taketuchi Y, Chinen T, Ichikawa Y, Ito M. Two cases of unilateral pigmented purpuric dermatosis. *J Dermatol* 2001;28: 493-498.
9. Ozkaya DB, Emiroglu N, Su O, Cengiz FP, Bahali AG, Yildiz P, et al. Dermatoscopic findings of pigmented purpuric dermatosis. An Bras Dermatol. 2016;91:584-7.
10. Abdullah L, Abbas O. Dermacase. Can you identify this condition? Unilateral linear capillaritis. Can Fam Physcian. 2011;57:563.
11. Yüksek J, Sezer E. Pigmente Purpurik Dermatozlar. Türkiye Klinikleri J Dermatol 2008;18:223-7.

Source of Support: Nil, **Conflict of Interest:** None declared.

Our Dermatology Online

Case Report

Botryomycosis or metastatic tuberculous abscess - A clinical dilemma to a dermatologist?

Parul Chojer, B.B. Mahajan, Jyoti Budhwar, Lovleen Kaur

Department of Dermatology, Venereology and Leprology, Government Medical College, Amritsar, India

Corresponding author: Dr. Parul Chojer, E-mail: parul199019@gmail.com

ABSTRACT

Cutaneous botryomycosis is a chronic focal infection characterised by a granulomatous inflammatory response to bacterial pathogens such as Staphylococcus aureus and occasionally Pseudomonas, Escherichia coli, Proteus, Streptococcus, etc. Early diagnosis and treatment with specific antibiotics alongwith surgical debridement is recommended. Cutaneous metastatic tuberculous abscess and scrofuloderma also presents as subcutaneous swellings and multiple discharging sinuses. A twenty two year old female patient presented with multiple erythematous subcutaneous lesions over lower back, buttocks and bilateral inguinal region, most of which were discharging purulent material since two years. This case is being reported because of the clinical dilemma it poses to the dermatologists.

Key words: Botryomycosis; Tuberculosis; Amoxy-clavulanic acid; Linezolid

INTRODUCTION

Cutaneous tuberculosis comprises only a small proportion of all cases of tuberculosis. Mycobacterium tuberculosis can cause skin infection by direct inoculation into the skin, by hematogenous spread from internal lesion and by direct contact with tuberculosis in an underlying deeper structure [1]. Pyodermas due to staphylococcus usually present as acute inflammatory skin changes such as impetigo and furunculosis. However, immunodeficiency may change the presentation due to staphylococcus skin infection towards chronic granulomatous condition. Botryomycosis (or bacterial pseudomycosis or pyoderma vegetans) is a rare chronic bacterial granulomatous disease that usually involves skin and rarely viscera [2]. Most common cause is *Staphylococcus aureus* and occasionally *Pseudomonas spp.*, *Escherichia coli*, *Proteus spp.*, and *Streptococcus spp* [3]. Metastatic tuberculous abscess and scrofuloderma has a similar presentation in the form of subcutaneous swellings as in Botryomycosis and posing a clinical dilemma to a dermatologist and hence, being reported.

CASE REPORT

A twenty two year old female patient presented with history of multiple erythematous skin lesions over lower back, buttocks and bilateral inguinal region, most of which were discharging purulent material since two years. She had history of fall over ground 2 years back for which she was treated at a local hospital and got temporary relief only as multiple nodules with discharging sinuses kept on appearing. Local cutaneous examination revealed multiple erythematousnodules over lower back, right buttock and bilateral inguinal region.Some of the lesions were discharging purulent material. On palpation, lesions were indurated, tender and not fixed to underlying structures with purulent discharge on manipulation. Some old healed lesions in the form of multiple hyperpigmented patches of size 1x3 cms to 5x2 cms with well- ill defined irregular margins were present over lower part of back (Fig. 1). Some of the lesions in the form of keloidal scar tracts were present over inguinal region (Fig. 2). Hair, nail and mucosae were normal. All vital signs were normal. Systemic examination did not reveal anything significant to the case. Routine investigations were within normal limits, except ESR,

How to cite this article: Chojer P, Mahajan BB, Budhwar J, Kaur L. Botryomycosis or metastatic tuberculous abscess - A clinical dilemma to a dermatologist? Our Dermatol Online. 2019;10(4):364-366.

Submission: 31.01.2019; **Acceptance:** 26.04.2019

DOI:10.7241/ourd.20194.12

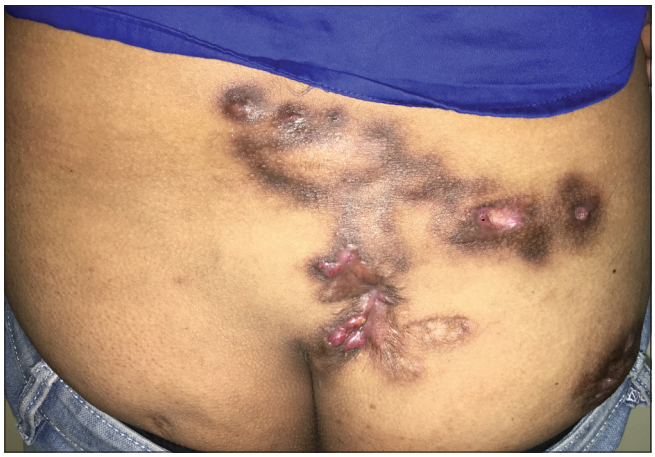

Figure 1: Multiple erythematous nodules over lower back, right buttock at the time of presentation.

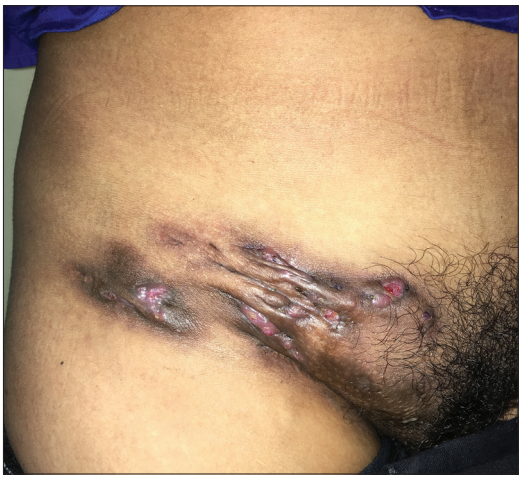

Figure 2: Multiple keloidal scar tracts over inguinal region at the site of presentation.

which was 70 (raised). On pus culture and sensitivity, the isolate grew as a golden yellow pigmented, opaque colony that was diagnosed as Staphylococcus aureus by Gram Staining. ZiehlNelssen staining, CBNAAT, KOH preparation and fungal culture were negative. Histopathology report was equivocal and on the basis of pus and culture sensitivity, patient was started on tablet amoxicillin- clavulanic acid 625 mg three times a day and linezolid 600 mg twice daily with only marginal improvement for a period of 4 weeks. Biopsy was repeated and it revealedorthohyperkeratosis, marked acanthosis with irregular elongation of rete ridges. In the dermis, inflammatory infiltrate composed of lymphocytes, plasma cells and histiocytes is seen. Non caseating granulomas was also seen, suggestive of cutaneous tuberculosis and patient was started on antitubercular therapy (Fig. 3). All the lesions improved and have started healing after 2 months of intensive antitubercular therapy (Fig. 4). Patient is still on regular

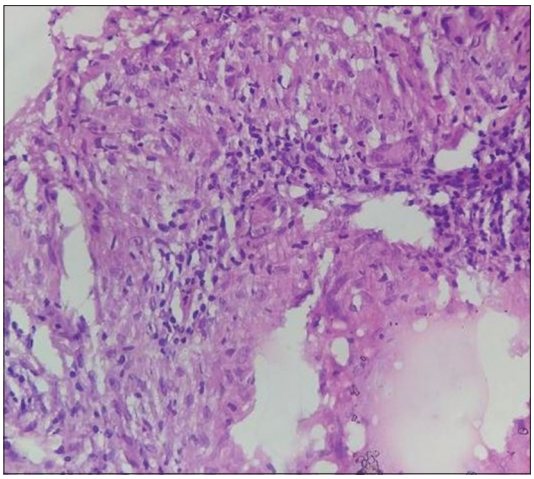

Figure 3: Photomicrograph showing orthohyperkeratosis, marked acanthosis with irregular elongation of rete ridges. In the dermis, inflammatory infiltrate composed of lymphocytes, plasma cells and histiocytes is seen. Non caseating granulomas seen. (H&E 400X).

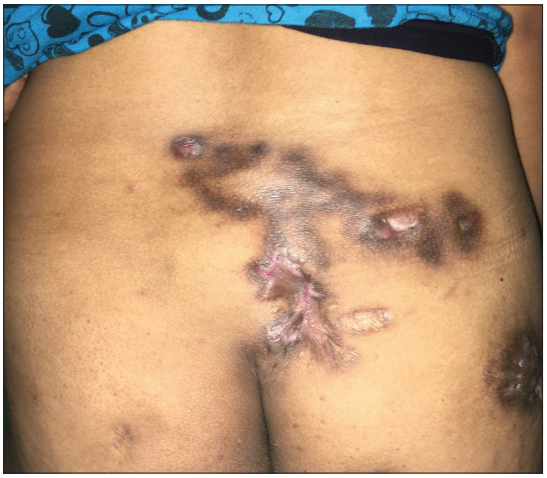

Figure 4: Improvement after 2 months of treatment.

follow up with remarkable improvement and healed up lesions showing keloidal scarring.

Prior to the study, patient gave written consent to the examination and biopsy after having been informed about the procedure.

DISCUSSION

Cutaneous tuberculosis (CTB) continues to be one of the most difficult diagnoses to make because of the wide variations in its clinical appearance, histopathology, immunology and treatment response [4,5]. The incidence of this disease has increased in the 21st century, due to a high incidence of HIV infection and multidrug-resistant pulmonary tuberculosis [6]. Metastatic tuberculous abscess or tubercular gumma results from disseminated

hematogenous spread of mycobacteria and presents as single or multiple dermal subcutaneous nodules which may become fluctuant or break down to form ulcers. Underlying tissue is not involved which is usually involved in scrofuloderma. Although the usual site of involvement is extremities. In our case, trunk was primarily involved [1]. Tuberculin test is usually positive but in our case it was negative and no other tests, namely, ZiehlNelssen, CBNAAT staining was positive. Systemic examination and radiological examination did not reveal any systemic involvement in our case. The differential diagnosis of metastatic tuberculous abscess include botryomycosis, actinomycosis and eumycetoma. Botryomycosis present in two forms: cutaneous and visceral. Chronic form presents as chronic, suppurative and granulomatous skin lesions similar to our patient. It may be preceded by trauma [3]. Most cases present with nodules, abscesses and sinuses with purulent discharge [7,8]. Visceral form is usually with pulmonary involvement [9], which is associated with cystic fibrosis and reaches skin forming sinuses and irregular masses. Rarely, polymicrobial etiology is considered. Most common cause is Staphylococcus aureus and occasionally *Pseudomonas spp., Proteus spp., and Streptococcus spp., E.Coli, Actinobacillusligniereissi*, etc. It is also associated with immunosuppression [10]. Thus, metastatic tuberculous abscess may be misdiagnosed as cutaneous botryomycosis posing a clinical dilemma to a dermatologist.

CONCLUSION

Metastatic tuberculous abscess and scrofuloderma has a similar presentation in the form of subcutaneous swellings as in Botryomycosis and posing a clinical dilemma to a dermatologist.

Consent

The examination of the patient was conducted according to the Declaration of Helsinki principles.

REFERENCES

1. Mycobacterial Infections. In: Victoria M. Yates, Stephen l. Walker. Rook's textbook of Dermatology, 8th edition; 2010; p.27.1-27.47.
2. Bacterial infections. In: James WD, Berger TG, Elston DM, editors. Andrews' diseases of the skin: Clinical dermatology, 11th ed. Elsevier; 2011. p. 250.
3. John K, Gunasekaran K, Kodiatte TA, Iyyadurai R. Cutaneous botryomycosis of the foot: A case report and review of literature. Indian J Med Microbiol. 2018;36:447-9
4. Bravo FG, Gotuzzo E. Cutaneous tuberculosis. Clin Dermatol. 2007;25:173–80.
5. Ghosh S, Aggarwal K, Jain VK, Chauduri S, Ghosh E, Arshdeep. Tuberculosis verrucosa cutis presenting as diffuse plantar keratoderma: an unusual sight. Indian J Dermatol. 2014;59:80–1.
6. Barbagallo J, Tager P, Ingleton R, Hirsch RJ, Weinberg JM. Cutaneous tuberculosis. Diagnosis and Treatment. Am J Clin Dermatol. 2002;3:319–28.
7. B Devi, B Behera, ML Dash, MR Puhan, SS Pattnaik, S Patro. Botryomycosis. Indian J Dermatol. 2013;58:406.
8. Chintaginjala A, Harshavardhan K, Senthil Kumar AL.Cutaneous Botryomycosis: A Rare Case Report. Indian J Dermatol. 2016;61:126.
9. Motswaledi H, Makama JZ, Khan N. Botryomycosis: A case report. SA J Radiol. 2006;10:14–5.
10. Rit K, Saha R, Chakrabarty P. A Case Report of *Staphylococcus aureus* Induced Cutaneous Botryomycosis in a Patient with Acquired Immune Deficiency Syndrome. MAMC J Med Sci. 2015;1:108-10.

Source of Support: Nil, **Conflict of Interest:** None declared.

Case Report

Scratching suspected porokeratosis lesion, simple and quick maneuver that facilitates its diagnosis

Paulo Ricardo Martins Souza, Thaís Marques Furtat, Nicole Reinisch, Paulo Henrique Pacheco Dario

[1]Dermatology Service of Santa Casa de Misericórdia de Porto Alegre Hospital - Porto Alegre (RS), Brazil, [2]Post-Graduation Program in Health and Behavior, Catholic University of Pelotas (UCPEL) - Pelotas (RS), Brazil, [3]Medicine Graduation – Federal University of Pelotas (UFPEL) – Pelotas (RS), Brazil

Corresponding author: Dr. Nicole Reinisch, E-mail: nicolereinisch23@gmail.com

ABSTRACT

Porokeratosis are morphologically distinct keratinization disorders, characterized clinically by papules or hyperkeratotic plaques surrounded by a linear raised border. Sometimes the border (the most characteristic change in porokeratosis, and practically the definition of diagnosis) is not easily identifiable. We demonstrated a clinical maneuver that facilitated the visualization of this more typical aspect in frame. A wooden tongue depressor was used to gently scratch one of the lesions. This maneuver revealed a desquamative halo in the hyperkeratotic lesion - better identifying the clinical aspect typical of the porokeratosis. The use of scratching may play a fundamental role in the diagnostic suspicion of porokeratosis and should be applied whenever the clinical history suggests this hypothesis as a differential diagnosis.

Key words: Porokeratosis; Keratotic lesions; Cornoid lamella

INTRODUCTION

Porokeratosis are morphologically distinct keratinization disorders, characterized clinically by papules or hyperkeratotic plaques surrounded by a linear raised border. Histologically, a thin column of paracerathotic cells extends throughout the corneal extract and is seen in all variants. This histopathological finding, known as the cornoid lamella, corresponds to clinically demonstrable hyperkeratosis [1-10]. Sometimes the border (the most characteristic change in porokeratosis, and practically the definition of diagnosis) is not easily identifiable. We demonstrated a clinical maneuver that facilitated the visualization of this more typical aspect in frame.

CASE REPORT

A 48-year-old female patient with multiple keratotic lesions for more than 20 years in the upper limbs with a characteristic appearance of actinic keratosis. Due to the early onset of the disease, actinic porokeratosis or disseminated superficial porokeratosis was suspected. In the search for lesions that identified porokeratosis, a wooden tongue depressor was used to gently scratch one of the lesions (Fig. 1). This maneuver revealed a desquamative halo in the hyperkeratotic lesion (Fig. 2) - better identifying the clinical aspect typical of the porokeratosis.

DISCUSSION

Porokeratosis include a heterogeneous genetic group of disorders that represent different phenotypic expressions of the same gene defect, which is inherited mainly in an autosomal dominant way [2,3]. The disease usually manifests itself in the third or fourth decades of life with a feminine preponderance. The tendency to develop these lesions is provided by two genes already mapped: DSAP1 on chromosome 12q23.2-24.1 and DSAP2 on chromosome 15q25.1-26.1 [4].

How to cite this article: Souza PRM, Furtat TM, Reinisch N, Dario PHP. Scratching suspected porokeratosis lesion, simple and quick maneuver that facilitates its diagnosis. Our Dermatol Online. 2019;10(4):367-368.

Submission: 02.05.2019; **Acceptance:** 04.07.2019

DOI: 10.7241/ourd.20194.13

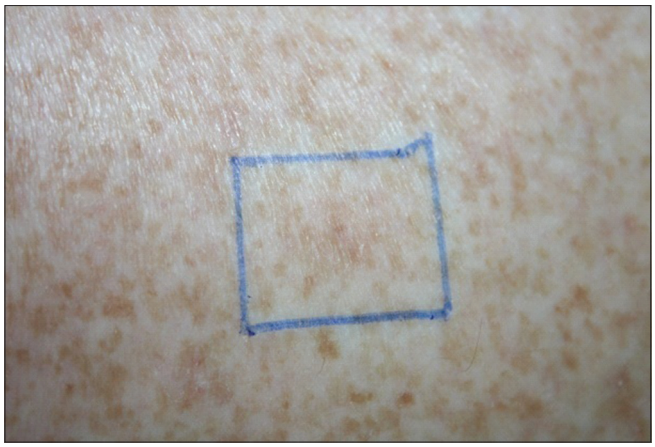

Figure 1: The suspected lesion, without the typical desquamative halo of the porokeratosis.

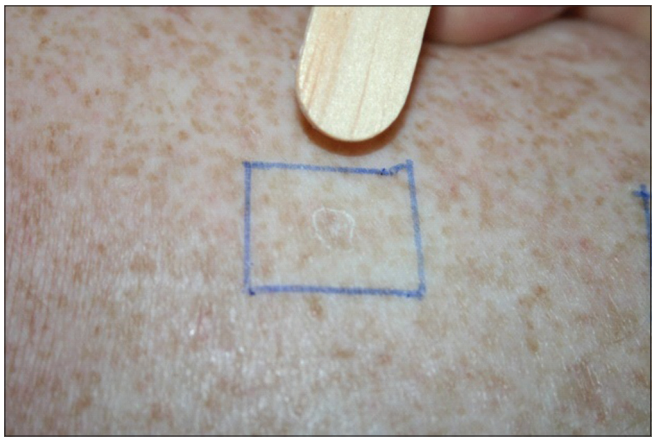

Figure 2: Typical desquamative halo after scratch the lesion with a wooden tongue depressor.

Although reports of transformation in non-melanoma skin cancer [1,3,5], the reported frequencies of malignant transformation (between 6.8% and 11.0%) are likely to be overestimated [6].

Dermatoscopy is a non-invasive and rapid auxiliary method, increasingly common in clinical practice, capable of improving accuracy in the diagnosis of pigmented lesions [7].

At the dermatoscopic examination, the cornoid lamella appears as a thin white border lined with brown pigmentation. The atrophic center of an injury often demonstrates a white area with red dots, globules and lines representing capillaries [8]. Unfortunately, the most characteristic change in porokeratosis, the border framing the lesion, is not always present at physical and dermatoscopic examination [9].

The onset of lesions before the age of 30 led to the suspicion that it was not keratoseactin, our initial clinical impression. With the hypothesis of porokeratosis, the scraping of a suspected area identified a clearer halo and favored the diagnosis, confirmed later histologically. We suggest this simple maneuver that facilitates diagnosis in some cases where the porokeratosis frame is not so obvious.

CONCLUSION

Therefore, the use of scratching may play a fundamental role in the diagnostic suspicion of porokeratosis and should be applied whenever the clinical history suggests this hypothesis as a differential diagnosis.

Consent

The examination of the patient was conducted according to the Declaration of Helsinki principles.

REFERENCES

1. O'Regan GM, Irvine AD.Porokeratosis. In: Fitzpatrick TB, Eisen AZ, Wolff K, Freedberg IM, Austen KF, editors. Dermatology in general medicine. 7th ed. New York: McGraw-Hill; 2008. p. 442-6.
2. Kanitakis J. Porokeratoses: an update of clinical, aetiopathogenic and therapeutic features. Eur J Dermatol. 2014;24:533-44.
3. Ferreira FR, Santos LDN, Tagliarini FANM, Alvarenga Lira ML. Poroqueratose de Mibelli - revisão da literatura e relato de um caso. An Bras Dermatol. 2013;88:S179-82.
4. Weidner T, Illing T, Miguel D, Elsner P. Treatment of porokeratosis: a systematic review. Am J Clin Dermatol. 2017;18:435-49.
5. Filho FB, Quaresma MV, Vendramini DL, Kac BK, Leal F, Azulay DR. Poroceratose superficial diseminada. Rev SPDV. 2013;71:501-5.
6. Gutierrez EL, Galarza C, Ramos W, Tello M, De Paz PC, Bobbio L, et al. Facial porokeratosis: A series of six patients. Australas J Dermatol. 2010;51:191-4.
7. Bastos CA. Non-traditional Indications in dermoscopy. Surg Cosmet Dermatol. 2012;4:203-5.
8. Zaballos P, Puig S, Malvehy J. Dermoscopy of disseminated superficial actinic porokeratosis. Arch Dermatol 2004;140:1410.
9. Chernosky ME, Freeman RG. Disseminated superficial actinic porokeratosis (DSAP). Arch Dermatol 1967;96:611-24.
10. Ferreira FR, Santos LDN, Tagliarini FANM, Alvarenga Lira ML. Poroqueratose de Mibelli - revisão da literatura e relato de um caso. An Bras Dermatol. 2013;88:S179-82.

Source of Support: Nil, **Conflict of Interest:** None declared.

Case Report

Solar urticaria related to ultraviolet nail lamps: a case report

Katrien Coninx[1], Olivier Aerts[2], An Bervoets[1,2]

[1]Department of Dermatology, University Hospital Leuven, Belgium, [2]Department of Dermatology, University Hospital Antwerp, Belgium

Corresponding author: Dr. Katrien Coninx, E-mail: katrienconinx@hotmail.com

ABSTRACT

Solar urticaria is a rare chronic skin condition triggered via (an) uncharacterized chromophore(s) and characterized by skin lesions and/or itch immediately after sun exposure. We present a 50-year-old woman who presented to us with a history of an itchy and burning sensation after a few minutes of sun exposure, first noticed after applying gel nails for the first time. We suggest that a photoallergen can be formed during the polymerization and hardening process of gel nails.

Key words: Solar urticaria; Ultraviolet nail lamps; Gel nails; Pathogenesis; Case report

INTRODUCTION

Solar urticaria is an idiopathic rare immunoglobulin E (IgE)-mediated photodermatosis with a largely hypothetical pathogenesis. A reaction between a precursor factor in the skin and an action spectrum is assumed [1]. We report a case of solar urticaria in which ultraviolet (UV) nail lamps are thought to be the trigger for solar urticaria. The intense effect of UVA exposure may provoke initial sensitization to an emerging photoallergen in sun-sensitive people. Further research is needed to investigate the process of emerging photoallergens in solar urticaria.

CASE REPORT

A 50-year-old woman noticed tingling of her hands after applying gel nails for the first time, ten months before the first consultation. This sensation returned after every application accompanied with pruritus and a burning sensation. In spring, she developed an itching and burning sensation on head, arms and legs. After a few minutes of sun exposure, she immediately developed an erythema on sun-exposed areas. These symptoms decreased a little bit after taking antihistamines (*cetirizine*). Later in spring, she noticed a feeling of swelling and discovered redness in the neck. The itchy feeling persisted and she also experienced symptoms on cloudy days, but not behind glass. The symptoms did not improve during summer. The general practitioner prescribed *ebastine* 20 mg, *bilastine* 20 mg and *cetirizine* 20 mg without any improvement. A neurological examination revealed no cause for the tingling sensation. There were no other systemic symptoms reported. She also reported that the rash always started at her fingers. The patient took daily *progesterone* 200 mg, *paroxetine* 10 mg, *levothyroxine* 100 μg, *lorazepam* 1 mg and *alendronic acid* with *cholecalciferol* once weekly. Contact allergy and photo contact allergy were excluded by (photo) patch tests with the Belgian standard series, cosmetic test series, drug test series, photo patch test series and own products and contents. The tests revealed positivity for nickel, cobalt and an unclear reaction to limonene and linalool hydroperoxides. These results couldn't explain the lesions. Eventually, she was referred to our specialized center to perform monochromatic phototesting to exclude any form of light allergy. We excluded cutaneous porphyria's by analyzing the heme synthesis (Table 1). Blood porphyrin analysis revealed free erythrocyte porphyrin levels of 1278 μg/L RBC with a normal PPIX/ZNPP ratio and normal plasma

How to cite this article: Coninx K, Aerts O, Bervoets A. Solar urticaria related to ultraviolet nail lamps: a case report. Our Dermatol Online. 2019;10(4):369-371.
Submission: 09.05.2019; **Acceptance:** 15.08.2019
DOI: 10.7241/ourd.20194.14

porphyrin, excluding the diagnosis of Erythropoietic Protoporphyria. The clinical findings and phototesting (Figs. 1 and 2) suggested the diagnosis of solar urticaria with a reduced minimal erythema dose (MED) of 10 J/cm² at 350±10 nm (UVA spectrum) and a strong erythemal flare reaction immediately after radiation (Table 2 and 3). The term MED as a measure of erythemal radiation is not a standard measure as normal ranges are highly dependent on individual sensitivity, characteristics of the source, determinants of the exposure, nature of the skin and observational factors. The reference limits are specific to a particular investigating center, these tables show the reference limits in our center [2]. We suggested protection with sunscreens, clothing, a hat and sunglasses. We also suggested continuing the treatment with antihistamines, but, if insufficient, UVB therapy thrice weekly with gradually increasing the dose was proposed.

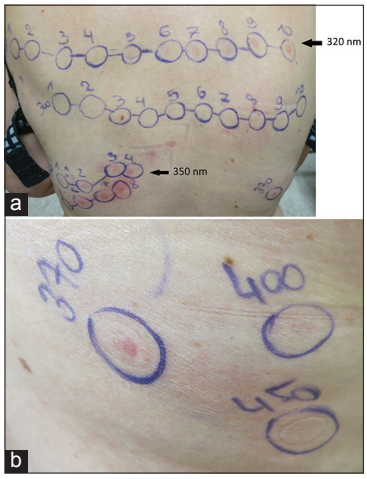

Figure 1: (a) At 350 nm, a strong erythemal flare reaction is visible immediately after irradiation. This clinical sign is very suggestive for the diagnosis of solar urticaria. (b) Details of the irradiation zones of 370, 400 und 450 nm immediately after irradiation. A clearly visible urticarial plaque is seen at 370 nm.

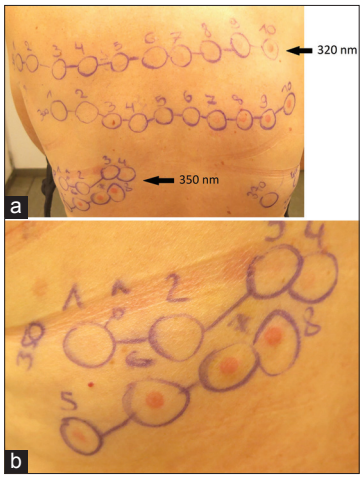

Figure 2: (a) 24 hours after irradiation a reduced MED of 40 mJ/cm² at 300 nm and of 2 J/cm² at 320 nm is visible. At 370 nm an erythemal response is visible. (b) 24 hours after irradiation, the strong reaction has disappeared. Reduced MED of 10 J/cm² is visible in the UVA-range (350 nm).

Table 1: Analysis of the Heme synthesis with free erythrocyte porphyrin, zinc-chelated protoporphyrin (ZnPP), free protoporphyrin (PPIX) and plasma porphyrin

Test	Levels	Reference limits
Free erythrocyte porphyrin	1278 µg/L RBC	200-550 µg/L RBC
Zinc-chelated protoporphyrin (ZnPP)	48%	
Free protoporphyrin (PPIX)	52%	
Plasma porphyrin	negative	

DISCUSSION

In the context of investigation of photosensitivity the patient was already tested for (photo)contact allergy. She did not take any medications known to cause phototoxicity. Familial history revealed no affected members. The clinical history of the time course, absence of hardening and swelling are also suggestive for solar urticaria. To complete the proper investigation of photosensitivity, the patient was tested with a monochromator (*LOT Oriel Group Europe, Germany)* in order to identify the correct minimal erythema dose and action spectrum. She developed a strong urticarial reaction immediately after irradiation in the UVA range, indicating a very low minimal urticarial dose (MUD) in these range. Consequently, we diagnosed the patient with solar urticaria with action spectrum in the UVA range.

A reaction between a precursor factor in the skin and an action spectrum is assumed in literature [1]. The resulting photo allergen induces immunoglobulin E production triggering mast cell degranulation, an erythematous flare reaction and wheals or itch appear as a result of type I allergy [3,4]. During the diagnostic process, we were surprised by the coincidence of the use of gel manicure systems and UV nail lamps and the development of solar urticaria. In the case of gel manicure systems, different acrylate monomers constitute together a nail polish, requiring UV light for polymerization and hardening, mostly in a wavelength range of 340-380 nanometer, in the UVA range [5,6]. The UVA radiation is necessary to let the artificial nail coating polymerize. In relation to the accepted pathogenesis of solar urticaria, it is remarkable that the patient developed solar urticaria in the range of the used UV nail lamp (365nm). During a sensitization

Table 2: Minimal erythema dose (MED) test 24-hour after irradiation

	Wavelength±margin of error (bandwidth)							
	300±2.5nm	320±5nm	350±10nm	370±10nm	400±10nm	450±10nm	500±10nm	600±10nm
	5nm	10nm	20nm	20nm	20nm	20nm	20nm	20nm
Patient	40mJ/cm²	2J/cm²	10J/cm²	+	-	-	-	-
Normal	20-50mJ/cm²	2-5J/cm²	20-50J/cm²	-	-	-	-	-

Table 3: MED-test immediately after irradiation

	Wavelength±margin of error (bandwidth)							
	300±2.5nm	320±5nm	350±10nm	370±10nm	400±10nm	450±10nm	500±10nm	600±10nm
	5nm	10nm	20nm	20nm	20nm	20nm	20nm	20nm
Patient	-	1J/cm²	5J/cm²	+	-	-	-	-
Normal	-	-	-	-	-	-	-	-

process, a precursor substance is converted to a photoallergen after light absorption of a wavelength corresponding to the triggering action spectrum (AS). Subsequently, IgE immunoglobulins are formed against the photoallergen resulting in an immediate-type hypersensitivity reaction by subsequent contact with the wavelength of the AS [7].

CONCLUSION

We reported on a development of solar urticaria after the use of UV nail lamps. and hypothesize that the patient was sensitized during the UV nail irradiation process. People need to be aware of the risks associated with the use of UV nail lamps.

Consent

The examination of the patient was conducted according to the Declaration of Helsinki principles.

REFERENCES

1. Botto NC, Warshaw EM. Solar urticaria. J Am Acad Dermatol. 2008;59:909-20.
2. Honigsmann H, Hawk JL, Lim HW: Photodermatology. 1st ed. Boca Raton (FL): CRC Press; 2007.
3. Goetze S, Elsner P. Lichturtikaria–Urticaria solaris. J Deuts Dermatol Gesell. 2015;13:1250-4.
4. Haylett AK, Koumaki D, Rhodes LE. Solar urticaria in 145 patients: Assessment of action spectra and impact on quality of life in adults and children. Photodermatol Photoimmunol Photomed. 2018;34:262-8.
5. Shihab N, Lim HW. Potential cutaneous carcinogenic risk of exposure to UV nail lamp: A review. Photodermatol Photoimmunol Photomed. 2018;34:362-5.
6. Rieder EA, Tosti A. Cosmetically induced disorders of the nail with update on contemporary nail manicures. J Clin Aesthet Dermatol. 2016;9:39.
7. Kojima M, Horiko T, Nakamura Y, Aoki T. Solar urticaria: the relationship of photoallergen and action spectrum. Arch Dermatol. 1986;122:550-5.

Source of Support: Nil, **Conflict of Interest:** None declared.

Case Report

Scorbut and purpuric hyperkeratotic skin lesions in the elderly: What relationship? A case report

Binan Yves[1], Kassi Komenan[2], Konan N'guessan[1], Acko Ubrich[1], Kaba Ibrahima[1], Bita Darius, Adom Hilaire[1], Toutou Toussaint[1]

[1]Department of Internal Medicine and Geriatrics, University Hospital Center (UHC)-Treichville, Abidjan, Cote d'Ivoire, [2]Department of Dermatology and Venerology, Training And Research Unit of Medical Sciences, University of Felix Houphouet Boigny of Abidjan, Côte d'Ivoire

Corresponding author: Dr. Kassi Komenan, E-mail: siskakomlo@yahoo.fr

ABSTRACT

Gingival bleeding and dental heaving during scurvy are the most reported in the literature. However nonspecific isolated purely cutaneous manifestations due to hypovitaminosis C are not uncommon. Their incidence increases with age related to decrease in microcirculation of the skin leading to trophic disorders observed in the skin extremities in the elderly. Here we report the case of an elderly with poly vascular disorders aged of 73 years old in whom we observed purpuric hyperkeratotic lesions on the extremities. The various paraclinical examinations and blood checks for different diagnostic hypotheses have helped to spread a disease of cholesterol emboli, systemic vasculitis and retain low vitamin C after dosing the ascorbic acid serum incidentally. The disappearance of these skin lesions after two weeks of oral vitamin C supplementation confirmed the diagnosis scorbut. The occurrence of mucocutaneous lesions in elderly with high risk of atherosclerosis and living in unfavorable socio-economic conditions must alert the clinician to look for low vitamin C and titrate the serum ascorbic acid.

Key words: Hypovitaminosis C; Ascorbic acid serum; Purpuric hyperkeratotic lesions; Elderly; Atherosclerosis

INTRODUCTION

Vitamin C is supplied exogenously by diet in human, primate and some animals. Vitamin C level decreases with age, especially in the epidermis [1,2]. This abnormality is responsible of diseases and the best known is scurvy which occurs when the value of ascorbic acid level is less than 6μmol/l. However, there are isolated specific manifestations purely Cutaneous in Hypovitaminosis C that are rarely described in the literature. They are a kind of follicular hyperkeratosis, pigmented icthyosis, healing delays and/or even venous ulcers [3]. In addition, during human aging a reflex in skin vasodilatation decreases [4,5]. This reduces microcirculation of the skin leading to trophic disorders observed in the skin extremities in the elderly. Furthermore, vitamin C supplementation improves skin blood flow [6]. We report a case of vitamin C deficiency in a septuagenarian revealed by purpuric hyperkeratotic lesions treated in fifteen days by vitamin C supplementation taken orally.

CASE REPORT

A 73-year-old-man, Guadeloupean, bachelor and retired is addressed in consultation in internal medicine for the fortuitous discovery of a monoclonal peak with light kappa chain associated with acrorhigosis and paresthesia of the feet. The clinical manifestations have been evolving for a year. Personal medical history revealed: hypertension known and treated since 1998 by quadritherapy (ACEBUTOLOL-200MG AMLOR® 5MG 3-CoAprovel® 300/5MG), a tobacco intoxication weaned in 1967, a dyslipidemia treated since 2002 by Crestor, ischemic stroke that occurred in 2002 without sequelae. On admission time, we noted a blood pressure

How to cite this article: Yves B, Komenan K, N'guessan K, Ubrich A, Ibrahima K, Darius B, Hilaire A, Toussaint A. Scorbut and purpuric hyperkeratotic skin lesions in the elderly: What relationship? A case report. Our Dermatol Online. 2019;10(4):372-375.

Submission: 22.04.2019; **Acceptance:** 27.06.2019

DOI:10.7241/ourd.20194.15

level of 135/80mmHg and a heart rate of 76/min, pedal pulses were abolished on the left, decreased on the right as well as tibioposterior pulses. Both right and left femoral pulses were well perceived. There is no breath on auscultation of arterial axes but the local state of the foot showed a very poor venous condition of the lower limbs and especially distal ischemic lesions in all areas of support points, toes and the sole associated with acrocyanosis and painful stasis and distal ulcerations. The rest of the physical examination was normal.

Biological examinations showed a normal blood count, normal blood and urine electrolytes, and creatinine clearance decreased to 44 ml/minute.

Serological tests such as, HIV, HBs Ag, HCV-Ag, Syphilis, Epstein-Barr virus, HTLV-1 and HTLV2 virus's tests were negatives, but HBs-Ag, HCV-Ag serological tests were positives, which were an evidence of an old virus infection.

Immunological tests, anti-nuclear, native anti DNA, and anti Beta2 GP1 antibodies tests were negatives and presence of anti Cardiolipin antibodies with IgM positive to 54 units.

Additional tests carried out showed the existence of cataract in the right eye fundus and a clear glass with the slit lamp without cholesterol embolus. But, there was a retro- fovea serous retinal detachment of the left eye, without cholesterol embolus.

A skin biopsy of the left first metatarsal root showed a normal thickness of the epidermis, a discrete vascular dilation without vasculitis or thrombosis. The direct Immuno-Fluorescence examination was negative.

Capillaroscopy showed the absence of abnormality, organic microangiopathy.

The other morphological examinations were unremarkable except the echocardiography that revealed a concentric LV cardiomyopathy with an ejection fraction of 65%.

Fortuitously, by dosing vitamin C level we noted hypovitaminosis in ascorbic acid estimated at 8.18 μmol/l (technique used: HPLC electrochemistry, laboratory standard: 45- 95 m/dl). We gave a vitamin C supplementation for a two-week period. Skin lesions that have been developing for about 1 year were healed and cleaned.

DISCUSSION

The degree of vitamin C deficiency should be defined. A rate over 26μmol/l is considered normal; a rate between 6μmol/l and 26μmol/l represents Hypovitaminosis C, which is known as severe if the rate is less than 13μmol/l. A rate under 6μmol/l defines a deficiency. And scurvy is defined when the rate is under 6μmol/l associated with clinical signs. Our patient had ascorbemia to 8.18μmol/l therefore severe Hypovitaminosis C.

The prevalence of Hypovitaminosis C is common in men and increases with age, as observed in our patient. A study of 1108 outpatients in the region of Paris [7] highlighted an ascorbemia less than 2 mg/l in 5% of women and in 12% of men, reaching 15% of women and 20% of men in age group over 65 years. In the united kingdom in 1970, the studies showed that 50% of elderly people living at home had ascorbemia less than 2 mg/l [5].

A number of vitamin C deficiency risk factors have been identified in the study of Fain et al: the elderly, male gender, being retired or unemployed, having an infectious diseases and excessive consumption of alcohol and tobacco [3]. In our case, the patient was aged of 72 years old, single, retired and former smoker. These risk factors represents limiting factors of vitamin C absorption in the body. Moreover, the body stores of vitamin C are low (1500 mg) [8] so that the clinical picture of scurvy appears in one to three months of absolute deficiency of ascorbic acid when the total pool of the organism is under 300 mg and the ascorbic acid level falls below 2 [9] to 2.5 mg/l [3] Fain O and al. The patient had no scurvy but, Hypovitaminosis C with severe acrocyanosis of the extremities of the lower limbs. These skin lesions of typical acrorhigosis of chronic evolution (Fig. 1) on a constitutional susceptibility of preexisting vascular pathologies such as hypertension, ischemic stroke, Dyslipidemia, moderate renal impairment and former smoker in our patient allowed us to discuss the disease of cholesterol embolism; With the presence of a hyper eosinophilia to 572 cells/mm^3. But the absence of micro-crystals of cholesterol in the urine, in the eye fundus and skin biopsy were not in favor to the diagnosis.

The search for ANCA vasculitis, connective and cryoglobulinaemia were negative. Finally we retained, vitamin C deficiency with ascorbemia equal to 8.18μmol/l revealed by a clinical picture of acrorhigosis

with paresthesia of the feet that has been developing. Indeed Several studies showed that the presence of clinical signs of deficiency leading to a determination of ascorbemia, highlights Hypovitaminosis almost systematically [10-12] and up to 100% in the population of Oguike [13] and 93% in Sentenac [14] although it is known that skin symptoms during vitamin C deficiency is extremely polymorphic and non-specific [3]. Purpuric hyperkeratotic lesions of extremities of limbs are rarely described unlike leg ulcers.

Vitamin C is involved in the synthesis of collagen as an essential cofactor for proline and lysine oxidase responsible for the formation of stable collagen helices. Vitamin C deficiency induces an alteration of the collagen structure [15]. There are 3 types of collagen including type 3 that is present in the skin and blood vessels. However, the amount of vitamin C is low in the elderly skin, particularly in the epidermis [1,2] and the majority of the patients were at risk for atherosclerosis as in our patient. But, in patients with atherosclerosis, there is biochemical evidence that indicates the increase of oxidative stress resulting from a change in the balance of pro- and endogenous antioxidants [4]. This oxidative stress is associated with increased consumption of vitamin C.

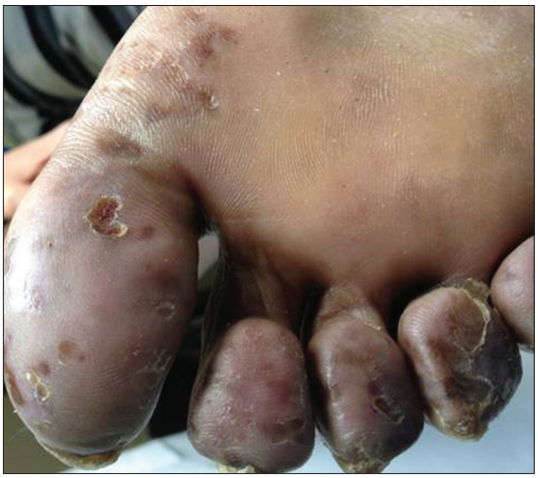

Figure 1: The sole of the foot before treatment.

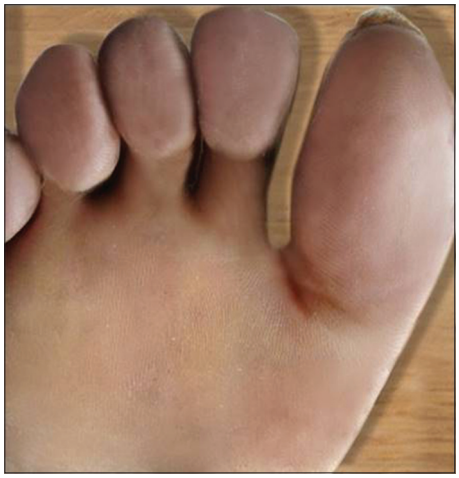

Figure 2: The sole of the foot after treatment.

In short, the vitamin C deficiency in the epidermis of the elderly associated with atherosclerosis and inadequate vitamin C intake are risk factors when combined and could lead to skin lesions like those observed in our patient.

The oxidative attack of lens proteins was also considered as a risk factor for cataract. In the literature there is no consensus on the correlation between vitamin C status and the frequency of cataracts. Some studies evoked a relationship between poor intakes of vitamin C and cataract, but others [16] did not find any correlation. Cataract found in our patient, however, can be related to severe low vitamin C.

The favorable outcome characterized by the disappearance of purpuric hyperkeratotic lesions (Fig. 2) by supplementing 1 g/day of ascorbic acid in our patient orally for two weeks demonstrated retrospectively the validity of the diagnosis.

CONCLUSION

The appearance of mucocutaneous lesions in geriatric subject with high risk of atherosclerosis and living in low socio-economic conditions should directed the clinician to the diagnosis of Hypovitaminosis C and to determine the ascorbic acid level.

The dosage of vitamin C level is expensive and difficult; therefore prevention of Hypovitaminosis C by daily supplementation in the diet of the Geriatric subject by the consumption of fruits and vegetables should be advocated.

Acknowldgements

We would like to knowledge all health practitioner from the teaching hospital of Treichville/Abidjan/Cote d'Ivoire.

Consent

The examination of the patient was conducted according to the Declaration of Helsinki principles.

REFERENCES

1. Leveque N, Muret P, Mary S, Makki S, Kantelip JP, Rougier A, et al. Decrease in skin ascorbic acid concentration with age. Eur J Dermatol. 2002;12:21–2.
2. Leveque N, Robin S, Makki S, Muret P, Rougier A, Humbert P. Iron and ascorbic acid concentrations in human dermis with regard to age and body sites. Gerontology. 2003;49:117–22.
3. Fain O, Pariés J, Jacquart B, Le Moël G. Hypovitaminosis C in hospitalized patients. Eur J Intern Med. 2003;14:419-25.
4. Kenney WL. Control of heat-induced cutaneous vasodilatation in relation to age. Eur J Appl Physiol Occup Physiol. 1988;57 120–5.
5. Kellogg DL Jr, Pergola PE, Piest KL, Kosiba WA, Crandall CG, Grossmann M, et al. Cutaneous active vasodilation in humans is mediated by cholinergic nerve cotransmission. Circ Res. 1995; 77:1222–8.
6. Jennifer J, DuPont, William B, Farquhar, Raymond R. Townsend. Ascorbic acid or l-arginine improves cutaneous microvascular function in chronic kidney disease. J Appl Physiol. 2011;111:1561–7.
7. Hercberg S, Preziosi P, Galan P, Deheeger M. Vitamin status of a healthy french population: dietary intakes and biochemical markers. Int J Vitamin Nutr Res. 1994;64:220-3.
8. Lazareth I, Hubert S, Michon-Pasturel U, Priollet PJ. Vitamin C deficiency and leg ulcers. A case control study. Mal Vasc. 2007; 32:96-9.
9. Johnstan CS, Thompson LL. Vitamin C status of an outpatient population. J Am Coll Nutr. 1998;17:366-70.
10. Blateau S. Scorbut et déficit en vitamine C: étude rétrospective à propos de 164 cas [Thèse d'exercice]. 2005. Université de Reims Champagne-Ardenne.
11. Le Bris T. Quel est l'intérêt de l'ascorbémie dans le diagnostic et le traitement [Thèse d'exercice]. [France]: Université de Caen UFR de médecine; 2012. 61. Raynaud-Simon. Scurvy in hospitalized elderly patients, 20617280.
12. Malmauret L, Leblanc J, Cuvelier I, Verger P. Dietary intakes and vitamin status of a sample of homeless people in Paris. Eur J Clin Nutr. 2002;56:313-20.
13. Oguike M. Scorbut et précarité, prévalence d'une maladie oubliée en médecine générale [Thèse d'exercice]. Université de Montpellier I. 2014. Faculté de Médecine.
14. Sentenac G. Le scorbut au XXIème siècle, une nouvelle maladie ? [Thèse d'exercice]. 2016. Université Rouen: UFR de Médecine.
15. Carr Ac, Frei B. Toward a new recommended dietary allowance for vitamin C based on antioxydant and health effects in humans. Am J Clin Nutr. 1999;69:1086-107.
16. Vitale S, West S, Hallfrisch J, Alston C, Wang F, Moorman C, et al. Plasma antioxidants and risk of cortical and nuclear cataract. Epidemiology. 1993;4:195-203.

Source of Support: Nil, **Conflict of Interest:** None declared.

Case Report

A squamous cell carcinoma of the lower lip with a discoid lupus erythematosus

Boubacar Ahy Diatta, Salimatou Diallo, Matar Ndiaye, Silly Touré, Gisèle Wotto Gaye, Mame Thierno Dieng

Department of Dermatology of the Cheikh Anta Diop University of Dakar, Dakar, Senegal

Corresponding author: Dr. Boubacar Ahy Diatta, E-mail: ahydiatta@yahoo.com

ABSTRACT

Squamous cell carcinoma (SCC) is a malignant tumor with an estimated prevalence of 0.09% in Dakar. We report the case of a 40-year-old man with chronic lupus of the lower lip confirmed by histology and treated with topical corticosteroids and synthetic antimalarials for six years. He was hospitalized for an ulcerated and budding tumor of the lower lip evolving for six months whose histological study confirmed a squamous cell carcinoma. Complete surgical resection was performed and safety margins of 1 cm were excised with lymph node dissection under the mandible. The clinical result was favorable. Early surgical management has improved its prognosis.

Key words: Squamous cell carcinoma; Discoid lupus erythematosus; Dakar

INTRODUCTION

Squamous cell carcinoma (SCC) is a malignant tumor with an estimated prevalence of 0.09% in Dakar. It most often occurs on preexisting dermatosis, such as discoid lupus erythematosus (DLE) [1]. This autoimmune dermatosis is characterized on the one hand by erythematous-squamous and atrophic lesions on the sun-exposed areas and on the other hand by histopathological alterations such as hyperkeratosis, atrophy of the mucous body of Malpighi, liquefying necrosis of the basal layer, and lymphocytic infiltrate [2]. Lip carcinoma accounts for 8% of labial dermatoses in Senegal [3]. Its severity is related to the risk of metastasis with fatal evolution and aesthetic damage [1,4,5]. We report a case of SCC of the lower lip occurring on a lesion of discoid lupus.

CASE REPORT

A 40-year-old man, with no history of alcohol or tobacco use, was admitted to the hospital for a tumor of the lower lip that had been evolving in a preexisting lesion six months ago. The previous medical and clinical reports revealed that he has been followed up for six years in a practice of dermatology for DLE of the lower lip and lower limbs, which was confirmed by histology. He received dermocorticoids and synthetic antimalarials for these lesions. Physical examination revealed an ulcerous-budding tumor measuring 3 cm in diameter associated with an erythematous, squamous, and atrophic plaque on the lower lip (Figs. 1a and 1b). There were also hypopigmented atrophic macules of the lower limbs. The lymph nodes were normal. Histopathology of the lip tumor revealed infiltrated and differentiated squamous cell carcinoma (Figs. 2a and 2b). The serological tests were normal, with leukocytes measured at 7200/mm^3, hemoglobin at 14 g/dl, and blood platelets at 250.103/mm^3. Fasting blood glucose was at 1.02 g/l. Transaminases, serum electrolytes, blood urea, creatinine clearance, C-reactive protein were also normal. Serology of HIV and viral hepatitis came back negative. A thoracoabdominal scan (computed tomography) was normal. A complete surgical resection was performed, and safety margins of 1cm were excised with node dissection under the mandible.

How to cite this article: Diatta BA, Diallo S, Ndiaye M, Touré S, Gaye GW, Dieng MT. A squamous cell carcinoma of the lower lip with a discoid lupus erythematosus. Our Dermatol Online. 2019;10(4):376-378.

Submission: 19.03.2019; **Acceptance:** 19.05.2019

DOI:10.7241/ourd.20194.16

The outcome was favorable.Complete healing was observed without reccurence (Fig. 3). The follow-up period was four years. Histopathological examination of the surgical specimen revealed healthy margins and the absence of metastases in the removed lymph nodes.

Prior to the study, patient gave written consent to the examination and biopsy after having been informed about the procedure.

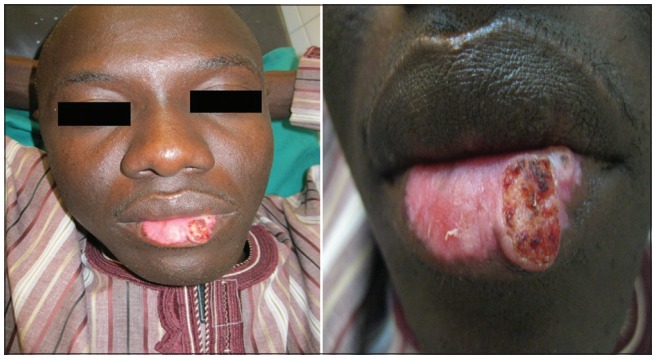

Figure 1: Ulcerated tumor of the lower lip on a lesion of discoid lupus erythematosus.

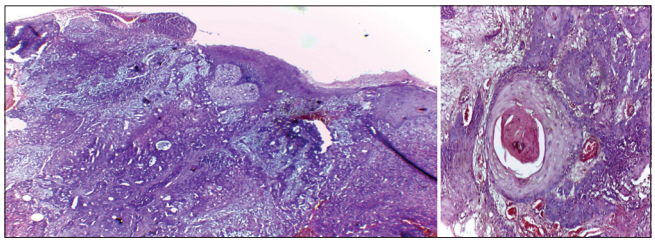

Figure 2: SCC grade1: cell carcinomatous proliferation with well-differentiated malignant epithelial cells invading the dermis with masses centered by keratin pearls (HE x40, x100).

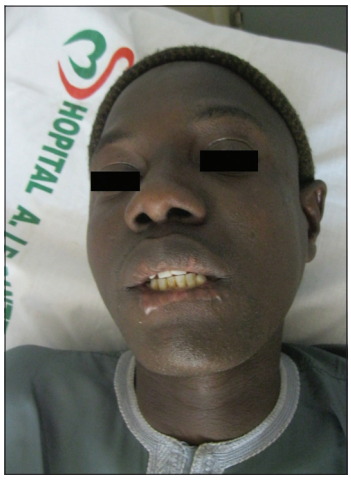

Figure 3: Complete cicatrization after surgical treatment.

DISCUSSION

In this case study, we report the early diagnosis, successful management, and favorable outcome of a case of squamous cell carcinoma of the lip. SCC can occur on acquired or congenital precancerous lesions. The most frequent of these include burn scars, discoid lupus, leg ulcer, xeroderma pigmentosum, and albinism [1,5,6]. Diagnostic delay is often observed in Senegal, resulting in a long duration of evolution that leads to very advanced tumors, thus making curative treatment difficult [1,3]. Discoid lupus of the lip constitutes the second most common pre-cancerous dermatosis in Senegal. It is characterized by erythema, scales, and skin atrophy [2]. The pathogenic mechanisms favoring photocarcinogenesis seem to be related to tumor suppressor gene inactivation (p53). Multiple solar exposures result in inactivation of the p53 protein, which in turn initiates and promotes the development of carcinoma [7]. The combined action of the repeated solar exposure and the presence of atrophic lupus lesion have contributed to the development of labial carcinoma in our patient [1,3,7]. The curative management of labial carcinomas can include major challenges, depending on early diagnosis of the tumor, the tumor's size, conservative surgery, and reconstruction plasties. The factors for good prognosis in our patient were the absence of both metastasis and recurrence after surgical treatment. However, monitoring long-term recurrences must be mandatory [8,9].

CONCLUSION

Squamous cell carcinoma of the lip is a severe tumor. It can be fatal in advanced forms. Early surgical management of localized tumors can improve the prognosis. Hence, multidisciplinary care for rigorous monitoring of precancerous lesions is important.

Consent

The examination of the patient was conducted according to the Declaration of Helsinki principles.

REFERENCES

1. Dieng MT, Diop NN, Déme A, Sy TN, Niang SO, Ndiaye B. Squamous cell carcinoma in black patients: 80 cases. Ann Dermatol Venereol. 2004;131:1055-7.
2. Dieng MT, Ndiaye B. Carcinome épidermoïde sur lupus érythémateux discoïde (Trois Observations). Dakar Med. 2001;46:73-5.

3. Niang SO, Diatta BA, Touré S, Niang PD, Coumé M, Kane A. Dermatoses des lèvres. A propos de 72 cas au Sénégal. Rev Sen Odontol Stomatol Chir Maxillo-Fac. 2010;7:11-7.
4. Maïga S, Diom ES, Palou ER, Ndiaye C, Ndiaye M, Dieye A, et al. Epidemiology, clinical features and treatment of lip cancers in Senegal. Health Sci Dis. 2017;18:74-8.
5. Fernandes MS, Girisha BS, Viswanathan N, Sripathi H, Noronha TM. Discoid lupus erythematosus with squamous cell carcinoma: a case report and review of the literature in Indian patients. Lupus. 2015;24:1562-6.
6. Wakisa KM, Fagan J. Squamous cell carcinoma in black patients with discoid lupus erythematosus. S Afr J Surg. 2006;44:144-6.
7. Kim DY, Rha EY, Yoo G, Lim JS. Squamous cell carcinoma on the upper lip of a patient with discoid lupus erythematosus. Arch Plast Surg. 2013;40:155-7.
8. Gervin CM, McCulla A, Williams M, Ouhtit A. Dysfunction of p53 in photocarcinogenesis. Front Bio sci. 2003;8:715-7.
9. Ee HL, Nq PP, Tan SH, Goh CL. Squamous cell carcinoma developing in two Chinese patients with chronic discoid lupus erythematosus: the need for continued surveillance. Clin Exp Dermatol. 2006;31:542-4.

Source of Support: Nil, **Conflict of Interest:** None declared.

Case Report

Idiopathic acro-osteolysis: Hajdu Cheney syndrome

Asmaa Sqalli Houssaini, Siham Mansouri, Ouiam El Aanzi, Nadia Ismaili, Karima Senouci, Badr Hassam

Dermatology and venereology department, University Hospital Center Ibn Sina, Rabat, Morocco

Corresponding author: Dr. Asmaa Sqalli Houssaini, E-mail: sqalli_asmae@hotmail.com

ABSTRACT

Acro-osteolysis (AO) involves partial or total destruction of the distal phalanges of the fingers or toes. The range of forms of AO is extremely wide. We distinguish acquired forms and the genetic and idiopathic forms. We report a case of 49 years old lady who presented shortening of the fingers on her right hand. We retained an idiopathic AO: Hajdu Cheney syndrome on clinical and radiological criteria as well as the absence of other etiologies. Despite recent improvement in the knowledge of the disease, no cure is available.

Key words: Acro-osteolysis; Idiopathic; Hajdu Cheney

INTRODUCTION

Hajdu-Cheney is a rare, autosomal dominant disorder, with sporadic cases, associated with mutations in the terminal exon 34 of the NOTCH2 gene encoding the transmembrane NOTCH2 receptor and characterized by acroosteolysis of hands and feet, developmental defects of bones, teeth and joints causing distinctive craniofacial and skull changes, and also manifested by severe osteoporosis and short stature [1]. We report a case of Hajdu Cheney syndrome.

CASE REPORT

A 49 years old lady consulted for a shortening of the fingers on her right hand that had been evolving for several years. The patient had no history of Raynaud's phenomena, occupational exposure to vinyl chloride gas or any recurrent trauma. Clinical examination revealed short stubby fingers with brachyonychia (Fig. 1). Detailed skin and systemic examination failed to detect any abnormalities. A short stature (1.47m) was noted. Otherwise, the patient reported that since the age of 15 she had a loss of teeth leading her to put a denture at 30 years.

The radiograph of her right hand showed a complete resorption of the third phalanges (Fig. 2) and the radiograph of the patient's skull revealed an occipital hyperostosis (Fig. 3). Blood counts, hepatic and renal function, Calcium levels, angiotensin converting enzyme and parathyroid hormone were normal. Antinuclear Antibodies (ANA) were negative. Neurological evaluation and The electromyogram were normal. Serological tests for syphilis were negative. The paraneoplastic checkup was normal as well. A diagnosis of idiopathic phalangeal acroosteolysis, Hadju Cheney disease in its sporadic form, was given as it was the most likely judging from the topography of osteolysis, the premature loss of teeth, the occipital hyperostosis, short stature, with no etiological cause identified. Supplementation with calcium and vitamin D. was recommended.

DISCUSSION

The few primitive forms of AO are retained after getting rid of medical causes, toxic, traumatic to paraneoplastic.

Radiologically, we consider two types. The longitudinal acro-osteolysis of the distal portion of the phalanx is more common in scleroderma, Raynaud's disease, sarcoidosis, psoriatic arthropathy, neuropathic disease, hyperparathyroidism, porphyria, progeria and

How to cite this article: Sqalli Houssaini A, Mansouri S, El Aanzi O, Ismaili N, Senouci K, Hassam B. Idiopathic acro-osteolysis: Hajdu Cheney syndrome. Our Dermatol Online. 2019;10(4):379-381.

Submission: 08.02.2019; **Acceptance:** 09.04.2019

DOI:10.7241/ourd.20194.17

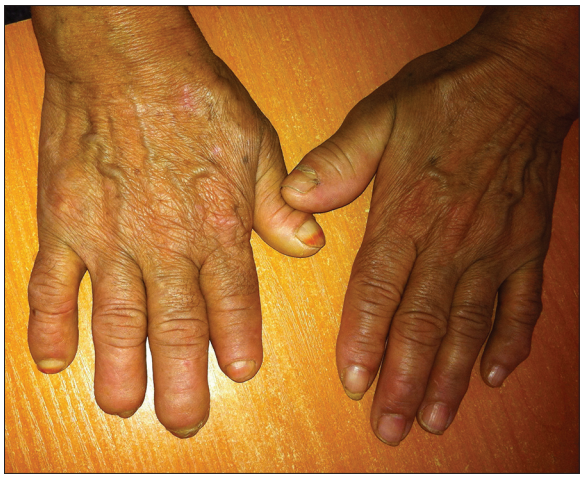

Figure1: Hands showing shortened fingers of the right hand with brachyonychia.

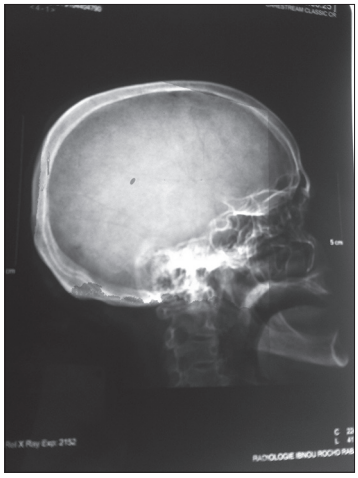

Figure 2: X-rays of the hands showed osteolysis of the 3rd phalanges.

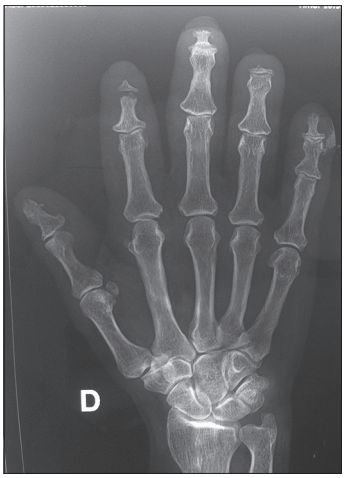

Figure 3: X-rays of the skull: occipital hyperostosis.

pachydermoperiostosis [2] probably secondary to arteritis of inflammatory lesions. The acro-osteolysis, transversally, suggests vinyl chloride poisoning or poisoning due to certain venoms and would be secondary to lesions of vasculitis immunoallergic. It can also appear due to repetitive work that requires constant and repeated pressure on the fingertips.

The idiopathic forms of acro-osteolysis syndrome mainly include the Hajdu Cheney syndrome which is an extremely rare condition (only about 100 recorded cases). Transmission is mainly autosomal dominant, but many cases are sporadic, and evoke new mutations which was the case with our patient who didn't have similar case in her family.

Hajdu Cheney syndrom is reportedly caused by mutations in NOTCH2, which has an important role in the development of the skeleton and in bone remodeling through its action on cells of the osteoblast and osteoclast lineage, and a gain-ofNOTCH2 function results in diverse clinical manifestations. [3]

There are no established criteria for this disease. Clinical manifestations are: acro-osteolysis, severe osteoporosis associated with additional ossification anomalies, hypermobility, and a craniofacial dysmorphic syndrome. AO is generally symmetric and bilateral, and leads to the shorting of digits. Vertebrae are mostly affected with vertebral collapse, which results in a short stature. Dysmorphia involves the loss of teeth, a dolichocephalic skull, a short neck, micrognathia, down-slanted palpepral fissures, hypertelorism, and downturned mouth [4].

Radiographs of patients with Hajdu-Cheney syndrome commonly show acro-osteolysis (band resorption of the middle third distal phalanx), persistent cranial sutures, absent or hypoplastic frontal sinuses, an elongated sella turcica, basilar invagination or platybasia, and biconcave vertebrae. Other clinical features may also be present including kidney cysts and heart defects (coarctation of aorta, patent ductus arteriosus, septal defect), chest deformity with respiratory failure and recurrent respiratory tract infections, ventricular dilatation, basilar compression, syringohydromyelic cavities, hearing loss, and abnormal deep voice. These malformations are rarely observed. In all cases of the literature, reported biological variables are within normal ranges, including phosphocalcic variables [4].

Although the genetic basis of this disease has been deciphered and NOTCH2 has been identified as a causal gene, there is still no cure and patients are currently treated with bone anti-resorptive agents [4] some data suggest that bone mineral density can be

remarkably improved by bisphosphonate treatment associated with supplementation with calcium and vitamin D [5,6].

CONCLUSION

Despite recent improvement in the knowledge of the disease, no cure is available. Its evolution is unpredictable; it will either stabilize or extend to the other bones of the hands and feet: hence the interest of long-term monitoring.

REFERENCES

1. Adami G, Rossini M, Gatti D, Orsolini G, Idolazzi L, et al. Hajdu Cheney syndrome; report of a novel NOTCH2 mutation and treatment with denosumab. Bone. 2016;92:150–156.
2. Datta PK, Ghosh S, De A. Idiopathic non-familial Acro-osteolysis: A rare case report. Indian J Dermatol. 2012;57:486-8.
3. Canalis E, Zanotti S. Hajdu-Cheney syndrome, a disease associated with NOTCH2 mutations. Curr Osteoporos Rep. 2016;14:126–31.
4. Deprouw C, Feydy A, Giraudet Le Quintrec JS, Ruiz B, Kahan A, Allanore Y. A very rare cause of acro-osteolysis: Hajdu-Cheney syndrome. Joint Bone Spine. Joint Bone Spine. 2015;82:455-9.
5. Drake WM, Hiorns MP, Kendler DL. Hadju-Cheney syndrome: response to therapy with bisphosphonates in two patients. J Bone Miner Res. 2003;18:131–3.
6. McKiernan FE. Integrated anti-remodeling and anabolic therapy for the osteoporosis of Hajdu-Cheney syndrome: 2-year follow-up. Osteoporos Int. 2008;19:379–80.

Source of Support: Nil, **Conflict of Interest:** None declared.

Case Report

A phenotypic variant of Job-Buckley syndrome

Asmae Rasso, Hanane Baybay, Hakima Elmahi, Sara Elloudi, Fatima Zahra Mernissi

Department of Dermatology, Hassan II University Hospital Center, Fes, Morocco

Corresponding author: Dr. Asmae Rasso, E-mail: rassoasmae@gmail.com

ABSTRACT

The syndrome of hyper-immunoglobulinemia E or Job-Buckley syndrome is a rare primary immunodeficiency, due to a dysfunction of the STAT 3 gene. It is characterized by a triad associating a high immunoglobulin E (IgE), eczema and recurrent severe infections with staphylococcus. It's about a patient of a 15-year-old t with a history of familial and personal atopy, a notion of bacterial and mycological infection repetitive since the age of 6 years without any similar case in the family. The clinical examination found a carapace of the scalp, a facial dysmorphism made of hypertelorism, epicanthus, mandibular prognathism, dental agenesis, macrocheilia, eczema, a stunting delay, a pubertal delay with an increase in total IgE. The patient was on oral antimycotic and topical, antibiotic, antihistamine, and vitamin C, with favorable evolution of more than 2 years. Buckley's syndrome is a rare entity that should not be ignored before a table of recurrent skin infections, inflammatory dermatitis, and hyper-gammaglobulinemia E.

Key words: Hyperimmunoglobulinemia E; STAT 3 gene; Skin manifestations

INTRODUCTION

Autosomal dominant hyper-IgE syndrome (AD-HIES) described for the first time in 1966 by Davis et al. called «Job". This syndrome was secondarily named by Buckley to a hyper-immunoglobulinemia E in 1972. It was in 1973 by Clark, then in 1974 when Hill showed that these two syndromes initially described rest on a defect of the chemotaxis of the neutrophils [1,2]. The physiopathology incriminates the mutation of the STAT3 gene. This gene is involved in the immune mechanisms. Indeed, the mutation of this gene will lead to an intensification of the production of immunoglobulin E by B lymphocytes, the loss of the modulation capacity of their production by IL 10 and IFN γ [4]. This pathology affects a female subject, but especially both sexes are reached, without ethnic factor. The familial character has only rarely been described [1]. This syndrome is associated with particular clinical characteristics of immunological and morphological order [1-3]. The usual diagnostic criteria of SHIE include [9]: Hyper IGE greater than 2000 IU/ml, moderate hyper eosinophilia, eczematous dermatitis, recurrent bacterial infections, specially staphylococcus aureus, with a cutaneous seat, pulmonary, Ear Nose and Throat. We report Moroccan boy in a 16-year-old has a SHIE.

CASE REPORT

Our case was a boy with 16 years old, 6th of a sibling of 7, from a non-consanguineous marriage, well vaccinated, good psychomotor development until the age of 7 years without any similar case in his family, he had an atopy eczema, rhinitis, conjunctivitis, and asthma in family, he presented a several episodes of bacterial and mycological infection, at 7 years of age. He was hospitalized for management of a severe mycotic infection of the scalp. The clinical examination found facial dysmorphism with hypertelorism. epicanthus, mandibular prognathism and dental agenesis (Fig. 2), a macrocheilia (Fig. 2), a carapace of the scalp with adhering yellowish scales (Fig. 1), a stunted delay with - 5 (Deviation Standard) (Fig. 1), a pubertal delay P1, G2 according to TANNER classification. Ophthalmological examination revealed superinfected allergic conjunctivitis and the Ear, Nose and Throat examination showed chronical otitis media. The biological assessment revealed a hyper eosinophilia at 2950 element/ml, a biological inflammatory syndrome,

How to cite this article: Rasso A, Baybay H, Elmahi H, Elloudi S, Mernissi FZ. A phenotypic variant of Job-Buckley syndrome. Our Dermatol Online. 2019;10(4):382-384.

Submission: 18.02.2019; **Acceptance:** 12.05.2019

DOI:10.7241/ourd.20194.18

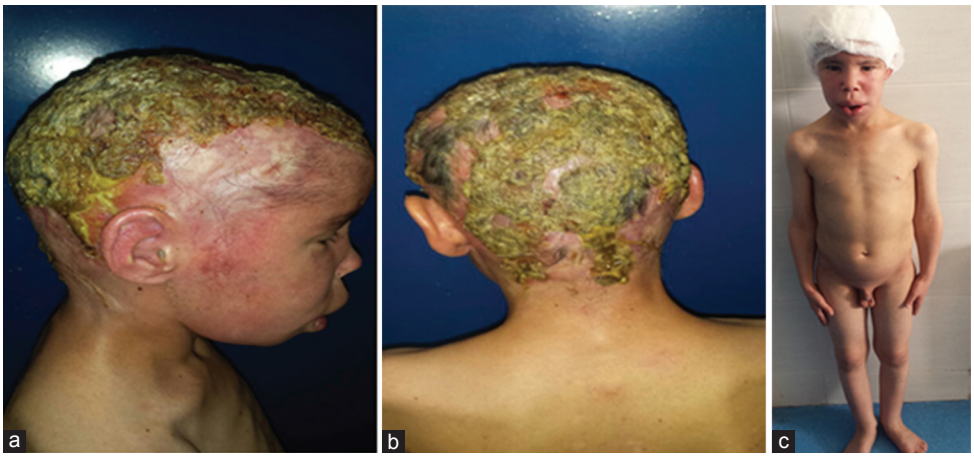

Figure 1: (a,b) Scalp carapasse, facial dysmorphia (c) a stunting and pubertal delay in 16 years old patient.

the bacteriological and mycological scalp sampling were positive with staphylococcus and Trichophyton Rubran. viral, bacterial, parasitic serologies (Hepatitis B and C, HIV, CMV, syphilis toxoplasmosis) were negative. A level of immunoglobins. intradermal to tuberculin was negative, abdominal ultrasound had found the liver is dysmorphic with hypertrophy of the left lobe, regular contours and echo homogeneous structure, and homogeneous splenomegaly, trans-thoracic ultrasonography revealed left ventricular hypertrophy, and a conserved ejection fraction. The result of the skin biopsy is in favor of non-specific folliculitis. a biopsy of the salivary glands made objectified chronic Sialadenitis grade 1 of Shisolmet Masson without specificity. The diagnosis of job-Buckley syndrom was retained on clinical, biological and radiological criteria. The patient has benefited from a symptomatic treatment based on antiseptic antibiotic and antimycotic "Griseofulvin" without reponse and then "Terbinafine" in front of the non-improvement, then he has benefited from red and blue light for anti-inflammatory effect, antihistamine and emollient creams with good evolution. then he was treated by an antibiotic prophylaxis injection of "Penitard 600000 IU/3 weeks" associated with the trimethoprim-sulfamethoxazole and vitamin C, dental extractions. then application of topical corticosteroid subsequently after conversion of infectious balance with a very favorable evolution without relapse in more than 2 years (Figs. 3 - 5).

DISCUSSION

Job-Buckley Syndrome or Hyper-Immunoglobulin E Syndrome (SHIE) is a rare multi-systemic infectious syndrome related to a primary immunological disorder. It affects both sexes, in the first weeks of life but sometimes at a later age as the case of our patient. This pathology

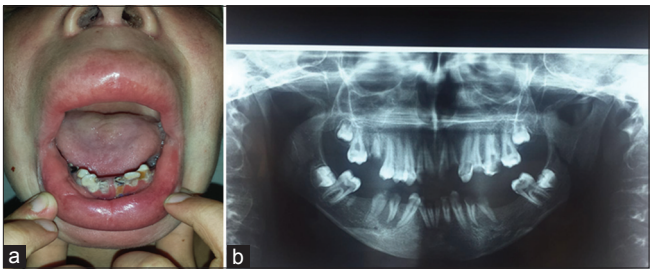

Figure 2: (a) Macrocheilia, (b) Mandibular prognathism and dental agenesis.

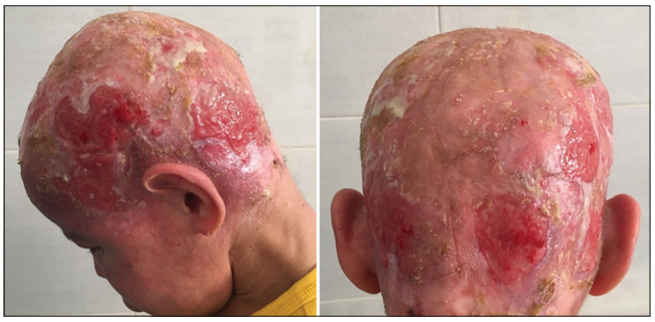

Figure 3: Favorable evolution after 6 months of treatment.

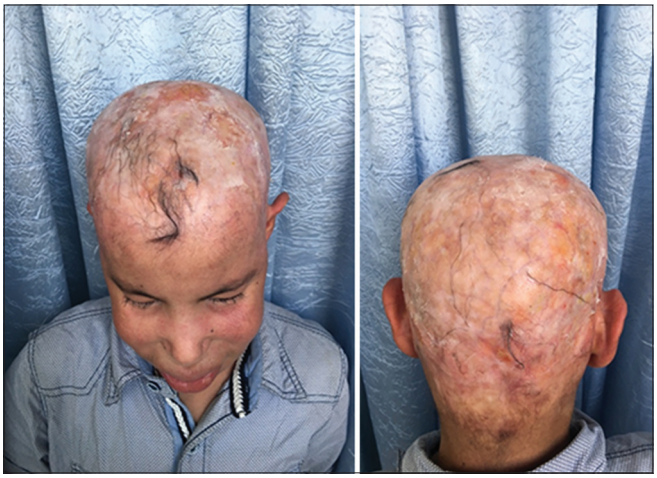

Figure 4: Favorable evolution after 2 years of treatment.

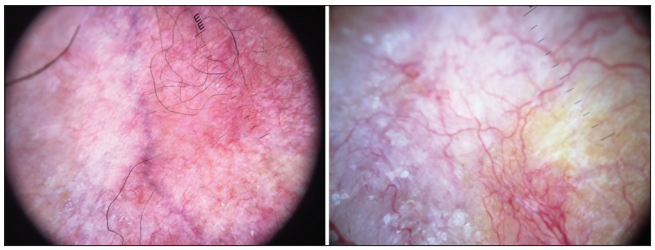

Figure 5: Cutaneous atrophy with telangiectasia at dermoscopy.

is caused by the lack of chemotaxis of neutrophils [5] which leads to an immunodeficiency responsible for the generalized infectious manifestations characteristic of this syndrome [1,6]. These are bacterial and are found mainly in the skin as abscesses, pneumonia. The offending bacterial species are, staphylococcus aureus in 60% of cases, hemophilus influenzae in 10% of cases and, infrequently, streptoccoccus, pneumoniae, cryptococcus neoformans, aspergillus fumigatus [1,2]. Chronic candida infections, mainly related to Candida albicans [1]. This explains therecurence bacterial and mycological infections in our patient. From a morphological point of view, the manifestations are mostly facial asymmetry with hemi-hypertrophy, flattening of the base of the nose, prominent forehead [1,2,4,7], as reported in this case. They develop early in childhood. The manifestations are also oral with a delay of the loss of the temporary teeth in 75% of the cases causing a delay of eruption of the permanent teeth or an ectopic eruption of these teeth and malocclusions [8]. Mucosal lesions are often seen in the form of keratotic streaks or plaques that may be similar of lichenoid lesions [1]. Other inconsistent skeletal signs are reported, such as early cranial synostosis, osteoporosis and osteogenesis imperfecta causing frequent fractures of long bones, scoliosis [2]. On the dermatological level, this syndrome is characterized by the presence of a chronic dermatosis like an atopical dermatis preferentially evolving in the face, ears and scalp, and this, from the first months of life [1]. Other clinical and biological manifestations, but more inconsistent, are observed in this pathology such as vascular, skeletal, facial and oral abnormalities.

In early childhood, we can mention 2 differential diagnoses:

- High-dose atopic dermatitis of IgE with recurrent staphylococcal skin infections, for which a favorable evolution of IgE can be observed. However, the best criterion remains the absence of visceral involvement in dermatitis [6].
- Chronic granulomatosis must also be mentioned, it is frequently associated with osteomyelitis, whereas this is not observed in Job's syndrome [6].

The treatment of Job-Buckley syndrome is purely symptomatic and concerns the infectious, dermatological and ocular manifestations. It is based on the regular and prophylactic use of antibiotics (including trimethoprim-sulfamethoxazole) The prescription of antibiotics, antihistamines and vitamins allows stabilization of lesions [6,9,10] as the case of our patient.

CONCLUSION

Job-Buckley syndrome is a rare immune disorder responsible for recurrent infections associated with high levels of serum IgE. There is currently no safe treatment that has clearly demonstrated efficacy. The prognosis depends primarily on the early management of pathology to reduce if possible, complications, particularly the infectious one.

Consent

The examination of the patient was conducted according to the Declaration of Helsinki principles.

RÉFÉRENCE

1. Ikiss JA, Alaoui OM. Le syndrome de Job-Buckley: à propos d'un cas et revue de la littérature. Med Buccale Chir Buccale. 2015;21:105-8.
2. DeWitt CA, Bishop AB, Buecher LS, Stone SP. Hyperimmunoglobulin E syndrome: two cases and a review of literature. J Am Acad Dermatol. 2006;54:855-65.
3. Buckley RH. The hyper IgE syndrome. Clin Rev Allergy Immunol. 2001;20:139-54.
4. Avery DT, Ma CS, Bryant VL, Santner-Nanan B, Nanan R, Wong M, et al. STAT3 is required for IL-21-induced secretion of IgE from human naive B cells. Blood 2008:1;112:1784-93.
5. Conti HR, Baker O, Freeman AF, Jang WS, Holland SM, Li RA, et al. New mechanism of oral immunity to mucosal candidias in hyper-IgE syndrome. Mucosal Immunol. 2011;4:448-55.
6. Dervaux B, Le Goff C, Turbanski F, Baidj Z, Coche R. Recurrent infection in a child caused by Job-Buckley syndrome. Arch Pediatr. 2009;16:122,142-5.
7. Borges WG, Hensley T, Carey JC, Petrak BA, Hill HR. The face of Job. J Pediatr 1998;133:303-5.
8. Bodard A-G, Delaunay T, Salino S. Manifestations buccales du syndrome de Job-Buckley: à propos d'un cas. Med Buccale Chir Buccale. 2010;16:113-7.
9. Fégel P. Le syndrome du Buckley: Revue de la littérature et à propos d'un cas. Thèse N°57. Université Henri Poincaré, Nancy 1 2002.
10. Guerouaz N. Benhiba H. Hassam B. Le syndrome de Buckley: une nouvelle observation. Ann de Dermatol Vénéréol. 2013;140:S44-5.

Source of Support: Nil, **Conflict of Interest:** None declared.

Clinical Image

Profuse warts revealing a WHIM syndrome

Younes Barbach, Mohammed Chaouche, Abdellah Dah Cherif, Salim Gallouj, Fatima Zahra Mernissi

Departement of Dermatology, CHU Hassan II, Fès, Morocco

Corresponding author: Dr. Younes Barbach, E-mail: dr.younes2011@gmail.com

Warts, hypogammaglobulinemia, recurrent infections, and myelokathexis (WHIM) syndrome is a rare autosomal dominant immune deficiency. It has been individualized since 1990, initially described in 1964 by Zuelzer-Krill [1]. Other symptoms include severe neutropenia, condyloma acuminate, malignancies (mainly carcinomas related to human papilloma virus infection), and B-cell lymphopenia with impaired antibody responses after vaccination. Patients may also present with or develop lymphopenia, monocytopenia, and deficiency of plasmacytoid dendritic cells in the circulation, with impairment in both innate and adaptive immunity. Mobilization of neutrophils can occur during acute infection. Thus, adequate neutrophil count should not rule out this condition, particularly if complete blood count is tested throughout the course of acute infections [2]. The prognosis for patients with WHIM depends in part on early recognition of the disorder, with aggressive medical intervention to reduce the frequency of recurrent bacterial infections, and to detect and extirpate in the early stages any HPV lesions that appear to be dysplastic or malignant [3].

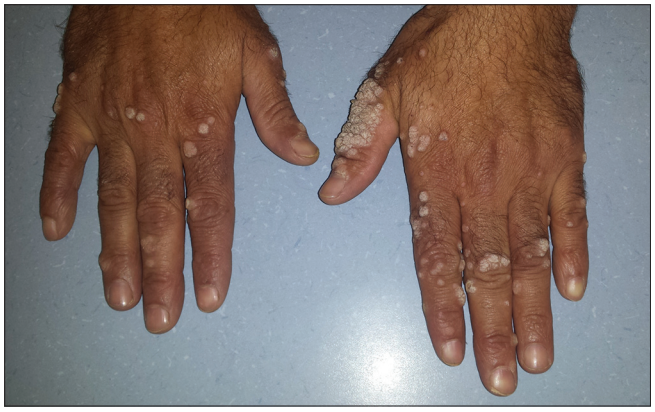

Figure 1: Vulgar warts diffused at the level of the 2 hands

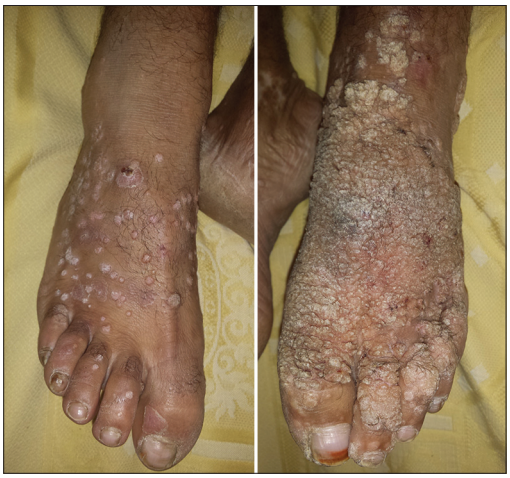

Figure 2-3: Diffuse vulgar warts at the level of 2 feet with the presence of a verrucous cupboard of the back of the left foot

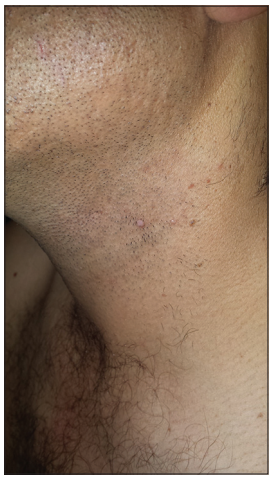

Figure 4: Multiple vulgar warts at the neck

How to cite this article: Barbach Y, Chaouche M, Cherif AD, Gallouj S, Mernissi FZ. Profuse warts revealing a WHIM syndrome. Our Dermatol Online. 2019;10(4):387-388.

Submission: 16.10.2018; **Acceptance:** 08.12.2018

DOI:10.7241/ourd.20194.19

We report the case of a 34-year-old patient, with no similar case in the family, who for the last 8 years had profuse warts on the hands, feet and neck (Figs. 1 - 4), as well as recurrent episodes of skin bacterial infections. Biological exploration showed the presence of severe neutropenia and moderate hypogammaglobulinemia. The patient was initially put under salicylic acid, then oral retinoid and cimetidine, with average improvement of lesions and antibiotic prophylaxis to prevent bacterial superinfections.

Consent

The examination of the patient was conducted according to the Declaration of Helsinki principles.

REFERENCES

1. Bouregaa S, Hammadi H, Meddour Y, Younsi F, Timsiline M, Keniza H, et al. Verrues profuses révélant un syndrome WHIM: à propos d'un cas algérien. Ann Dermatol Vénéréologie. 2014;141(12, Suppl):S376–7.
2. Saettini F, Notarangelo LD, Biondi A, Bonanomi S. Neutropenia, hypogammaglobulinemia, and pneumonia: A case of WHIM syndrome. Pediatr Int. 2018;60:318–9.
3. Kawai T, Malech HL. WHIM Syndrome: Congenital Immune Deficiency Disease. Curr Opin Hematol. 2009;16:20–6.

Source of Support: Nil, **Conflict of Interest:** None declared.

Clinical Image

Melkersson Rosenthal syndrome: a case report of a rare disease

Taysir Ben Achour, Sameh Sayhi

Autoimmune Disease Research Unit (UR17DN02), Internal Department of Medicine, Military Hospital of Tunis, Tunisia

Corresponding author: Dr. Sameh Sayhi, E-mail: sameh_sayhi@yahoo.fr

Melkersson-Rosenthal syndrome (MRS) or Cheilitis granulomatosa is a rare granulomatous disease, which presents as orofacial swelling, facial palsy and fissured tongue [1]. These symptoms may occur simultaneously or, more frequently, with an oligosymptomatic or monosymptomatic pattern [2]. The histological characteristics of MRS are granulomatous infltrate constituted by epitheloid cells and multinucleate giant cells, without caseous necrosis, associated with some degree of lymphoedema and fibrosis [3]. Treatment involves systemic and/or topical corticosteroid.

We present a 41-year old male patient with no familial and personal history of angioedema, was admitted in our department with persistant lip oedema. Dermatologic examination found lower lip edema on his face and fissure on his tongue (Fig. 1). The patient informed us about his recurrent and spontaneous facial paralysis in previous years. C1-inhibitor (C1-INH) deficiency was eliminated. A Melkersson-Rosenthal syndrome was confirmed by histologic findings of non caseating granulomas on lip biopsy. Corticoids were established with regression of symptoms.

Consent

The examination of the patient was conducted according to the Declaration of Helsinki principles.

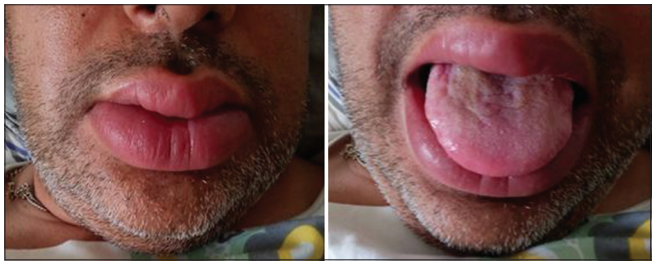

Figure 1: Lip oedema and fissured tongue.

REFERENCES

1. Kosovali B, Yavuz A, Yesiler F, Kemal Bayar M. Melkersson-Rosenthal syndrome: a rare cause of recurrent facial nerve palsy and acute respiratory distress syndrome. Case Rep. Neurol Med. 2018;2018:1373581.
2. Klii R, Chebbi W. Syndrome de Melkersson-rosenthal: une entité rare à ne pas méconnaitre. Pan African Med J. 2015;21:33.
3. Cancian M, Giovannini S, Angelini A, Fedrigo M, Bendo R, Senter R, et al. Melkersson-Rosenthal syndrome: a case report of a rare disease with overlapping features. Allergy Asthma Clin Immunol. 2019;15:1.

Source of Support: Nil, **Conflict of Interest:** None declared.

How to cite this article: Achour TB, Sayhi S. Melkersson Rosenthal syndrome: a case report of a rare disease. Our Dermatol Online. 2019;10(4):389.
Submission: 19.03.2019; **Acceptance:** 19.05.2019
DOI: 10.7241/ourd.20194.20

Clinical Image

Eyebrows contact dermatitis miming angioedema

Imane Alouani[1], Siham Dikhaye[1,2], Nada Zizi[1,2]

[1]*Department of Dermatology, Mohammed 6 University Hospital of Oujda - Medical School of Oujda, Oujda, Morocco,*
[2]*Laboratory of Epidemiology, Clinical Research and Public Health, Medical School of Oujda, Mohammed First University, Oujda, Morocco*

Corresponding author: Dr. Imane Alouani, E-mail: alouani01@gmail.com

A 27-years-old lady was admitted to the emergency department of our institute for bilateral pruritic periorbital swelling. She had no prior history of eczema or any allergic reactions. Three days before her admission, she had her brows tinted by with a black eyebrow dye containing para-phenylenediamine (PPD). Examination revealed an erythematous papulovesicular, partially crusted lesion on both eyebrows (Fig. 1). A diagnosis of a contact dermatitis was made and a course of topical desonide ointment once a day for one week resolved the eruption.

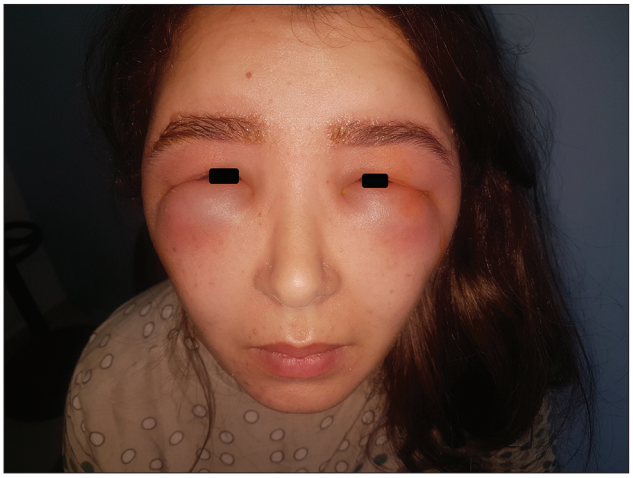

Figure 1: Bilateral pruritic periorbital swelling with papulovesicular crusted lesion of the eyebrows.

Contact dermatitis from PPD miming angioedema has rarely been reported in the literature [1,2]. The skin lesions have been reported to be erythema, erythema multiforme-like eruption, bullous contact dermatitis, pruritic, edematous, erythematous scaly patches and plaques or vesicular lesions [1].

Consent

The examination of the patient was conducted according to the Declaration of Helsinki principles.

REFERENCES

1. Demirci GT, Altunay IK, Atis G, Kucukunal A. Allergic contact dermatitis mimicking angioedema due to paraphenylendiamine hypersensitivity: a case report. Cutaneous and Ocular Toxicology, 2012;31:250–2.
2. Sánchez-Guerrero IM, Huertas AJ, López MP, Carreño A, Ramírez M, Pajarón M. Angioedema-like allergic contact dermatitis to castor oil. Contact Derm. 2010;62:318–9.

Source of Support: Nil, **Conflict of Interest:** None declared.

How to cite this article: Alouani I, Dikhaye S, Zizi N. Eyebrows contact dermatitis miming angioedema. Our Dermatol Online. 2019;10(4):390.
Submission: 11.11.2018; **Acceptance:** 28.01.2019
DOI: 10.7241/ourd.20194.21

Letter to the Editor

Adapalene in management of molluscum contagiosum in pediatric population

Mrinal Gupta

Department of Dermatology, Treatwell Skin Centre, Jammu and Kashmir, India

Corresponding author: Dr. Mrinal Gupta, E-mail: drmrinalgupta@yahoo.com

Sir,

Molluscum contagiosum (MC) is a common viral infection caused by DNA Poxvirus. It has no other reservoir than humans and is transmitted directly by skin-to-skin contact or indirectly through fomites. It's a widely prevalent infection commonly affecting children, sexually active adults, and immunodeficient individuals [1]. A large number of treatments exist for treatment of MC which include destructive therapies like curettage, cryotherapy, pricking with a sterile needle, electrodesiccation, photodynamic therapy and lasers. Other topical medications include salicylic acid, tretinoin, potassium hydroxide, trichloroacetic acid and imiquimod. However, no therapy is universally effective and most of these treatment modalities are not well tolerated by children [2-4].

In this study, we tried to evaluate the safety and efficacy of Adapalene 0.1% gel in MC in the pediatric age group.

It was a prospective study carried out over a period of one year in our centre where children aged 3-18 years with molluscum contagiosum were treated with bed time application of adapalene 0.1% and were followed up for three months to evaluate the efficacy and any adverse effects. Those patients who were on any systemic therapy in the past 8 weeks were excluded from the study. All other topical treatments were stopped prior to the study. The effect of treatment was evaluated monthly for three months.

A total of 25 children aged between 3-18 years with a mean age 7.14±1.36 years (M: F 14:11) were included in the study and were followed up over a period of three months. Out of 25 patients, 20 patients completed the study. The total number of molluscum per patient varied from 1-24 with a mean of 3.4 lesions per patient and the mean duration of lesions was 9 weeks ± 2.36 weeks. After one month of treatment, two patients had complete resolution of lesions, whereas after two months, five patients had complete clearance and four had partial response. At the end of three months of follow up, eleven patients (55%) showed complete clearance of lesions, three patients (15%) had partial resolution of lesions where a few molluscum were still present, whereas six patients (30%) had no response. Side effects of adapalene were also observed and over the course of study, five patients (25%) showed some adverse effects like dryness (n=1), erythema (n=3) or irritation (n=4).

A large variety of treatment modalities have been used for molluscum but most of these involve destructive modalities which are not favored in pediatric population. The ideal agent for children should be effective, less irritant, well tolerated and easily available, which can be conveniently applied. Adapalene is a retinoid with ability to alter keratinization and affinity for retinoic acid receptor (RARɣ). It has been found to have anti-inflammatory action, inhibits cell proliferation, and modulates cell differentiation. A few studies have demonstrated the efficacy and safety of adapalene 0.1% gel in the management of molluscum in children [5].

Kashif et al studied the efficacy and safety of trichloroacetic acid 35% versus adapalene 0.1% in treatment of molluscum contagiosum in children, in which they treated 30 children each with trichloroacetic acid and adapalene and observed the clinical response over a period of six weeks. They observed that complete clinical clearance was seen in observed in 25 (83.3%)

How to cite this article: Gupta M. Adapalene in management of molluscum contagiosum in pediatric population. Our Dermatol Online. 2019;10(4):391-392.
Submission: 20.05.2018; **Acceptance:** 25.09.2018
DOI:10.7241/ourd.20194.22

of patients treated with TCA and 20 (66.7%) patients treated with adapalene, however, adverse effects were more common in TCA group with 30% patients (n=9) having adverse effects like erythema, scarring and dyspigmentation as compared to 3.3% (n=1) patients in adapalene group [5]. In our study, we observed a complete clearance in 55% and adverse effects were observed in 25% patients.

Treatment options like extirpation, electrodessication, cryosurgery, TCA and KOH application are the commonly used techniques but they can cause irritation and pain and can lead to scarring, so their use in children is not universally accepted. Adapalene can be used a safer alternative to other modalities in the treatment of MC especially in children.

This study has certain limitations. First of all, it was a single centered trial conducted in a limited population size and the dropout rate was quite high. Moreover, application of adapalene was not carried out under medical supervision as the patients were sent home and had to apply it by themselves.

CONSENT

The examination of the patient was conducted according to the Declaration of Helsinki principles.

REFERENCES

1. Hanson D, Diven DG. Molluscum contagiosum. Dermatol Online J. 2003;9:2.
2. Metkar A, Pande S, Khopkar U. An open, nonrandomized, comparative study of imiquimod 5% cream versus 10% potassium hydroxide solution in the treatment of molluscum contagiosum. Indian J Dermatol VenereolLeprol. 2008;74:614-8.
3. Bayerl C, Feller G, Goerdt S. Experience in treating molluscum contagiosum in children with imiquimod 5% cream. Br J Dermatol. 2003;149:25-9.
4. Mahajan BB, Pall A, Gupta RR. Topical 20% KOH-An effective therapeutic modality for molluscum contagiosum in children. Indian J Dermatol VenereolLeprol. 2003;69:175-7.
5. Kashif M, Tahir R, Hussain I. Efficacy and safety of trichloroacetic acid 35% versus adapalene 0.1% in treatment of molluscum contagiosum in children. J Pak Associat Dermatol. 2017;26:366-70.

Source of Support: Nil, **Conflict of Interest:** None declared.

Letter to the Editor

Rosacea treated with rose petals: a calembour that affords intriguing results

Piotr Brzezinski[1], Lorenzo Martini[2]

[1]*Institute of Biology and Environmental Protection, Pomeranian Academy, Slupsk, Poland,* [2]*University of Siena, Department of Pharmaceutical Biotechnologies, Via A. Moro 2, 53100 Siena, Italy*

Corresponding author: Lorenzo Martini, E-mail: martinil163@libero.it

Sir,

Rosacea is a long-term skin condition that typically affects the face characterized by redness, pimples, swelling, and small and superficial dilated blood vessels [1]. Often the nose, cheeks, forehead, and chin are involved [2].

The cause of rosacea is unknow [1]. Risk factors are believed to include a family history of the condition [2]. Factors that may potentially worsen the condition include excessive heat, UV rays, excessive cold, spicy food, alcohol, menopause, psychological stress [3].

The presence of free radicals (as superoxide and hydroxyl) is utterly incontestable.

In 2007, Gallo and colleagues noticed that patients with rosacea had high levels of the antimicrobial peptide cathelicidin [4] and elevated levels of stratum corneum tryptic enzymes (SCTEs). Cathelicidin is not but a protein produced by neutrophil granulocytes after the signal evoked by inflammatory cytokines. It occurs spontaneously when the skin condition is affected by the presence of bacteria, especially Gram +.

This means that when a patient is affected by Rosacea the presence of bacteria is involved always.

Rosacea affects somewhere between one and ten percent of people. Those affected are most often 30 to 50 years old and female. Caucasians are more frequently affected. The condition was already described in *The Canterbury Tales* in the 1300s [1].

It is noticeable that rose petals, depending on the species of the roses,do contain polyphenols and ellagitannins, apt to reduce free radicals and acting as vasoconstrictor and for this they could be a special remedy to cure Rosacea.

Effectively, some Researchers [5] affirmed that petals of Rosa damascena showed a strong antiradical activity (with DPPH•). Thus, significant antiradical properties (IC_{50} 1.33-0.08 mg mg^{-1} DPPH•) were demonstrated by these A.A. Moreover, notable antimicrobial activity against eight bacterial (i.e. *Staphylococcus epidermidis*, *S. aureus*, *Bacillus subtilis*, *Micrococcus luteus*, *Escherichia coli*, *Klebsiella pneumoniae*, *Pseudomonas aeruginosa*, *Proteus mirabilis*) and two yeast strains (*Candida albicans*, *C. parapsilosis*) was referred by the same Researchers. Total phenolic, flavonoid, phenolic acid, tannin, carotenoid and polysaccharide content in petals was determined using spectrophotometric methods.

It must be stressed that a complete approach to defeat all the problems concerning Rosacea (bacterial profile, redness, vasodilatation, SCTEs, free radicals, presence of mites as Demodex mites) is inconceivable and so we made up our mind to face the two main problems:

Inflammation, vasodilatation, microbial assault

Excess of free radicals.

In order to solve this dilemma we have selected 8 types of common roses that present different antiradical capacities and content of gallic acid (expressed in ellagitannins) and we have chosen different kinds of

How to cite this article: Brzezinski P, Martini L. Rosacea treated with rose petals: a calembour that affords intriguing results. Our Dermatol Online. 2019;10(4):393-395.

Submission: 03.10.2018; **Acceptance:** 22.12.2018

DOI:10.7241/ourd.20194.23

rose petals that showed the maximum FRAP value and the maximum of content of ellagitannins, to combat inflammation, vasodilatation, microbial assault and moreover the free radicals that represent the typical morphology of every type of Rosacea.

Ellagitannins act as anti-inflammatory agents, abstringent, antimicrobial as well.

In Tables 1 and 2 were the antiradical abilities and the contents of ellagitannins of the diverse roses are plotted [4].

And so we decided to use, in order to treat severe Rosacea, the following rose petals: Rosa gallica; Rosa alba; Rosa Provence.

Since they present a very high antiradical capacity and a very high percentage of gallic acid.(expressed in elagitannins).

But we have not neglected the other roses since they are necessary for treating other types of Rosacea, as we will explain in Materials and methods.

We have selected three volunteers, suffering from diverse kinds of Rosacea.

Table 1: Values of antiradical capacity of diverse species of Rose we have employed in this study

Type of rose	Antiradical capacity measured by FRAP
Rosa gallica	1.43 μg/ml at the concentrations of 100 μg/ml
Rosa alba	1.72 μg/ml at the concentrations of 100 μg/ml
Rose provence	1.81 μg/ml at the concentrations of 100 μg/ml
Rose portland	0.99 μg/ml at the concentrations of 100 μg/ml
Rose noisette	1.02 μg/ml at the concentrations of 100 μg/ml
Rose bourbon	1.31 μg/ml at the concentrations of 100 μg/ml
Rose tea	1.40 μg/ml at the concentrations of 100 μg/ml
Rose eglantine	1.61 μg/ml at the concentrations of 100 μg/ml

Table 2: Content of ellagitannins in diverse rose petals (% of the total polyphenols)

Type of rose	Content of ellagitannins (% on total polyphenols)
Rosa gallica	67
Rosa alba	71
Rosa provence	69
Rose portland	72
Rose noisette	69
Rose bourbon	55
Rose tea	66
Rose eglantine	72

- Mild Rosacea (that is represented chiefly by redness especially on forehead and cheekbones)
- Less severe Rosacea (pimples and very strong redness and couperose)
- Severe Rosacea (swelling and exaggerated vasodilatation in all the face).

We have chosen the following roses for the mild and less severe Rosacea, idest:

- Rose Portland, Noisette and Bourbon
- Rosa gallica, Rose Provence and Rose tea.

We have invited the three people to spread the rose petals onto their face for one hour/day and after to rinse with lukewarm water. The treatment lasted one week.

We stated the remission by comparing the gradation of red of the face redness, keeping on account this scale.

Granata; Terracotta; Kermes; Cherry; Pompeian red; Persian red; Dark pinkish.

In Table 3 the decrease of redness of the three volunteers is plotted, day by day, for the entire week.

All the cases, spreading rose petals on their face, at the end of the treatment show a decrease of the redness as well, and their "facies" exhibit a dark pinkish colour, that correspond to a real flesh-coloured appearance, that reveals a complete status of good health and remission of the syndrome.

Mild Rosacea is characterized by a cherry colour, that is the lightest red and anyway this colour decreases after the 4th day to yield to dark pinkish.

Less severe Rosacea is characterized by a red more intense, but after the 4th day the darkness of the face colour diminishes till Persian red, and at the end reach the Dark pinkish colour.

Severe Rosacea is characterized by a red Granata resembling dark brownish, and the remission is slower than in the other cases, although a final dark pinkish is reached after a week of treatment.

The usage of rose petals could be a very exceptional remedy for many cases of Rosacea.

Table 3: The decrease of redness of the three volunteers is plotted, for the entire week

Case	1st day	2nd day	3rd day	4th day	5th day	6th day	7th day
a	Cherry	Cherry	Pompeian red	Pompeian red	Pompeian red	Dark pinkish	Dark pinkish
b	Terracotta	Terracotta	Kermes	Persian red	Persian red	Dark pinkish	Dark pinkish
c	Granata	Granata	Granata	Kermes	Kermes	Persian red	Dark Pinkish

Consent

The examination of the patient was conducted according to the Declaration of Helsinki principles.

REFERENCES

1. Tüzün Y, Wolf R, Kutlubay Z, Karakuş O, Engin B. Rosacea and rhinophyma. Clin Dermatol. 2014;32:35–46.
2. Bimbi C, Brzezinski P. Rosacea-like Tinea Faciei. Our Dermatol Online. 2016;7:78-80.
3. Sener S, Kilinc F, Akbas A, Metin A, Pektas SD, Neselioglu S, et al. Decreased arylesterase activity and increased total oxidative status in rosacea. Our Dermatol Online. 2017;8:385-8.
4. Yamasaki K, Di Nardo A, Bardan A, Murakami M, Ohtake T, Coda A, et al. Increased serine protease activity and cathelicidin promotes skin inflammation in rosacea. Nature Med. 2017;13:975–80.
5. Nowak R, Olech M, Pecio L, Oleszek W, Los R, Malm A, et al. Cytotoxic, antioxidant, antimicrobial properties and chemical composition of rose petals. J Sci Food Agric. 2014;94:560-7.

Source of Support: Nil, **Conflict of Interest:** None declared.

Letter to the Editor

Childhood acute generalized exanthematous pustulosis

Masato Ishikawa, Tatsuhiko Mori, Yuka Hanami, Toshiyuki Yamamoto

Department of Dermatology, Fukushima Medical University, Fukushima, Japan

Corresponding author: Dr. Masato Ishikawa, E-mail: ishimasa@fmu.ac.jp

Sir,

Acute generalized exanthematous pustulosis (AGEP) is an uncommon disease which is usually caused by systemic medication, and its incidence is reported to be 0.35–5 per million per year [1,2]. It is especially rare for AGEP to develop on childhood. We herein describe a pediatric case of AGEP induced by ampicillin.

A 13-year-old boy was hospitalized to the Plastic Surgery Department in our hospital for surgical treatment of scar contracture after extensive burns. He was referred to our department, complaining of high fever and skin rash. In the perioperative period, he was administered ampicillin, cefaclor, non-steroidal anti-inflammatory drugs, acetaminophen, and rabeprazole sodium. Three days after from surgery, itchy erythema appeared to his back. As a result of having been given ampicillin again due to fever, the skin rash spread to a whole body rapidly. Physical examination revealed erythroderma with a number of pinpoint pustules (Figs. 1a and b). Symptoms such as hyperemia were not seen in the mucous membrane, and Nikolsky sign was negative. Laboratory data showed elevated white blood cell count (17600/μl, with 81% neutrophils), and C-reactive protein (6.36 mg/dl). Although a little staphylococcuses were detected in pustule, no bacteria were detected in the blood. A skin biopsy showed pustules in the epidermis with spongiform pustules, and perivascular inflammatory cell infiltration, mainly composed of lymphocytes and eosinophils, in the upper dermis (Fig. 2). After discontinuation of ampicillin and initiation of oral prednisolone (25 mg/day), the erythema and fever quickly disappeared. Patch test showed positive reaction to 10% and 20% ampicillin and negative reaction to all the other drugs used in the perioperative period.

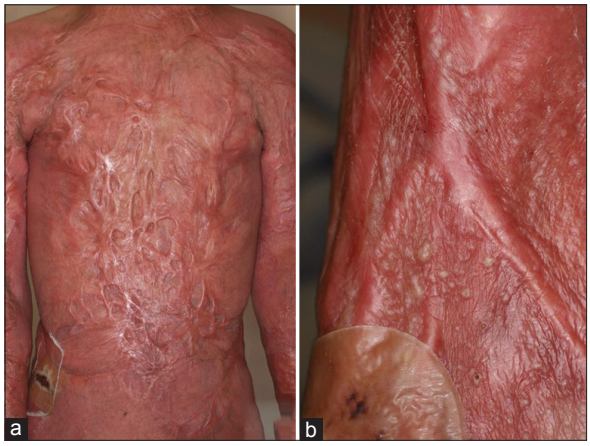

Figure 1: (a) Clinical feature on the trunk showing erythroderma with a number of pinpoint pustules. (b) Pinpoint pustules on the back of the hand.

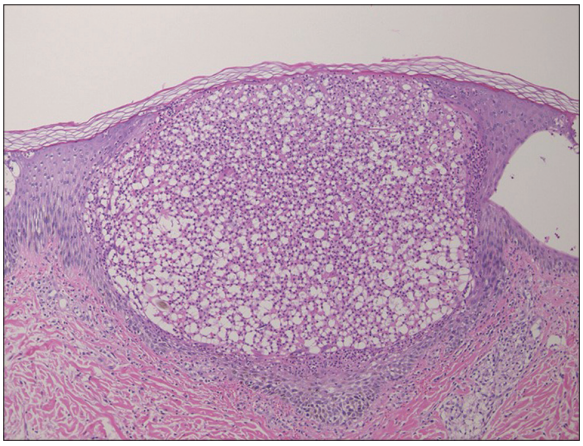

Figure 2: Histopathological specimen showed spongiform pustules in the epidermis, and perivascular inflammatory cell infiltration, mainly composed of lymphocytes and eosinophils, in the upper dermis (hematoxylin-eosin, original magnification x100).

To date, only six English literature cases of childhood AGEP have been reported. The age of patients were

How to cite this article: Ishikawa M, Mori T, Hanami Y, Yamamoto T. Childhood acute generalized exanthematous pustulosis. Our Dermatol Online. 2019;10(4):396-397.

Submission: 28.04.2019; **Acceptance:** 22.07.2019

DOI:10.7241/ourd.20194.24

17 months [3], 4-year-old, 7-year-old, 11-year-old, 12-year-old [4], 13-year-old [5], and 14-year-old (our case). It was assumed that the skin rash was caused by amoxicillin [3], contrast agent, paracetamol, cetirizine, ketoconazole [4], and amoxicillin-clavulanic acid [5]. One case was relieved by just ceasing the application of the suspected drug [3], and other cases were needed another antihistaminic drug, corticosteroid ointment, antihistaminic drug [5], and intravenous corticosteroid [4,5]. In our case, the patient showed erythroderma, and we needed oral prednisolone. To date, there are no reports of such the serious case of childhood AGEP.

The main differentiation diagnosis is that of generalized pustular psoriasis (GPP). It is often difficult to distinguish both diseases by eruption and histopathology. It is necessary to pay attention to recurrence in long-term clinical progress to distinguish between both diseases, as AGEP only rarely recurs, but GPP recurs many times. In pediatric cases, the differentiation from Kawasaki disease is also necessary, because Kawasaki disease rarely presents with skin rash similar to AGEP, which manifests as an erythematous pustular eruption. Although rare, we should bear in mind that AGEP can occur even in children.

Consent

The examination of the patient was conducted according to the Declaration of Helsinki principles.

REFERENCES

1. Sidoroff A, Halevy S, Bavinck JN, Vaillant L, Roujeau JC. Acute generalized exanthematous pustulosis (AGEP): a clinical reaction pattern. J Cutan Pathol. 2001;28:113-9.
2. Davidovici B, Dodiuk-Gad R, Rozenman D, Halevy S; Israeli RegiSCAR Network. Profile of acute generalized exanthematous pustulosis in Israel during 2002-2005: results of the RegiSCAR Study. Isr Med Assoc J. 2008;10:410-2.
3. Meadows KP, Egan CA, Vanderhooft S. Acute generalized exanthematous pustulosis (AGEP), an uncommon condition in children: case report and review of the literature. Pediatr Dermatol. 2000;17:399-402.
4. Miteva L, Kadurina M, Schwartz RA. Childhood acute generalized exanthematous pustulosis induced by oral ketoconazole. Acta Dermatovenerol Croat. 2010;18:267-70.
5. Riten K, Shahina Q, Jeannette J, Palma-Diaz MF. A severe case of acute generalized exanthematous pustulosis (AGEP) in a child after the administration of amoxicillin-clavulanic acid: brief report. Pediatr Dermatol. 2009;26:623-5.

Source of Support: Nil, **Conflict of Interest:** None declared.

Letter to the Editor

Palmoplantar pustulosis: Oral bacteria as a causative factor and ozone as an effective therapeutic means?

Yasuhiro Horiuchi

Division of Dermatology, Tsuruse Orthopedic Clinic, Saitama, Japan

Corresponding author: Dr. Yasuhiro Horiuchi, E-mail: tshoriuchi15@gmail.com

Sir,

In recent years, reports on bacteria that cause palmoplantar pustulosis (PPP) [1] have been accumulating [2,3]. Reliable means of treating PPP have yet to be adequately established. Although the complete removal of dental plaques and calculus by mechanical debridement may be difficult on occasions, periodontal therapy [3] for PPP patients has been reported to improve the skin lesions remarkably, suggesting the involvement of bacteria in PPP.

A male PPP patient aged 49 was presented to the clinic. He exhibited scaly erythemas, including several vesiculopustules on both soles and/or palms, but without extra-palmoplantar lesions and systemic symptoms such as joint pain, occurring in the past 2 years. Additionally, he had dental caries and gingivitis and was maintained on topical vitamin D analogues and steroid ointments for over 6 months. However, these treatments were minimally effective. At the exacerbated stage of his disease, antibiotics (Roxithromycin) were also administered for 5 months and skin lesions were alleviated, but did not heal completely. As he had previously worked for a company dealing with ozone gas-generating equipment and due to the antimicrobial activity of ozone [4], I explained the therapeutic possibility of ozone to him. Subsequently, he offered to perform the ozone method by himself, and had carried out the treatment by washing the inside of the oral cavity with ozone a couple of minutes every day at the company. Following this oral washing with ozone for about 3 months, his skin lesions nearly completely resolved. It is notable that even after stopping the ozone treatment at about 6 months, there has been no recurrence of this disease for more than 8 years.

These accumulated findings, including the author's experiment and related literature [2,3], may support the fact that oral bacteria can be a potential cause of PPP. Ozone (O_3) [4] exhibits a strong sterilizing activity which can kill bacteria, fungi, and viruses mechanically. Recently, the ozone nano-bubble (ONB) water (NAGA Co.,Ltd. Japan) [4], which is treated with nano-sized ozone gas, has been made available, and reveals strong antiseptic effects by which periodontal pathogens are eradicated within approximately 30s of exposure. Clinical trials in dentistry with ONB water [5] as an adjunctive antiseptic for treating periodontitis have begun. Therefore, ozone shows promising potential as a treatment for PPP. I expect that the cause of this disease could be periodontopathic bacteria and that a reliable and safer treatment method is established that includes ozone.

Acknowledgements

Ozone treatment in this case was performed at the patient's own discretion.

Consent

The examination of the patient was conducted according to the Declaration of Helsinki principles.

How to cite this article: Horiuchi Y. Palmoplantar pustulosis: Oral bacteria as a causative factor and ozone as an effective therapeutic means?. Our Dermatol Online. 2019;10(4):398-399.

Submission: 10.04.2019; **Acceptance:** 18.06.2019

DOI:10.7241/ourd.20194.25

REFERENCES

1. Brunasso G, Massone C. Palmoplantar pustulosis: Epidemiology, clinical features, and diagnosis. UpToDate 2015 [open access]
2. Kikuchi N, YamamotoT. Dental infection as a triggering factor for palmoplantar pustulosis. Acta Derm Venereol. 2013;93:721-2.
3. Murai O, Suwabe K, Ohkawa Y, Sasaki D, Yaegashi T. Palmoplantar pustulosis and periodontal therapy. Nihon Shishubyo Gakkai Kaishi (J Jap Society of Periodontol). 2018; 60:131-8.
4. Hayakumo S, Arakawa S, Takahashi M, Kondo K, Mano Y, Izumi Y. Effects of ozone nano-bubble water on periodontopathic bacteria and oral cells- *in vitro* studies. Sci Tech Adv Mater. 2014;15:055003.
5. Hayakumo S, Arakawa S, Mano Y, Izumi Y. Clinical and microbiological effects of ozone nano-bubble water irrigation as an adjunct to mechanical subgingival debridement in periodontitis patients in a randomized controlled trial. Clin Oral Investig. 2013; 17:379-88.

Source of Support: Nil, **Conflict of Interest:** None declared.

Letter to the Editor

Guttate psoriasis

Amina Lamouaffaq, Salim Gallouj, Hanane Baybay, Fatima Zahra Mernissi

Department of Dermatology, University Hospital Hassan II, Fez, Morocco

Corresponding author: Dr. Amina Lamouaffaq, E-mail: a.lamouaffaq@gmail.com

Sir.,

A 13-year-old child, with no pathological history, who presents for 3 years multiple small lesions erythemato-squamous dispersed all over the body, itchy, evolving by push-remission, with worsening winter. Clinical examination revealed multiple erythematous papules, about 5 mm in diameter, with thick whitish scales, at the trunk, back, the elbows and the members (Figs. 1 - 2), with Auspitz sign (Figs. 3a and 3b). The diagnosis of psoriasis gouttata was retained and the child was treated with dermocorticoides and emollient with good improvement after 2 months.

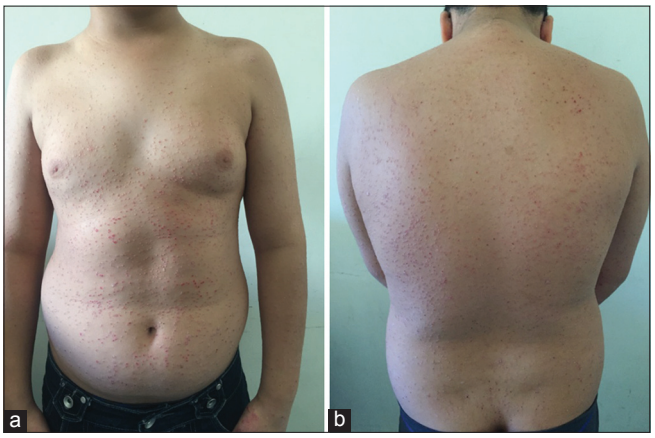

Figure 1: (a and b) Multiple erythematous papules, about 5 mm in diameter, with thick whitish scales, at the trunk and back.

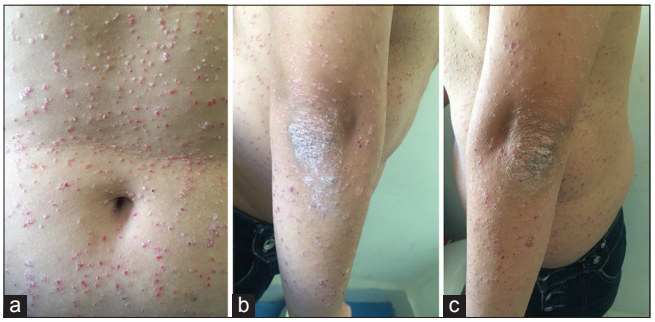

Figure 2: (a-c) Multiple erythematous papules, about 5 mm in diameter, with thick whitish scales, at the trunk and elbows.

Psoriasis is a non-contagious inflammatory disease, predominantly cutaneous, which evolves with exacerbations towards a chronicity. Its prevalence is 1.5-2%. It starts before age 40 in 75% of patients and has 2 peak incidence at 15-25 years and 50-60 years. The etiology is unknown, although it appears to be related to the immune system and environmental factors in people with genetic susceptibility [1,2]. There are several factors that trigger outbreaks of psoriasis, such as physical trauma, bacterial infections (due to the production of superantigens), viral infections, stress and medications [2]. In the case of physical trauma, the phenomenon was recognized by Koebner, in 1872, observed especially in patients who develop the disease at early ages, and has a torpid course. This phenomenon occurs in 20% of cases, and can be seen in other diseases, such as lichen planus, lupus erythematosus or sarcoidosis [3]. The morphology of the lesions is characterized by the presence of homogeneous erythematous plaques covered with scales, Auspitz sign (after the scratching of the lesions appear hemorrhagic spots on the erythematous surface) and Koebner phenomenon [2]. There are different clinical patterns of psoriasis: in plaques (the most frequent), drops or guttate, erythrodermic, pustular and ungueal. Psoriasis guttata predominantly affects children and adolescents, and there are multiple papular lesions with scales of 0.5-1.5 cm, often after a streptococcal infection of the upper respiratory tract, despite the correct antibiotic treatment. Its diagnosis is mainly clinical. The biopsy is performed when the clinical diagnosis offers doubts. In the differential diagnosis should take into account diseases such as pityriasis rosea, lichen planus, secondary syphilis and seborrheic dermatitis. Currently there is no curative treatment, this is

How to cite this article: Lamouaffaq A, Gallouj S, Baybay H, Mernissi FZ. Guttate psoriasis. Our Dermatol Online. 2019;10(4):400-401.
Submission: 27.11.2018; **Acceptance:** 27.01.2019
DOI: 10.7241/ourd.20194.26

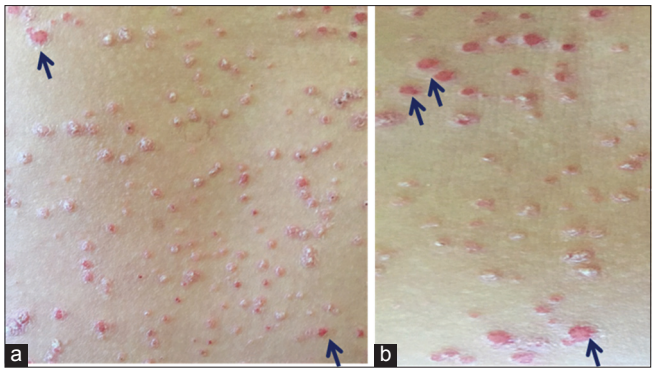

Figure 3: (a and b) Auspitz sign (after the scratching of the lesions appear hemorrhagic spots on the erythematous surface).

aimed at clinical improvement and the decrease in severity. It can be: topical, systemic and phototherapy. The treatment must be individualized according to the severity, the extension, the benefit-risk profile, the patient's preferences and their response. Emollients will be used for preventive and maintenance treatment; topical treatment in mild forms, avoiding prolonged use of corticosteroids. The combination of vitamin D analogues with corticosteroids is more effective than any of them in monotherapy and is considered the treatment of choice in primary care [1,2].

Consent

The examination of the patient was conducted according to the Declaration of Helsinki principles.

REFERENCES

1. Martínez Luya AD, Garcíab RP, Artuñedo AP. Psoriasis guttata. FMC. 2014;21:252-3.
2. Hernández IM, Ruzafa AL, Cavero SC. Psoriasis guttata. FMC. 2007;14:195-8.
3. Ueki H. Koebner phenomenon in lupus erythematosus with special consideration of clinical findings. Autoimmun Rev. 2005;4:219-23.

Source of Support: Nil, **Conflict of Interest:** None declared.

Letter to the Editor

Annular lichen planus: clinical and dermoscopic features

Aicha Nassiri[1], Niema Aqil[1], Sara Elloudi[1], Hanane Baybay[1], Fatima Zahra Mernissi[1], Omar Amrani[2], Mustapha Ahsaini[2], Alaoui Nabil[2], Mohamed Fadl Tazi[2], Moulay El Hassan Farih[2]

[1]Department of Dermatology, Hassan II University Hospital Center, Fes, Morocco, [2]Department of Urology, Hassan II University Hospital Center, Fes, Morocco

Corresponding author: Dr. Aicha Nassiri, E-mail: aichanassiri6@gmail.com

Sir,

Annular lichen planus (ALP) is a long-recognized clinical variant of lichen planus, but is often considered uncommon in occurrence. The typical distribution and presentation of this variant have not been well described.

We sought to better define the sites affected and clinical characteristics of the annular variant of lichen planus, along with the age and race of patients affected with this disorder.

A 34-year-old man visited our department for evaluation of a three-month, mildly pruritic eruption on the genital area. Clinical examination violaceous plaques of annular morphology with central atrophyon scrotum (Fig. 1). Application of dermoscopy revealed white annular lines (the so-called Wickham striae) were dermoscopically evident, along with dotted and short linear vessels and yellow scales (Fig. 2). Since the dermoscopic presence of Wickham striae is considered highly specific of LP, the dermoscopic findings prompted us to perform a biopsy for histopathologic assessment. Histopathology, revealed hyperkeratosis, dense hypergranulosis, vacuolar degeneration of basal cell keratinocytes, band-like lymphocytic infiltration in the upper dermis, as well as presence of colloid bodies, justifying the diagnosis of LP.

Dermoscopy is a non-invasive tool that is widely recognized and used in the diagnosis of pigmented and non-pigmented skin tumors [1,2]. In recent years,

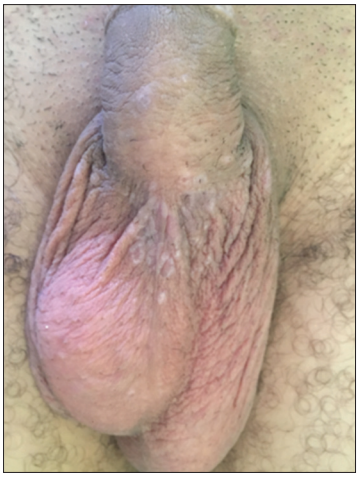

Figure 1: Violaceous plaques of annular morphology with central atrophyon scrotum.

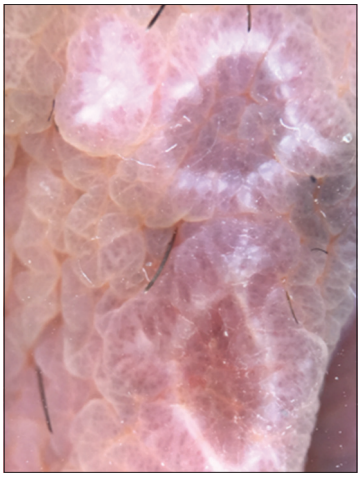

Figure 2: Annular Wickham striae.

How to cite this article: Nassiri A, Aqil N, Elloudi S, Baybay H, Mernissi FZ, Amrani O, Ahsaini M, Nabil A, Tazi MF, El Hassan Farih M. Annular lichen planus: clinical and dermoscopic features. Our Dermatol Online. 2019;10(4):402-403.

Submission: 19.01.2019; **Acceptance:** 10.04.2019

DOI:10.7241/ourd.20194.27

dermoscopy has been used for other dermatologic diseases including psoriasis, lichen planus, alopecia, and skin infestations [1,2]. Lichen planus (LP) is an acute or chronic inflammatory skin disorder characterized by discrete, violaceous, polygonal papules [2,3]. Though the diagnosis of LP can be made clinically, it can sometimes be challenging and histopathological examination is needed. Dermoscopic examination may be helpful in these settings to aid the diagnosis. In this study, we aimed to categorize the dermoscopic images of LP patients before and after treatment.

Wickham striae is commonly seen on dermoscopic examination in CLP lesions and it corresponds to hypergranulosis histologically [3-6]. WS disappears after treatment, suggesting that we can use it as an activation marker in LP lesions.

Wickham striae is classically seen as white crossing lines on dermoscopic evaluation and defined as "reticular pattern WS" [3,5].

In the current case, circular and radial streaming Wickham striae patterns were detected similar to the Tan et al. study. We believe that dermoscopic evaluation can be useful both in the diagnosis and follow up of LP.

ALP commonly involves the male genitalia but also has a predilection for intertriginous areas such as the axilla and groin folds. Eruptions typically consist of a few lesions localized to one or a few sites. Distal aspects of the extremities, and less commonly the trunk, may also be involved. ALP is a subtype of lichen planus that may be more common than is reflected in the literature.

Consent

The examination of the patient was conducted according to the Declaration of Helsinki principles.

REFERENCES

1. Lallas A, Kyrgidis A, Tzellos TG, Apalla Z, Karakyriou E, Karatolias A, et al. Accuracy of dermoscopic criteria for the diagnosis of psoriasis, dermatitis, lichen planus and pityriasis rosea. Br J Dermatol 2012;166:1198-205.
2. Zalaudek I, Argenziano G. Dermoscopy subpatterns of inflammatory skin disorders. Arch Dermatol. 2006;142:808.
3. Vazquez-Lopez F, Palacios-Garcia L, Gomez-Diez S, Argenziano G. Dermoscopy for discriminating between lichenoid sarcoidosis and lichen planus. Arch Dermatol. 2011;147:1130.
4. Gungor S, Topal IO, Erdogan S, Ozcan D. Classical lichen planus and lichen planus pigmentosus inversus overlap with dermoscopıc features. Our Dermatol Online. 2014;5:42-4.
5. Vázquez-López F, Gómez-Díez S, Sánchez J, Pérez-Oliva N. Dermoscopy of active lichen planus. Arch Dermatol. 2007;143:1092.
6. Vázquez-López F, Vidal AM, Zalaudek I. Dermoscopic subpatterns of ashy dermatosis related to lichen planus. Arch Dermatol. 2010; 146:110.

Source of Support: Nil, **Conflict of Interest:** None declared.

Letter to the Editor

Lichen planus pigmentosus

Ouiame El Jouari, Ghita Senhaji, Salim Gallouj, Hanane Baybay, Fatima Zahra Mernissi

Department of Dermatology, University Hospital Hassan II, Fez, Morocco

Corresponding author: Dr. Ouiame El Jouari, E-mail: eljouariouiame@gmail.com

Sir,

Lichen planus pigmentosus is considered a rare variant of lichen planus. It occurs in both sexes but shows a female preponderance. It is characterized by acquired dark brown to gray macular pigmentation located on sun - exposed areas. The dermoscopy and histology help to confirm the diagnosis. It is a disease which is basically recalcitrant to treatment and therapies attempted in this disorder are quite ineffective.

A 54-year-old dark-skinned postmenopausal woman presented with 3 years' history of itchy pigmented lesion of the face and lower limbs. On examination, large pigmented cupboards of the face and neckline (Fig. 1), as well as, multiple well-defined dark brown plates of varying size located on the legs (Fig. 2), were observed. Examination of the mucous membranes, nails and scalp was normal. The pull test was negative. Dermoscopical examination objectified multiples rosettes, whitish scales, and brown perifollicular hyperpigmentation (Fig. 3). A skin biopsy was performed. The histological examination showed an atrophic epidermis with hypergranulosis, band-like lymphocytic infiltrate of the upper dermis with abundant colloid bodies, and marked pigmentary incontinence. These findings were suggestive of lichen plan pigmentosus (Fig. 4). The patient was treated by topical steroids, depigmenting cream, associated to hydroxychloroquine 400 mg/day and strict photoprotection. At follow-up visits, the pigmented lesions became lighter after 9 months and the decline is 12 months.

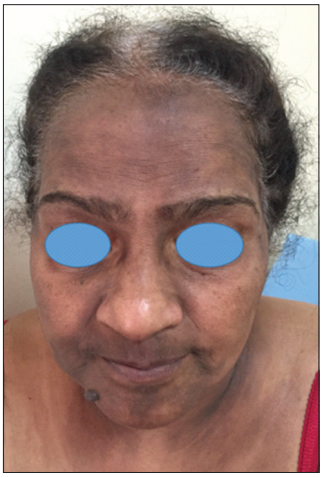

Figure 1: Large pigmented cupboards of the face and neckline.

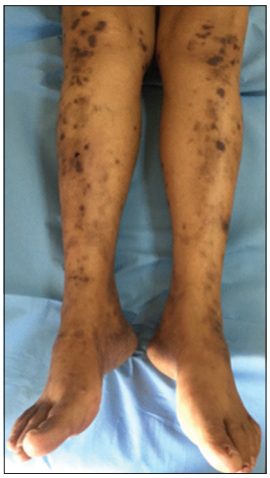

Figure 2: Multiple dark brown plaques of the legs.

Lichen planus pigmentosus is considered a rare variant of lichen planus [1]. It is essentially a disease of the adult starting insidiously after the age of 30. It occurs in both sexes but shows a female preponderance. It has been reported to occur predominantly in people with darker skin [2]. Pathogenesis represented by an altered cellular immune response mediated by T lymphocytes, in which CD8+ T lymphocytes recognize and attack epidermal keratinocytes, causing intense pigmentary incontinence. It is characterized by acquired dark brown to gray macular pigmentation located on sun- exposed areas of the face, neck, and flexures, commonly found in dark-skinned patients [1]. The dermoscopy

How to cite this article: El Jouari O, Senhaji G, Gallouj S, Baybay H, Mernissi FZ. Lichen planus pigmentosus. Our Dermatol Online. 2019;10(4):404-405.
Submission: 16.10.2018; **Acceptance:** 04.12.2018
DOI: 10.7241/ourd.20194.28



Figure 3: Dermoscopy showing rosettes, hyperkeratosis, and blue-grey perifollicular hyperpigmentation.

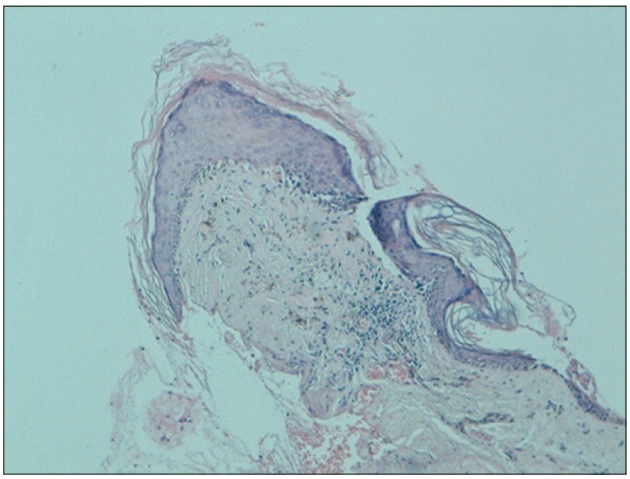

Figure 4: Histopathologic findings: focal interface dermatitis with superficial dermal melanosis and pigmentary incontinence.

of lichen plan pigmentosus can reveal reduction of the follicular openings, follicular hyperkeratosis, keratotic plugs, perifollicular erythema, white dots, interfollicular vessels with single loops, arborizing vessels and pigment network. Blue-grey structures in an annular or speckled pattern can also be found [3]. Erythema dyschromicum perstans is considered as the principal differential diagnosis of lichen plan pigmentosus. Other differentials are fixed drug eruption, macular amyloidosis, urticaria-pigmentosa, tar melanosis, frictional melanosis, berloque dermatitis, pigmented cosmetic dermatitis (Reihl's melanosis), postinflammatory hyperpigmentation, and idiopathic eruptive macular pigmentation and hyperpigmentation due to drugs and heavy metals [4]. Moreover, it may be associated with other disorders such as hepatitis C virus-induced liver disease, endocrinopathies, and autoimmune diseases as well as other variants of lichen planus and its sequelae [5]. Histopathology inclue perifollicular hyperkeratosis, atrophy with hydropic or vacuolar degeneration of the basal layer of the epidermis and scarce lymphohistiocytic or lichenoid infiltrates along the dermis, with pigmentary incontinence and the presence of melanophages [6]. Lichen plan pigmentosus is a disease which is basically recalcitrant to treatment and therapies attempted in this disorder are quite ineffective [4]. The management includes the use of topical medications such as steroids, immunomodulators, keratolytics, hydroquinone with or without retinoic acid, azelaic acid, kojic acid, glycolic acid, vitamin A, aqueous solution of 10% dimethyl-sulfoxide, among others, with variable results. There are favorable recent reports of the use of Nd: YAG laser, intense pulsed light and dermabrasion [3].

Consent

The examination of the patient was conducted according to the Declaration of Helsinki principles.

REFERENCES

1. Robles-Méndez JC, Rizo-Frías P, Herz-Ruelas ME, Pandya AG, Ocampo Candiani J. Lichen planus pigmentosus and its variants: review and update. Int J Dermatol. 2018;57:505–14.
2. Kanwar AJ, Dogra S, Handa S, Parsad D, Radotra BD. A study of 124 Indian patients with lichen planus pigmentosus. Clin Exp Dermatol. 2003;28:481–5.
3. Mulinari-Brenner FA, Guilherme MR, Peretti MC, Werner B. Frontal fibrosing alopecia and lichen planus pigmentosus: diagnosis and therapeutic challenge. An Bras Dermatol. 2017;92(5 Suppl 1):79-81.
4. Ghosh A, Coondoo A. Lichen planus pigmentosus. Indian J Dermatol. 2016;61:482–6.
5. Al-Mutairi N, El-Khalawany M. Clinicopathological characteristics of lichen planus pigmentosus and its response to tacrolimus ointment: an open label, non-randomized, prospective study. J Eur Acad Dermatol Venereol. 2010;24:535–40.
6. Das A, Mishra V, Podder I, Kumar P, Das D, Das NK. Linear lichen planus pigmentosus: A rare entity with an illusory presentation. Pigment Int. 2014;1:100-2.

Source of Support: Nil, **Conflict of Interest:** None declared.

Letter to the Editor

Phytocontact dermatitis due to Mentha rotundifolia: A case report

Ouiam El Anzi, Asmae Sqalli, Safae Maouni, Karima Senouci, Badredine Hassam

Department of Dermatology-Venereology, Ibn Sina University Hospital, Mohammed V University, Rabat, Morocco

Corresponding author: Dr. Ouiam El Anzi, E-mail: elanzi.ouiam@gmail.com

Sir.,

Phytodermatoses are skin lesions secondary to prolonged contact with bound herbs. Many plants are represented liable for this kind of incident [1].

We present a case of phytocontact dermatitis associated with the use of a plant mimicking burn injury.

A 38-year-old female patient, without pathological history, presented to the consultation with complaints of vesiculous lesions at the lumber region (Fig. 1). The questioning found the application 2 days ago of a poultice for 6 hours containing the "Mentha rotundifolia" to treat low back pain.

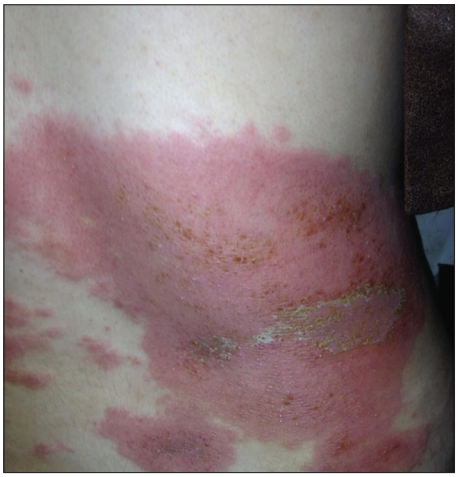

Figure 1: Vesiculo-erythematous lesions at the lumber region.

Dermatological examination revealed a second degree burn. The care provided helped a favorable evolution in few days.

Many modern drugs owe their origin to plant-based complementary medicine, and there has been an upsurge of interest in the potential use of medicinal plants for the treatment of a wide range of disorders [2]. In Morocco, it is well known that many alternative herbal remedies are used for different indications, especially for rheumatological joint pain.

The adverse effects of plants on skin are typically manifest via 3 main mechanisms: irritant, phototoxic, and hypersensitivity reactions [3].

Mentha rotundifolia (Fig. 2) also called Mentha suaveolens or apple mint belongs to Lamiaceae family is found along rivers in plains and mountains.

Figure 2: Mentha rotundifolia.

It is a perennial plant that blooms in spring and summer under the semi-arid cold and subhumid Mediterranean bioclimate [4].

How to cite this article: El Anzi O, Sqalli A, Maouni S, Senouci K, Hassam B. Phytocontact dermatitis due to Mentha rotundifolia: A case report. Our Dermatol Online. 2019;10(4):406-407.

Submission: 30.10.2018; **Acceptance:** 06.01.2019

DOI:10.7241/ourd.20194.29

Features oblong to ovate light green leave and terminal spikes of small pink to white flowers in summer.

Leaves have a fruity fragrance and taste.

It is gently used in herbal medicine for her virtues tonic, antispasmodic, antipyretic, stimulating and even for culinary purposes.

In our case, use for antalgic purposes has caused a chemical burn of the second degree. There is a phytodermatose described only once to our knowledge.

Although plant poultices applied to the skin show positive effects on many rheumatic and dermatological diseases, they even have several adverse effects [5]. We believe that benefiting from modern medicine is the correct approach rather than attempting alternative treatment methods, whose therapeutic effects have not been proven yet by scientific studies.

Consent

The examination of the patient was conducted according to the Declaration of Helsinki principles.

REFERENCES

1. El Makrini N, Hassam B. Artemisia absinthium: burning plant! Pan Afr Med J. 2016;23:10.
2. Mantle D, Gok MA, Lennard TWC. Adverse and beneficial effects of plant extracts on skin and skin disorders. Adverse Drug React Toxicol Rev. 2001:20:89–103.
3. Polat M, Oztas P, Yalcin B, Tamer E, Gur G, Alli N. Contact dermatitis due to Allivum sativum and Ranunculus illyricus: two cases. Contact Dermatitis. 2007;57:279-80.
4. Benhiba H, Hassam B. [Phytophotodermatitis due to Mentha rotundifolia]. Pan Afr Med J. 2014;18:192.
5. Akbulut S, Semur H, Kose O, Ozhasenekler A, Celiktas M, Basbug M, et al. Phytocontact dermatitis due to Ranunculus arvensis mimicking burn injury: report of three cases and literature review. Int J Emerg Med. 2011;4:7.

Source of Support: Nil, **Conflict of Interest:** None declared.

Letter to the Editor

Umbilical squamous papilloma: A case report

Mehmet Eren Yuksel[1], Funda Tamer[2], Guler Senyildiz Hasturk[3]

[1]Aksaray University School of Medicine, Department of General Surgery, Aksaray, Turkey, [2]Ufuk University School of Medicine, Department of Dermatology, Ankara, Turkey, [3]Aksaray University Training and Research Hospital, Department of Pathology, Aksaray, Turkey

Corresponding author: Dr. Funda Tamer, E-mail: fundatmr@yahoo.com

Sir,

A 21-year-old Caucasian male presented with a 2-year history of an asymptomatic mass in the umbilicus. The patient stated that the lesion increased in size gradually. Therefore, the patient was complaining of cosmetic disfigurement. However, he did not receive any treatment previously. The past medical history and family history were both unremarkable. The patient denied any trauma to the umbilical region.

The physical examination of the patient revealed a skin colored pedunculated plaque with verrucous surface in the umbilicus measuring 1.5x1 cm in size (Fig. 1). The lesion was removed surgically under local anesthesia to reach a definitive diagnosis. Histopathological evaluation of the specimen revealed multiple finger-like projections supported by central fibrovascular cores which were covered by a stratified squamous epithelium. The longest diameter of the polipoid lesion was 1.5 cm. However, the diameter of the basis of the lesion was measured 0.4x0.3 cm. No evidence of malignancy or koilocytic changes in the epithelium were observed. The diagnosis of squamous papilloma was made based on clinical and histopathological features (Fig. 2).

Squamous papilloma is a benign neoplastic proliferation with finger like morphology which usually affects skin, cervix, breast duct, respiratory tract and gastrointestinal tract. Human papilloma virus (HPV) infection plays role in the etiology of squamous papilloma [1].

It has been suggested that stem cell population of the hair follicle which contains keratin 15 might contribute to the development of squamous papilloma. Li et al. investigated the role of keratin 15 + hair follicle cells in the etiopathogenesis of cutaneous papillomas in the *Krt1-15CrePR1;R26R* transgenic mouse. Li et al. reported that keratin 15 expressing cells contributed to papillomas following 20 weeks of promotion, and persistence of keratin 15 progeny in papillomas [2].

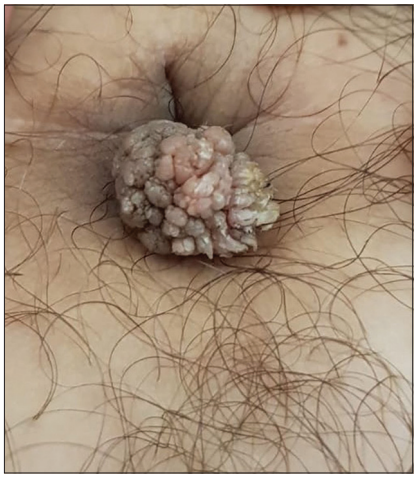

Figure 1: Skin colored plaque with verrucous surface in the umbilicus.

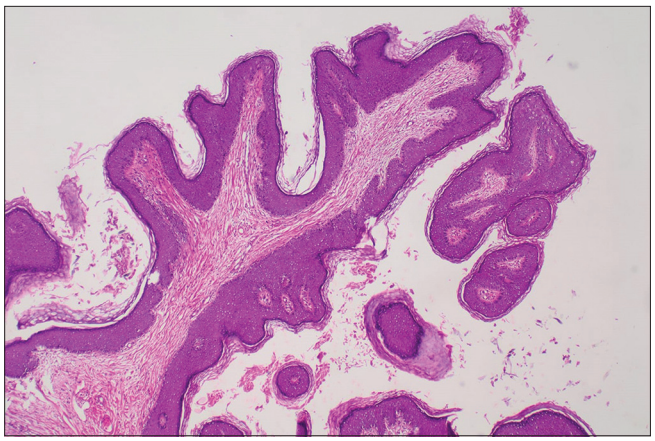

Figure 2: Histopathological view of the squamous papilloma. Multiple finger-like projections supported by central fibrovascular cores and covered by a stratified squamous epithelium. No koilocytic changes were observed (H&Ex40).

How to cite this article: Yuksel ME, Tamer F, Senyildiz Hasturk G. Umbilical squamous papilloma: A case report. Our Dermatol Online. 2019;10(4):408-409.
Submission: 16.11.2018; **Acceptance:** 19.01.2019
DOI:10.7241/ourd.20194.30

Terada reported a 46-year-old female patient with a squamous papilloma measuring 13 mm in size on the scalp, arising from an epidermal cyst. Squamous papilloma showed intracystic growth with fibrovascular cores. The tumor had benign character, and thus no atypia was observed. Immunohistochemical evaluation showed no association between squamous papilloma and HPV. Terada reported that squamous papilloma could arise in epidermal cysts. Therefore, differential diagnosis of squamous papilloma from trichilemmal tumor and proliferating trichilemmal cyst should be made [3].

Squamous papilloma of the umbilicus is a rare condition. Vijayabhaskar et al. reported a 47-year-old female patient with microinvasive squamous cell carcinoma of the cervix and benign squamous papilloma in the umbilicus at the same time [4]. Nathan reported coexistence of squamous papilloma arising from the umbilicus and genital warts. Nathan suggested possible role of autoinoculation from genital region to umbilicus during bathing [5].

Verrucous carcinoma is a differentiated type of squamous cell carcinoma which presents as a slow growing warty papule. Differential diagnosis of squamous papilloma from verrucous carcinoma is crucial as the verrucous carcinoma can lead to local invasion and metastasis. The risk of misdiagnosis increases in laryngeal lesions and in cases when the biopsy specimen is small [6]. In addition, Kim et al. reported a 20-year-old female patient with condyloma lata in the umbilicus, perineum and mucous patches on the lips. Even it is rare, syphilis should be kept in mind in the differential diagnosis of verrucous nodules in the umbilicus [7].

In conclusion, the patient presented hereby had a lesion diagnosed as squamous papilloma in the umbilicus which was an unusual localization for squamous papilloma. Possible initiating factors such as HPV infection, chronic irritation and rare diseases such as verrucous carcinoma and syphilis in the differential diagnosis of squamous papilloma are reminded through this case report.

Consent

The examination of the patient was conducted according to the Declaration of Helsinki principles.

REFERENCES

1. Goyal E, Gupta P, Dokania A, Rizvi Y. Squamous papilloma over lid margin: An uncommon presentation. Int J Adv Integ Med Scien. 2016; 1:128-30.
2. Li S, Park H, Trempus CS, Gordon D, Liu Y, Cotsarelis G, et al. A keratin 15 containing stem cell population from the hair follicle contributes to squamous papilloma development in the mouse. Mol Carcinog. 2013;52:751-9.
3. Terada T. Squamous papilloma and squamous cell carcinoma arising from epidermal cyst: report of 4 cases. Human Pathology Case Reports. 2015;2:55-7.
4. Vijayabhaskar R, Sadasivam OL, Kirushnakumar KS. Papilloma of the umbilicus. Indian J Surg. 2014;76:329-30.
5. Nathan M. Umbilical warts: a new entity? Genitourin Med. 1994; 70:49-50.
6. Cooper JR, Hellquist HB, Michaels L. Image analysis in the discrimination of verrucous carcinoma and squamous papilloma. J Pathol. 1992;166:383-7.
7. Kim JS, Kang MS, Sagong C, Ko JY, Yu HJ. An unusual extensive secondary syphilis: condyloma lata on the umbilicus and perineum and mucous patches on the lips. Clin Exp Dermatol. 2009; 34:299-301.

Source of Support: Nil, **Conflict of Interest:** None declared.

Case Report

Herpes zoster in a healthy 24-year old final year medical student one month before final examinations

Rishi Agrawal

Imperial College London, South Kensington, London, UK

Corresponding author: Dr. Rishi Agrawal, E-mail: Rishi.agrawal@doctors.org.uk

ABSTRACT:

Herpes zoster occurs after the varicella zoster virus reactivates and typically effects the elderly and those who are immunocompromised. Stressful and negative life events have also been associated with outbreaks of herpes zoster. However, herpes zoster that occurs in apparently healthy immunocompetent adults is relatively rare. We report a case of a healthy 24-year old male final year medical student, with no past medical or medication history, who developed herpes zoster two months before his final academic medical examinations.

Key words: Herpes zoster; Immunocompetent; Medical student; Stress; Academic examinations

INTRODUCTION

Herpes zoster (shingles) is a painful vesicular rash that occurs after the varicella zoster virus reactivates in the dorsal root ganglion of a sensory dermatome. An individual must have had a primary infection with varicella zoster (chickenpox) earlier in life in order to develop herpes zoster, which is typically seen in the elderly [1]. However, children and young adults with medical conditions that predispose towards immunosuppression may also develop herpes zoster [2], since any disease state or medication that compromises immunity has the potential to trigger latent viral reactivation. Herpes zoster that occurs in apparently healthy adults, with no history of chronic medical conditions, current illnesses or immunosuppressive medications, is rare [3]. This raises the possibility that other factors, besides the known medical causes of immunocompromise, may play a role in triggering herpes zoster.

Indeed, the stress induced by negative life events, such as bereavement, unemployment and divorce, has been associated with sporadic outbreaks of herpes zoster [4-6]. However, despite these associations with negative life events, there has yet to be a reported case of herpes zoster that is associated with the psychological stress of upcoming academic medical examinations.

CASE REPORT

A 24 year old male, with no past medical or surgical history, presented with a 1 week history of burning and extremely sensitive skin on his chest and back. Five days following the onset of his initial symptoms, a red rash appeared on his back. The patient reported no recent history of viral infection, flu-like symptoms or fever and takes no regular medications. He suffered from varicella zoster (chickenpox) at the age of 5. On social history, the patient drinks on average one unit of alcohol per week, has never smoked and has never used recreational drugs. He is a final year medical student and subjectively reports to be under a lot of stress because he is one month away from his final university medical examinations.

On examination, the patient outlined an area of painful skin that matches the distribution of the left T5 dermatome. Additionally, there are several well defined vesicles on an erythematous base in the distribution of the left dorsal T5 dermatome (Figs. 1a and 1b).

How to cite this article: Agrawal R. Herpes zoster in a healthy 24-year old final year medical student one month before final examinations. Our Dermatol Online. 2019;10(4):385-386.

Submission: 26.04.2019; **Acceptance:** 18.07.2019

DOI: 10.7241/ourd.20194.31

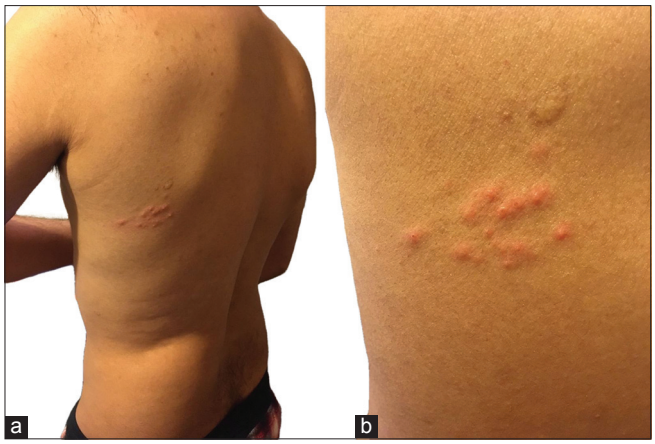

Figure 1: (a) The typical dermatomal rash of herpes zoster affecting the dorsal left T5 dermatome. (b) A higher magnification image showing many vesicles on an erythematous base.

A clinical diagnosis of herpes zoster was made in the urgent care centre and the patient was prescribed a 7-day course of acyclovir.

DISCUSSION

Herpes zoster (shingles) is most common in the elderly [1] and in the United Kingdom there has been a preventative vaccine available since 2013 for patients in their 70s. However, it can also occur in patients who are immunocompromised, either through a disease process or via medication [1]. Therefore the patient presented in this case report represents an unusual case of herpes zoster since he is a healthy 24 year old with no underlying medical conditions or any other known medical cause for immunosuppression.

This suggests that the stress induced by the patient's upcoming medical examinations may have played a role in causing a temporary state of immunocompromise, which allowed the varicella zoster virus to reactivate in the dorsal root ganglion of the left T5 dermatome. Indeed, psychological stress induced by negative life events has been associated with outbreaks of herpes zoster [4-6]. A popular mechanism involves the damaging affect of chronically high levels of endogenous glucocorticoids on the immune system. It is well recognised that high levels of cortisol can induce lymphocyte apoptosis [7,8], which can subsequently reduce the immunity to viruses.

CONCLUSION

This may be one of the first case reports presenting a patient with herpes zoster that is directly associated with the stress induced by upcoming medical examinations. This case report provides further evidence for the interplay between psychological stress, immunosuppression and herpes zoster.

ACKNOWLEDGEMENTS

The author would like to thank Elizabeth Colwell BSc MRes, Imperial College London, for taking the clinical photographs.

Consent

The examination of the patient was conducted according to the Declaration of Helsinki principles.

REFERENCES

1. Yoshikawa TT, Schmader K. Herpes zoster in older adults. Clinical Infectious Diseases. 2001;32:1481-6.
2. Ferreira JC, Marques HH, Ferriani MP, Gormezano NW, Terreri MT, Pereira RM, et al. Herpes zoster infection in childhood-onset systemic lupus erythematosus patients: a large multicenter study. Lupus. 2016;25:754-9.
3. Johnson BH, Palmer L, Gatwood J, Lenhart G, Kawai K, Acosta CJ. Annual incidence rates of herpes zoster among an immunocompetent population in the United States. BMC infectious diseases. 2015;15:502.
4. Lasserre A, Blaizeau F, Gorwood P, Bloch K, Chauvin P, Liard F, et al. Herpes zoster: family history and psychological stress-case-control study. J Clin Virol. 2012;55:153-7.
5. Schmader K, Studenski S, MacMillan J, Grufferman S, Cohen HJ. Are stressful life events risk factors for herpes zoster? J Am Geriatr Soc. 1990;38:1188-94.
6. Schmader K, George LK, Burchett BM, Hamilton JD, Pieper CF. Race and stress in the incidence of herpes zoster in older adults. J Am Geriatr Soc. 1998;46:973-7.
7. Smith LK, Cidlowski JA. Glucocorticoid-induced apoptosis of healthy and malignant lymphocytes. Prog Brain Res. 2010;182:1-30.
8. Wang Z, Rong YP, Malone MH, Davis MC, Zhong F, Distelhorst CW. Thioredoxin-interacting protein (txnip) is a glucocorticoid-regulated primary response gene involved in mediating glucocorticoid-induced apoptosis. Oncogene. 2006;25:1903-13.

Source of Support: Nil, **Conflict of Interest:** None declared.

Letter to the Editor

Krukenberg tumor in a patient treated with biologics for psoriasis

Anca Chiriac[1,2,3], Piotr Brzezinski[4,5]

[1]Apollonia University, Department o Physiology-Dermatology, Iasi, Romania, [2]Nicolina Medical Center, Departemt of dermatology, Iasi, Romania, [3]" P.Poni" Institute of Macromolecular Chemistry, Romanian, [4]Institute of Biology and Environmental Protection, Pomeranian Academy, Slupsk, Poland, [5]Department of Dermatology, Provincial Specialist Hospital in Slupsk, ul. Mickiewicza 12, 76-270 Ustka, Poland

Corresponding author: Prof. Anca Chiriac, E-mail: ancachiriac@yahoo.com

Sir,

Krukenberg tumor (KT) is, by definition, any ovarian metastatic carcinoma derived from a primary malignancy [1]. The name of the malignancy, that can create confusion in clinical practice, belongs to Friedrich Ernst Krukenberg who described a new form of ovarian cancer in 1896, which proved, to be metastatic, 6 years later [2].

It has been evidenced lately the origin of the KT could be, in most cases, gastric and colorectal cancers, but also other sites have been reported, such as breast, small intestine, lung, gallbladder and biliary ducts, urinary tract, pancreas, uterine cervix [2,3].

KT has been considered a rare type of ovarian malignancy, occurring in 1% -2% of patients, with a higher incidence in China, Korea and Japan, affecting females of all ages, but preferentially during pre-menopause period [1].

We report a case of 60-year-old female patient, who has been treated, for more than 10 years, with adalimumab for a severe plaque psoriasis and psoriatic arthritis, with close follow-up, every 6 months and good clinical evolution. Suddenly, in the absence of any previous symptoms, she was hospitalized in Emergency for abdominal and pelvic pain, bloating and anorexia. She was transferred to Oncology Department for investigations, computed tomography revealed large bilateral ovarian solid masses and huge ascites, associated with very high levels of serum CA-125. She died within hours after admission at the hospital, family did not accept necropsy. A diagnosis of KT was supposed.

Particularities of present case are the following: a menopause woman, treated with biologics for many years for psoriasis, evaluated carefully at every 6 months, who was diagnosed with KT.

Searching medical data base there is no report of KT diagnosed in a patient treated with biologics for psoriasis. Could it be a coincidence or more? Long-term cancer risks with anti-TNF therapies should be a concern for all physicians and any case should be reported.

Consent

The examination of the patient was conducted according to the Declaration of Helsinki principles.

REFERENCES

1. Qiu L, Yang T, Shan XH, Hu MB, Li Y. Metastatic factors for Krukenberg tumor: a clinical study on 102 cases. Med Oncol. 2011;28:1514-9.
2. Bennett JA, Oliva E. Pathology of the adnexal mass. Clin Obstet Gynecol. 2015;58:3-27.
3. Muthukrishnan S, Naganathbabu OL, Murugesan SD, Srinivasan UP, Amudhan A, Rajendran S. Krukenberg tumours from gastrointestinal cancers-analysis from a tertiary care centre in India.J Gastrointest Oncol. 2018;9:1164-7.

Source of Support: Nil, **Conflict of Interest:** None declared.

How to cite this article: Chiriac A, Piotr Brzezinski P. Krukenberg tumor in a patient treated with biologics for psoriasis. Our Dermatol Online. 2019;10(4):410.
Submission: 17.04.2019; **Acceptance:** 30.06.2019
DOI: 10.7241/ourd.20194.32

Letter to the Editor

Omphalolith: a rare umbilical concretion

Siham Mansouri, Sara Mai, Badr Hassam, Meriem Meziane

Dermatology Department, University Hospital Ibn Sina, Rabat Morocco

Corresponding author: Dr. Siham Mansouri, E-mail: siham-mnsr@hotmail.fr

Sir,

A 76-year-old woman was referred by her general physician to our dermatology department for the management of suspicious looking umbilical nodule of 10 years duration. She had no abdominal pain, weight loss, or fever. The patient did not give any history of passage of mucous, faces, or other discharge through the umbilicus. On exam she had a painful brownish-black, dry appearing mass of approximately 2 centimeters in length (Fig. 1) protruding from her umbilicus. There was no frank ulceration. The dermoscopic examination did not show a pigmented network or vascular patterns. It exhibited a dry crusted appearance. (Fig. 2). The remainder of the examination was unremarkable. Clinically, an omphalolith or umbilical concretion was suspected. It was easily removed with a warmed glycerin preparation. The histopathological examination of the specimen revealed concentric lamellae of keratin without evidence of any tumor.

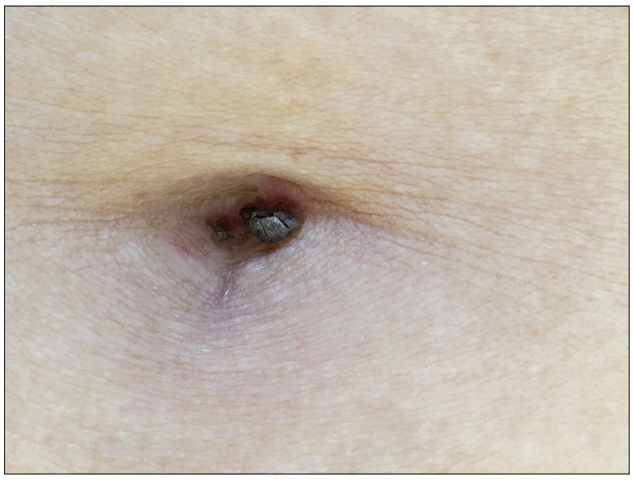

Figure 1: A painful brownish-black umbilical mass.

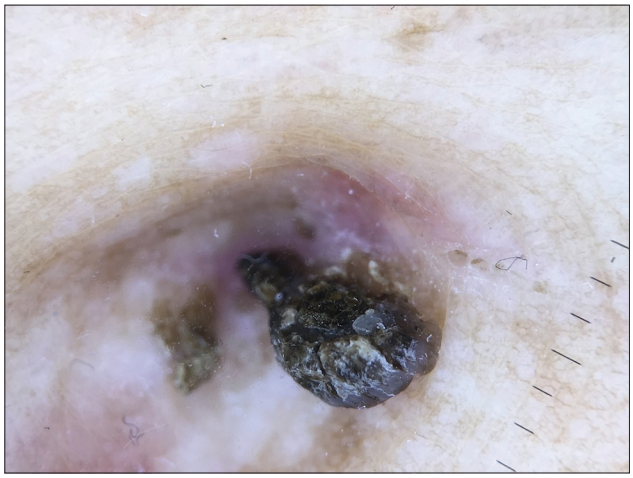

Figure 2: The dermoscopic examination exhibited a dry crusted appearance

Omphalolith is an uncommon entity under normal circumstances, generally asymptomatic, very few cases have been reported. It refers to sebum and keratin that have accumulated into a stone-like concretion in an umbilical cleft [1]. This calculi may remain undiagnosed for many years until revealed by secondary complication (infection or ulceration) [1,2]. Omphalolith generally presents with a firm, black umbilical mass that could be mistaken for other benign or malignant tumors of the umbilicus (melanoma, primary umbilical malignancy, umbilical metastasis, cholesteatoma, endometriosis…) [3,4], pushing for unnecessary and costly consultations, procedures and imaging studies [5]. Superficial parts of the omphalolith can appear dark brown or black, likely due to melanin and oxidation of lipids much like an open comedone [4]. Omphalolith is usually associated with bad hygiene, when the patient fails to clean a deep umbilical cleft enough to contain a significant concretion [3]. It can be removed by gentle manipulation or through adequate opening of umbilical foramen under local anesthesia to the periumbilical area.

Recognition of the diagnosis of omphalolith is important owing to the rarity of the condition. It's

How to cite this article: Siham Mansouri, Sara Mai, Badr Hassam, Meriem Meziane. Omphalolith: a rare umbilical concretion. Our Dermatol Online. 2019;10(4):411-412.

Submission: 13.02.2019; **Acceptance:** 04.05.2019

DOI: 10.7241/ourd.20194.33

crucial to differentiate it from other benign and malignant conditions of the umbilicus and to avoid unnecessary imaging and procedures.

Consent

The examination of the patient was conducted according to the Declaration of Helsinki principles.

REFERENCES

1. Ichiki Y, Kitajima Y. Omphalith. Clin Exp Dermatol. 2008;34:420–1.
2. Mihara K. Omphalolith: An umbilical concretion to recognize. J Gen Intern Med. 2016;31:1396.
3. Nittala P. Omphalolith/umbolith: CT and MR imaging appearances in two patients. Singapore Med J. 2009;50:745.
4. Sheehan D, Sarwat H, Vijayaraghavan G. Umbilical concretion. Radiol Case. 2011;5:25–31.
5. Kumar SKL, Reddy CO, Reddy K. Omphalolith. Indian J Surg. 2011;73:238-9.

Source of Support: Nil, **Conflict of Interest:** None declared.

Historical Article

Dermatology Eponyms – sign –Lexicon (V)

Piotr Brzeziński[1], Lorenzo Martini[1], Marta Stawczyk-Macieja[2]

[1]University of Siena, Department of Pharmaceutical Biotechnologies, Via A. Moro 2, 53100 Siena, Italy, [2]Department of Dermatology, Venereology and Allergology, Medical University of Gdańsk, Dębinki 7 St, Gdańsk 80-211, Poland

Corresponding author: Dr. Piotr Brzeziński, E-mail: brzezoo77@yahoo.com

ABSTRACT

Eponyms are used almost daily in the clinical practice of dermatology. And yet, information about the person behind the eponyms is difficult to find. Indeed, who is? What is this person's nationality? Is this person alive or dead? How can one find the paper in which this person first described the disease? Eponyms are used to describe not only disease, but also clinical signs, surgical procedures, staining techniques, pharmacological formulations, and even pieces of equipment. In this article we present the symptoms starting with (V) and other. The symptoms and their synonyms, and those who have described this symptom or phenomenon.

Key words: Eponyms; Skin diseases; Sign; Phenomenon

V- SIGN

Confluent macular violaceous erythema on the anterior neck and chest in patients of dermatomyositis is called "V" sign (Fig. 1) [1,2].

VACCINOID SIGN

A slight cutaneous reaction to vaccination in a person partially immune to small pox [3].

VAGABOND'S SIGN

1. Parasitic melanoderma; discoloration of the skin in persons of filthy habits, caused by the irritation of lice [4]. Also called Greenhow's sign 2. A pigmentary process from an itching disease like prurigo and pityriasis stimulating morbus Addisonii, particularly found in vagrants and tramps. Also called Vagrant's disease and sign.

EDWARD HEADLAM GREENHOW

English physician, 1814-1888 (Fig. 2). He studied medicine at Edinburgh and Montpelier. In 1855 he was appointed lecturer on public health at St. Thomas's Hospital. In 1875 he delivered the Croonian lectures at the Royal College of Physicians on Addison's disease. Greenhow wrote: 1. 'On Diphtheria,' 1860. 2. 'On Addison's Disease,' 1866. 3. 'On Chronic Bronchitis,' 1869. 4. 'Croonian Lectures on Addison's Disease,' 1875. He also prepared the following parliamentary reports: 'The different Proportions of Deaths from certain Diseases in different Districts in England and Wales,' 1858 [4,5].

VAGRANT'S SIGN

Also called Vagabond's sign.

VALLEY FEVER SIGN

Zoonotic fungal coccidioidomycosis [6].

VAMPIRE'S SIGN

Severe mutilating skin lesions caused by photosensitivity, neurological disruptions, liver pathology, and strange purple urine. These are indications of forms of porphyria. It is now suggested that Vlad Dracul the I5,h

How to cite this article: Brzeziński P, Martini L, Stawczyk-Macieja M. Dermatology Eponyms – sign –Lexicon (V). Our Dermatol Online. 2019;10(4):413-416.
Submission: 13.01.2019; **Acceptance:** 11.05.2019
DOI: 10.7241/ourd.20194.34

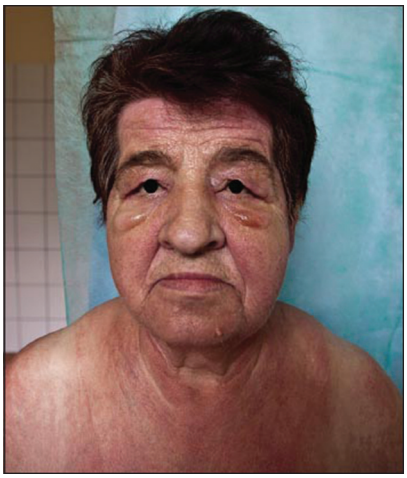

Figure 1: V- sign.

Figure 2: Edward Headlam Greenhow.

century slayer prince, also known as Vlad the Impaler suffered from hereditary porphyria. There is supporting evidence that some sufferers craved blood due to iron deficiency. Coupled with the fact that the disease can he manifested with painful cutaneous photosensitivity, allowing some victims to only come out after dark caused them to be sadly mistaken for yampires. Also called Dracula's sign [7].

VLAD DRACUL

Vlad III the Impaler. Prince of Wallachia, dynasty of Basarab. (1431–1476) (Fig. 3). It's best known for his resistance against the Ottoman Empire and its expansion. His postmortem moniker of "Impaler" originated in his killing opponents by impalement. In Turkish, he was known as "Kazikli Voyvoda" which means "Impaler Prince". Was born in Sighisoara, Transylvania (part of the Kingdom of Hungary at the time).

VERDIGRIS SIGN

Free flow of saliva, bluish or greenish vomited material, strong coppery taste. A sign of poisoning with copper salts [8]. Also known as Salivation sign.

VERONAL SIGN

Lips and finger-tips blue, drooping of eyelids, and usually loss of control of bladder and bowels. An indication of barbitonum poisoning [9]. Also known as Barbitonum sign.

VINCENT'S SIGN

A pupil which is miotic and responds to accommodation effort, however it does not respond to light [10-12]. Also known as Argyll Robertson's sign or pupil.

DOUGLAS MORAY COOPER LAMB ARGYLL ROBERTSON

Scotch ophthalmologist and surgeon, 1837-1909 (Fig. 4). After earning his degree in 1857 from the University of St Andrews, he went to Berlin to study under Albrecht von Graefe. Robertson spent most of his medical career in Edinburgh as an eye surgeon at the Edinburgh Royal Infirmary and teacher of ophthalmology at the University of Edinburgh. For a while he was honorary eye physician to Queen Victoria and King Edward VII. Robertson made several contributions in the field of ophthalmology; in 1863 he researched the effects on the eye made by physostigmine, an extract from the Calabar bean (Physostigma venenosum), which is found in tropical Africa. He correctly predicted that physostigmine would become very important in the treatment of eye disorders. He also described a symptom of neurosyphilis that affects the pupils of the eye, which is known today as Argyll Robertson pupils [10,11].

HENRI VINCENT

French physician, 1862-1950. His name is associated with Vincent's Disease or Vincent s Angina. It is also

widely known as Trench Mouth, due to an outbreak in soldiers in trenches during World War One. Borrelia vincentii used to be spread out worldwide, but is now mainly in countries that are not very developed [10,11].

VINCENT'S WAR SIGN

Painful, acute necrotizing ulcerative gingivitis [10-15]. Also known as ulceromembranous gingivitis, and Trench Mouth sign or ANUG sign.

VIOLET SWEAT SIGN

Chromidrosis, perspiration with a violet color. Similar sign: Lusitanus's sign [13], Chojnowski's sign [16], Bartholinus's sign [17].

Figure 3: Vlad Dracul.

Figure 4: Douglas Moray Cooper Lamb Argyll Robertson.

VOLCANO SIGN

It is descriptive term for the morphologic feature of Old World cutaneous leishmaniasis (Fig. 6) [18-20]. The lesion starts as a small nontender papule, which enlarges in size and ulcerates in the centre. The border of the crusted ulcer often has an erythematous rim and is called as "Volcano sign". Also known as oriental boil, cutaneous leishmaniasis, Delhi boil, old world leishmaniasis, oriental sore, tropical sore, oriental boil, Bagdad boil, Delhi sore, Bombay boil, deli fever, Biskra button, furunculus Orientalis, Jericho boil, Tashkent ulcer, herpes du nil, die Orientbeule, die Aleppobeule, orientbyld, pendsjabzweer, lupus endemicus, leishmaniasis furunculosa, Bombaybuil, Bassorabuil, Cochinzweer, Bagdadbuil, Asjbadkazweer, leishmaniasis tropica, Aleppobuil, bouton du Nil, φ?μα της Ανατολ?ς, fuma tis anatolis, (Saunders 1945, E.J. Marzinowsky and Bogbow 1904).

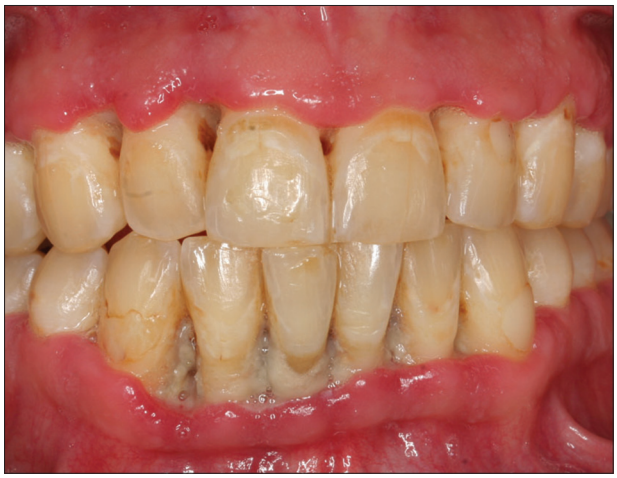

Figure 5: Vincent's War sign.

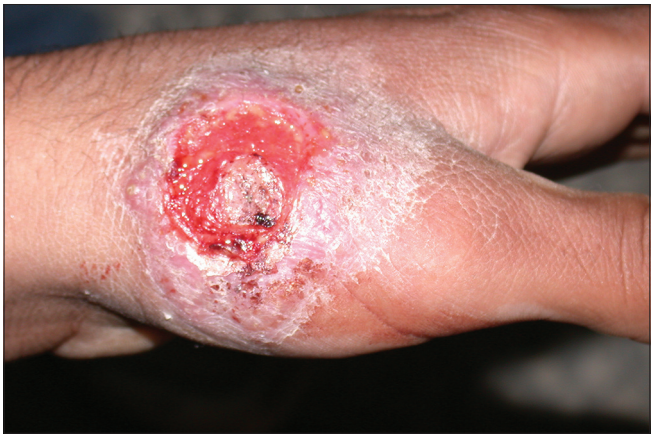

Figure 6: Volcano sign.

REFERENCES

1. Stawczyk-Macieja M, Szczerkowska-Dobosz A, Błażewicz I, Wilkowska A, Nowicki R. Dermatomyositis related to the relapse of cervical cancer. Our Dermatol Online. 2015;6:183-6.
2. Famularo G. Amyopathic dermatomyositis associated with an endometrial adenocarcinoma. Our Dermatol Online. 2017;8:235-6.
3. Docekal JW, Francisco G, Lee JC. Recurrent epicardial ventricular tachycardia following smallpox vaccination. HeartRhythm Case Rep. 2018;5:6-9.
4. Brzezinski P, Sinjab AT, Masferrer E, Gopie P, Naraysingh V, Yamamoto T, et al. Dermatology Eponyms – sign –Lexicon (G). Our Dermatol Online 2012;3:243-57.
5. Greenhow EH: On Addison`s Disease: Clnical Lectures and Reports on Diseases of the Supra-renal Capsules [with Comments on Dr. Addison`s Treatment and Theory]. London, J. W. Roche, 1866. On Addison`s Disease, being the Croonian Lectures for 1875.
6. Deresinski S, Mirels LF. Coccidioidomycosis: What a long strange trip it's been. Med Mycol. 2019;57(Supplement_1):S3-S15.
7. Brzezinski P, Wollina U, Poklękowska K, Khamesipour A, Herrero GJE, Bimbi C, et al. Dermatology eponyms – phenomen/sign –Lexicon (D). N Dermatol Online. 2011;2:158-70.
8. Krízek M, Senft V, Motán J. [Copper and the human body]. Cas Lek Cesk. 1997;136:698-701.
9. Rodichok LD. A case of barbiturate poisoning with a readily-accessible laboratory reagent. J Toxicol Clin Toxicol. 1992;30:455-8.
10. Brzeziński P, Sinjab AT, Campbell CM, Kentorp N, Sand C, Karwan K. Dermatology Eponyms – phenomen/sign –Lexicon (supplement). Our Dermatol Online. 2012;3:147-55.
11. Brzezinski P, Hassan I, Chiriac A, Sinjab AT. Dermatology Eponyms – sign –Lexicon (I). Our Dermatol Online. 2013;4:256-9.
12. Brzezinski P, Pessoa L, Galvão V, Barja Lopez JM, Adaskevich UP, Niamba PA, et al. Dermatology Eponyms – sign –Lexicon (H). Our Dermatol Online. 2013;4:130-43.
13. Brzezinski P, Chiriac A, Rath SK. Dermatology Eponyms – Sign – Lexicon – (M). Our Dermatol Online. 2014;5:442-7.
14. Brzezinski P, Chiriac A, Arenas R, Dori GU, Monteiro R, CairncrossS, et al. Dermatology Eponyms – Sign – Lexicon – (L). Our Dermatol Online. 2014;5:217-30.
15. Brzeziński P, Martini L, Di Martino Ortiz BA, Sajjan V, Narita M, Ono Y, et al. Dermatology Eponyms – sign –Lexicon (T). Part 2. Our Dermatol Online. 2019;10(2):X-X.
16. Brzeziński P, Passarini B, Nogueira A. Dermatology eponyms – phenomen/sign –dictionary (C). N Dermatol Online. 2011;2:81-100.
17. Brzeziński P, Hossein S-Z, Shane T, Bonifaz A, Arenas R, Royer-Bégyn M. Dermatology eponym – phenomen/sign – Dictionary (B). N Dermatol Online. 2011;2:35-45.
18. Kubba R, Al-Gindan Y, el-Hassan AM, Omer AH. Clinical diagnosis of cutaneous leishmaniasis (oriental sore). J Am Acad Dermatol. 1987;16:1183-9.
19. Brzeziński P, Wass J, White K, Daboul MW, Arlt W, van den Hombergh P, et al. Dermatology eponyms – phenomen/sign – Dictionary (A) – continued. N Dermatol Online. 2011;2:27-34.
20. Salissou L, Doulla M, Ouedraogo MM, Brah S, Daou M, Ali D, Adehossi E. [A crushing ulcerous lesion of the internal angle of the right eye: Cutaneous leishmaniasis is one of the causes]. Our Dermatol Online. 2018;9:203-6.

Source of Support: Nil, **Conflict of Interest:** None declared.

Our Dermatology Online

www.odermatol.com

4.2019 (03.October.2019)