Volume 9, Number 1, January 2018
p. 1 - 109
Issue online since Tuesday January 09, 2018

ISSN: 2081-9390
DOI: 10.7241/ourd

Our Dermatology Online

www.odermatol.com

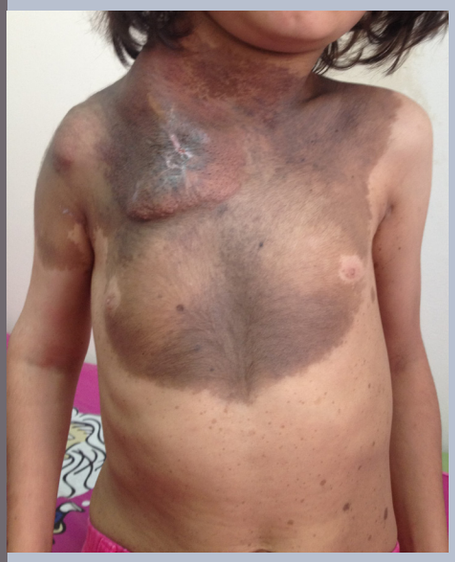

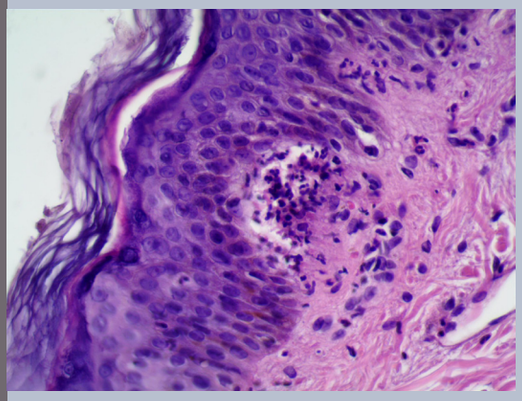

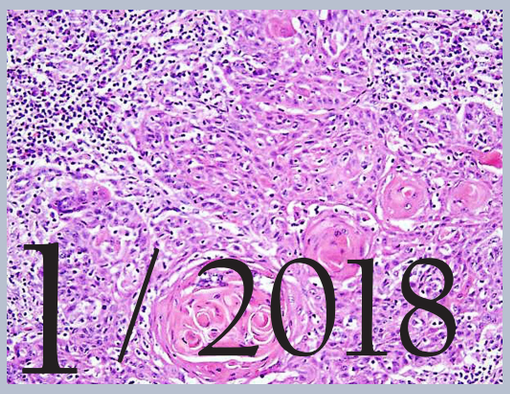

Editorial Pages

e-ISSN: 2081-9390
DOI: 10.7241/ourd

Quarterly
Our Dermatol Online

published since 01/06/2010 years

www.odermatol.com

Indexed in:

Universal Impact Factor for year 2012 is = 0.7319
system of opinion of scientific periodicals INDEX COPERNICUS (8,69)
(Academic Search) EBSCO
(Academic Search Premier) EBSCO
MNiSW (kbn)-Ministerstwo Nauki i Szkolnictwa Wyższego (7.00)
DOAJ (Directory of Open Acces Journals)
Geneva Foundation for Medical Education and Research (GFMER), Google Scholar, Open J-Gate, NewJour,
International Committee of Medical Journal Editors (ICMJE), Genamics JournalSeek, Hinari,
Bielefeld Academic Search Engine (BASE), WorldCat, e -journal, WorldWideScience.org, National Science Library,
LibSearch, Sciencegate, Virtual Science Library (VSL), Wanfang Data, COnnecting REpositories (CORE),
CAB Abstracts, Global Health, Journal Indexed in Directory of Research Journals Indexing,
OAIster: The Open Access Initiative, OAJSE - Open Access Journals Search Engine, Scirus

Previous website:	issue 1.2010	www.ndermatol.like.pl
	since issue 2.2010 to issue 3.2011	www.odermatol.like.pl
	since issue 4.2011	www.odermatol.com
Previous shortcut:	since issue 1.2010 to issue 3.2011	N Dermatol Online
	since issue 4.2011	Our Dermatol Online

Editorial Board

Contents

Contents

Contents

Our Dermatology Online

Original Article

Data analysis of 287 patients present with erythema nodosum: A closer look at associations

Oktem Ayse, Incel Uysal Pinar, Sahin Buket, Yalcin Basak

Department of Dermatology, Ankara Numune Training and Research Hospital, Ankara, Turkey

Corresponding author: Dr. Oktem Ayse, E-mail: ayseoktem@yahoo.com

ABSTRACT

Background: Erythema nodosum (EN) is the most common clinical variant of panniculitis. It may occur in association with a wide variety of causative stimuli. The aim of our study is to describe the possible etiologic factors associated with EN and compare them with the series previously reported in the literature. **Materials and Method:** This is a retrospective chart review of 287 patients who have presented to our clinic with tender erythematous nodular lesions and finally diagnosed as eythema nodosum between January 2010 and December 2015. **Results:** Our retrospective study included 239 females and 48 males (sex ratio, 5:1). Of the 287 EN patients, etiologic factor has been determined in 123 (42.85%) of the participants and this group was categorized as secondary EN. In secondary EN group the leading etiologic factor was infections (n=68, 23.69%). Other etiologic factors were Behcet's Disease (n=18, 6.27%), connective tissue disease (n=8, 2.78%), tuberculosis (n=6, 2.09%) sarcoidosis (n= 5, %1.74), drugs (n=6, 2.09%), granulomatous mastitis (n=2, 0.69%), IBD (n=2,0.69%), malignancy (n=1, 0.34%) and food supplement (n=1, 0.34%). **Conclusion:** Our data confirm that viral and bacterial infections are the leading causative factors of EN, followed by Behcet's Disease, pregnancy and connective tissue disease (CTD). These conditions should be investigated as part of systemic search.

Key words: Behcet's Disease; Erythema Nodosum; Erythematous Nodule

INTRODUCTION

Erythema nodosum (EN) is the most common clinical variant of panniculitis which is characterized with symmetric, warm, non-ulcerating, non-scarring, tender, red nodosities. The condition frequently occurs on the lower extremities especially on pretibial regions. Most cases appear between the second and fourth decades and the condition affects females more frequently [1-3].

The lesions generally tend to regress within three or four weeks spontaneously. New crops of lesions may continue to appear up to 6 weeks. Even though the diagnosis is based on mainly typical clinical characteristics, deep incisional biopsy may be beneficial for atypical cases. Histopathological examination reveals hypodermal septal inflammation without sign of vasculitis. The exact pathogenesis remains unclear even though it is considered to be a hypersensitivity reaction against various antigenic stimuli. It may occur in association with a wide variety of causative stimuli including infection diseases, drugs, inflammatory bowel disease (IBH), sarcoidosis, tuberculosis, Behcet's disease (BD) and malignancy. Despite most cases have no clearly identified causative factor, it may be a cutaneous sign of systemic serious comorbidity [1,3,4].

The aim of our study is to describe the possible etiologic factors associated with EN, to examine the characteristics of the primary and secondary forms of the disease and to compare them with the series previously reported in the literature. For this purpose we have collected data of the patients with the diagnosis of EN who have been diagnosed and treated in our department during the period of 2010-2015.

MATERIALS AND METHODS

This is a retrospective chart review of 287 patients who have presented to our outpatient clinic with tender

How to cite this article: Ayse O, Pinar IU, Buket S, Basak Y. Data analysis of 287 patients present with erythema nodosum: A closer look at associations. Our Dermatol Online. 2018;9(1):1-6.

Submission: 19.07.2017; **Acceptance:** 08.09.2017

DOI: 10.7241/ourd.20181.1

erythematous nodular lesions between January 2010 and December 2015. They were finally diagnosed EN by characteristic clinical findings with or without histological confirmation. Skin biopsies have been carried out in the patients (n= 62) who had not been diagnosed with existing clinical features and had atypical clinical presentation.

Patients were included on the basis of recorded data on the software of hospital information system, Fonet. Medical charts of patients with the ICD code of erythema nodosum for past medical history, infectious symptoms and drug use in preceding weeks. The demographic features (age and sex); clinical features, laboratory tests including complete blood count, erythrocyte sedimentation rate, C-reactive protein, liver function tests, rheumatoid factor, angiotensin converting enzyme, hepatitis B and C serology, anti-streptolysin O (ASO) titer in two consecutive evaluation at 2-4 weeks intervals, anti-nuclear antibody (ANA), urine test; tuberculin skin test; radiological studies including chest x-ray and thorax computed tomography results were evaluated. Patients who had incompatible histological characteristics and whose data were lacking were excluded from the study.

We diagnosed group A beta-hemolytic streptococcal infections with positive throat culture with/or two high consecutive ASO titers with 2-4 weeks interval. We considered patients as viral upper respiratory tract infection when there are clinical findings without bacteriologic evidence of streptococcal or any other bacteriologic infection. Diagnosis of tuberculosis and sarcoidosis were biopsy proven. Patients were questioned and evaluated for the signs and symptoms of BD according to the recently described diagnostic criteria of Behcet's Syndrome International Study Group Criteria [5] and these patients were newly diagnosed with BD after the clinical presentation of EN lesions. Given the aim of this study is examining patients present with erythema nodosum we excluded the data of BD patients who had been following-up in our Behcet disease outpatient clinic. 58% of whom had EN/EN like lesions during follow-up period.

Patients with EN who were previously diagnosed of BD and in our clinic. Continuous data were reported as the mean SD and categorical variables were reported as percentages.

Ethics Statement

The methods were in accordance with ethical principles of Declaration of Helsinki and the approval letter of ethics committee was obtained.

RESULTS

Patients in our retrospective study included 239 females and 48 males (sex ratio, 5:1). Patient's ages ranged between of 8-88 years (mean age of 39.2). Thirty eight percent (n=38) of the patients were required inpatient management. Mean hospital stay was 16 days for these patients. Many of the outpatient cases (n=169 patients, 58.88%) were sufficiently treated with removing triggering factor, leg elevation, wet dressing (with 0.9% NaCl or eau de goulard for 20 minutes twice in a day) with bed-rest. In 37 patients nonsteroidal anti-inflammatory drugs and potassium iodide treatment (300-500 mg three times daily) were effective. Colchicine or colchicine-corticosteroid combination was used in 27 of inpatients, effectively. Three of patients who have presented with severe clinical symptoms or did not show clinical improvement were treated with colchicine, corticosteroid and azothioprine combination.

Of the 287 EN patients, we could not identify any causative factor or association in 164 (57.14%) of participants. Possible etiologic factor has been determined in 123(42.85%) of the participants and this group was categorized as secondary EN (Table 1).

Prodromal systemic symptoms were exist in 25% (n=41) of primary and 38% (n=46) of secondary groups. Atypical clinical presentation (n=62) such as unilateral involvement, or atypical localization including upper extremities, gluteus, trunk and thighs were mostly – in 48 patients- observed in secondary EN group. In secondary EN group the leading etiologic factor was infections (n=68, 23.69%). Other etiologic factors were BD (n=18, 6.27%), connective tissue disease (n=8, 2.78%), tuberculosis (n=6, 2.09%) sarcoidosis (n= 5, 1.74%), drugs (n=6, 2.09%), granulomatous mastitis (n=2, 0.69%), IBD (n=2, 0.69 %), malignancy (n=1, 0.34%) and food supplement (n=1, 0.34%). Pregnancy was the precipitating event in twelve (5.02 %) of 239 female patients (Table 1).

Upper respiratory tract infections, common cold and influenza were the most common associated infectious

Table 1: Etiologic factors of patients diagnosed with erythema nodosum

Etiology	n (%)
Idiopathic	164 (57.54)
Secondary	121 (42.45)
Infection	66 (23.1)
1) Viral infections	37 (12.98)
Viral upper respiratory infection	34 (11.92)
Hepatitis B virus infection	2 (0.70)
Orf Disease	1 (0.35)
2) Bacterial infections	23 (8.07)
AGBH streptoccocal tonsillitis	11 (3.85)
Urinary infection	6 (2.10)
Pneumoniae (s.pneumonia)	3 (1.05)
Tularemia	2 (0.70)
Gardnerella vaginalis vaginitis	1 (0.35)
3) Tuberculosis	5 (1.75)
Pulmonary tuberculosis	3 (1.05)
Tuberculous lypmhadenitis	1 (0.35)
Cutaneous tuberculosis	1 (0.35)
4) Atypical Mycobacterial infection	1 (0.35)
Behcet's disease	18 (6.31)
Pregnancy	12 (4.21)
Connective tissue sisease	8 (2.80)
Romatoid arthritis	2 (0.70)
Ankylosing spondylitis	1 (0.35)
Systemic sclerosis	1 (0.35)
Sjogren's syndrome	1 (0.35)
Systemic lupus erythematosus	1 (0.35)
Sarcoidosis	5 (1.75)
Granulomatos mastitis	2 (0.70)
Drugs	6 (2.10)
Oral contraceptive drugs	5 (1.75)
Non steroidal anti-inflamamtory drugs	1 (0.35)
Inflammatory bowel disease	2 (0.70)
Malignancy (ALL)	1 (0.35)
Food supplement (protein powder)	1 (0.35)

triggers. The diagnosis of acute hepatitis B (HBV) infection was established by characteristic serologic profile in two patients and another one has had the history of chronic inactive hepatitis. In one patient EBV tonsillitis had been proven with acute exudative tonsillitis and EBV IgM positivity. A patient with a purulent-appearing papulonodular lesion on the finger and a history of contact with sheep had the diagnosis of orf disease. Among bacterial infections, group A beta-hemolytic streptococcal infections were discovered in eleven of patients. Six patients that had dysuria symptom and finding of *Eschericia coli* in urine culture were regarded as urinary tract infection. In three patient that have admitted with fever, cough with which phlegm, chest pain, infiltration in chest X-ray, a diagnosis of streptococcal pneumonia has been done with positive sputum cultures. Two cases that have had the history of living in the epidemic regions were considered the diagnosis of ulceroglandular tularemia. One female patient had a

Table 2: Laboratory findings of idiopathic and secondary Erythema nodosum groups

	Idiopathic Erythema nodosum	Secondary Erythema nodosum
Female/male	133/31	104/17
Mean age	42	35
Laboratory tests		
Leukocytosis	39 (13.6%)	6 (21%)
High sedimentation rate	83 (29.1%)	32 (11.2%)
C-reactive protein positivity	74 (25.9%)	37 (12.9%)
High ASO level	31 (10.8%)	11 (3.8%)
Tuberculin skin test postivity	31 (10.8%)	10 (3.5%)
Radiological examination		
Bilateral hilar and mediastinal LAP on thorax CT	2 (0.7%)	8 (2.8%)

diagnosis of *Gardnerella vaginalis* associated vaginitis. We established active pulmonary tuberculosis in three, tuberculosis lymphadenitis in one, tuberculous spondylitis in one and cutaneous tuberculosis in one of the cases.

Eighteen (6.27%) of cases were diagnosed with BD. Five patients who have presented with typical Löfgren's syndrome findings such as EN, bilateral hilar adenopathy were diagnosed with sarcoidosis. Granulomatous mastitis has been established in two females. The other potential etiologies and laboratory findings are summarized in Tables 1 and 2.

Regarding the patients with preceding viral upper respiratory tract infections and tonsillitis approximately 3 weeks of time interval was observed between the infection and onset of lesions. Exact time period could not be identified for other potential associations. There was not any detectable difference in primary or secondary EN groups according the lesion number. Highest number of EN lesions (nine nodules) was observed in a patient with the diagnosis of inflammatory bowel disease. During the 5-year data period recurrence was observed in twelve patients (9 of idiopathic group and 3 of secondary group; one had sarcoidosis, two had Behcet disease).

DISCUSSION

To our knowledge, this is the largest series of patients in the literature. Our study indicates that most common (23.1%) predictive factor of EN is infections and viral infections were the most common form. However demonstrating the causative factors and link between an infectious disease and EN may be extremely difficult because of the clinical or serologic improvement at the

time of lesion development. Also, differentiating the preceding subclinical symptoms of erythema nodosum (malaise, arthritis, fever etc) from the prodromal period of an infectious etiology is a potential pitfall. On the other hand, drugs frequently implicated factors in etiology of EN, nevertheless we could assessed medication in 2% of participants. The incidence of drug use in the etiology of EN was much lower than we expected regarding the lack of data regarding medical history and unconsciously medication use attitudes of our society. For these reasons, we believe that infectious and medical triggers may be overlooked and these patients were classified as 'idiopathic' or primary EN.

There are variable results about the frequency of tuberculosis in the etiology of EN in Turkey. Mert et al. were reported higher frequencies of primary tuberculosis [3,6]. On the other hand none of the patients were diagnosed with primary tuberculosis in the series of Kisacik et al [7]. Our study revealed that tuberculine skin test (TST) was reactive in 41(14%) of all cases whereas mycobacterium tuberculosis infection could be identified as a predictive factor in 6 (2%) of the cases. Given the fact that EN is a reactive process of immuncompetent individuals, strong positive response to TST is not surprising especially in Turkey, high incidence setting for tuberculosis. Therefore, according to our experience, erythema nodosum may occur in patients with highly positive tuberculine skin test but without focus of infection.

In our series other uncommon infectious triggers were also identified; hepatitis B virus, parapoxviurs (orf disease), Francisella Tularensis (tularemia), Gardnerella Vaginalis, atypical mycobacterial infection. In literature numerous factors other than infections and drugs have been known to cause to EN; malignant disease, pregnancy, sarcoidosis and romatologic disease. Needless to say, the proportion of secondary factors and overall incidence of EN differs from between distinct geographic regions (Tables 3 and 4).

In contrary to some reports, we detected BD as a second common trigger in 6.3% of patients presenting with erythema nodosum [8]. Similar to other reports from our country, by taking into account data of BD patients who had develop EN lesions in the follow-up period, association of BD and EN was detected in 29,7% of our patients [9,10] (Table 3).

Sarcoidosis is one of the most common etiologic factors in Europe [11,12]. However, we detected sarcoidosis with the ratio of 1%. Pregnancy, hormone therapy and oral contraceptive pills are other well known triggering factors of EN [1,13]. In a young male patient we could associate EN with usage of protein powder supplement with the purpose of gaining muscle for a few weeks. We considered that the protein products might induced the occurrence of EN although there is not report in the literature. Idiopathic granulomatous mastitis (IGM) represents a rare association of EN [14]. Notably our

Table 3: Secondary factors and overall incidence of Erythema nodosum in distinct geographic regions

Study	Singapore (1994-1997)[16]	France (1960-1995)[1]	Turkey (2003-2007)[9]	Spain (1988-1997)[12]	Turkey (1993-2004)[3]	Turkey (2013)[17]	Turkey (2005-2010)[11]	Greece (1984-1990)[8]	Current study (2010-2015)
Patient number	75	129	72	106	100	107	66	132	285
Female/Male	65/10	108/21	51/21	82/24	84/16	70/37	47/19	110/22	238/48
İdiopathic	45 (60%)	71 (55%)	30 (41%)	39 (36.8%)	53 (53%)	37 (34.6%)	52 (78%)	46 (35%)	164 (58%)
Secondary	30 (40%)	58 (45%)	42 (58.3%)	67 (63.2%)	47 (47%)	70 (65.4%)	14 (21%)	86 (65%)	121 (42%)
Infections	25 (33.3%)	42 (32.6%)	24 (33.3%)	34 (32.07%)	21 (21%)	9 (8.4%)	6 (9.09%)	25 (19%)	66 (23%)
Behcet's syndrome	2 (3%)		13 (18%)	2 (1.9%)	6 (6%)	40 (37.4%)	15 (22%)	5 (3.8%)	18 (6%)
Pregnancy	3 (4%)	5 (4.6%)	1 (1.3%)		2 (2%)		2 (3%)	8 (6%)	12 (14%)
Drugs alone			3 (4.1%)	3 (2.8%)	5 (5%)		13 (19%)	10 (7.6%)	6 (2%)
Sarcoidosis		14 (10.8%)	1 (1.3%)	22 (20.75%)	10 (10%)	17 (15.9%)	10 (15%)	37 (28%)	5 (1%)
Rheumatoid Diseases						2 (1.9%)		1 (0.8%)	8 (3%)
Inflammatory bowel disease		2 (1.5%)		3 (2.8%)	3 (3%)				2 (0.7%)
Malignancy				1 (0.94%)					1 (0.35%)
Sweet syndrome				2 (1.9%)					
Granulomatous mastitis									2 (1%)
Food suplement									1 (0.35%)

Table 4: Infectious precipitant factors of Erythema nodosum in distinct geographic regions, Cold, flu/influenza, or nonpurulent pharyngitis*

Study	Singapore[16] (1994-1997)	France[1] (1960-1995)	Turkey[9] (2003-2007)	Spain[12] (1988-1997)	Turkey[3] (1993-2004)	Turkey[17] (2014)	Turkey[10]] (2005-2010)	Greece[11] (1984-1990)	Current study (2010-2015)
Infections	25	42	24	34	22	9	6 (unspecified)	25	66
Bacterial	11	42	22	14	22	9		12	29
Bacterial URTI			20						
Bacterial UTI			2						6
Streptococcal infections	7	36		7	11	9		8	14
Tuberculosis	2	1		5	10			2	5
Cat scratch disease	1								
Gonorrhoea	1								
M.pneumonia		1							1
C.trochomatis		2							
C.pneumonia		1							
Yercinia enterocolitica		1							
E. coli				1					
Salmonellosis								2	
Brucellosis				1					
Tularemia									2
G.vaginalis									1
Viral	14		2	20*				13	37
URTI									34
HBV									2
Orf disease									1
EBV, CMV								13	
Unspesified	13								
Varicella	1								

two patients with idiopathic granulomatous mastitis were required systemic steroid and colchicine treatment for EN.

In fact, it may be extremely difficult to prove the true predictive factor in some instances. The strength of our study is in its high numbers for the condition. On the other hand, potential pitfall of this study is retrospective study design, lack of control group. Among the extensive etiologic factor list, new onset of EN after receiving vaccination is not common, but in the literature there are reported cases following vaccination for tetanus, diphtheria, and acellular pertussis (Tdap), hepatitis B, tuberculosis, cholera, typhoid, human papillomavirus, malaria, small pox and rabies [15]. In our series of 287 patients we did not detect any case that triggered with vaccination.

CONCLUSION

In our series we could not find any precipitating factors in 57.5 % of the patients. Our data confirm that viral and bacterial infections are the leading causative factors of EN, followed by BD, pregnancy and connective tissue disease (CTD). These conditions should be investigated as part of systemic search at initial presentation. Nevertheless clinicians should be aware of uncommon precipitating conditions such as rare microbial agents, idiopathic granulomatous mastitis or food supplement. Large prospective studies are still needed for reliable results providing interactions with EN and its associations.

REFERENCES

1. Cribier B, Caille A, Heid E, Grosshans E. Erythema nodosum and associated diseases. A study of 129 cases. Int J Dermatol. 1998;37:667-72.
2. Bohn S, Buchner S, Itin P. [Erythema nodosum: 112 cases. Epidemiology, clinical aspects and histopathology]. Schweiz Med Wochenschr. 1997;127:1168-76.
3. Mert A, Kumbasar H, Ozaras R, Erten S, Tasli L, Tabak F, et al. Erythema nodosum: an evaluation of 100 cases. Clin Exp Rheumatol. 2007;25:563-70.
4. Schwartz RA, Nervi SJ. Erythema nodosum: a sign of systemic disease. Am Fam Physician. 2007;75:695-700.
5. Criteria for diagnosis of Behcet's disease. International Study Group for Behcet's Disease. Lancet. 1990;335:1078-80.
6. Mert A, Ozaras R, Tabak F, Pekmezci S, Demirkesen C, Ozturk R. Erythema nodosum: an experience of 10 years. Scand J Infect Dis. 2004;36:424-7.
7. Kisacik B, Onat AM, Pehlivan Y. Multiclinical experiences in

erythema nodosum: rheumatology clinics versus dermatology and infection diseases clinics. Rheumatol Int. 2013;33:315-8.

8. Atanes A, Gomez N, Aspe B, de Toro J, Grana J, Sanchez JM, et al. [Erythema nodosum: a study of 160 cases]. Med Clin (Barc). 1991;96:169-72.
9. Oz A, Adim S, Izol B, Saricaoglu H, Baskan E, Tunali S. Erythema nodosum epidemiology: 5-years Retrospective Study. Turk J Dermatol. 2012;6:87-90.
10. Adışen E, Şeker Ü, Gürer MA. Etiologic Factors In Erythema Nodosum. Turkderm. 2008;42:113-7.
11. Psychos DN, Voulgari PV, Skopouli FN, Drosos AA, Moutsopoulos HM. Erythema nodosum: the underlying conditions. Clin Rheumatol. 2000;19:212-6.
12. Garcia-Porrua C, Gonzalez-Gay MA, Vazquez-Caruncho M, Lopez-Lazaro L, Lueiro M, Fernandez ML, et al. Erythema nodosum: etiologic and predictive factors in a defined population. Arthritis Rheum. 2000;43:584-92.
13. Yang SG, Han KH, Cho KH, Lee AY. Development of erythema nodosum in the course of oestrogen replacement therapy. The British journal of dermatology. 1997;137:319-20.
14. Fruchter R, Castilla C, Ng E, Pomeranz MK, Femia AN. Erythema nodosum in association with idiopathic granulomatous mastitis: a case series and review of the literature. J Europ Acad Dermatol Venereol. 2017;31:e391-e3.
15. Cohen PR. Combined reduced-antigen content tetanus, diphtheria, and acellular pertussis (tdap) vaccine-related erythema nodosum: case report and review of vaccine-associated erythema nodosum. Dermatol Ther (Heidelb). 2013;3:191-7.
16. Giam YC, Ong BH, Tan T. Erythema nodosum leprosum in Singapore. Ann Acad Med Singapore. 1987;16:658-62.
17. Aydin-Teke T, Tanir G, Bayhan GI, Metin O, Oz N. Erythema nodosum in children: evaluation of 39 patients. Turk J Pediatr. 2014;56:144-9.

Source of Support: Nil, **Conflict of Interest:** None declared.

Original Article

Management of hemangiomas by propranolol: Epidemiological, clinical and therapeutic aspects: Retrospective study about 15 cases

Moussa Doulla[1], Harouna Bako[2], Laouali Salissou[1], Maimouna M Ouédraogo[1], Ide Hassane[3], Mariama Abdoulaye[1], Hassan Moumouni[4]

[1]Department of Dermatology Venerology, National Hospital of Niamey, Niger, [2]National Center Dermato-Leprosy, Niamey, Niger, [3]Cardiology Department, National Hospital of Niamey, Niger, [4]Laboratory of Cytology and Genetics, Faculty of Health Sciences, Niamey, Niger

Corresponding author: Dr. Laouali Salissou, E-mail: danmata@yahoo.com

ABSTRACT

The objective of this study was to determine the epidemiological, clinical and therapeutic profile of cutaneous hemangioma at the Niamey National Hospital. This is a retrospective study carried out over a period of 2 years, in the Unity of Dermatology and Venerology. Out of a total of 1648 consultations in 2 years, 33 cases of cutaneous angioma were identified; which represented 2%. The prevalence was predominantly female (80%) and the sex ratio M/F was 0.25. The age group 0-5 months was more represented (66.7%) with ages ranging 2 days and 24 months. Of the 33 cases of angioma, 25 were hemangiomas and 8 were malformations without any cardiac anomalie. Patients retained for the study were those with hemangioma (25 cases with 76%) who received the Propranolol protocol used in the oral dosage of 1 mg/kg/day for 24 months. Only 15 patients recovered totally from hemangioma. Tolerance was good in 93.3%. **Conclusion:** Several therapies still show their limit. Due to the often serious side effects with corticosteroids, treatment based on betablockers can be a way of the future, given the satisfaction of results and the good tolerance to these molecules.

Key words: Angioma; Hemangioma; Propranolol

INTRODUCTION

Angiomas are a heterogeneous group of vascular diseases including hemangiomas and malformations [1-3]. Immature angioma or hemangioma is a benign vascular tumor of undetermined etiology following proliferation of endothelial and mesenchymal cells with formation of neo-vessels in the dermis [4,5]. They are the most common tumors of the child, with a prevalence of 10% and whose diagnosis is essentially clinical [4-6]. The management uses various methods namely: corticosteroid therapy, surgery, laser, radiotherapy, interferon, betablockers that currently seem the most used [5,7,8]. The purpose of this study was to determine the epidemiological and clinical aspects of angiomas, but also to evaluate the outcome of the management of hemangioma by a betablocker, that is Propranolol.

MATERIAL AND METHODS

This is a retrospective study lasting 2 years from January 1, 2012 to December 31, 2013, conducted at the Dermatology and Venereology Department of the National Hospital of Niamey. The information was collected from the consultation records using a survey card containing epidemiological, clinical, paraclinical and therapeutic data. Included in this study were all

How to cite this article: Doulla M, Bako H, Salissou L, Ouédraogo MM, Hassane I, Abdoulaye M, Moumouni H. Management of hemangiomas by propranolol: Epidemiological, clinical and therapeutic aspects: retrospective study about 15 cases. Our Dermatol Online. 2018;9(1):7-10.

Submission: 05.05.2017; **Acceptance:** 21.11.2017

DOI: 10.7241/ourd.20181.2

cases of skin hemangiomas diagnosed and treated with Propranolol tablet for 24 months. The protocol of Propranolol was as follows: 1 mg / kg / day diluted in tap water, and administered with a 10 ml syringe. The intake was 5ml in the morning and 5 ml in the evening. Patients with vascular malformation and cases of hemangioma lost from the study were excluded from the study. The data was entered on the Epi-info software version 3.5.1 and transferred to the EXCEL software for analysis.

RESULTS

During the study period, we collected 33 cases of cutaneous angioma out of 1648 consultations, either a frequency of 2%. Of these 33 cases, 25 patients (76%) had hemangioma and 8 had vascular malformation (24%). Fifteen out of twenty five patients with hemangioma (26%) performed Propranolol treatment, including 12 girls and 3 boys. The concept of consanguinity was found in 6.7% of cases. Patients younger than 5 months were the most represented (66.7%). The average age was 5.8 months and the extremes were 2 days and 24 months. Hemangiomas appeared 2 months after birth in 46.6% of cases, with a predominant localization in the cephalic region (forehead and cheeks) (Table I).

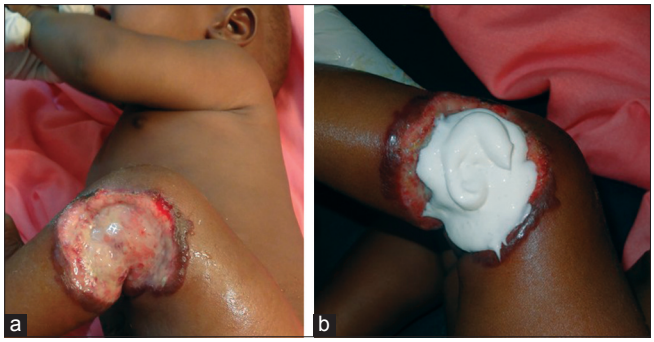

Figure 1: (a) Ulcerated hemangioma of the outer face of the left knee. (b) Ulcerated hemangioma of the outer face of the left knee.

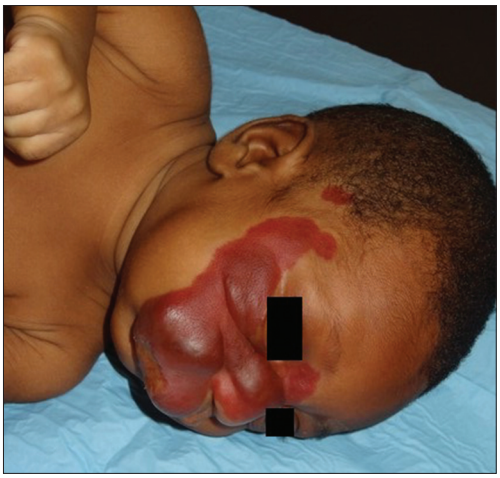

Figure 2: Hemangioma disfiguring the right hemiface.

The pre-therapeutic assessment carried out namely: Glycemia, Transaminases, Creatinemia, ECG, was without any particularity. Tolerance to oral therapy was good in all patients. Local treatment has been associated with trolamine in ulcerated hemangiomas (Figs 1A and 1B) Complications were noted in 6 cases (40%): either aesthetic type (Fig. 2) in 83% of cases, or infectious type in 16.7% of cases (Fig. 3). Treatment evolution was favorable in 93.3% of cases (Figs. 1A and 4).

DISCUSSION

Out of a total of 1648 consultations in 2 years, 33 cases of cutaneous angioma were collected, either a frequency of 2%. Lower frequencies have been reported: In Mali, GUINDO O et al. reported on 4544 dermatological consultations 31 cases of angiomas during a study period from 19 July 2005 to 23 April 2009, ie 0.68% [9]; in Burkina Faso TRAORE FB et al. in 2003 found 12 cases of angiomas among 14265 patients consulted during the study period from January 1, 1992 to December 31, 1996, a frequency of 0.08% [10].In our study the sex ratio was 1 man for 4 women. Most studies have reported a female predominance [7,11,12-14]. In literature this predominance of women has no explanation yet [15].

The 0-5 month age group was the most represented in our study (66.7%), with an average age of 5.8 months. This average age was lower than that reported by some authors with respectively 9.65 months and 13.06 months[11,13]. As in our case with 6.7%, the notion of consanguinity is poorly reported in the literature [11,16,17].We reported the presence of hemangiomas in 46.6% at birth; This corroborates data from the literature which shows that lesions may be present at birth or may appear in the days or weeks following birth [17,18]. We have noted a ubiquitous

Table I: Distribution of patients by topography

Topography	Patients	Percentage (%)
Forehead	6	40
Cheeks	5	33 ,33
Knees	1	6,66
Legs	3	20
Total	15	100,0

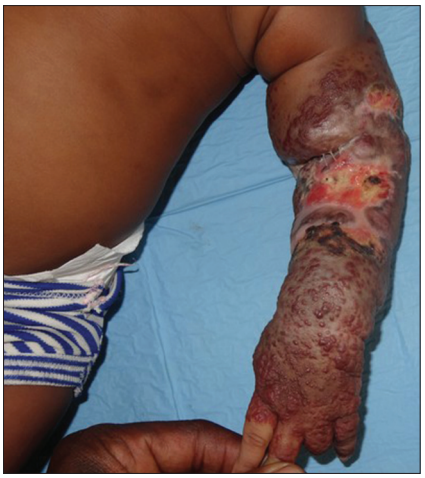

Figure 3: Impetigentiated hemangioma of the left thoracic limb.

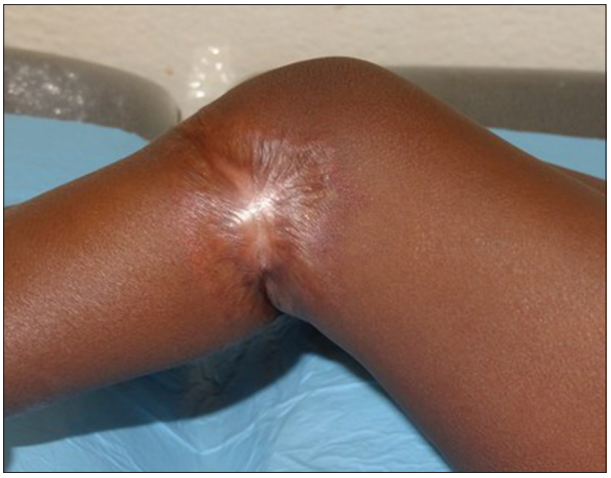

Figure 4: Ulcerated hemangioma after treatment with retractile scar.

distribution of lesions, as reported by some authors with, however, as in our series a cephalic predominance [12,18,19]. From the therapeutic point of view, since the observation of their effectiveness, betablockers are the subject of several studies [20-23]. In our study we noted a remarkable efficacy of Propranolol in 93.3% after 24 months of treatment. Despite the low dose we used (1m / kg / d), our results are similar to those of some series with 84% efficacy [17], at a dose of 3 mg / kg / day on also a period of 24 months; and even higher than those of a study reporting 46% efficacy using a dose of 2 mg / kg / day [24]. Tolerance was good in all cases, but some authors have reported side effects such as hypoglycaemia, diarrhea, vomiting, insomnia, low blood pressure, cold extremities [12,25]. Our percentages of healing (93.3%) are comparable to those of some literatures who obtained 88.2% [21]. In our study we noted complications in 40% of cases, type of infection and aesthetic damage. The aesthetic damage was observed in 83.3%, and was significantly higher than that reported by Yacouba K. with 63.6% [26]. There is no standard rating of these harms, however, it is reported in the literature that severe forms account for less than 5% [17,18].

CONCLUSION

In this study cutaneous angioma represents 2% of dermatological consultations. The predominance of female cases may be related to aesthetic reasons. The efficacy and tolerability of Propranolol treatment was significant and favorable. A prospective study on a more significant number of cases, will confirm the choice of betablockers in the management of hemangiomas.

Statement of Human and Animal Rights

All procedures followed were in accordance with the ethical standards of the responsible committee on human experimentation (institutional and national) and with the Helsinki Declaration of 1975, as revised in 2008.

Statement of Informed Consent

Informed consent was obtained from all parent patients for being included in the study.

RÉFÉRENCES

1. Odile Enjolras, Véronique Soupre, Arnaud Picard. Classification des anomalies vasculaires Superficielles. Presse Med. 2010;39:457-64.
2. A. Dompmartin. Classification des anomalies vasculaires. Ann Dermatol Vénérol. 2013;140:337-9.
3. Tiemtoré-Kambou BMA, Ouédraogo NA, Ndé/Ouédraogo NA, Traoré F, Ouédraogo PA, Dao BA, Ouattara B, et al. Angioma plane of the face: About two cases of which one revealing sturge weber and krabbe syndrome. Our Dermatol Online. 2017;8:70-4.
4. Bonnetblanc J-M: Angiomes Cutanés. Ann Dermatol Vénérol. 2012;139: A185-A91.
5. Eschard C. Hémangiomes infantiles. Quand explorer et actualités thérapeutiques. Ann Dermatol Vénérol. 2015;142:476-82.
6. Chiller KG, Passaro D, Fieden IJ. Hemangiomas of infancy clinical characteristics, morphologic subtypes and their relationship to race, ethnicity and sex. Arch Dermatol. 2002;138:1567–76.
7. David LR, Malek MM, Argenta LC. Efficacity of pulsed dye laser therapy for the treatment of ulcerated hemangiomas: a review of 78 patients. Br J Plast Surg. 2003;56:317-27.
8. Achauer BM, Chang CJ, Vander Kam VM. Management of hemangioma of infancy: review of 245 patients. Plast Reconstr Surg. 1997;99:1301–8.
9. GUINDO O**.** Aspects épidémiologiques, cliniques et thérapeutiques des angiomes immatures. [l'institut Marchoux]: Bamako; 2000.
10. Ttaroe FB, Traroe A, Konate I, Traroe S. Tumeurs cutanéo- muqeuses: aspects épidémiologiques. Cah études recherc francoph/Santé Avril 2003 13 (2).
11. Fatemeh L, Pouran L, Behzad A, Mohammad A T, Maryam A M, Ali T. Propranolol for infantile hemangioma: An evaluation of its

efficacy and safety in Iranian infants. Iranian Jr Neonat. 2016:7:20.
12. Marlies G, Johannes M. Adverse effects of propranolol when used in the treatment of hemangiomas: A case series of 28 infants. J Am Acad Dermatol. 2011;65:320-7.
13. R. Gammoudi L, Boussofara W, Saidi A, Aounallah N, Ghariani C, Belajouza P, et al. Le propranolol dans l'hémangiome infantile. Ann Dermatol Vénérol. 2014;141:336–7.
14. Bouras M, Khadir K, Fatwaki FZ, Hali F, Salimi S, Chbani K, et al. Évaluation à long terme de l'efficacité du propranolol par voie orale dans le traitement des hémangiomes infantiles: étude prospective de 68 cas. Ann Dermatol Vénérol. 2013;140:1-4.
15. Enjolras O. Quoi de neuf dans les angiomes ? Tumeurs vasculaires infantiles. Nouv Dermatol. 2003;22:602-4.
16. Ousi B. Traitement des angiomes plans de l'adulte par laser KTP. Journ Paris Grp Laser Soc Fr Dermatol. 2007;26:34–8.
17. Enjolras O. Anomalies vasculaires superficielles : les «angiomes. Encycl Méd Chir. (Editions Scientifiques et Médicales Elsevier SAS, Paris), Paris; 2001. p. 15.
18. Lemarchand, Venencie F, Enjolras O. Angiomes et malformations vasculaires. Dermatologie et infections sexuellement transmissibles. 4 ème édition. Paris; 2004;696–703.
19. Lemarchand F-V, Enjolras O, Bisdorff A-B. Dermatologie et infections sexuellement transmissibles: Angiomes et malformations vasculaires [Internet]. Elsevier Masson; 2008. Available from: www.em-consulte.com/article/195571/réference
20. Léauté-Labrèze C. Traitement par propranolol des hémangiomes infantiles. Arch Pédiat. 2015;22:452–5.
21. Price CJ. Propranolol vs Corticosteroids for Infantile Hemangiomas: A Multicenter Retrospective Analysis. Arch Dermatol. 2001;147:1371.
22. Holmes WJ, Mishra A, Gorst C, Liew SH. Propranolol as first-line treatment for rapidly proliferating infantile haemangiomas. J Plast Reconstr Aesthet Surg. 2011;64:445–51.
23. Chik KK, Luk CK, Chan HB, Tan HY. Use of propranolol in infantile haemangioma among Chinese children. Hong Kong Med J. 2010;16:341–6.
24. Léaute-Labrèze C, Prey S, Ezzedine K. Infantile haemangioma: Part I. Pathophysiology, epidemiology, clinical features, life cycle and associated structural abnormalities and Part.II : Risks, complications and treatment. J Eur Acad Dermatol Venerol. 2011;25:1245-53.
25. Holland KE, Frieden IJ, Frommelt PC, Mancini AJ, Wyatt D, Drolet BA, Hypoglycemia in Children Taking Propranolol for the Treatment of Infantile Hemangioma. Arch Dermatol. 2010;146:775-8.
26. Diarra YK, Rhaly AA, Cisse IA, Traroe B, Diawara KH. Aspects épidémiologiques et cliniques des angiomes au CHU de Gabriel Toure. [CHU de Gabriel Toure Bamako]: faculté de Médecine, de Pharmacie et d'Odonto- Stomatologie; 2010.

Source of Support: Nil, **Conflict of Interest:** None declared.

Original Article

Melanoma and medical education: knowledge and sun safety practices amongst medical students

Nicolina Smith[1], Margaret Finn[2], Larry Segars[3], Erin Burns[2], Johanna Peterson[4], Angela Sutton[3], Kaitlin Vogt[2], Molly Menser[5]

[1]Department of Anatomy, Kansas City University of Medicine and Biosciences. Kansas City, Missouri, USA, [2]Department of Dermatology, The University of Missouri. Kansas City, Missouri, USA, [3]Department of Pharmacology, Kansas City University of Medicine and Biosciences. Kansas City, Missouri, USA, [4]Department of Dermatology, The University of Kansas Hospital. Kansas City, Missouri, USA, [5]Dermatology, Sunflower Dermatology and Medical Day Spa. Kansas City, Missouri, USA

Corresponding author: Dr. Nicolina Smith., E-mail: NMSmith@Kcumb.edu

ABSTRACT

Introduction: Melanoma has become a public health problem; however, with proper education and the use of sun safety techniques, most cases can be prevented. The purpose of this study is to determine if medical students have safer sun practices than the general population. **Material and Methods:** An online survey was sent to all students enrolled in the three medical schools in the Kansas City metropolitan area. Surveys were sent to 1200 medical students with a 39.25% response rate (n=471). **Results:** Most of the student population (n=436; 92.6%) indicated that over the past year they had used one or more forms of sun protection. Of the respondents, 60.7% (n=286) indicated they had, to this point in their medical training, been educated counseling patients about the risk factors for prevention of skin cancer. Respondents who indicated that they had been educated on the steps/procedures of a complete skin exam were significantly more likely to indicate they had used sun protective equipment in the past year (P=.024). **Conclusions:** The general population is in need of dermatologic education on the basic risk factors of skin cancer as well as ways to prevent skin cancer. As education increases in the general population one would anticipate that these individuals would engage in safe sun practices as seen in the medical student community.

Key words: Dermatology curriculum; Melanoma; Sun safety; Preventative medicine

INTRODUCTION

Skin cancer is the most prevalent type of cancer in the United States [1]. Of the three major types of skin cancer, melanoma is the least prevalent; however, it is responsible for 75% of skin cancer deaths [2] Every 52 minutes one person dies of melanoma in the United States. This is alarming when considering for over 40 years the incidence of melanoma in the United States has been increasing. Melanoma has become a public health problem; however, with proper education and the use of sun safety techniques, most cases of this deadly disease are possibly preventable [3].

Patients with nonmelanoma and melanoma skin cancers often initially present to a non-dermatologist, suggesting that more physicians need to have the clinical skills to diagnose worrisome lesions and counsel on proper sun protective practices [4-6]. Physicians with better personal health practices are more likely to have better attitudes towards counseling patients, counsel a broader range of patients and counsel more frequently [7]. We investigated the level of education and personal practices of medical students regarding skin examinations and sun protection habits.

MATERIAL AND METHODS

A detailed medical literature review was initially performed looking at the habits and experiences of the general public in relation to sun exposure and indoor

How to cite this article: Smith N, Finn M, Segars L, Burns E, Peterson J, Sutton A, Vogt K, Menser M. Melanoma and medical education: knowledge and sun safety practices amongst medical students. Our Dermatol Online. 2018;9(1):11-14.

Submission: 09.09.2017; **Acceptance:** 26.11.2017

DOI: 10.7241/ourd.20181.3

tanning bed use, as well as the research available on medical student training with safe skin practices and skin examination. From this literature evaluation we developed a survey that had two primary sections and included a total of 22 questions. These questions assessed the skin characteristics of each student as well as their personal sun practices.

The survey was distributed via school-specific email accounts in the fall semester of 2012 to all medical students, MS1 to MS4, (n= 1200) from the following medical schools: University of Kansas School of Medicine, University of Missouri-Kansas City School of Medicine, and Kansas City University of Medicine and Biosciences. Study data was collected and managed using the Research Electronic Data Capture (REDCap) (Vanderbilt University, Copyright 2016) electronic data capture tool hosted at the University of Missouri-Kansas City. REDCap is a secure, web-based application designed to support data capture for research studies. The respective Institutional Review Boards at each of the participating medical schools approved this study.

Survey responses were reviewed for completeness. Surveys submitted without responses were removed and not included in the final study population or descriptive statistics (n=2). Descriptive statistics were generated for all survey items and an initial univariate analysis was performed on each item through use of the chi-square test. Correlations were also performed to evaluate direction and magnitude of any significant associations found between survey items. Sequential and systematic stratified univariate and multivariate logistic and multinomial regression analyses, as appropriate, were conducted to assess for significance, confounding and effect modification on selected items utilized as outcome variables. All variables found to be statistically significant or to be associated with confounding/interaction were utilized in the final regression models. Odds ratios (OR) and 95% confidence intervals (CI) were determined from regression modeling and all tests for significance were two-tailed with an *a priori* level of 0.05 (P=.05). Stata statistical software package (SE version 9.2; Stata Corp., College Station, Texas) was utilized for all analyses.

RESULTS

An estimated total of 1200 medical students were surveyed and resulted with a 39.25% response rate (n=471). Most of the student population (n=436; 92.6%) indicated that over the past year they had used one or more forms of sun protection. Only 10.4% (n=49) of the respondents indicated they had used a tanning bed during the past year (Table 1).

Of the respondents, 60.7% (n=286) indicated they had, to this point in their medical training, been educated on counseling patients about the risk factors for prevention of skin cancer. Medical student respondents who indicated they had been educated on how to perform a complete skin examination were significantly more likely to use protective sun equipment in the past year (P=.024). Respondents who indicated they had been educated on the performance of a complete skin examination indicated they were significantly more likely to seek shade while outside (P=.003), avoid peak sun hours (P=.030), use creams, sprays, or other artificial tanning products to have tan skin (P=.011). Students who had been educated on the performance of a complete skin examination also indicated that medical education changed their personal belief in tanned skin (P=.005). They felt it was very important to counsel patients on the risk factors and prevention of skin cancer (P=.040) and, they had a higher total number of sun protection practices (P=.003) (Table 2).

Medical student respondents who indicated they had been educated on how to counsel patients on the risk factors and prevention of skin cancer were significantly more likely to indicate they seek shade as much as possible (P=.049), avoid peak sun hours (P=.010), believe that their medical education had changed their beliefs about tanned skin, and would be more likely to perform a complete skin exam on their future patients (P=.001). These students were also less likely to use a tanning booth in the past year (P=.003) (Table 3).

Table 1: Medical student sun practices

Utilized forms of sun protection in past year	
Yes	436 (92.6)
No	32 (6.8)
No response	3 (0.6)
Spent time in sun to tan in past year	
Yes	266 (56.5)
No	203 (43.1)
No response	2 (0.4)
Utilized a tanning bed/booth in past year	
Yes	49 (10.4)
No	418 (88.7)
No response	4 (0.8)

[§]Includes sunscreen, protective clothing/equipment (e.g., long sleeves, long pants, hat, umbrella), seeking shade as much as possible (e.g., trees, buildings, awnings), or avoiding peak sun hours (e.g., 10 a.m. to 4 p.m.)

Table 2: Comparing medical students who were educated about risk factors and prevention of skin cancer and the use of sun protection practices

Educated on counseling patients about risk factors for/ prevention of skin cancer	
Yes	286 (60.7)
No	185 (39.3)
No response	0 (0.0)
Educated on steps/procedures in performing complete skin examination	
Yes	139 (29.5)
No	331 (70.3)
No response	1 (0.2)
Total sun protection practices*ƒ*	
0	36 (7.6)
1	153 (32.5)
2	124 (26.3)
3	104 (22.1)
4	54 (11.5)
No response	0 (0.0)
Utilized artificial tanning products¥	
Yes	92 (19.5)
No	376 (79.8)
No response	3 (0.6)
Believe medical education has changed desire for tanned skin	
Yes	171 (36.3)
No	186 (39.5)
Not applicable	112 (23.8)
No response	2 (0.4)
How likely to perform annual complete skin examination on future patients	
Very likely	109 (23.1)
Somewhat likely	210 (44.6)
Neither likely or unlikely	78 (16.6)
Somewhat unlikely	40 (8.5)
Very unlikely	34 (7.2)
No response	0 (0.0)
Importance of counseling patients about risk factors for/ prevention of skin cancer	
Very important	299 (63.5)
Somewhat important	165 (35.0)
Neither important or unimportant	4 (0.8)
Somewhat unimportant	0 (0.0)
Very unimportant	0 (0.0)
No response	3 (0.6)

*ƒ*Total sum of individually designated sun protection practices (e.g., use of sunscreen; use of protective clothing/equipment (e.g., long sleeves, long pants, hat, umbrella); seeking shade as much as possible e.g., trees, buildings, awnings); avoiding peak sun hours (e.g., 10 a.m. to 4 p.m.)

¥Includes spray tans, tanning creams or tinted moisturizers.

Table 3: Comparing medical students who were educated versus those who were not on the behaviors above

Educated on counseling patients about risk factors for prevention of skin cancer	
Yes	286 (60.7)
No	185 (39.3)
No response	0 (0.0)
Total sun protection practices	
0	36 (7.6)
1	153 (32.5)
2	124 (26.3)
3	104 (22.1)
4	54 (11.5)
No response	0 (0.0)
Believe medical education has changed desire for tanned skin	
Yes	171 (36.3)
No	186 (39.5)
Not applicable	112 (23.8)
No response	2 (0.4)
Utilized a tanning bed/booth in past year	
Yes	49 (10.4)
No	418 (88.7)
No response	4 (0.8)

DISCUSSION

Adult medical students (92.6%) are more likely to use one or more forms of sun protection in comparison to the general U.S. adult (18 and older) population (70%) [1]. The correlations performed in our study suggest that medical students who have been educated on the steps and procedures of a complete skin examination were more likely to use forms of protective sun equipment and believed their medical education had changed their belief of tan skin. Medical students who indicated they had been educated on how to counsel patients about risk factors and prevention were also more likely to seek shade when possible, avoid peak sun hours, and believe that their medical education has changed their beliefs about tanned skin. Our analyses suggest that medical school students have better sun protective practices because they are educated about skin cancer and potential risk factors. Thus, there could be a positive correlation between the amount an individual is educated about risk factors and prevention of skin cancer and the likelihood of engaging in safe skin practices. These findings should encourage primary care physicians as well as dermatologists to reach out to communities and offer education to the general public about skin cancer.

The lack of education amongst the adult population translates to the lack of parent sun-protection practices for children. Framingham, Massachusetts conducted a population–based study showing that 55% of children reported experiencing one or more sunburns during the prior summer and, more alarmingly, only 25% routinely used sunscreen [8]. There is a need to integrate sunscreen use into children's daily routines to reduce their risk of developing skin cancer.

With the rates of skin cancer increasing it is also important to consider the economical impact. The annual cost of melanoma treatment has increased by 288% from 2002 to 2006 and from 2007 to 2011.6 This

is high, especially when you compare it to treatment for all other cancers, which has only increased by 25% within the same timeframe. In the United States, skin cancer treatment costs $8.1 billion and of that $3.3 billion is from melanoma [9-13].

The level of skin cancer education in the general public is a problem that needs to be addressed. The Community Guide, which was made by The Community Preventive Services Task Force, states that there is enough evidence to recommend education approaches to increase the knowledge of preventative behaviors amongst child care centers, schools, and occupational settings. The Community Guide states that multicomponent interventions are the most effective when implementing preventative behaviors. The interventions must have two distinct components which can be any combination of the following: individual strategy, mass media campaign, or environmental and policy changes.[14,15] Using these guidelines to create a skin cancer campaign, education of the general population should increase and, in turn, raise their likelihood to engage in adequate sun safety techniques.

CONCLUSIONS

Our study compared medical students who are educated on safe sun practices and risk factors of skin cancer to students who are not yet educated on these topics. These results led us to believe that education makes a difference in a person's likelihood to engage in safe sun practices. This could be the reason for such a gap in sun safety practices between the medical students we studied and the general population. In order to educate individuals of all socioeconomic statuses, the knowledge could potentially be transmitted as a public service campaign. As the general population becomes more aware about skin cancer risk factors and sun safety practices, the prevalence of this form of cancer should decrease.

REFERENCES

1. Centers for Disease Control and Prevention, National Center for Health Statistics. UV Exposure and Sun Protective Practices. National Health Interview Survey NCI and CDC Co-sponsored Cancer Control Supplement, 1992-2010, 2005-2010. progressreport.cancer.gov/sun_protection. Accessed June 15, 2016.
2. US Cancer Statistics Working Group. United States Cancer Statistics: 1999-2012 Incidence and Mortality. Web-based report. Atlanta, GA: Centers for Disease Control and Prevention; 2015. cdc.gov/uscs. Accessed June 9, 2016.
3. US Department of Health and Human Services. The Surgeon General's Call to Action to Prevent Skin Cancer. Washington, DC: US Department of Health and Human Services, Office of the Surgeon General; 2014. surgeongeneral.gov/library/calls/prevent-skin-cancer/call-to-action-prevent-skin-cancer.pdf. Accessed June 12, 2016.
4. Lin JS, Eder M, Weinmann S. Behavioral counseling to prevent skin cancer: a systematic review for the U.S. Preventive Services Task Force. Ann Intern Med. 2011;154:190-201.
5. Moyer VA, U.S. Preventive Services Task Force. Behavioral counseling to prevent skin cancer: U.S. Preventive Services Task Force recommendation statement. *Ann Intern Med.* 2012;157:59-65.
6. U.S. Preventive Services Task Force. Behavioral counseling to prevent skin cancer: U.S. Preventive Services Task Force recommendation statement website. http://www.uspreventiveservicestaskforce.org/uspstf11/skincancouns/skincancounsrs.htm. Accessed May 16, 2013.
7. Wells KB, Lewis CE, Leake B, Ware JE Jr. Do physicians preach what they practice? a study of physician's health habits and counseling practices. JAMA 1984;2522846-2848.
8. Dusza SW, Halpern AC, Statagopan JM, Oliveria SA, Weinstock MA, Scope A, et al. Prospective study of sunburn and sun behavior patterns during adolescence. Pediatrics. 2012;129:309-17.
9. Guy GP Jr, Machlin SR, Ekwueme DU, Yabroff KR. Prevalence and costs of skin cancer treatment in the US, 2002-2006 and 2007-2010. Am J Prev Med. 2015;48;183-7.
10. Jemal A, Saraiya M, Patel P, Cherala SS, Barnholtz-Sloan J, Kim J, et al. Recent trends in cutaneous melanoma incidence and death rates in the United States, 1992-2006. J Am Acad Dermatol. 2011;65(5 suppl 1):S17.e01-S17.e11.
11. Lomas A, Leonardi-Bee J, Bath-Hextall F. A systematic review of worldwide incidence of nonmelanoma skin cancer. Br J Dermatol. 2012;166:1069-80.
12. Machlin S, Carper K, Kashihara D. Health care expenditures for non-melanoma skin cancer among adults, 2005–2008 (average annual). Statistical Brief #345. Rockville, MD: Agency for Healthcare Research and Quality; 2011. http://www.meps.ahrq.gov/mepsweb/data_files/publications/st345/stat345.shtml. Accessed January 16, 2014.
13. Stern RS. Prevalence of a history of skin cancer in 2007: results of an incidence-based model. Arch Dermatol. 2010;146:279-82.
14. Balk SJ, Council on Environmental Health, Section on Dermatology. Ultraviolet radiation: a hazard to children and adolescents. Pediatrics. 2011;127:e791-e817.
15. Community Preventive Services Task Force. Preventing Skin Cancer: Education and Policy Approaches. thecommunityguide.org/cancer/skin/education-policy/index.html. Accessed June 2, 2016.

Source of Support: Nil, **Conflict of Interest:** None declared.

Our Dermatology Online

Original Article

A study of knowledge, attitude and practices regarding hair dye use among general population

Mrinal Gupta

Department of Dermatology, Treatwell Skin Centre, Jammu and Kashmir, India

Corresponding author: Dr. Mrinal Gupta, E-mail: drmrinalgupta@yahoo.com

ABSTRACT

Background: Hair dye usage is extremely common all over the world. Hair dyes have been reported to cause a wide range of adverse effects, therefore, the consumer's knowledge about hair dyeing and related side effects are important. **Aim:** To assess the knowledge, attitude and practices of general population towards the use of hair dyes. **Materials and Methods:** Two hundred and fifty consecutive persons using hair dyes were enrolled for this questionnaire-based cross-sectional, descriptive study. **Results:** These 250 patients comprised 141 men (56.4%) and 109 women (43.6%) (M: F 1.29:1), aged between 16 and 74 (mean 47.13) years. The majority, 212 patients (84.8%) were aged between 20–60 years and 66.4% (n=166) belonged to an urban background. When asked about the reason for using hair color, the principle reason was "to look younger" (59.6%, n=149). Most of the respondents were using synthetic hair dye preparations (55.2%, n=138) and when asked about the brand of hair dye being used, 25.2% (n=63) did not know about the brand they were using. When asked about their perception regarding safety of HD, 61% (n=152) respondents agreed that hair dyes are not safe and on being asked about the carcinogenic potential of HD, only 24% (n=60) respondents agreed. When enquired about the safest variety of HD, majority of respondents (52.4%, n=131) believed that plant based hair colors are the safest. When asked about the safety of HD during pregnancy and lactation, 68% (n=168) of the respondents were unaware regarding this aspect. 14.4% of the respondents reported suffering from some adverse effects due to hair dye use but only 11.11% (n=4) of those stopped using hair dyes. **Conclusions:** There is lack of awareness about the hair dyes and their adverse effects in the general population. There is an urgent need to increase awareness among consumers regarding the adverse effects of hair dyes and the available safer alternatives. **Limitations:** Small number of respondents and the use of a convenience sample, which might not be representative of the whole community.

Key words: Hair dye; PPD; Cosmetic dermatitis; Contact dermatitis; Hair colors; PPD sensitization

INTRODUCTION

Hair dyes (HD) are perhaps among the most commonly used cosmetics by elderly and the young alike - for concealing gray hair by the former or just for a fashion statement by the latter. The popularity of hair coloring can be gauged from the fact that the median age for debut was 16 years and nearly 75% of women and 18% of men had dyed their hair at some point in their lives according to a Danish population-based study [1]. This rising trend of hair coloring has resulted in an increased prevalence of hair dye-associated adverse effects, which vary from mild contact dermatitis localized to one body site (hand dermatitis) or disseminated generalized dermatitis to severe life threatening complications such as contact urticaria/angioedema, rhinitis/bronchospasm/asthma, and renal toxicity [2,3].

Adequate knowledge and accurate information about hair dye usage and its adverse effects are important for the general population. Identification of correlates of poor knowledge, casual attitude, and wrong perceptions among the hair dye users will help in reducing the prevalence of hair dye associated complications. However, there is a paucity of literature on the level of knowledge, attitude, and perceptions of general

How to cite this article: Gupta M. A study of knowledge, attitude and practices regarding hair dye use among general population. Our Dermatol Online. 2017;9(1):15-18.

Submission: 17.12.2016; **Acceptance:** 10.03.2017

DOI: 10.7241/ourd.20181.4

population toward hair dye usage. This study assesses the knowledge, attitude, and perceptions of general population towards hair dyes attending a dermatology outpatient clinic.

MATERIALS AND METHODS

All patients using hair dyes, attending outpatient dermatology clinic during October 2015 to September 2016 were enrolled for this questionnaire based, cross-sectional, descriptive study. Children aged <14 years and severely ill patients were excluded from the study owing to their inability to comprehend or respond to the questionnaire. After informed written consent and assuring confidentiality, they were asked to answer a predesigned, structured questionnaire in their native language. The questionnaire had two parts with the first section for their sociodemographic details and the second section comprised questions aimed at assessing their knowledge, attitude, and perception towards hair dyes.

RESULTS

These 250 patients comprised 141 men (56.4%) and 109 women (43.6%) (M: F 1.29:1), aged between 16 and 74 (mean 47.13) years. Their baseline demographic features are shown in Table 1. The majority, 212 patients (84.8%) were aged between 20–60 years and 66.4% (n=166) of the study group belonged to an urban background. Most subjects (48.4%, n=121) started coloring their hair after 40 years of age, with the median age being 43.7 years (Table 2). When asked about the reason for using hair color, the principle reasons were "to look younger" (59.6%, n=149), "as a fashion statement" (20.4%, n= 51) and "recommendation by others" (10.8%, n= 27). On the brand of hair dye being used, a sizeable minority (25.2%, n=63) did not know about the brand they were using. Most of the respondents were using synthetic hair dye preparations (55.2%, n=138) but a large proportion of the study group reported using herbal/plant based hair coloring products (44.8%, n=112). When questioned on the frequency of HD use, 48% (n=120) indicated that they did so more than 6 times in a year and when asked about the interval between two consecutive HD applications, their answers ranged from 15 days to 24 months (mean - 3.73 months).

Table 1: Baseline characteristics of the study population

Baseline characteristics of the patients studied	Total number of patients (n=250)
Gender (male: female)	141:109
Age (years)	
Range (mean)	16-74 (47.13)
<20 yrs	14 (5.6%)
20-39 yrs	84 (33.6%)
40-59 yrs	128 (51.2%)
>60 yrs	24 (9.6%)
Social background	
Urban	166 (66.4%)
Rural	84 (33.6%)
Duration of hair dye use	
Range (mean)	2 months- 28 years (7.43 years)
Frequency of hair dye use	
Once a year	56 (22.4%)
2-6 times/year	74 (29.6%)
>6 times/year	120 (48%)
Reason for using hair dye	
To appear younger	149 (59.6%)
As a fashion statement	51 (20.4%)
Recommended by others	27 (10.8%)
Others	23 (9.2%)

Analysis of the questionnaire (Table 2) revealed that 61% (n=152) respondents agree that hair dyes are not safe. On being asked about the carcinogenic potential of HD, only 24% (n=60) respondents agreed. When enquired about the safest variety of HD, majority of respondents (52.4%, n=131) believed that plant based hair colors are the safest. When asked about the safety of HD during pregnancy and lactation, 67% (n=168) of the respondents were unaware regarding this aspect. When the participants were asked if they performed an allergy test before using a new HD, only 6% (n=15) reported that they did so before using a new hair coloring product and only 29% (n=73) respondents said that they read the application instructions before applying the product. When enquired about the adverse effects, 36 respondents (14.4%) reported adverse effects with the use of HD. The most common adverse effect was itching, followed by erythema and swelling. From the 36 respondents who experienced side effects, only 12 (33.3%) visited a medical provider for treatment. When enquired regarding the reasons for not visiting a medical provider, 19 (52.77%) answered that the adverse effects were not severe, while the others considered them as part of hair dyeing (11.1%, n=4) or did some self-medication for the same (2.77%, n=1). Despite the adverse effects, only 4 patients (11.1%) stopped using hair dyes, 7 (19.44%) changed the product while the remainder persisted with the same hair coloring agent.

DISCUSSION

The use of hair colorants has increased exponentially over the last few decades due to increased societal pressure and changing fashion trends. Over the years,

Table 2 : Results of questionnaire on hair dye related knowledge, attitude, and perception

Questions	n=150 (%)		
	Yes	No	No answer/don't know
1. Are the hair dyes safe?	35 (14)	152 (60.8)	63 (25.2)
2. Can hair dyes cause cancer?	60 (24)	48 (19.2)	142 (56.8)
3. Can hair dyes be used during pregnancy and lactation?	31 (12.4)	51 (20.4)	168 (67.2)
4. Which are the safest type of hair dyes			
• Synthetic	44 (17.6)		
• Plant based/herbal	131 (52.4)		
• Don't know	75 (30)		
5. Do you perform allergy testing before using hair dye?	15 (6)	149 (59.6)	86 (34.4)
6. Do you read the instruction manual before using hair dye?	73 (29.2)	109 (43.6)	68 (27.2)
7. Have you ever experienced any adverse effect with hair dye use?	36 (14.4)	187 (74.8)	27 (10.8)
a. If yes, did you consult a medical practitioner for the same?	12/36 (33.3)	22/36 (61.11)	2 (5.55)
8. Are you still using hair dye even after experiencing side effects?	31/36 (86.11)	4/36 (11.11)	1/36 (2.77)

the coloring agents have diversified in nature with the arrival of oxidative hair dyes that include many synthetic and natural agents. This rising trend of hair coloring has resulted in an increased prevalence of hair dye associated adverse effects [4]. The safety of hair dyes is being under continuous surveillance for the last many years. Hair dyes include a variety of coloring agents such as 2,7-naphthalenediol, 2 - aminomethyl-*p* aminophenol hydrochloride, 2-chloro-*p*-phenylenediamine and *p*-phenylenediamine which have been implicated in the etiology of various disorders [5]. Numerous researchers have reported life threatening adverse effects like renal toxicity and angioedema with their use apart from allergic contact dermatitis, whereas, a few studies have also linked hair dye use with the development of certain malignancies. The most common cutaneous adverse effects include contact dermatitis localized to sites of contact or photoexposed skin, periorbital dermatitis, airborne contact dermatitis, hand dermatitis and disseminated eczema [6]. Keeping in view, the numerous health hazards associated with the use of HD, it becomes important that the general population should be well aware of the various aspects of HD usage and their associated adverse effects. Therefore, we tried to assess the public's knowledge, attitudes, and practices towards HD.

In today's world, the desire to look younger is widespread which is being reinforced everyday by the media and the social media. Many people do not want graying hair and they seek hair dyeing products to cover it. This is supported by our survey responses that most respondents said they color their hair to look younger. The prevalence of HD usage can be gauged from the fact that more than 50% of women in the industrial world use HDs [7]. The median age of starting hair dye use is also becoming younger with the median age at first hair dyeing being 16 years in a Danish study, 22 years in a study from middle-east, and 27 years in an Indian study but in our study group, the median age was 38.7 years indicating that HD use is not extremely high among teenagers and young adults in our society [1,8,9]. A large number of respondents in our study did not know the hair color brand which they were using, and majority was unaware of the allergy testing before application and the application instructions. In a study by Kim *et al*, 73% of the respondents were unaware of the hair color brand they were using [10].

A large proportion of population in our study group believed that hair dyes are harmful, while in a study by Al Ghamdi *et al*, 52% respondents were aware of the harms of hair dyes [8]. In our study, 36 respondents (14.4%) reported adverse effects with the use of hair dyes which is higher than the prevalence rate of 5.2% in a Danish study but lesser than the 42% prevalence rate reported in an Indian study [1,10]. Despite the experience of side effects, most of the people (32 out of 36) continued hair dyeing. Furthermore, only a small portion of the respondents (12 out of 36) who experienced side effects visited a medical practitioner for treatment as the others considered the adverse effects to be minor or considered them as a part of hair dyeing.

There are very few studies concerning HD use during human pregnancy [11]. Animal studies have shown that doses 100 times higher than the dose normally used in human application did not produce significant changes in fetal development. But low levels of HD can be absorbed through the skin after application, which does not cause a developmental problem to the fetus [12,13]. However, the use of HDs during pregnancy is not recommended and might be associated with future health problems in children [14]. The lack of knowledge regarding the adverse effects of HD and their safety profile during pregnancy and lactation in a majority of respondents in our study indicates the lack of knowledge and awareness regarding HD in our population.

Limitations

Our study had certain limitations also. The small number of respondents and the use of a convenience sample might not be representative of the whole community.

CONCLUSIONS

There is lack of awareness about the hair dyes and their adverse effects in the general population. There is an urgent need to increase awareness among consumers regarding the adverse effects of hair dyes, the available safer alternatives, and the significance of performing sensitivity testing prior to actual use, in adherence of usage instructions. It is also desirable that manufacturers print directions in bold text over the product package regarding safe use of the hair dye.

REFERENCES

1. Søsted H, Hesse U, Menné T, Andersen KE, Johansen JD, Sosted H, *et al*. Contact dermatitis to hair dyes in an adult Danish population-An interview-based study. Br J Dermatol. 2005;153:132-5.
2. Helaskoski E, Suojalehto H, Virtanen H, Airaksinen L, Kuuliala O, Aalto-Korte K, *et al*. Occupational asthma, rhinitis, and contact urticaria caused by oxidative hair dyes in hairdressers. Ann Allergy Asthma Immunol. 2014;112:46-52.
3. Fukunaga T, Kawagoe R, Hozumi H, Kanzaki T. Contact anaphylaxis due to para-phenylenediamine. Contact Dermatitis. 1996;35:185-6.
4. Uter W, Lessmann H, Geier J, Schnuch A. Contact allergy to ingredients of hair cosmetics in female hairdressers and clients-an 8-year analysis of IVDK data. Contact Dermatitis. 2003;49:236-40.
5. Sosted H, Basketter DA, Estrada E, Johansen JD, Patlewicz GY. Ranking of hair dye substances according to predicted sensitization potency-quantitative structure-activity relationships. Contact Dermatitis. 2004;51:241-54.
6. Gupta M, Mahajan VK, Mehta KS, Chauhan PS. Hair dye dermatitis and p-phenylenediamine contact sensitivity: A preliminary report. Indian Dermatol Online J. 2015;6:241-5.
7. Søsted H, Rastogi SC, Andersen KE, Johansen JD, Menné T. Hair dye contact allergy: Quantitative exposure assessment of selected products and clinical cases. Contact Dermatitis. 2004;50:344-8.
8. AlGhamdi KM, Moussa NA. Knowledge and practices of, and attitudes towards, the use of hair dyes among females visiting a teaching hospital in Riyadh, Saudi Arabia. Ann Saudi Med. 2011;31:613-9.
9. Patel D, Narayana S, Krishnaswamy B. Trends in use of hair dye: A cross-sectional study. Int J Trichol. 2013;5:140-3.
10. Kim JE, Jung HD, Kang H. A Survey of the Awareness, Knowledge and Behavior of Hair Dye Use in a Korean Population with Gray Hair. Ann Dermatol. 2012;24:274-9.
11. Blackmore-Prince C, Harlow SD, Gargiullo P, Lee MA, Savitz DA. Chemical hair treatments and adverse pregnancy outcome among Black women in central North Carolina. Am J Epidemiol. 1999;149:712-6.
12. DiNardo JC, Picciano JC, Schnetzinger RW, Morris WE, Wolf BA, *et al*. Teratological assessment of five oxidative hair dyes in the rat. Toxicol Appl Pharmacol. 1985;78:163-6.
13. Burnett C, Goldenthal EI, Harris SB, Wazeter FX, Strausburg J, Kapp R, *et al*. Teratology and percutaneous toxicity studies on hair dyes. J Toxicol Environ Health. 1976;1:1027-40.
14. McCall EE, Olshan AF, Daniels JL. Maternal hair dye use and risk of neuroblastoma in offspring. Cancer Causes Control. 2005;16:743-8.

Source of Support: Nil, **Conflict of Interest:** None declared.

Brief Report

Skin pathology of the elderly patients: Case of black African

Almamy Diabaté[1], Hamdan Sarah Kourouma[2], Bamba Vagamon[1], Irené Gué[1], Mamadou Kaloga[2], Boussou Romain Aka[1]

[1]Dermatology Department, University Teaching Hospital, Bouaké, Côte d'Ivoire, [2]Dermatology Department, University Teaching Hospital of Treichville, Abidjan, Côte d'Ivoire

Corresponding author: Dr. Almamy Diabaté, E-mail: docalmamy@yahoo.fr

ABSTRACT

Background: Skin diseases of the elderly subjects have clinical signs which are different from those of the young people. The purpose of this study was to determine the skin diseases that led elderly people to consult at the Department of Dermatology at the University Teaching Hospital in Bouaké, Côte d'Ivoire. **Methods:** That was a descriptive cross-sectional study conducting between January 1, 2015 and December 31, 2015 and including patients 65 years and older who were diagnosed with skin diseases the Department of Dermatology at the University Teaching Hospital in Bouaké, Côte d'Ivoire. **Results:** During the study period, 109 patients aged 65 years and older (1.8%) were recruited. These patients consulted for 227 diagnoses. The average age of the patients was 71.8 and sex ratio was 0.7. Mycoses were the major reason for consultation (18.7%) followed by pruritus (17.9%), eczema (13.1%), and (9.0%) tumors with 76.5% of benign tumors and (5.1%) disorders of keratinization. Leg ulcers were 2.1%. Mycoses were represented by intertrigo (52.9%) and dermatomycosis of the glabrous skin (25.7%). Kaposi sarcoma and keloid were the most frequent tumors. **Conclusion:** Our study shows a predominance of mycosis, eczema, and pruritus in the elderly subjects. Mycoses and pruritus could result from the weather and the skin aging, respectively.

Key words: Cutaneous pathology; Elderly; Bouaké

INTRODUCTION

Skin pathologies of the elderly subjects are varied and display diagnosis, management, and follow-up issues [1]. Their symptomatology differs from that of the young subjects [2]. Several studies have been done in many countries to determine the profile of these disorders in the elderly [3-6]; however, the skin diseases of aged patients were undocumented in Côte d'Ivoire. The purpose of this study was to describe the features of cutaneous pathology in the elderly patients at the Department of Dermatology in Bouaké, Côte d'Ivoire.

PATIENTS AND METHODS

A transversal and multicenter study was conducted between January 2014 and December 2015 at the Department of Dermatology of the University Teaching Hospital in Bouaké. This study included patients 65 years and older who presented dermatologic conditions. Dermatologists collected the data based on age, sex, duration of evolution of the cutaneous pathology before the consultation and the new diagnoses of each patient. Patients gave the written consent. All data were analysed by Epi Info 3.5.1.

RESULTS

During the study period, 109 (1.8%) out of 6055 patients who consulted for 227 diagnoses and were aged 65 years and over. The mean age of the patients were 71.8±6.5 years old with extremes: 65-95 years. The peak age was between 65 and 74 years with 68.7%. Among 109 patients, 46 were male and 63 were female with a sex ratio of 0.7. The female predominance was found in all age groups. The Table 1 summarizes the cutaneous pathologies. Mycoses were the most frequent infectious skin diseases and all skin diseases, affecting

How to cite this article: Diabaté A, Kourouma HS, Vagamon B, Gué I, Kaloga M, Aka BR. Skin pathology of the elderly patients: Case of black African. Our Dermatol Online. 2018;9(1):19-21.

Submission: 28.06.2017; **Acceptance:** 29.08.2017

DOI: 10.7241/ourd.20181.5

more female than male. The intertrigos (41.7%) were predominant followed by the onychomycoses (31.4%), and the dermatomycoses of the glabrous skin (15.7%). Bacterial skin diseases were prevalent in female (sex ratio:1.7) and represented by pyodermitis (75%) and erysipelas (25%). The most common viral dermatosis was shingles (68.8%) which was 2.9% of all skin diseases. 12 cases of parasitic skin diseases were scabies. Senile pruritus (36 cases) associated cutaneous xerosis (14) was found. The isolated skin xerosis was identified in 6 cases. The eczema and the urticaria were diagnosed in 19 cases and in 6 cases, respectively. Our study reported 23 cases of tumors: the benign tumors were keloid (32.7%), cyst (23.1%), and mollusca pendulum (8.5%) and the malignant tumor was Kaposi sarcoma (1.9%), melanoma (0,8%), and squamous cell carcinoma (0,4%). Palmoplantar keratodermia (25%) was the most common keratinization disorder while vitiligo (75%) was frequent in pigmentary disorders. Out of 8 cases of toxidermia, 7 cases were fixed pigmented erythema and 1 case of toxic epidermal necrolysis. Leg ulcers were predominant in male and occurred since 5 years. The connectivities were represented by 2 cases of discoid lupus and 1 case of scleroderma. 4 cases of autoimmune bullous dermatoses were consisted bullous pemphigoid (3 cases) and vulgar pemphigus (1case).

Table 1: Dermatoses reported in our series

	Number of cases (%)
Infectious dermatoses	79 (34.8)
Fungal dermatoses	48 (21.1)
Bacterial dermatoses	17 (7.5)
Viral dermatoses	8 (3.5)
Parasitic dermatoses	6 (2.6)
Pruritus	36 (15.9)
Tumors	23 (10.1)
Benign tumors	17 (7.5)
Malignant tumors	6 (2.6)
Palmoplantar hyperkeratosis	25 (11)
Eczema	19 (8.4)
Cutaneous xerosis	14 (6.1)
Leg ulcer	8 (3.5)
Toxidermia	8 (3.5)
Urticaria	6 (2.6)
Autoimmune bullous Dermatoses	4 (1.8)
Connectivity	3 (1.3)
Total	227 (100)

DISCUSSION

In this study, the major reasons for consultation of the elderly were chronic pathological conditions. The small sample size of our population was the limitation of study. Therefore, we cannot extrapolate our results to all seniors in the city of Bouake and in the country. The issues of affordability of people in care could explain the small number of patients admitted at the hospital during the study period.

Interestingly, because of socio-economic, cultural, and health context and mildness of some skin diseases, people would undergo traditional treatments or self-medication. Despite these limitations, this study has documented the main reasons of consultations of the elderly. In our study, the proportion of the elderly was lower than that reported in Tunisia [3,4] and in Taiwan [5]. These results can be explained by the relative short life expectancy related to poverty and deficient health systems in Subsaharan Africa. In Ivory Coast, the rate of the elderly people was 3.9% of the population in 2014. Pitché et al. have identified significant difference between skin disorders in the elderly individuals and those in the general population. They revealed that mycosis, eczema, and pruritus were frequent in while eczema, mycosis, and the acne were the most occurring in the general population [7].

The high frequency of pruritus in the elderly is related to their age, their skin aging, and the xerosis. However, acne is a skin disease occurring in adolescents, and thus, representing the third reason of consultation in the youth who predominates in the general population.

Mycosis followed by eczema was the most common reason of consultation in the elderly in Tunisia as in our study [3,4] compared with the Western countries where eczema followed by tumors were the most prevalent (Table 2). The climatic factors such as heat and humidity could be explain the high rate of mycoses in Africa.

The low value of malignant tumors in our study is discordant with several studies [3-5,8-10]. This

Table 2: Common dermatoses of the elderly in our series

	Our study Bouaké	Tunisia Sfax [4]	Croatia Karlovac [8]	Canada Ottawa [9]	USA New York [10]
Mycosis (%)	21.1	16	6.81	3.4	4.5
Eczema (%)	8.4	12	7.30	16.3	37.9
Pruritus (%)	15.9	4.2	6.20	1.2	1.8
BT* (%)	7.5	14.7	18.98	13.8	11.5
MT** (%)	2.6	12.3	9.37	12.6	9.0

*BT: Benign tumor, **MT: Malignant tumor

difference is due to genetically pigmented skin of our patients whose dense epidermal melanin protects them from ultraviolet radiation [11], and therefore, preventing them from skin cancers. In the present study, Kaposi sarcoma was the most common cancer which is similar to that of several Subsaharian African studies [12,13] and different from that of developed country studies in which basal cell carcinoma was the most prevalent [3-5].

This unusual frequency of the Kaposi sarcoma results from the increase of HIV prevalence in Africa [14]. Among benign tumors, keloids were predominant in our study compared to other studies where cysts or seborrheic keratoses were frequent [3].

CONCLUSION

This study shows a small proportion of the elderly subjects 65 years and older at the Dermatology Department in Bouaké. Cutaneous mycoses are the most common skin diseases in these patients in Africa. The most occurring mycoses could be due to the heat and the humidity.

REFERENCES

1. Farage MA, Miller KW, Berardesca E, Maibach HI. Clinical implications of aging skin: cutaneous disorders in the elderly. Am J Clin Dermatol. 2009;10:73–86.
2. Jafferany M, Huynh TV, Silverman MA, Zaidi Z. Geriatric dermatoses: a clinical review of skin diseases in an aging population. Int J Dermatol. 2012;51:509–2.
3. Souissi A, Zeglaoui F, El Fekih N, Fazaa B, Zouari B, Kamoun MR. Pathologie cutanée chez le sujet âgé: Etude multicentrique tunisienne. Ann Dermatol Venereol. 2006;133:231–4.
4. Mseddi M, Borgi N, Sellami L, Meziou TJ, Turki H, Zahaf A. Pathologie cutanée du sujet âgé en dermatologie. Ann Dermatol Venereol. 2006;133:272–4.
5. Liao YH, Chen KH, Tseng MP, Sun CC. Pattern of skin diseases in a geriatric patient group in Taiwan: a 7-year survey from the outpatient clinic of a university medical center. Dermatology. 2001;203:308-13.
6. Yalçin B, Tamer E, Toy GG, Oztas P, Hayran M, Alli N. The prevalence of skin diseases in the elderly: analysis of 4099 geriatric patients. Int J Dermatol. 2006;45:672–6.
7. Pitché P, Tchamdja S, Amanga Y, Tchangaï-Walla K. Pathologies dermatologiques en consultation hospitalière à Lomé (Togo). Nouv Dermatol. 1997;16:369–73.
8. Cvitanovic H, Knezevic E, Kuljanac I, Jancic E. Skin disease in a geriatric patients group in outpatient dermatologic clinic Karlovac, Croatia. Coll Antropol. 2010;34(Suppl 2):247–51.
9. Adam JE. The prevalence of skin disorders in geriatric age group. Australas J Dermatol. 1987;28:72–6.
10. Young AW. Dermatologic complaint presented by 330 geriatric patients. Geriatrics. 1958;13:428–34.
11. Alam M, Ratner D. Cutaneous squamous cell carcinoma. N Engl J Med. 2001;344:975–83.
12. Asuquo ME, Ebughe G. Cutaneous cancers in Calabar, Southern Nigeria. Dermatol Online J. 2009;15:11.
13. Saka B, Souley Z, Kombaté K, Mouhari-Toure A, Akakpo S, Napo-Koura G, et al. Les cancers cutanés au Togo: étude de 223 observations. Med Trop. 2010;70:169–71.
14. ONUSIDA. Genève: ONUSIDA; 2010. Rapport sur l'épidémie mondiale de VIH/sida, 2010; p. 364.

Source of Support: Nil, **Conflict of Interest:** None declared.

Brief Report

Kefir and champagne vinegar to defeat bacterial vaginosis in woman, avoiding oral metronidazole, clindamycin and bothersome douchings

Piotr Brzezinski[1,2], Lorenzo Martini[3]

[1]Institute of Biology and Environmental Protection, Pomeranian Academy, ul. Arciszewskiego 22A, 76-200 Slupsk, Poland, [2]Department of Dermatology, 6th Military Support Unit, Ustka, Poland, [3]Department of Pharmaceutical Biotechmologies, University of Siena, Siena , Italy

Corresponding author: Lorenzo Martini, E-mail: martinil163@libero.it

ABSTRACT

Scope ouf our study is to treat with natural remedies vaginitis in woman, when it has been detected the disease originates from bacterical assault (*Gardnerella vaginalis* and/or *Streptococca spp.*) in order to avoid the administration of perilous antibiotics and elicit sexual desire and eliminate pain during urination in the woman who has suffered from this disease after 4-5 days only. We have to proceed with the preliminary phase of a simplest test (the ammin whiff test) and determine the type of vaginitis and thus treat it using champagne or cider vinegar to adjust mucosal pH and kefir, a fermented beverage, that is extremely rich in mesophyllic bacteria, apt to reveal an important and suggestive function regard vaginal microbes.

Key words: Vaginitis; Vulva; Kefir; Gardnerella vaginalis; Champagne vinegar

INTRODUCTION

Vaginitis is an inflammation of the vagina and possible vulva It can result in discharge, itching and pain, and is often associated with an irritation or infection of the vulva. Infected women may also be asymptomatic.

It is usually due to infection. The three main kinds of vaginitis are bacterial vaginosis (BV), vaginal candidiasis, and trichomoniasis. A woman may have a combination of vaginal infections at one time.

Bacterial vaginosis is generally sustained by gardnerella vaginalis and it is preferable to individuate if the woman who suffers from vaginitis, has this infection instead of fungal assaults, in order to treat the disease by the best and more rapid way and to avoid to administer to her antimycotics instead of antibiotics and vice versa and moreover, to trace the best path to cure the malaise owing to natural medicaments.

Gardnerella is treated commonly by metronidazole [1] clindamycin [2-4].

Now it is well acquainted that amongst the manifold side effects given by metronidazole, the most common are numbered in Box 1.

And amongst the side effects given by assumption of clindamycin, these are the most severe (Box 2).

A recent paper [5] asserts that in case of aggression of gardnerella or other microbiota typical of vaginosis, the physiological production of lactic acid and other short chain fatty acids, apt to mantain pH 4,5 (optimal for combating the occurrence of yeasts or bacterial infections in vagina and vulva), decreases abruptely or goes to end.

These bacteria are able, indded, to produce long chain fatty acids, as acetates, propionates, butyrates, and succinates.

How to cite this article: Brzezinski P, Martini L. Kefir and champagne vinegar to defeat bacterial vaginosis in woman, avoiding oral metronidazole, clindamycin and bothersome douchings. Our Dermatol Online. 2018;9(1):22-24.

Submission: 09.06.2017; **Acceptance:** 12.09.2017

DOI: 10.7241/ourd.20181.6

Box 1: The side effects by metronidazole

numbness or tingling in hands or feet;
white patches or sores inside mouth or on lips;
pain or burning when urinating;
diarrhea that is watery or bloody;
vision problems, pain behind eyes;
trouble concentrating, slurred speech, mood or behavior changes, tremors, muscle twitching, seizure (convulsions);
fever, chills, muscle pain, confusion, headache, sore throat, neck stiffness, increased sensitivity to light, drowsiness, nausea and vomiting; or
severe skin reaction -- fever, sore throat, swelling in your face or tongue, burning in eyes, skin pain, followed by a red or purple skin rash that spreads (especially in the face or upper body) and causes blistering and peeling.

Box 2: The side effects by clindamycin

abdominal or stomach cramps, pain, or tenderness	heartburn
bleeding gums	loss of appetite
blistering, peeling, or loosening of the skin	pain during sexual intercourse
blood in the urine or stools	painful or difficult urination
blurred vision	pinpoint red spots on the skin
chest pain	redness of the skin
cough or hoarseness	shortness of breath
dark urine	sore throat
decrease in the amount of urine	sores, ulcers, or white spots in the mouth or on the lips
diarrhea	swollen glands
dry mouth	thick, white vaginal discharge with no odor or with a mild odor
fast heartbeat	unpleasant breath odor
fever with or without chills	bleeding or bruising
general feeling of tiredness or weakness	unusual weight loss
headache	yellow eyes or skin.

A simplest method to distinguish if the vaginitis is originated by bacterial aggressions or fungal assaults is the ammin whiff test, that is used to determine the quantity of gardnerella vaginalis in order to adjust the dosage of antibiotics, and in the preliminary phase, during the preparation of the kit, and using a 10% KOH solution, a strong fragrance of fish comes out and this is the indisputable sign of presence of these bacteria and/or *Streptococca spp* and the presence or co-presence of fungi or Trichomoniasis is exorcised at all.

Other discovered too that mesophyllic bacteria are able to oxidate octanoates at temperatures comprised between 7.5°C and 40°C, this fact signifies that mesophyllic bacteria are capable to denature vaginal commensal bacteria [6].

Kefir is a fermented milk drink that originated in the north Caucasus Mountains made with kefir "grains", a yeast/bacterial fermentation starter.It is prepared by inoculating cow, goat, or sheep milk with kefir grains [7] and moreover these grains called kefiran contain bacterial colonies especially mesophyllic living symbiotically with yeasts.

An acidic milieu (below 4.5) must be reached and naturally speaking the best way is to cleanse vagina with douche containing pure cider vinegar, or to insert a cotton ball soaked in cider or champagne vinegar and let it stay all through the night inside vagina.

Kefir must be spread as a liquid emulsion every time the woman has urinated and washed with lukewarm water and savon de marseille (that shows a mild antibacterial function too).

Kefir must be kept in fridge, for this, the woman had to keep the beverage in fidge at home (or even at work).

Applications were 6-7 pro day.

MATERIALS AND METHODS

We have recruited a woman (27 y. old) who had declared to feel a severe annoyance during urinating, perpetual itching during day and night in her vagina and vulva.

She was very embarassed when she was at work or spent her time in social occasions.

She was sure not to suffer or have suffered from Candida albicans since the Candida anti-body blood test was negative, she has always avoided high sugar diet, never taken antibiotics, did not suffer from chronic stress, did not assume contraceptive pill, and did not have diabetes.

She used to wear banana hammock, even she used to wash it almost three times pro week.She has thought she had mistaken the usage of the detergent for washing her intime underwear.

First of all, we have effectuated the ammine whiff test (only the preliminary phase) and we assayed the penetrating fish odour pouring a KOH 10% solution directly in her discharge, but we identified by electronic microscope even the presence of Gardnerella and Streptococca spp.

We began the experimentations following this schedule:

the volunteer had to insert a cotton ball (as it were a normal vaginal swab) all the night long for five nights, almost 7-8 hours.

During the day, she had to spread kefir (kept in cool) every time she had urinated.

Table 1: Responses of ammin whiff tests effectuated every day for five days

Number of day of treatment	Response to whiff test
1	+
2	+
3	-
4	-
5	-

+ stands for positive, and thus positive reaction to ammin whiff test, – stands for negative, idest no malodour comes out from whiff test

Table 2: Sensation of itching during the treatment of five days.

Number of day of treatment	Feeling of itching referred from the volunteer
1	a
2	b
3	d
4	e
5	e

a) Itching during day and night; b) Itching only during the day; c) Itching only after urinated; d) Mild itching through all the day, but tolerable; e) Absence of itching

RESULTS

From Table 1 it is possible to observe that after the second day discharge and unpleasant odour (simply adding KOH solution to her urine at the mornig) disappeared at all.

From Table 2 it is possible to behold the feeling of itching, according to a conventional scale:

a) Itching during day and night
b) Itching only during the day
c) Itching only after urinated
d) Mild itching through all the day, but tolerable
e) Absence of itching

DISCUSSIONS AND CONCLUSIONS

It is suggestive to herald that avoiding drastic antibiotics, endowed of side effects too often risky, is possible to treat bacterial vaginosis (when the co-presence or co-presence of fungi are exorcised), a woman suffering from bacterial vaginosis, who declares pain in urinating, lack of sexual desire, extreme itching and malodorous abrupt discharges, may be treated by simplest natural remedies as champagne or cider vinegar (to be applied as a swab during the night) and spreading kefir 6-7-8 times pro day.

REFERENCES

1. Jones BM, Geary I, Alawattegama AB, Kinghorn GR, Duerden BI. In-vitro and in-vivo activity of metronidazole against Gardnerella vaginalis, Bacteroides spp. and Mobiluncus spp. in bacterial vaginosis. J Antimicrob Chemother. 1985;16:189–91.
2. Kiser CJ, Urish KL, Boateng HA. Development of Clostridium septicum gas gangrene as an adverse effect of clindamycin-induced Clostridium difficile infection in a pediatric patient. J Pediatr Orthop. 2014;34:e19-21.
3. Khan FZ. Microbial Infections in females of childbearing age and therapeutic interventions. Rawal Med J. 2011;36:178–81.
4. Ferris DG, Litaker MS, Woodward L, Mathis D, Hendrich J. Treatment of bacterial vaginosis: a comparison of oral metronidazole, metronidazole vaginal gel, and clindamycin vaginal cream. J Fam Pract. 1995;41:443–9.
5. Aldunate M, Srbinovski D, Hearps AC, Latham CF, Ramsland PA, Gugasyan R, et al. Antimicrobial and immune modulatory effects of lactic acid and short chain fatty acids produced by vaginal microbiota associated with eubiosis and bacterial vaginosis. Front Physiol. 2015;6:164.
6. Sultzer BM. Oxidative activity of psychrophilic and mesophyllic bacteria on saturated fatty acid. J Bacteriol. 1961;82:492–7.
7. Altay F, Karbancıoglu-Güler F, Daskaya-Dikmen C, Heperkan D. A review on traditional Turkish fermented non-alcoholic beverages: microbiota, fermentation process and quality characteristics. Int J Food Microbiol. 2013;167:44–56.

Source of Support: Nil, **Conflict of Interest:** None declared.

Case Report

Toxicoderma by gemcitabine: About a case

Flora López-López, Santiago Ponce, Guillermo De Velasco

Department of Medical Oncology, 12 Octubre Hospital, Madrid, Spain

Corresponding author: Dr. Guillermo De Velasco, E-mail: gdvelasco.gdv@gmail.com

ABSTRACT

Skin reactions are often related with drugs, particularly with chemotherapy. Several types of cutaneous involvement have been described from pruritus alone to generalized eruptions not always but generally related with hypersensitivity or inflammatory reactions that usually are independent of primary tumor location. Gemcitabine is a widely used chemotherapy drug that may typically produce a mild skin rash. Herein, we show a case of uncommon and severe direct skin toxicity because of gemcitabine in context of thrombocytopenia. We have also performed a review of the literature showing that this may be the first case of such toxicity.

Key words: Gemcitabine; Rash; Lung cancer

INTRODUCTION

Gemcitabine is a nucleoside analog approved for many tumor types such as bladder, breast, lung or pancreatic. Common toxicities include mild myelosuppression, increase liver enzymes and flu-like symptoms. Skin rash may occur in up to 30% of patients, though grade 3-4 is uncommon [1]. Several types of cutaneous involvement have been described from pruritus alone or generalized morbilliform eruptions [2] to scleroderma-like changes in lower extremities [2,3], generally related with hypersensitivity or inflammatory reactions.

Herein, we show a toxic skin reaction by gemcitabine associated to thrombocytopenic purpura in context of hematological toxicity grade 4 (Common Terminology Criteria for Adverse Events version 4) after first cycle of carboplatin plus gemcitabine. The patient underwent skin biopsy which confirmed diagnostic and oral steroids were given until resolution. This is an unusual case because skin reactions by gemcitabine use to be immune-mediated not for direct cutaneous toxicity and the lesions presented have a particular characteristics and distribution.

CASE REPORT

A 60-year-old white man, former smoker, was given the diagnosis of non-small cell lung cancer with squamous differentiation and liver metastasis. He started first line platinum-gemcitabine regimen. Four days after fist cycle, patient consulted at emergency room with fever and skin lesions on the chest, root of upper limbs and lower limbs slightly itchy, bilateral and symmetric without edema (Figs. 1a and 1b). He did not have other source of infection and he had not taken other drugs.

At physical examination there were no other notable findings but mild bronchospasm.

Chest X-ray did not show any infiltrates, urine was normal and blood tests showed grade 4 neutropenia and thrombocytopenia (Table 1). Empirical antibiotic therapy with amoxicillin clavulanic and ciprofloxacin was initiated. Blood transfusions and granulocyte colony-stimulating factor were also required. Dermatology took skin biopsies and patient was on systemic steroids (intravenous prednisone at doses of 0,5 mg/kg/day) with progressive resolution of the lesions. Almost complete

How to cite this article: López-López F, Ponce S, De Velasco G. Toxicoderma by gemcitabine: about a case. Our Dermatol Online. 2018;9(1):25-26.
Submission: 19.06.2017; **Acceptance:** 21.08.2017
DOI: 10.7241/ourd.20181.7

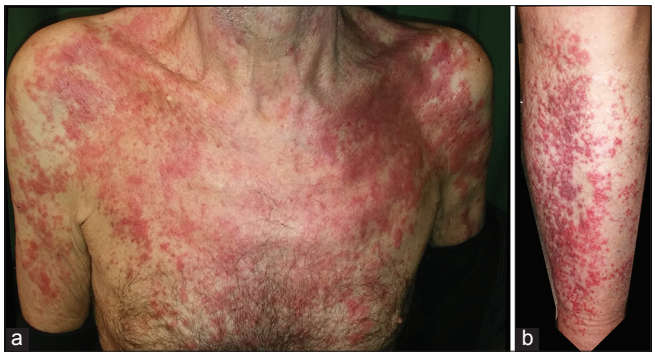

Figure 1: Chest (A) and legs (B) erythematous violets cutaneous lesions with purpuric areas grouped in palpable confluent plaques.

Table 1: Laboratory test evolution during hospitalization with treatment established

	25/12/2016	29/12/2016	02/01/2017
Creatinine	0.95 mg/dl	0.78 mg/dl	0.85 mg/dl
CRP	11.9 mg/dl	10.9 mg/dl	1.08 mg/dl
Hemoglobin	7.9 g/dl	9.4 g/dl	9.3 g/dl
Leukocytes	400/mm^3	1000/mm^3	12000/mm^3
Neutrophils	100/mm^3	400/mm^3	9100/mm^3
Monocytes	0/mm^3	200/mm^3	2000/mm^3
Platelets	18.000/mm^3	29.000/mm^3	98.000/mm^3

hematological recovery was achieved at 8 days, ending the antibiotic cycle without microbiological isolation.

The skin biopsy result and response to steroids confirmed the plausible pharmacological origin of the rash. In the absence of other new drugs, gemcitabine is the most likely responsible agent. After complete resolution of the laboratory tests, the patient was able to continue the treatment with dose adjustment and without resurgence of the rash, although he needed a slow downward steroid regimen for a month after hospitalization.

DISCUSSION

Since its approval, gemcitabine has been reported associated with a limited number of cutaneous reactions (24,8%), rash (20,3%) and urticaria or pruritus [4]. These side effects are usually mild and transient, are resolved spontaneously and rarely resulting in adjustment of the dose. The kind of lesions presented in our patient are not similar to those reported previously [5,6], because of their purpuric features and the circumscribed distribution to the thorax and lower limbs, being generalized in most cases. In this patient the coincidence with thrombopenia and febrile neutropenia is likely to distort part of the symptoms.

We think that the importance of this case is to be aware that despite the long time in use of certain antitumor drugs, there may always be toxicity not previously described that depends on the idiosyncrasy of each patient. In addition to the importance of an adequate differential diagnosis with specific tests (such as biopsy) that may help to guide the diagnosis.

REFERENCES

1. Ficha técnica de Gemcitabina On line en www.aemps.gob.es. Link descarga: https://www.aemps.gob.es/cima/pdfs/es/ft/69947/P_69947.pdf
2. Payne A, Savarese D. Cutaneous side effects of conventional chemotherapy agents. Feb 2017 UpToDate.
3. Bessis D, Guillot B, Legouffe E, Guilhou JJ. Gemcitabine-associated scleroderma-like changes of the lower extremities. J Am Acad Dermatol. 2004;51(2 Suppl):S73-6.
4. Aapro MS, Martin C, Hatty S. Gemcitabine--a safety review. Anticancer Drugs. 1998;9:191-201.
5. Kuku I, Kaya E, Sevinc A, Aydogdu I. Gemcitabine-induced erysipeloid skin lesions in a patient with malignant mesothelioma. J Eur Acad Dermatol Venereol. 2002;16:271-2.
6. D'epiro S, Salvi M, Mattozzi C, Giancristoforo S, Campoli M, Zanniello R, et al. Gemcitabine-induced extensive skin necrosis. Case Rep Med. 2012;2012:831616.

Source of Support: Nil, **Conflict of Interest:** None declared.

Our Dermatology Online

Case Report

Ecthyma gangrenosum aggravated by systemic antibiotics: A case report and literature review

Bibush Amatya[1], Rishabh Dev Tripathee[1], Rashmi Sharma[1], Leison Maharjan[2]

[1]Resident, Dermatology, Institute of Medicine, Tribhuvan University Teaching Hospital, Kathmandu, Nepal, [2]Resident, Otorhinolaryngology, Institute of Medicine, Tribhuvan University Teaching Hospital, Kathmandu, Nepal

Corresponding author: Dr. Bibush Amatya, E-mail: doc_bibush@hotmail.com

ABSTRACT

Ecthyma gangrenosum is a cutaneous manifestation of systemic infection caused predominantly by *Pseudomonas aeruginosa*. We report a case of ecthyma gangrenosum in a child caused by *P. aeruginosa* who had been previously unsuccessfully treated with systemic antibiotics. A four years old boy presented with the complaints of fever and ulcers on the trunk and extremities. He had been initiated on systemic antibiotics without sending or awaiting reports of blood and skin swab culture and sensitivity. The swab samples taken from the ulcers revealed growth of *P. aeruginosa*. He was then started on antipseudomonal intravenous antibiotics which eventually led to full recovery. Injudicious use of systemic antibiotics can lead to colonization and infection by opportunistic organisms such as *P. aeruginosa*. The use of antibiotics has to be based on reports of culture and sensitivity.

Key words: Ecthyma Gangrenosum; Vancomycin; Superinfection

INTRODUCTION

Ecthyma gangrenosum is a type of cutaneous lesion usually caused by *Pseudomonas aeruginosa* [1]. Although previously thought to occur primarily due to *P. aeruginosa* infection, newer studies [2] have revealed the condition to be caused by other bacteria [3,4] and fungi [5,6] too. The lesion starts as an erythematous papule, which slowly evolves to form a haemorrhagic blister, which then deroofs to reveal a characteristic ulcer with dark necrotic eschar and surrounding erythema [1]. We present a report of a four year old boy with ecthyma gangrenosum secondary to *P. aeruginosa* and *Staphylococcus aureus* infections, which resolved after a triple combination of intravenous antibiotics.

CASE REPORT

A four years old boy presented to the paediatric emergency with the complaints of fever and ulcers on trunk and extremities for 10 days. The patient was apparently well 10 days back, when he developed fever. On the same day as the onset of fever, he developed a small (pea sized) fluid filled lesion on the dorsum of his right hand. It was painful and associated with raised temperature. In the next three days, similar lesions developed on the trunk and bilateral upper and lower extremities. The fluid filled lesions ruptured in the next two to three days leaving a deep ulcer with dark underlying base and redness in the skin surrounding the ulcers.

He was taken to a subhealth post the next day and was given topical framycetin and oral flucloxacillin by a community health worker. However, there was no improvement in the appearance of the lesions and was further complicated by appearance of similar lesions on other body sites. After 5 days, he was taken to a pharmacy, where he was started on vancomycin intravenously and topical application of fusidic acid empirically. The therapy was continued for 3 days without any improvement after which the family members of the patient decided to visit our hospital.

His temperature at the time of admission was 101°F, heart rate138 beats per minute, respiratory rate 24 per

How to cite this article: Amatya B, Tripathee RD, Sharma R, Maharjan L. Ecthyma gangrenosum aggravated by systemic antibiotics: A case report and literature review. Our Dermatol Online. 2018;9(1):27-30.

Submission: 03.03.2017; **Acceptance:** 24.06.2017

DOI: 10.7241/ourd.20181.8

minute and blood pressure was 100/70 mm Hg with pallor noted on lower palpebral conjunctiva. His systemic examination did not reveal any abnormalities. His cutaneous examination revealed multiple circular small to large deep ulcers ranging from 1 cm X 1cm to 4 cm X 4 cm on the trunk (Figure 1) and extremities (Figure 2) with black necrotic eschar, purulent exudates and erythema in surrounding skin.

Based on the history and clinical appearance of the lesions, a provisional diagnosis of ecthyma gangrenosum was made.

His baseline haematological and biochemistry investigations revealed the following findings:

- Total leukocyte count – 27,700/mm^3
- Differential leukocyte count – Neutrophils 78%, Lymphocytes 20%, Monocytes 2%
- ESR – 50 mm in 1st hour.

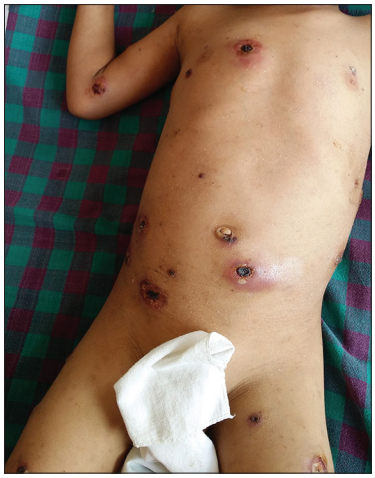

Fig. 1: Deep seated ulcers with black necrotic eschar and surrounding erythema on the trunk.

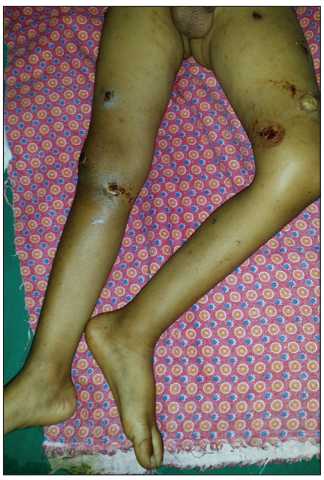

Fig. 2: Similar ulcers on the lower extremities.

- CRP – Positive.
- Biochemical parameters were within normal limits
- Blood culture and sensitivity and swab culture and sensitivity were sent.

The treatments initiated at the time were injection cloxacillin 250 mg IV QID, syrup paracetamol (125 mg/5 ml) 6 ml QID, daily dressing with potassium permanganate 1:10,000 diluted solution and application of mupirocin ointment twice daily.

Three days later, his condition had not improved. His blood culture did not reveal growth of any organism while the skin swab revealed isolation of *Staphylococcus aureus* sensitive to Tigecycline, Doxycycline, Clindamycin, Vancomycin and Chloramphenicol while resistant to Cloxacillin, Cefadroxil, Erythromycin, Ciprofloxacin, Levofloxacin and Amoxycillin.

In light of the swab culture and sensitivity report, cloxacillin was stopped and Injection Vancomycin 100 mg IV QID was initiated, and haematology, biochemistry and swab culture and sensitivity were repeated.

Three days later, his condition improved marginally and the repeated culture revealed isolation of *Pseudomonas aeruginosa* sensitive to Amikacin, Tazobactam + Piperacillin, Polymyxin B but resistant to Ciprofloxacin, Levofloxacin, Gentamicin.

His diagnosis was revised as swab culture revealed the growth of *Pseudomonas aeruginosa*. He was subsequently put on injection Amikacin 150 mg IV OD and injection Tazobactam+Piperacillin 1 g IV TDS. The topical therapy was changed to a triple combination of Neomycin, Polymyxin B and Bacitracin.

Three days later, there was marked improvement in his symptoms with resolution of fever and associated improvement in the appearance of cutaneous lesions (Figure 3). The repeated swab culture revealed growth of *Candida* species other than *Candida albicans*.

The same treatment was continued for another 7 days during which time the lesions had started to heal with absence of exudates and black necrotic eschar. He was discharged on the 10th day with all systemic medications stopped and was advised dressing of the healing wounds twice daily at home with normal saline followed by application of triple combination antibiotic (Neomycin/Polymyxin B/Bacitracin) ointment till full resolution.

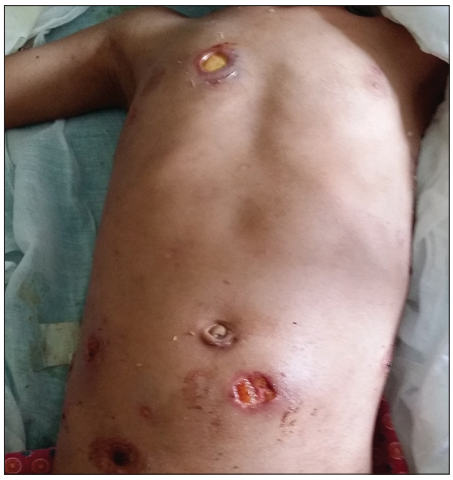

Fig. 3: Appearance of lesions while on treatment.

DISCUSSION

Ecthyma gangrenosum is one of the cutaneous manifestations of severe systemic *Pseudomonas* infection [1]. Previously, ecthyma gangrenosum was assumed to be caused solely by *P. aeruginosa* and that too only in the immunocompromised patients [2].

However, the paradigm has slowly changed in the last 40 years. Ecthyma gangrenosum like lesions have been known to be caused by other bacteria including *Escherichia coli* [3], *Klebsiella pneumoniae* [4] and *Pseudomonas stutzeri* [5]. The fungi known to cause these characteristic lesions include *Candida* [6], *Fusarium* [7], *Mucor* [8], *Scytalidium* [9] and *Metarhizium* [10].

The condition can occur with [11] or without bacteraemia [12] in both immunocompetent [13] and immunocompromised individuals [14]. The diagnosis is based on the appearance of characteristic deep ulcers with dark necrotic eschar on the base and erythema in the surrounding skin associated with a picture of leukocytosis or leukopenia in the total and differential blood count, isolation of the causative organisms in blood or wound culture and improvement of the condition after institution of systemic antibiotics or antifungals based on the culture and sensitivity reports.

The difficulty in our case lay in the isolation of two different organisms, *S. aureus* and *P. aeruginosa* from two distinct sites. Our patient had already been initiated on vancomycin at another centre but had not improved while on vancomycin. As the first swab culture revealed growth of *S. aureus* sensitive to vancomycin, our patient was re-started on vancomycin. However, the degree of clinical improvement while on vancomycin was not appreciable.

The isolation of *P. aeruginosa* from the second swab site three days after the detection of *S. aureus* can be explained in two different ways. The first is co-infection by *Pseudomonas aeruginosa* with *S. aureus*, with the characteristic ulcers being a feature of *Pseudomonas* infection. Another theory is the secondary colonization of the ulcer bed by *Pseudomonas* after removal of the Gram positive organisms by first systemic cloxacillin and then by systemic vancomycin. This is especially relevant in Nepal where systemic antibiotics are available over the counter resulting in their indiscriminate use.

The combination of two systemic agents is recommended for pseudomonal infection, because of higher rate of morbidity and mortality associated with this infection. As the combination of tazobactam-piperallicin and amikacin shows the greater synergy [15], the two agents were systemically administered in our patient. The reports of the wound swab culture and sensitivity also showed the organism to be susceptible to both the agents. Similarly, the use of topical antibiotic combination of neomycin/bacitracin/polymyxin B was also guided by the results of wound swab culture and sensitivity.

CONCLUSION

Ecthyma gangrenosum is usually caused by infection with *Pseudomonas aeruginosa*. However, similar lesions were caused in our patient by co-infection with *Staphylococcus aureus* and *P. aeruginosa*. Pseudomonal colonization and infection can occur after systemic treatment for Gram positive organisms. The treatment approach has to be based on the results of blood and wound swab culture and sensitivity. A combination of systemic vancomycin for *S. aureus* infection, amikacin and piperacillin-tazobactam for *P. aeruginosa* infection was effective in treating the deep ulcers of ecthyma gangrenosum.

Injudicious use of systemic antibiotics can lead to colonization and infection by other organisms. This is especially relevant in Nepal where administration of systemic antibiotics do not require prescription by health care providers. Stricter laws preventing over the counter sale of systemic antibiotics may help curtail these problems.

ACKNOWLEDGEMENTS

The authors would like to thank the guardians of the subject for granting their approval to write and publish this case report. The authors are also grateful to the faculty members and residents of the Department of Dermatology and Venereology at the Institute of Medicine, Tribhuvan University Teaching Hospital, Maharajgunj, Kathmandu, Nepal for their encouragement in preparing this case report.

REFERENCES

1. Boisseau AM, Sarlangue J, Perel Y, Hehunstre JP, Taieb A, Maleville J. Perineal ecthyma gangrenosum in infancy and early childhood: septicemic and nonsepticemic forms. J Am Acad Dermatol. 1992;27:415-8.
2. Vaiman M, Lazarovitch T, Heller L, Lotan G. Ecthyma gangrenosum and ecthyma like lesions: review article. Eur J Clin Microbiol Infect Dis. 2014;34:633-9.
3. Edelstein H, Cutting HO. Escherichia coli as cause of ecthyma gangrenosum. Postgrad Med. 1986;79:44–5.
4. Rodot S, Lacour JP, van Elslande L, Castanet J, Desruelles F, Ortonne JP. Ecthyma gangrenosum caused by Klebsiella pneumoniae. Int J Dermatol. 1995;34:216–7.
5. Puzenat E, Chirouze C, Khayat N, Aubin F, Estavoyer JM, Humbert P, Hoen B. Ecthyma gangrenosum caused by Pseudomonas stutzeri with bacteraemia and systemic vascularitis. Rev Med Interne. 2004;25:315–8.
6. Agarwal S, Sharma M, Mehndirata V. Solitary ecthyma gangrenosum (EG)-like lesion consequent to Candida albicans in a neonate. Indian J Pediatr. 2007;74:582–4.
7. Uludokumacı S, Balkan II, Mete B, Ozaras R, Saltoğlu N, Soysal T. Ecthyma gangrenosum-like lesions in a febrile neutropenic patient with simultaneous Pseudomonas sepsis and disseminated fusariosis. Turk J Haematol. 2013;30:321–4.
8. Kramer BS, Hernandez AD, Reddick RL, Levine AS. Cutaneous infarction: Manifestation of disseminated mucormycosis. Arch Dermatol. 1977;113:1075–6.
9. Benne CA, Neeleman C, Bruin M, de Hoog GS, Fleer A. Disseminating infection with Scytalidium dimidiatum in a granulocytopenic child. Eur J Clin Microbiol Infect Dis. 1993;12:118–21.
10. Burgner D, Eagles G, Burgess M, Procopis P, Rogers M, Muir D, et al. Disseminated invasive infection due to Metarrhizium anisopliae in an immunocompromised child. J Clin Microbiol. 1998;36:1146–50.
11. Duman M, Ozdemir D, Yiş U, Köroğlu TF, Oren O, Berktaş S. Multiple erythematous nodules and ecthyma gangrenosum as a manifestation of Pseudomonas aeruginosa sepsis in a previously healthy infant. Pediatr Dermatol. 2006;23:243–6.
12. Gençer S, Ozer S, Ege Gül A, Doğan M, Ak O. Ecthyma gangrenosum without bacteremia in a previously healthy man: A case report. J Med Case Rep. 2008;2:14.
13. Fabrizi G, Pagliarello C. Multiple ecthyma gangrenosum with a favorable course in a nonimmunocompromised child with moyamoya disease. Eur J Dermatol. 2007;17:253–4.
14. Techatawepisarn T, Chiewchanvit S, Salee P, Mahanupab P, Baosoung V, Praparattanapan J. Ecthyma gangrenosum-like lesions associated with disseminated nontuberculous mycobacterial infection in an HIV-infected patient. Southeast Asian J Trop Med Public Health. 2013;44:649–54.
15. Burgess DS, Hastings RW. Activity of piperacillin/tazobactam in combination with amikacin, ciprofloxacin, and trovafloxacin against Pseudomonas aeruginosa by time-kill. Diagn Microbiol Infect Dis. 2000;38:37-41.

Source of Support: Nil, **Conflict of Interest:** None declared.

Case Report

Cowpox virus infection from pet rat

Uwe Wollina[1], Gesina Hansel[1], Jacqueline Schönlebe[2]

[1]*Department of Dermatology and Allergology Academic Teaching Hospital Dresden-Friedrichstadt, Dresden, Germany,*
[2]*Institute of Pathology, "Georg Schmorl", Academic Teaching Hospital Dresden-Friedrichstadt, Dresden, Germany*

Corresponding author: Prof. Dr. Uwe Wollina, E-mail: wollina-uw@khdf.de

ABSTRACT

Cowpox virus belongs to the genera of double-stranded DNA orthopoxviruses. Although it has a low pathogenicity for humans, transmission from infected animals like rodents and cats to humans has been observed. We report on a 19-year-olf female patient who presented with oculo-cutaneous ulcerations and lymphadenopathy, fever and general malaise. Detailed medical history, contact to infected pet rats, histopathology, and course confirmed the diagnosis of human cowpox. Human cowpox is rare but seems to be an emerging disease transmitted in most cases by pets to humans. There is yet no specific treatment available.

Key words: Orthopoxvirus; Cowpox; Rodents; Humans; Oculo-cutaneous ulcers; Lymphadenopathy

INTRODUCTION

Poxviruses are the largest double-stranded DNA viruses which replicate in the cytoplasm of host cells. The human-pathogeneic poxviruses belong to several genera: orthopoxvirus, parapoxvirus, yatapoxvirus, camelpox virus, molluscipoxvirus, etc. [1].

Cowpox virus belongs to genera orthopoxvirus - a heterogeneous group of viruses that infect a broad spectrum of wild rodents and domestic animals, but seem to be restricted to the Old World [2,3].

Human cowpox is a relatively rare zoonotic infection. The largest case review is based on 54 cases investigated from 1969–1993 [4]. Smaller outbreaks have been reported after turn of the century from France and Germany caused by transmission from pets [5-7].

Human cowpox can be acquired by implantation of a virus into injured skin after contact with infected animals, mostly cats or rats. The sero-prevalence among cats has been calculated between 2% to 4% [4,8]. Small rodents, such as voles and mice, are considered a natural reservoir. No transmission between humans has been reported so far [1-3].

The incubation period lasts 8–12 days. In immunocompetent humans, cowpox remains a localized skin disease with or without local lymphadenopathy. The lesions start as erythematous macules developing into papules and seropapules, followed by ulcerated plaques with eschar formation. Healing is delayed and often accompanied by scar formation and takes several weeks [4].

More severe courses have been described in patients with atopic dermatitis [9], Darier's disease [10], and systemic corticosteroid therapy [4]. Fatal infections were reported in a patient with atopic dermatitis and allergic bronchial asthma who was receiving systemic steroids at the time of infection [11] and in a 17-year-old boy after kidney transplantation [12]. Most of the reported cases occurred among children and adolescents [4].

Hands and fingers and hands are most commonly affected, followed by face and neck [4]. There are also documented cases of complicated eyelid involvement and bilateral pneumonia from Finland and Germany [6,13].

The diagnosis is problematic because the disease is rare, specific tests are not widely available, therefore clinical assessment is essential.

How to cite this article: Wollina U, Hansel G, Schönlebe J. Cowpox virus infection from pet rat. Our Dermatol Online. 2018;9(1):31-34.
Submission: 09.02.2017; **Acceptance:** 06.07.2017
DOI: 10.7241/ourd.20181.9

CASE REPORT

A 19-year-old woman presented with painful ulcerated lesions on face, conjunctiva and lower arm. There was a painful lymphadenopathy as well. She had fever and general malaise. Her medical history was unremarkable. She had not medications.

On examination, we observed inflammatory plaques with a central depressed ulceration, minor oozing and raised, sharp borders above the left mandible and on the flexural left lower arm, surrounded by erythema with a maximum diameter of 7 cm. A similar lesion was observed on the conjunctiva of the left lower lid. A single seropapule was noted on the left cheek. Regional lymph nodes on the neck were swollen and painful on pressure (Figs. 1a - d).

The working diagnosis was oculo-cutaneous tularemia.

Laboratory investigations demonstrated an increased blood sedimentation rate of 30 mm/h (normal range <20), C-reactive protein of 82.6 mg/l (< 5), 1,334/µl erythrocytes in urine (<15). Serological tests for herpes, tularemia, leptospirosis, and listeriosis were negative. Microbial swabs from the ulcerated lesions remained negative in culture.

A diagnostic skin biopsy was performed from a lesion on the lower arm, formalin-fixed and stained with hematoxylin-eosin, Giemsa stain, periodic acid-Schiff reaction (PAS), and Prussian blue reaction.

Histologic examination demonstrated deep seated hemorrhagic necrosis and necrotic hair follicles. Epidermal acanthosis was noted around the ulcer. Here, ballooning degeneration of keratinocytes and hair follicle epithelium, necrotic keratinocytes and basophilic cytoplasmatic inclusion (Guarnieri) bodies were observed. Within dermis and subcutis, a dense lymphocytic infiltrate with some neutrophilic and esosinophilic granulocytes and individual mast cells was present. Giant cells of Touton- and foreign body-type were occasionally noted (Fig. 2).

Oral antibiosis with sultamicillin 3 x 1.5 g/d and doxycycline 2 x 100 mg/d initiated under the suspicion of tularemia was ineffective and ulcers enlarged. The lymphadenopathy was persistent (Fig. 1c). The patient developed a maculo-papular exanthema 2 weeks later, that was treated by topical betamethasone ointment and oral levocetericine 2 x 5 mg/d.

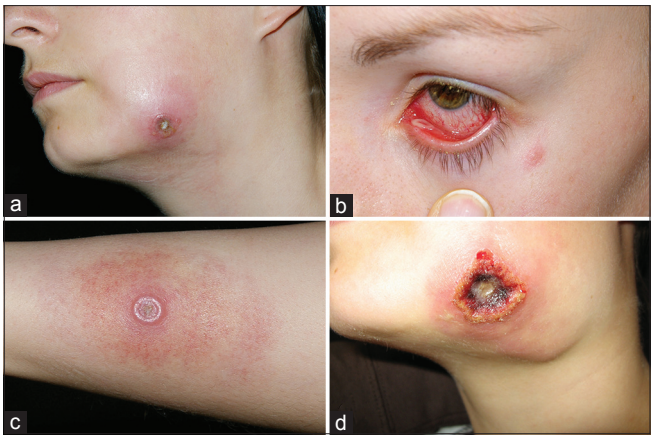

Figure 1: Human cowpox. (a) Facial ulcer with elevated margins. (b) Conjunctival ulcer with blepharitis. (c) Rounded plaque with elevated borders and surrounding erythema on the lower arm. (d) Progressive ulceration 11 days later with lymphadenopathy.

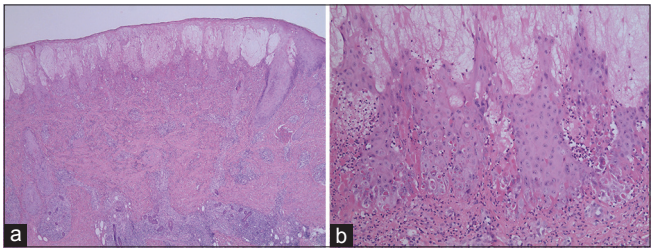

Figure 2: Human cowpox histology (Hematoxylin-eosin). (a) Epidermal acanthosis with ballooning keratinocytes, lympho-monocytic dermal infiltrate (x 2). (b) Detail showing ballooning degeneration of keratinocytes, necrotic keratinocytes and basophilic cytoplasmatic inclusions. In the upper dermis, there is an inflammatory infiltrate with some intermingled giant cells.

After repeated questioning, it became clear that she had 3 pet rats at home suspicious of mite infestation, one of them died. She remembered rat bites in her fingers.

The rat was later presented to veterinary medicine where foot pad lesions were noted comparable with cowpox infection. It became clear that the mite infestation was a misdiagnosis.

The diagnosis of a human cowpox virus infection transmitted by a pet rat was confirmed.

The patient was treated by good ulcer care for open wounds. The lesions eventually healed by scarring after eight weeks. There was no relapse during follow-up of 8 years.

DISCUSSION

Tularemia was the first suspicion in our young patient with oculo-cutaneous lesions combined with lymphadenopathy. Tularemia is caused by gram-negative

coccobacillus *Francisella tularensis* and re-emerged in Germany in 2004. *F. tularensis* had been identified in yellow-necked field mice (2.9%), bank voles (4.5%), common voles (8.0%), field voles (10.0%), and water voles (15.0%) [14]. The clinical presentation is highly variable. The diagnosis was excluded later based on exposure to pet cowpox infected rats, histopathology, and clinical course.

Cowpox virus has relatively low pathogenicity for humans but has a wide range of sensitive animal hosts. Human cowpox is a rare sporadic disease, which develops when the virus is transmitted from an infected animal to humans. This disease is mainly recorded in Europe [1].

Pet dog and cat populations have substantially increased in the developed world and it is estimated that dogs and cats are present in more than 50% of households in the USA and Europe [15]. In a study on feline cowpox infection, a remarkable genetic heterogeneity of genetic virus variants was reported that translates also into variable virulence [16].

Pet rats have become popular domestic animals. Their claws may produce scratches and punctures, unnoticed by the owner and thereby inoculate the cowpox virus. Infected rats like cats most frequently develop ulcers on the legs, toes, footpads, faces, and ears [7, 17]. In the present case, several finger bites by pet rats were remembered by the patient.

There have been several reports on outbreaks of cowpox virus infections in humans transmitted from pet rats in Germany and France. There is a report about 4 patients with cowpox infections form pet rats in 2008 and 2009 from France. Affection of skin, eyes and mucous membranes with coughing, lymphadenopathy, fever and general malaise were observed [5]. In 2008, in the region of Krefeld, Germany, six patients were affected with one case of severe eye involvement and another case with pulmonary infections [6]. In 2009, an outbreak of ulcero-cutaneous cowpox was reported in greater Munich area, Germany, with five affected patients who had bought rats form the same litter [18]. In 2011, eight patients were affected in Munich, Germany [7]. Most patients developed seropapules, some ulcerated plaques with or without lymphadenopathy. In the same year four cases have been reported from France with ulcero-cutaneous lesions [19].

Neurogenic inflammation is a possible symptom of persistent cowpox infection [20]. Severe ear chondritis developed from cowpox transmitted from a pet rat [21]. Generalized cowpox infection has been described in HIV-positive patients [22].

The differential diagnosis comprises a broad range of infectious diseases: bacterial (atypical mycobacteriosis, cat scratch disease, ecthyma, pyodermia, ulcero-cutaneous tularemia, cutaneous anthrax, rickettsial infections, actinomycosis, syphilis maligna), fungal (sporotrichiosis, blastomycosis), viral (smallpox, monkeypox, herpes simplex, varicella zoster infections, milker's nodules, orf). An initial skin lesion can resemble drug eruption, insect bite or pyoderma gangrenosum. For biosafety reasons, a prompt diagnosis is essential in multifocal cases resembling smallpox [4].

Laboratory methods to detect cowpox virus include electron microscopy tungstic acid-stained native material, real-time polymerase chain reaction (PCR) and semi-nested PCR. Serological tests are indirect methods. For interpretation, vaccination against smallpox with vaccinia virus must be considered [23-25].

The treatment of the mostly self-limiting illness is symptomatic by wound care. Surgical interventions may prolong the healing process. Antibiotic treatment is required only in patients with a bacterial superinfection [6].

Steroids are contraindicated and may exacerbate the disease. The use of antiviral treatment with cidofovir or anti-vaccinial-hyperimmunoglobulin is discussed controversial. These options should be reserved for very severe disease courses and personal at high risk of infection. The use of antiviral drugs in human cowpox is off-label [26,27].

Key messages

- Cowpox is an orthopoxvirus disease of emerging importance.
- Small rodents are the natural reservoir of cowpox virus.
- Pets like cats and rats are major transmitters of cowpox from animal to humans.
- In most cases the disease is self-limited but fatal cases have been observed in immunosuppressed patients.

Consent

The examination of the patient was conducted according to the Declaration of Helsinki principles.

REFERENCES

1. Shchelkunov SN. An increasing danger of zoonotic orthopoxvirus infections. PLoS Pathog. 2013;9:e1003756.
2. Chantrey J, Meyer H, Baxby D, Begon M, Bown KJ, Hazel SM, et al. Cowpox: reservoir hosts and geographic range. Epidemiol Infect. 1999;122:455–60.
3. Hoffmann D, Franke A, Jenckel M, Tamošiūnaitė A, Schluckebier J, Granzow H, et al. Out of the reservoir: phenotypic and genotypic characterization of a novel cowpox virus isolated from a common vole. J Virol. 2015;89:10959-69.
4. Baxby D, Bennett M, Getty B. Human cowpox 1969–93: a review based on 54 cases. Br J Dermatol. 1994;131:598–607.
5. Ninove L, Domart Y, Vervel C, Voinot C, Salez N, Raoult D, et al. Cowpox virus transmission from pet rats to humans, France. Emerg Infect Dis. 2009;15:781-4.
6. Becker C, Kurth A, Hessler F, Kramp H, Gokel M, Hoffmann R, et al. Cowpox virus infection in pet rat owners: not always immediately recognized. Dtsch Arztebl Int. 2009;106:329-34.
7. Vogel S, Sárdy M, Glos K, Korting HC, Ruzicka T, Wollenberg A. The Munich outbreak of cutaneous cowpox infection: transmission by infected pet rats. Acta Derm Venereol. 2012;92:126-31.
8. Nowotny N. Serologic studies of domestic cats for potential human pathogenic virus infections from wild rodents. Zentralbl Hyg Umweltmed. 1996;198:452–61.
9. Pelkonen PM, Tarvainen K, Hynninen A, Kallio ERK, Henttonen H, Palva A, et al. Cowpox with severe generalized eruption, Finland. Emerg Infect Dis. 2003;9:1458–61.
10. Haase O, Moser A, Rose C, Kurth A, Zillikens D, Schmidt E. Generalized cowpox infection in a patient with Darier disease. Br J Dermatol. 2011;164:1116–8.
11. Czerny CP, Eis-Hübinger AM, Mayr A, Schneweis KE, Pfeiff B. Animal poxviruses transmitted from cat to man: current event with lethal end. Zentralbl Veterinarmed B. 1991;38:421–31.
12. Gazzani P, Gach JE, Colmenero I, Martin J, Morton H, Brown K, et al. Fatal disseminated cowpox virus infection in an adolescent renal transplant recipient. Pediatr Nephrol. 2017;32:533-6.
13. Kinnunen PM, Holopainen JM, Hemmilä H, Piiparinen H, Sironen T, Kivelä T, et al. Severe ocular cowpox in a human, Finland. Emerg Infect Dis. 2015;21:2261-3.
14. Kaysser P, Seibold E, Mätz-Rensing K, Pfeffer M, Essbauer S, Splettstoesser WD. Re-emergence of tularemia in Germany: Presence of *Francisella tularensis* in different rodent species in endemic areas. BMC Infect Dis. 2008;8:157.
15. Chomel BB. Emerging and re-emerging zoonoses of dogs and cats. Animals (Basel). 2014;4:434-45.
16. Kaysser P, von Bomhard W, Dobrzykowski L, Meyer H. Genetic diversity of feline cowpox virus, Germany 2000-2008. Vet Microbiol. 2010;141:282-8.
17. Kuczka A, Nitsche A, Höveler R, Becker C, Kurth A. Seltene Zoonose vermehrt in Deutschland nachgewiesen. Ein Bericht über durch Heimtierratten auf Menschen übertragene Kuhpockeninfektion. Dtsch Tierärztebl. 2009;5:316-9.
18. Campe H, Zimmermann P, Glos K, Bayer M, Bergemann H, Dreweck C, et al. Cowpox virus transmission from pet rats to humans, Germany. Emerg Infect Dis. 2009;15:777-80.
19. Ducournau C, Ferrier-Rembert A, Ferraris O, Joffre A, Favier AL, Flusin O, et al. Concomitant human infections with 2 cowpox virus strains in related cases, France, 2011. Emerg Infect Dis. 2013;19:1996-9.
20. Hobi S, Mueller RS, Hill M, Nitsche A, Löscher T, Guggemos W, et al. Neurogenic inflammation and colliquative lymphadenitis with persistent orthopox virus DNA detection in a human case of cowpox virus infection transmitted by a domestic cat. Br J Dermatol. 2015;173:535-9.
21. Elsendoorn A, Agius G, Le Moal G, Aajaji F, Favier AL, Wierzbicka-Hainault E, et al. Severe ear chondritis due to cowpox virus transmitted by a pet rat. J Infect. 2011;63:391-3.
22. Fassbender P, Zange S, Ibrahim S, Zoeller G, Herbstreit F, Meyer H. Generalized cowpox virus infection in a patient with HIV, Germany, 2012. Emerg Infect Dis. 2016;22:553-5.
23. Kurth A, Nitsche A. Detection of human-pathogenic poxviruses. Methods Mol Biol. 2011;665:257-78.
24. Maksyutov RA, Gavrilova EV, Meyer H, Shchelkunov SN. Real-time PCR assay for specific detection of cowpox virus. J Virol Methods. 2015;211:8-11.
25. Abrahão JS, Drumond BP, Trindade Gde S, da Silva-Fernandes AT, Ferreira JM, Alves PA, et al. Rapid detection of orthopoxvirus by semi-nested PCR directly from clinical specimens: a useful alternative for routine laboratories. J Med Virol. 2010;82:692-9.
26. Hostetler KY. Synthesis and early development of hexadecylopropylcidofovir: an oral antipoxvirus nucleoside phosphonate. Viruses 2010;2:2213–25.
27. Petersen BW, Harms TJ, Reynolds MG, Harrison LH. Use of vaccinia virus smallpox vaccine in laboratory and health care personnel at risk for occupational exposure to orthopoxviruses - recommendations of the Advisory Committee on Immunization Practices (ACIP), 2015. MMWR Morb Mortal Wkly Rep. 2016;65:257-62.

Source of Support: Nil, **Conflict of Interest:** None declared.

Case Report

Trichomycosis axillaris

Patricia Chang[1], Tyson Meaux[2]

[1]Department of Dermatology, Hospital General de Enfermedades IGSS and Hospital Ángeles, Guatemala, [2]Student, Hospital General de Enfermedades IGSS and Hospital Ángeles, Guatemala,

Corresponding author: Dr. Patricia Chang, E-mail: pchang2622@gmail.com

ABSTRACT

We report a cases of trichomicosys axillaris in a male patient 48 years old that was an incidental finding on dermatological examination for another dermatological consultation.

Key words: Trichomycosis axillaris; *Corynebacterium flavescent*; Axillar hair; Whitish concretions

CASE REPORT

We present a case of a male patient working as a carpenter 48 years old, who visited our emergency room for a contact dermatitis affecting the hands bilaterally. During the physical examination, he was found to have a trichopathy localized at the axillary hair, consisting of multiple whitish concretions and nodules (Figs. 1a and 1b). Dermoscopy showed multiple nodular concretions around the hair Figs. 2a and 2b), direct examination showed concretions around the hairs (Fig. 3), with microscopy, pods seen around the hairs (Fig. 4).

The remainder of the examination was within normal limits. The patient did not have any change in the color of his axillar sweat.

This trichopathy was an incidental finding on dermatological examination for another reason, and the patient reports that he had not noticed it previously. Patient reports an unremarkable personal and family history.

With this clinical data, the diagnosis of trichomycosis axillaris was made. It was recommended to shave the axillary hair and apply 1% fusidic acid three times daily for 8 days.

DISCUSION

Trichomycosis axillaris (TMA), also known as Trichobacteriosis, is a superficial infection of the axillary hair shaft caused by the aerobic gram positive bacterium *Corynebacterium flavescens*, formerly named *Corynebacterium tenuis*. This bacterium is present in nature as both bacillus and diphtheroid, and mostly causes disease in humid, tropical climates [1-3]. The mechanism of infection involves physical contact between the bacteria and the hair shaft. *C. flavescens* is able to adhere to the surface of the shaft due to a substance produced by both the organism and the apocrine glands of the human host [2]. Obesity, poor hygiene, and disturbances in apocrine sweat production contribute to the occurrence of this disease process [1,4]. Patients may have concurrent pitted keratolysis and/or erythrasma (all three present in 13% of patients with pitted keratolysis according to one study) [5,6]. In fact, when a patient has all three of these diseases, it is given a special name, "the *Corynebacterium* triad" [3]. An adult male with axillary hyperhidrosis and bromhydrosis, stained clothes, and roughened texture of axillary hairs, are the typical historical findings that aid physiciansin the diagnosis of trichomycosis axillaris [2,4,7]. This disease can produce three types of hair discoloration: yellow, which is most common (98% of cases), red, and black [3]. Physical examination demonstrates 1-2mm discrete nodules attached to axillary hair shafts. While the axillae are involved in roughly 97% of cases, it is possible for other areas of the body to also be affected. Those reported include the pubic, inter-gluteal and eyebrow regions [2,5]. Differential diagnosis includes erythrasma, tinea, white and black piedra, pediculosis,

How to cite this article: Chang P, Meaux T. Trichomycosis axillaris. Our Dermatol Online. 2018;9(1):35-37.
Submission: 30.01.2017; **Acceptance:** 25.05.2017
DOI: 10.7241/ourd.20181.10

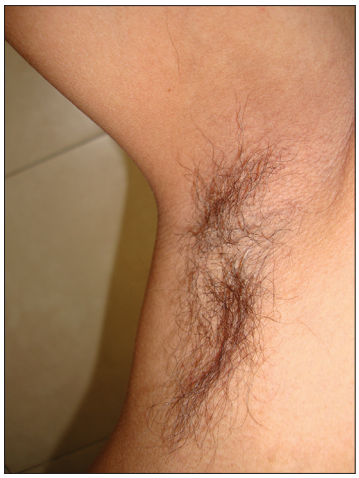

Figure 1a: Multiple whitish axillary hairs.

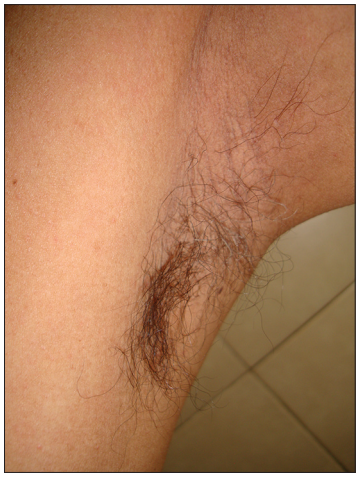

Figure 1b: Multiple whitish axillary hairs.

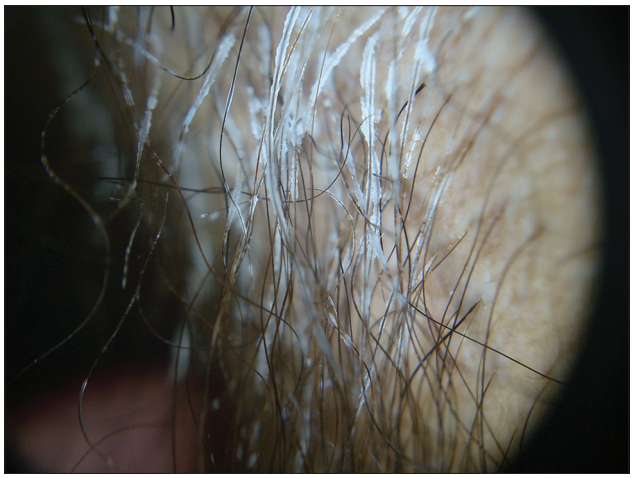

Figure 2a: Dermatoscopic aspect of axillary hairs surrounded by nodules and pods.

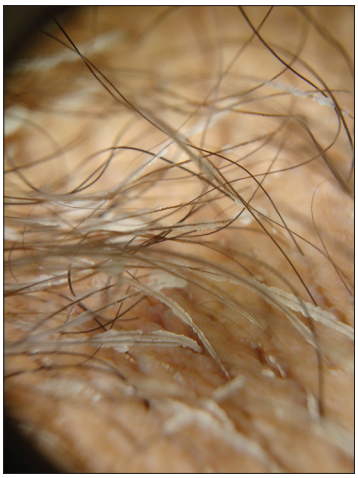

Figure 2b: Dermatoscopic aspect of axillary hairs surrounded by nodules and pods.

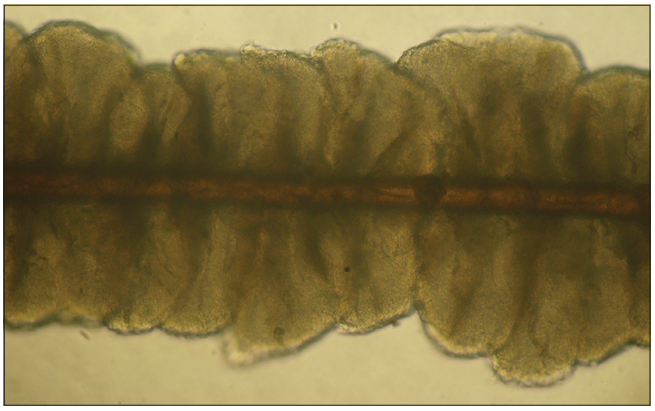

Figure 3: Direct examination, concretions around the axillary hair are appreciated.

Figure 4: With microscopy, pods seen around the hairs.

and *Trichosporonaselie* [2,7]. Microscopic examination with 10% KOH shows pods or concretions, which are actually masses of bacteria surrounding the hair shaft. When direct pressure is applied to these structures,microscopic visualization of 5-1μmcoccoids and diptheroids adherent to hair shafts eliminates a fungal etiology, while the absence of coral red fluorescence under woods lamp rules out erythrasma [1-3]. Woods lamp is also useful in determining which parts of the body are affected, as infected hair shafts fluoresce under

low-intensity UV light due to the presence of bacterial concretions [2]. Dermoscopy also aids in the diagnosis of trichobacteriosis, revealing waxy and yellowish adherent nodules and concretions along the hair shaft [4]. Culture of Corynebacterium is difficult and not necessary for diagnosis. Treatment options for TMA include shaving the hair in the affected area, topical anti-bacterial or anti-fungal preparations, and other topical treatments containing 3% sulfur, 2% formalin, 1% fusidic acid, mercuric chloride, or 2% sodium hypochlorite [2,5]. Preventative measures include regular and continued use of topical ammonium chloride solution or drying powders to counter perspiration [7]. Regarding topical antibiotic preparations, one study showed no difference in efficacy between benzoyl peroxide and erythromycin. The study also showed that shaving did not lead to a quicker cure, and average time to complete cure was roughly 3 weeks [8].

REFERENCES

1. Ma DL, Vano-Galvan S. Trichomycosis axillaris. N Engl J Med. 2013;369:1735.
2. Bonifaz A, Vaquez-Gonzalez D, Fierro L, Araiza J, Ponce RM. Trichomycosis (Trichobacteriosis): Clinical and Microbiological Experience with 56 Cases. Int J Trichology. 2013;5:12–6.
3. Bonifaz A. Micología Médica Basica. Mc Graw Hill México. 2013:171-3.
4. Salim G, Zahra MF. Trichobacteriosis: contribution of dermoscopy. Dermatol Online J. 2014;16;20.
5. James WD, Berger TG, Elston DM. Diseases of the Skin Appendages in: Andrews' Diseases of the Skin: Clinical Dermatology. Saunders Elsevier. 2006: 763.
6. Kim MG, Kim JA, Rho NK, Kim BJ, Kim WS, Lee DY, et al. A Clinical analysis of 133 cases of pitted keratolysis. Korean J Dermatol. 2006;44:1165-70.

Source of Support: Nil, **Conflict of Interest:** None declared.

Case Report

Cornelia de Lange syndrome and psoriasis: Report of a case

Andrea Lubkov[1], Veronica Uraga[1], Maria-Cecilia Briones[2], Enrique Uraga[1,2]

[1]Deparment of Dermatology, Hospital "Luis Vernaza", Guayaquil, Ecuador, [2]Deparment of Dermatology, Centro Privado de Piel "Dr. Enrique Uraga Peña", Guayaquil, Ecuador

Corresponding author: Dr. Andrea Lubkov, E-mail: andrealubkov@gmail.com

ABSTRACT

Cornelia de Lange syndrome was first reported in 1916 and it is characterized by growth deficiency, psychomotor delay and unique facial expression. Its incidence is 1:45.000 live births, being an infrequently reported entity. We present the case of a 15 years old girl with Cornelia de Lange syndrome associated with Psoriasis.

Key words: Cornelia de Lange; Psoriasis; Syndrome

INTRODUCTION

Cornelia de Lange syndrome is a multi systemic disease, first reported in 1933 by Cornelia Catharina de Lange, who described two cases and named it "typus degenerativus amstelodamensis". A similar case was described in 1916 by Winfred Brachmann, and then renamed it as "Brachmann-deLange syndrome". It is characterized by growth deficiency and psychomotor delay, feeding and behavioral difficulties [1,2].

The incidence is variable, ranging from 1:10.000 to 1:30.000 live births. Some cases are sporadic, related to genes SMC1A, SMC3, RAD21 and HDAC8 on chromosome X, but also some of them are autosomic dominant, related to gene NIPBL on chromosome 5, responsible for 50% of the cases. This syndrome has a wide spectrum of manifestations that includes neurological, endocrinological, muscle-skeletal and cutaneous abnormalities [2].

CASE REPORT

A 15 years old female patient, with Cornelia de Lange syndrome, presents since 9 years old relapsing erythematous descamative plaques, some of them with a circinate or nummular pattern, disseminated but more intense in trunk and extremities, with severe pruritus (Figs. 1 and 2). The girl's mother referred that she presented at birth low weight, congenital heart disease (paten foramen oval presumed due to its spontaneous closure), seizures and hip dislocation, that led to the diagnosis of Cornelia de Lange syndrome.

In the physical exam, we noticed weak cry, psychomotor delay, short stature, synophrys, low hairline, hirsutism, down-turned angles of the mouth, low-set ears, and muscle-skeletal abnormalities (Fig. 3). A histopathological diagnosis of psoriasis was made, as we examined our therapeutic options. Treatment with topical clobetazol and coal tar was established showing complete resolution of the lesions after one month of treatment (Fig. 4).

DISCUSSION

Cornelia de Lange syndrome (CdLS) is also known as Brachmann de Lange syndrome, it's characterized by a wide phenotypical spectrum, which makes it easy to diagnosis, although some cases remained undiagnosed years after birth [2]. The genes implicated in its pathophysiology are SMC1A, SMC3, RAD21 and HDAC8 that codify proteins of the cohesine complex [3].

How to cite this article: Lubkov A, Uraga V, Briones M-C, Uraga E. Cornelia de Lange syndrome and psoriasis: Report of a case. Our Dermatol Online. 2018;9(1):38-40.

Submission: 08.08.2017; **Acceptance:** 13.10.2017

DOI: 10.7241/ourd.20181.11

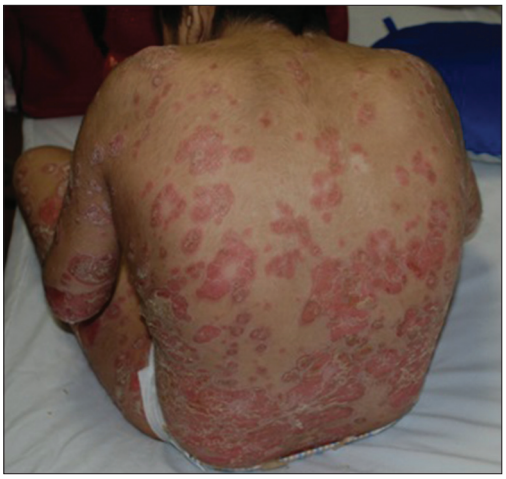

Figure 1: Disseminated erythematous desqamative plaques in the trunk.

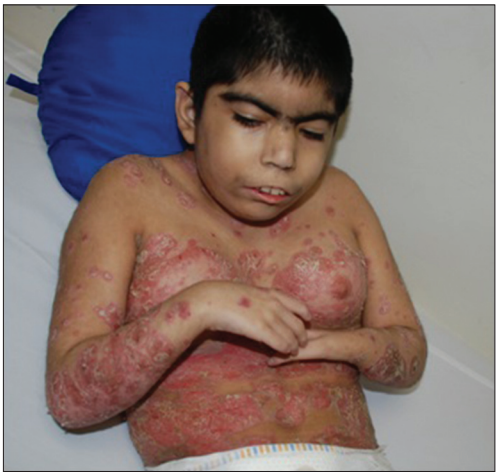

Figure 3: Facial features as synophrys, depressed nasal bridge, down-turned angles of the mouth, low hairline, low-set ears.

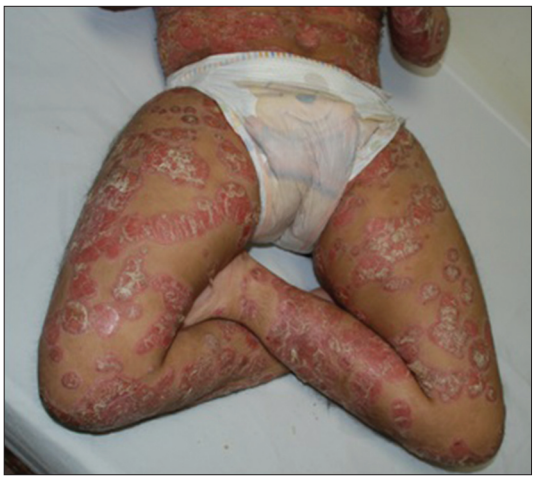

Figure 2: Disseminated erythematous desqamative plaques in the legs.

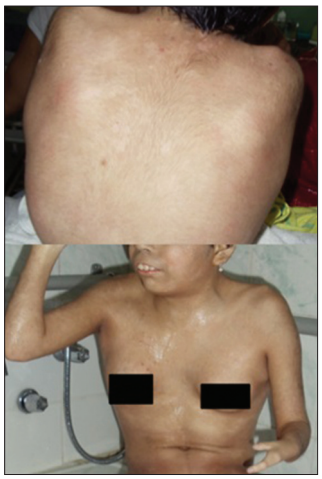

Figure 4: 1 month after treatment.

These patients are characterized by short stature, and psychomotor delay. Mean stature for men is 156 cm and 131 cm for women. Some cases present central obesity. Multiple associations have been described, including gastrointestinal abnormalities, as gastroesophageal reflux between the most common [4]. Other alterations may be present including ophthalmologic, cardiovascular, and urinary [5,6].

Facial features include hirsutism, synophrys, long and thick eyelashes, low-set ears, broad nasal bridge, thin superior lip, down-turned angles of the mouth, and micrognatia [7,8]. Hirsutism is a common feature, although some patients present alopecia. Cutis marmorata and cutis verticis gyrata have been described [5]. Xerosis and hypoplasic borders of the fingers are observed, the latter often leading to erasure of finger prints [8-10]. According to its phenotypic expression, CdLS can be classified in three groups (Table 1); mild, moderate and severe disease, due to the extremities, growth and psychomotor affection [11-13].

Another classification divides it in [1]:
1. Classical phenotype: Characteristic facial and skeletal changes.
2. Mild phenotype: Mild characteristic facial and skeletal changes.
3. CdLS-like: Similar phenotypic expression but related to chromosomic or teratogenic affections.

Diagnosis is made when [1]:
1. Positive affected gene
2. Facial features and two growth, developmental or behavioral criteria
3. Facial features and, one growth, developmental or behavioral criteria, and two additional criteria.

A severity score system has been established, that includes physical and psychomotor development, which

Table 1: Classification of Cornelia de lange syndrome according phenotypic characteristics (Adapted from Gillis *et al.*, 2004)

Parameters	Mild	Moderate	Severe
Limb reduction	No reduction defect	Partial defect (>2 digits on each hand)	Severe defect (<2 digits)
Developmentand cognitive abilities	Motor milestones <2 years delayed; speech and communication skills present	Motor milestones >2 years delayed; limited speech and communication	Profound delay in motor milestones; lack of meaningful communication
Growth*	>75th percentile	25th-75th	<25th percentile

*Average of percentiles for weight, height, and head circumference, plotted on CdLS standard growth curves

Table 2: Severity score system (Kline)

Parameters	1 points	3 points	5 points
Low weight at birth	>2.500gr	2.000-2.500gr	<2.000gr
Sits alone	Before 9 months old	9-20 months old	After 20 months old
Walks alone	Before 18 months old	18-42 months old	After 42 months old
First words	Before 24 months old	24-48 months old	After 48 months old
Upper limb malformation	No defect	Partial defect (>2 digits)	Severe defect (<2 digits)
Other malformations	0-1	2-3	>3
Hearing loss	Absent	Mild	Moderate-severe

divides them according to its classification in severe involvement (>22 points), moderate involvement (15-22 points), mild involvement (<15 points) (Table 2) [14]. Our patient score was 25 points.

Several case reports have associated CdLS with other pathologies, although dermatologic associations are infrequently reported. In the literature at our disposal we found an association with rosacea in a 16 years old female [15], and Uleritema Ofriogenes in a 17 years old female [16]. Our patient represents the second case of CdLS associated with psoriasis [17].

CONCLUSION

Although psoriasis is a well known and commonly reported disease, its incidence in CdLS is extremely low. This association is very rare, to the best of our knowledge; there is only one previous report in a Pakistani girl. Our case represents a therapeutic challenge due to the limited options available for this specific case. We had a rapid response with only topic corticoids and coal tar.

REFERENCES

1. Mikołajewska E. Interdisciplinary therapy in Cornelia de Lange syndrome - review of the literature. Adv Clin Exp. 2013;22:571–7.
2. Vall J. Cornelia de Lange syndrome. Med J Aust. Am Soc Surg Hand. 1978;1:335.
3. Deardorff MA, Kaur M, Yaeger D, Rampuria A, Korolev S, Pie J, et al. Mutations in Cohesin Complex Members SMC3 and SMC1A Cause a Mild Variant of Cornelia de Lange Syndrome with Predominant Mental Retardation. Am J Hum Genet. 2007;80:485–94.
4. Castronovo P, Delahaye-Duriez A, Gervasini C, Azzollini J, Minier F, Russo S, et al. Somatic mosaicism in Cornelia de Lange syndrome: A further contributor to the wide clinical expressivity? Clin Genet. 2010;78:560–4.
5. Collis L, Moss J, Jutley J, Cornish K, Oliver C. Facial expression of affect in children with Cornelia de Lange syndrome. J Intellect Disabil Res. 2008;52:207–15.
6. Koch A, Eisig S. Syndromes with unusual facies. Atlas Oral MaxillofacSurgClin North Am [Internet]. Elsevier Inc. 2014;22:205–10.
7. He Q, Johnston J, Zeitlinger J, City K, City K. HHS Public Access. 2015;33:395–401.
8. Macchini F, Fava G, Selicorni A, Torricelli M, Leva E, Valadè A. Barrett's esophagus and Cornelia de Lange Syndrome. Acta Paediatr. 2010;99:1407–10.
9. Humberto D, Fernando J, Daniel M. Sindrome Cornelia de Lange. Rev Chil Pediatr.1980;51:55-8.
10. Salazar FN, De Lange C, Opitz JM, Laurence KM, Ptacek LJ, Jervis GA, et al. Dermatological Manifestations of the Cornelia de Lange Syndrome. Arch Dermatol Am Med Assoc. 1966;94:38.
11. Gillis LA, McCallum J, Kaur M, DeScipio C, Yaeger D, Mariani A, et al. NIPBL mutational analysis in 120 individuals with Cornelia de Lange syndrome and evaluation of genotype-phenotype correlations. Am J Hum Genet Elsevier. 2004;75:610–23.
12. Recavarren AM, Araníbar DL, Ureta LP, Castillo TS, Tellerías CL. Síndrome de Cornelia de Lange. Rev Chil Dermatol. 2008;3:233–6.
13. Gil MC, Ribate MP, Ramos FJ. Síndrome de Cornelia de Lange. Protoc Diagn Ter Pediatr. 2010;1:1-12.
14. Malik LM, Khan GA, Azfar NA, Jahangir M. Case Report Cornelia de Lange Syndrome - a cause of hypertrichosis in children: Case report and review of literature. J Pak Assoc Dermatol. 2011;21:211–4.
15. Eghlileb AM, Finlay AY. Granulomatous rosacea in Cornelia de Lange syndrome. Indian J Dermatol Venereol Leprol. 2009;75:74–5.
16. Flórez A, Fernández-Redondo V, Toribio J. Ulerythemaophryogenes in Cornelia de Lange syndrome. Pediatr Dermatol.2016;19:42–5.
17. Shahzad A, Suhail Pal S, Khurshid K. Cornelia De Lange Syndrome with generalized pustular psoriasis: A rare coexistence. J Pakistan Assoc Dermatologists. 2005;15:281–4.

Source of Support: Nil, **Conflict of Interest:** None declared.

Case Report

IgD, cyclooxygenase-2 and ribosomal protein S6-PS240 immune response in a case of early psoriasis

Ana Maria Abreu Velez[1], Gabrielle M. Sabini[2], Michael S. Howard[1]

[1]Immunodermatology, Georgia Dermatopathology Associates Atlanta, Georgia, USA, [2]Department of Dermatology, North Atlanta Dermatology, Duluth, Georgia, USA

Corresponding author: Ana Maria Abreu Velez, E-mail: abreuvelez@yahoo.com

ABSTRACT

Psoriasis is an inflammatory skin disease. Five classic types of psoriasis have been defined: plaque, inverse, pustular, guttate, and erythrodermic. The early psoriasis immunologic skin immune response is not well understood. Here we aim to show an immune and cell signaling response in a case of early psoriasis. A 56 year old female presented with a desquamative lesion on her right leg. A skin biopsy for hematoxylin and eosin (H&E) and immunohistochemistry (IHC) staining was taken. The diagnosis indicated early psoriasis, and IHC showed positive IgD staining in the epidermal corneal layer, as well as positive staining with ribosomal protein S6-pS240 (RIBO) in the hyperproliferative epidermis. Cyclooxygenase-2 (COX-2) was also very positive in the granular layer in spots, at the basement membrane zone of the skin and in the inflammatory infiltrate in the dermis subjacent to hyperproliferative psoriatic areas. In an early case of psoriasis, we confirmed the presence of IgD, RIBO and COX-2. Each molecule seems to be playing a role in inflammation and intracellular signaling pathways in early psoriasis. The role of IgD is unknown, and this case brings to light the complexity of the pathologic changes occurring in early psoriatic lesions.

Key words: Psoriasis; Cyclooxygenase-2; Ribosomal protein S6-ps240 phosphorylation site specific; IgD

INTRODUCTION

Psoriasis is a common, chronic inflammatory skin disease frequently presenting as well-demarcated, scaly plaques; many other clinical forms have been described [1]. The clinical presentation covers a spectrum including acute, chronic and relapsing forms; each stage seems to correlate with different immunologic markers. The chronic psoriasis immune response is characterized by hyperproliferative keratinocytes, infiltration of T cells, dendritic cells, macrophages and neutrophils, corneal ectopic expression of molecules and some autoreactivity [1-4]. *In vivo* binding of IgG in the stratum corneum of psoriatic lesions as well as in blood vessels has been previously documented [2,3] Autoantigen candidates for psoriasis include peroxiredoxin 2, ezrin, maspin, and heat shock protein 27. Some putative amino acid sequences with homologies to streptococcal proteins have been shown to react with the sera from psoriasis patients [5]. Multiple studies also point to possible alterations in the signaling pathways of nuclear factor-κB, interferon-γ, and interleukins (IL)-23 and Il-17; and antigen presentation as central axes of psoriatic inflammation [1]. IL-17-producing dermal γδ T cells seem to be recently linked to psoriasis [4]. In our case of early psoriasis, we investigated the presence of cyclooxygenase-2 (COX-2), and ribosomal protein S6-ps240 (RIBO) [2,3]. A 56 year old female presented to the dermatologist for a scaling, itching plaque. The clinical examination revealed an erythematous, scaling plaque on the right leg. A skin biopsy for hematoxylin and eosin (H&E) and immunohistochemical (IHC) staining was taken.

CASE REPORT

No patient identifiers were recorded, and our research was conducted following medical guidelines of

How to cite this article: Abreu Velez AM, Sabini GM, Howard MS. IgD, cyclooxygenase-2 and ribosomal protein S6-PS240 immune response in a case of early psoriasis. Our Dermatol Online. 2018;9(1):41-43.

Submission: 07.06.2017; **Acceptance:** 30.07.2017

DOI: 10.7241/ourd.20181.12

non-disclosure. Lesional skin was biopsied and studied utilizing hematoxylin and eosin (H&E) staining, as well as via IHC. All techniques were performed as previously described [2,3].

IHC Double Staining

Our double staining was performed utilizing a Leica (Buffalo Grove, IL, USA) double staining system. Specifically, for primary staining we utilized a Bond Max platform autostainer with bond polymer refined red detection DS9390, an alkaline phosphatase linker polymer and fast red chromogen (red staining). For our secondary staining, we utilized bond polymer refined detection DS9800, a horseradish peroxidase linker polymer and DAB chromogen (brown staining). Positive and negative controls were consistently performed. We utilized antibodies directed against ribosomal protein S6-pS240 phosphorylation site specific (RIBO), Clone DAK-S6-240; cyclooxygenase-2 (COX-2), and immunoglobulin D (IgD), all from Dako (Carpinteria, CA, USA).

Microscopic Description

The H&E staining demonstrated focal confluent parakeratosis within the stratum corneum. In addition, scattered collections of neutrophils were seen within the stratum corneum. Overall, the epidermis displayed a mild psoriasiform hyperplasia. The stratum granulosum was focally attenuated. Minimal epidermal spongiosis was appreciated. Within the underlying dermis, a mild, perivascular infiltrate of lymphocytes, histiocytes and neutrophils was present (Fig. 1).

IHC Staining

Our IHC staining showed strong staining with COX-2, IgD and RIBO in the corneal layer. COX-2 and RIBO were very positive in cells around the inflamed dermal blood vessels under the epidermal lesions. The RIBO stain was most pronounced in the hyperproliferative regions of the epidermis (Fig. 1).

DISCUSSION

In this early case of psoriasis, we confirmed the presence of IgD, RIBO and COX-2. Each molecule seems to be playing a role at this stage of psoriasis. RIBO is integral to protein translation, and is activated by phosphorylation via the mammalian rapamycin pathway [6]. We found expression of RIBO, showing differential phosphorylation in

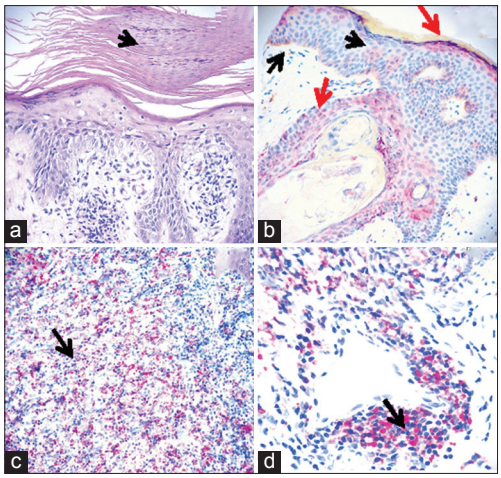

Figure 1: We highlight our main findings. (a) shows the psoriatic lesion using H&E staining with hyperkeratosis and Munro microabscesses (black arrow) (200X). (b) We present a double IHC stain with RIBO in red showing positivity in some spots in the corneal layer, as well as in the proliferative epidermis (red arrows) (200X). COX-2 is positive in different areas, mainly in discrete granular layer spots and at the basement membrane zone of the skin (black arrows, punctate brown staining). (c) Strong expression of COX-2 in the inflammatory infiltrate under a epidermal psoriatic lesion (red staining; black arrow)(100X) and a few cells staining positive for RIBO in brown. (d) A strong expression of COX-2 in the inflammatory infiltrate around dermal blood vessels (red staining; black arrow) (400X).

distinct epidermal layers; the expression was most pronounced in hyperproliferative regions. Based on our previous [2,3], and current findings and those of others, differential S6 phosphorylation may play a role in abnormal keratinocyte proliferation/differentiation in psoriasis, although only a few cases have been documented [2,3,5]. A larger series of cases is needed to adequately study the role of RIBO in intracellular pathways in psoriasis patients.

In regard to COX-2, we have previously shown positivity of this molecule in psoriatic skin and associated with inflammatory cells. Our findings here confirm our previous findings; however, the previous findings were in chronic cases [2,3]. Other authors in a recent study compared normal skin versus psoriatic skin; they compared the expression of both COX-2 and RIBO before and after treatment (using salt water baths and artificial ultraviolet (UVB) radiation, common therapeutic options for psoriasis) [6]. These authors studied the untreated versus the treated samples by testing COX-2 mRNA; this molecule was significantly increased in UVB irradiated normal psoriatic epidermis models versus normal skin [6].

Concerning the positivity of IgD, one previous study's findings are relevant to our present study. Other authors had studied the mean values of serum immunoglobulins

A, G, M and D levels in 42 psoriasis patients and controls, showing no differences between the groups [7]. They also searched for serum antiglobulin antibodies, yielding negative results; an antinuclear factor could be demonstrated in only 4.8% of the cases [7]. The authors suggested that serum antiglobulins became exhausted within the lesions; this hypothesis is supported by our preliminary findings of focal deposition in the stratum corneum of IgG, IgM and complement. Consulting the online PUBMED database, we could not found other studies linking IgD and psoriatic lesions.

In conclusion, our case of early psoriasis shows expression of IgD, RIBO and COX-2. Larger studies are needed to confirm any pathologic association between psoriasis and these molecules.

ACKNOWLEDGEMENT

Jonathan S. Jones, HT (ASCP) at Georgia Dermatopathology Associates provided excellent technical assistance.

Abbreviations

Hematoxylin and eosin (H&E), immunohistochemistry (IHC), cyclooxygenase-2 (COX-2), ribosomal protein S6-pS240 phosphorylation site specific (RIBO).

REFERENCES

1. Boehncke WH. Etiology and Pathogenesis of Psoriasis. Rheum Dis Clin North Am. 2015;41:665-75.
2. Abreu-Velez AM, Googe PB, Howard MS. Immune reactivity in psoriatic Munro-Saboureau microabscesses, stratum corneum and blood vessels. N Am J Med Sci. 2012;4:257-65.
3. Abreu-Velez AM, Googe PB, Jr, Howard MS. Ribosomal Protein S6-pS240 is expressed in lesional skin from patients with autoimmune skin blistering diseases. N Am J Med Sci. 2013;5:604–8.
4. Cai Y, Fleming C, Jun Yan J. New insights of T cells in the pathogenesis of psoriasis. Cell Mol Immunol. 2012;9:302–9.
5. Besgen P, Trommler P, Vollmer S, Prinz JC. Ezrin, maspin, peroxiredoxin 2, and heat shock protein 27: potential targets of a streptococcal-induced autoimmune response in psoriasis. J Immunol. 2010;184:5392–402.
6. Ruf MT, Andreoli A, Itin P, Pluschke G, Schmid P. Ribosomal protein S6 is hyperactivated and differentially phosphorylated in epidermal lesions of patients with psoriasis and atopic dermatitis. Br J Dermatol. 201;171:1533-6.
7. Gambichler T, Terras S, Skrygan M. Cyclooxygenase 2 expression and apoptosis in normal and psoriatic epidermis models exposed to salt water soaks and narrowband ultraviolet B radiation. J Eur Acad Dermatol Venereol. 2015;29:180-83.
8. Nickoloff BJ. Skin innate immune system in psoriasis: friend or foe? J Clin Invest. 1999;104:1161–4.

Source of Support: Nil, **Conflict of Interest:** None declared.

Case Report

Dermatitis herpetiformis: celiac disease of the skin. Report of two cases

Beatriz Di Martino Ortiz[1], Hugo Macchi[2], Celeste Valiente Rebull[3], María Lorena Re Dominguez[3], Guadalupe Barboza[3]

[1]*Dermatology Department, Clinicas Hospital, Faculty of Medical Sciences, National University of Ausunción-Paraguay,*
[2]*Department of Endoscopy, Clinicas Hospital, Faculty of Medical Sciences, National University of Ausunción-Paraguay,*
[3]*Clinicas Hospital, Faculty of Medical Sciences, National University of Ausunción-Paraguay*

Corresponding author: Prof. Dr. Beatriz Di Martino Ortiz, E-mail: beatrizdimartino@gmail.com

SUMMARY

Dermatitis herpetiformis or Duhring-Brocq disease is a chronic, autoimmune, pleomorphic disease, characterized by lesions on extension surfaces, accompanied by intense pruritus, and is usually associated with celiac disease, gluten sensitivity, gluten sensitivity ataxia and some forms of IgA neuropathy. Two cases of dermatitis herpetiformis are presented in female patients and we make a brief review of the literature on the treatment of this pathology.

Key words: Dermatitis herpetiformis; Duhring-Brocq disease; Celiac disease

INTRODUCTION

Dermatitis herpetiformis was first described by Louis Adolphus Duhring in 1884 at the University of Pennsylvania [1-3]. In 1888 Brocq described similar lesions diagnosed as "pruritic polymorphic dermatitis" [4]. It is also known as Duhring-Brocq disease [2-4]. However, the association of celiac disease, gluten-sensitive enteropathy and dermatitis herpetiformis was observed by Mards, Fry and Shuster in the 1960s [4].

It is characterized by the presence of IgA deposits in the dermal papillae [1,5].

Dermatitis herpetiformis is a chronic autoimmune subepidermal blistering disease with recurrent episodes where autoantibodies are not directed at any molecules of the dermoepidermal binding complex [3,6].

CLINICAL CASES

Case 1: 22 years old white female, from urban area of Paraguay, student. She presents a 9 months of evolution of raised reddish lesions, some with clear liquid content at the beginning, which then present crusts, accompanied by intense pruritus, initially in arms and legs, then in neck and abdomen. She auto medicate herself with topical clobetasol and moisturizing creams, with improvement of pruritus, that reappears when suspending. Deny relatives with similar pathology.

Physical examination shows multiple erythematous plaques and papules, some with blisters of citrus liquid content, others with crusts of 0.4 to 1.5 cm, net limits, regular borders, seated on forearms, buttocks, chest and abdomen (Figs. 1a and 1b).

Histopathological examination: histopathological subepidermal vesicles, with micro papillary neutrophil abscesses (Figs. 2a and 2b).

Direct immunofluorescence: granular IgA deposits in dermoepidermal junction.

Laboratories: HIV and VDRL negative.

Endoscopy: scalloping of folds and reduction in the number of folds.

How to cite this article: Di Martino Ortiz B, Macchi H, Rebull CV, Re Dominguez ML, Barboza G. Dermatitis herpetiformis: celiac disease of the skin. Report of two cases. Our Dermatol Online. 2018;9(1):44-47.
Submission: 09.03.2017; **Acceptance:** 30.06.2017
DOI: 10.7241/ourd.20181.13

Final diagnosis: Dermatitis herpetiformis.

Evolution: Betamethasone plus fusidic acid, antiallergic, but the patient does not return to the consultation.

Case 2: 8 years old White female, from urban area of Paraguay, student. She presents a picture of 1 year of evolution of raised reddish pruriginous lesions, some with clear liquid content, that break and cover of crusts, that initiate in elbows and extend to knees and buttocks. It is treated several times with Betamethasone with partial improvement. These lesions show irregular outbreaks.

Physical examination: erythematous plaques of 1 to 1.5 cm, net limits, irregular borders, some confluent, that settle on forearms and buttocks (Figs. 3a and 3b).

Histopathological examination: histopathological subepidermal vesicles, with micro papillary neutrophil abscesses (Figs. 4a and 4b).

Direct immunofluorescence: granular IgA deposits in dermoepidermal junction.

Laboratories: Anti-transglutaminase antibody IgA positive, anti-gliadin positive IgG antibody.

Endoscopy: scalloping of folds and reduction in the number of folds.

Final diagnosis: Dermatitis Herpetiformis.

Evolution: request consultation with Gastroenterology and gluten-free diet. Betamethasone and anti allergic. Good evolution.

DISCUSSION

Dermatitis herpetiformis is a relatively rare disease. It is observed mainly in men, in a proportion 2:1, predominates in the north of Europe and in Caucasians. The highest incidence is in Ireland, with 1 person affected per 300 inhabitants.

The family incidence is 2.3 to 6.5%, as well as concordance in twins and celiac disease [6].

It is exceptional in children under 3 years of age, and may appear at any age, but the peak incidence is in the third decade [5,6].

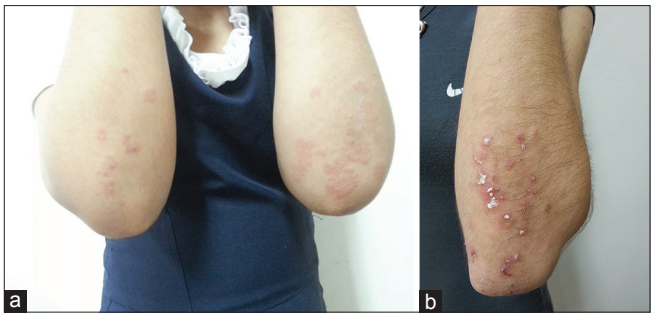

Figures 1: (a-b). Case 1. Clinic. Multiple erythematous plaques and papules, some with clear content vesicles, others with whitish crusts of 0.4 to 1.5 cm in diameter, net limits, regular borders, that settle on forearms, buttocks, chest and abdomen.

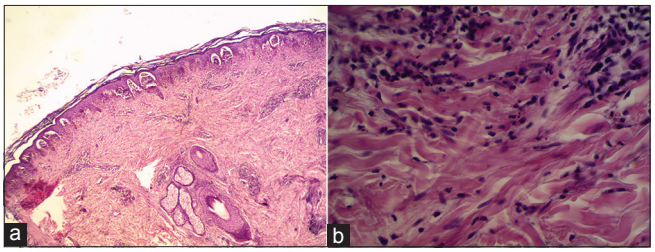

Figure 2: (a-b). Case 1. Histopathology. Subepidermal vesicles, with papillary neutrophil microabcesses, with neutrophil, some eosinophil and lymphocytes infiltrates in the superficial dermis.

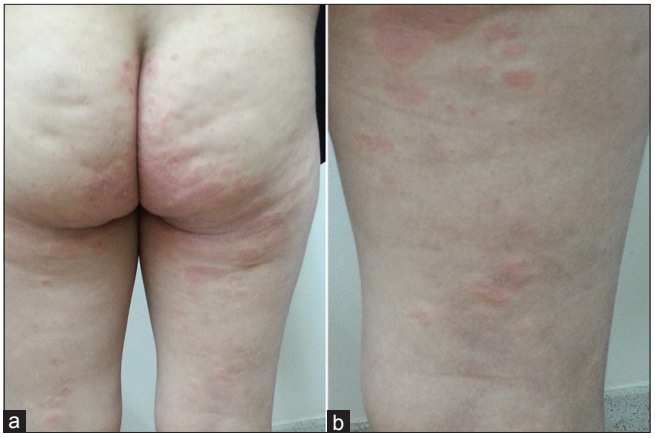

Figures 3: (a-b). Case 2. Clinic. Erythematous plaques of 1 to 1.5 cm diameter, net limits, irregular borders, some confluent that settle on forearms and buttocks.

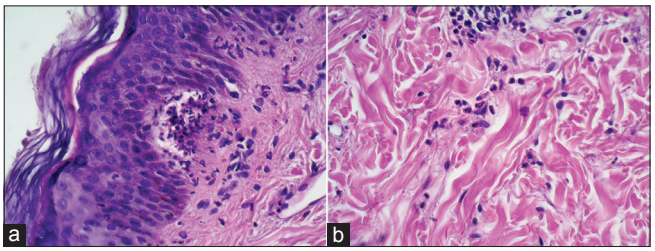

Figure 4: (a-b). Case 2. Histopathology. Subepidermal vesicles, with papillary neutrophil microabcesses, with neutrophil, eosinophil and lymphocytes infiltrates in the superficial dermis.

In pathogenesis, HLA DQ2 and HLA DQ8 haplotypes are known to be involved, both in dermatitis herpetiformis and in celiac disease [7,8]. 90% of patients are DQ2 positive, and the remaining DQ8 [5,6]. The association with HLA DR3, B8 and A1 explains the association with other autoimmune diseases [9].

The fundamental environmental factor in the development of both pathologies is the exposure to gluten, which causes the formation of autoantibodies against gliadin, which is the protein constituent thereof [6].

At the time of DH diagnosis, celiac disease is asymptomatic or is associated with malabsorption, but 60% is asymptomatic, with 60 to 70% of alterations in the intestinal biopsy [10]. However, there are no skin manifestations in those severe cases of celiac disease [6].

On physical examination, there may be present lesions such as papules, plaques, vesico blisters that develop commonly on extensor surfaces and buttocks, which are very itchy. In addition, excoriations, hyperpigmented scars may be present, because these lesions have periods of remission [1-10].

In children, it is common to find petechial or echimotic lesions in palmoplantar regions, especially at fingertips [6,7].

Mucosal involvement is rare, although IgA is frequently deposited in these regions [7]. Other less common forms are also seen as palmoplantar hyperkeratosis, purupuric lesions with the appearance of leukocytoclastic vasculitis and lesions that mimic prurigo pigmentosum [7,11].

Differential diagnoses arise with atopic dermatitis, scabies, prurigo, papular urticaria, eczema, and blistering lesions such as linear IgA dermatitis and pemphigoid. Other pathologies also to be ruled out are erythema multiforme, urticaria and prurigo in adults [6,11].

The diagnosis is clinical, histopathological, immunological and serological.

Histopathology shows subepidermal vesicles or blisters, with neutrophil abscesses in the dermal papillae, and occasionally eosinophils could be found in the dermal infiltrate, which makes it difficult for the differential diagnosis with the bullous pemphigoid. So the gold standard is the direct immunofluorescence [11].

Direct immunofluorescence shows the deposit of IgA in the basement membrane [11-13].

This deposit currently has 3 patterns [11]:

1. A granular pattern that is deposited on the dermal papillae.
2. A granular deposit in the basement membrane, and
3. A fibrillar IgA deposit in the dermal papillae.

In addition, deposits of perivascular IgA and in the upper dermis, as well as granular IgM or deposits of C3 in the dermoepidermal junction can be found [11].

Serological tests, especially anti-tissue transglutaminase IgA antibodies and antiendomysium, are sensitive and specific tools for initial detection of gluten-sensitive diseases as well as for dermatitis herpetiformis [13].

Tissue anti-transglutaminase antibodies are elevated in patients with intestinal activity and decreases with the adoption of a gluten free diet [7].

Epidermal anti-transglutaminase (eTG) antibodies are specific antigens of DH, but so far only for research purposes and not for the clinical management of patients [11].

DH is also associated with other autoimmune diseases, such as autoimmune thyroid diseases, pernicious anemia, gastric atrophy, type 1 diabetes mellitus, sarcoidosis, systemic lupus erythematosus, Schogren's disease, vitiligo and alopecia areata [7].

It is associated with an increased risk of non-Hodgkin lymphoma, T-cell lymphomas associated with enteropathy [6].

In patients with celiac disease/dermatitis herpetiformis, non-specific antibodies must be detected, such as antithyroid peroxidase (in almost 20% of patients), gastric parietal cells (in 10-25% of patients), antinuclear and anti- Ro/SSA. The presence of such antibodies correlates with the autoimmune predisposition of patients with celiac disease/dermatitis herpetiformis [13].

The treatment of DH is based on three pillars, first gluten-free diet, medical treatment that could be with dapsone or sulfapyridine and avoid NSAIDs and iodides [14].

The gluten-free diet must be for life, the same, is effective for the disappearance of skin lesions and

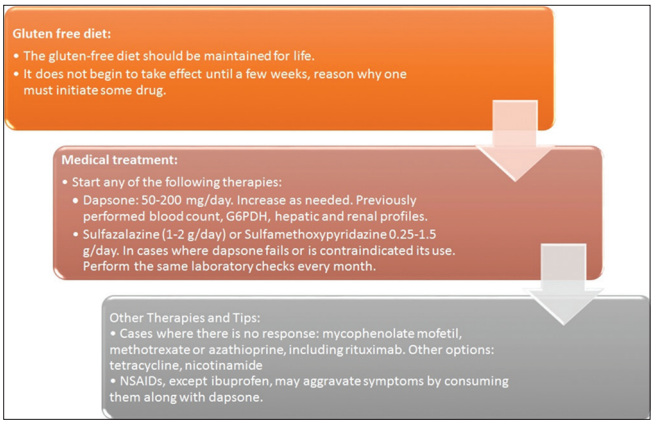

Box 1: Treatment of DH.

digestive manifestations. It also reduces or decreases medication, resulting in the resolution of enteropathy, corrects malabsorption and prevents lymphomas.

Dapsone treatment is effective, it rapidly achieves an improvement in skin lesions and has no effect on gastrointestinal pathology, it has no curative effects [14].

It starts at low doses of 50 mg/day and is progressively increased to 200 mg/day according to the needs of the patient. Plasma G6PDH dosage, blood count, renal and hepatic function should be performed, which are controlled weekly, bi weekly during the first month, monthly during the first three months and then every 3 to 6 months. Methemoglobinemis and hemolysis are dose dependent in many cases [9].

The use of sulfasalazine and sulfamethoxypyridazine are in cases in which treatment with dapsone fails or presents side effects. The suggested dose is 1-2 g/day for sulfazalazine and 0.25-1.5 g/day for sulfamethoxypyridazine. Laboratory controls are performed monthly [14].

Topical corticosteroids are not very effective, but if there is impetiginization, topical antibiotics should be administered [9,14].

In cases in which there is no response to treatment with gluten and dapsone free diet, immunosuppressants such as mycophenolate mofetil, methotrexate or azathioprine, including rituximab, may be indicated. Other options could be tetracycline, nicotinamide [14,15].

NSAIDs, other than ibuprofen, have been shown to aggravate symptoms when taken together with dapsone, such as pruritus and rash [15]. The treatment is sumarized in box 1.

CONCLUSION

In summary patients with celiac disease may develop DH by any time. This is most often an indicator of poor adherence to GFD, and a rigorous dietary intervention is necessary. In the majority of cases, DH will be detected without prior celiac disease diagnosis, but the physicians should recognize this phenotype alteration.

REFERENCES

1. Pérez Cortés S, de Peña Ortíz J, Ramos Garibay A, Pérez Maciel CA. Dermatitis herpetiforme. Rev Cent Dermatol Pascua. 2007;16:137-42.
2. Miller JL, Zaman SA, Hall R. Editor board: Wells MJ, Nunley JR. Chief Editor: Elston DM. Dermatitis herpetiformis. Updated: Mar 31, 2016. Disponible en: http://emedicine.medscape.com/article/1062640.
3. Plotnikova N, Miller JL. Dermatitis herpetiformis. Skin Therapy Lett. 2013;18:1-3.
4. Mendes FBR, Hissa-Elian A, Abreu MAMM, Gonçalves VS. Review: dermatitis herpetiformis. An Bras Dermatol. 2013;88:594-9.
5. Herrero-González JE. Guía clínica de diagnóstico y tratamiento de la dermatitis herpetiforme. Actas Dermosifiliogr. 2010;101:820–6.
6. Iranzo Fernández P. Dermatitis herpetiforme. Patogenia, diagnóstico y tratamiento. Med Cutan Iber Lat Am. 2010;38:5-15.
7. Clarindo MV, Possebon AT, Soligo EM, Uyeda H, Ruaro RT, Empinotti JC. Dermatitis herpetiformis: pathophysiology, clinical presentation, diagnosis and treatment. An Bras Dermatol. 2014;89:865-77.
8. Bonciani D, Verdelli A, Bonciolini V, D´Errico A, Antiga E, Fabbri P, et al. Dermatitis herpetiformis: from the genetics to the development of skin lesions. Clin Develop Immunol. 2012:1-5.
9. Sanjinés L, Martínez M, Magliano J. Dermatitis herpetiforme como carta de presentación de la enfermedad celíaca. Rev Urug Med Interna. 2016;1:5-11.
10. Alonso-Llamazares J, Gibson LE, Rogers RS 3rd. Clinical, pathologic, and immunopathologic features of dermatitis herpetiformis: review of the Mayo Clinic experience. Int J Dermatol. 2007;46: 910-9.
11. Antiga E, Caproni M. The diagnosis and treatment of dermatitis herpetiformis. Clin Cosmet Investig Dermatol. 2015;8:257–65.
12. Reunala T, Salmi TT, Hervonen K. Dermatitis herpetiformis: patognomonic trasglutaminase IgA deposits in the skin and excellent prognosis on a gluten-free diet. Acta Derm Venereol. 2015;95:917–92.
13. Caproni M, Antiga E, Melani L, Fabbri P. Guidelines for the diagnosis and treatment of dermatitis herpetiformis. JEADV. 2009;23:633-8.
14. American gastroenterological association medical position statement: Celiac sprue. Gastroenterology. 2001;120:1522-5.
15. Da Silva Kotze L. Dermatitis herpetiformis, the celiac disease of the skin. Arq Gastroenterol. 2013;50:231-5.

Source of Support: Nil, **Conflict of Interest:** None declared.

Case Report

Vitiligo on tribal mark: A demostration of Wolf's isotopic response

Mufutau Muphy Oripelaye, Olaniyi Onayemi, Olayinka Abimbola Olasode, Fatai Olatunde Olanrewaju

Department of Dermatology, Obafemi Awolowo University, Ile-Ife, Osun state, Nigeria

Corresponding author: Dr. Mufutau Muphy Oripelaye, E-mail: mmoripe@yahoo.co.uk

ABSTRACT

Background: Wolf's isotopic response is the development of new lesions on old scar. Although this phenomenon is uncommon, most of the reported cases have been associated with development new lesions on the previously healed scar of herpes zoster infections. **Case Report:** Our patient is 74 year old woman with generalized vitiligo who demonstrated Wolf's isotopic response by developing new lesions of vitiligo along the track of old scar (tribal mark). **Conclusion:** The exhibition of Wolf's Isotopic response on old tribal mark, may transform a benign, asymptomatic tribal mark into a clinically significant feature which may aid the diagnosis of vitiligo.

Key words: Vitiligo; Wolf's isotopic response; Tribal mark

INTRODUCTION

Koebner phenomenon is the development of new lesions in a normal skin following injury and it is a well-documented feature of vitiligo [1]. The appearance of a new skin disease on a healed scar of an old lesion known as Wolf's Isotopic response are not frequently reported. We present a 74 year old woman who presented with features of Wolf's Isotopic response by the development of vitiligo on tribal mark.

CASE REPORT WOLF'S PHENOMENON

We present a 74year old Nigeria woman of Yoruba extraction. She presented with a complain of generalize loss of skin colour (depigmentation) of 2 years duration. The skin depigmentation was notice on the face, the upper and the lower limbs as well as the trunk. The depigmentation has been increasing in severity from the time it was first noticed 2 years ago.

The patient was otherwise well except for the cosmetic distress cause by depigmentation. There is no history of associated fever, no history of oral ulcer or genital ulcer. She has no present or past history of shingles, and no associated autoimmune disease was found in the patient. She has never handle nor worked with chemicals known to cause skin depigmentation. There is no history of facial itching upon application of any cosmetic product. She is not known to react to any cosmetic product.

She was born to Yoruba parents 74 years ago and as part of the prevailing cultural practices at time, she had a tribal incision on her cheeks. She had lived all her life with the tribal marks on her face and has come to accept it as part of her identity. The scar has expectedly been asymptomatic. However, 2 years ago, with the onset of generalize depigmentation, similar depigmentation has also developed along the line of the scar, sparring other parts of the face. Examination of her skin shows symmetrical depigmentations involving the upper and lower limbs as well as trunk. A track of depigmented macules was observed on the two inferiorly located scarification mark (tribal mark) of both cheeks.

Her blood sugar including the fasting blood sugar and two hour post prandial were within normal limit. She

How to cite this article: Oripelaye MM, Onayemi O, Olasode OA, Olanrewaju FO. Vitiligo on tribal mark: A demostration of Wolf's isotopic response. Our Dermatol Online. 2017;9(1):48-50.

Submission: 12.04.2017; **Acceptance:** 21.10.2017

DOI: 10.7241/ourd.20181.14

was seronegative for HIV, Hepatitis B infection and hepatitis C infection. The VDRL was also negative.

The assessment of generalize vitiligo was made and the demonstrated wolf's isotopic phenomenon observed in the scars of tribal mark was noted.

DISCUSSION

Vitiligo is an acquired disorder of pigmentation characterize by idiopathic loss of melanocyte. The melanocyte loss results in depigmented skin lesions associated with vitiligo. Useful but non-specific signs or phenomenon that may be used in the diagnosis of vitiligo is the Koebner phenomenon [1]. In addition to the koebner phenomenon which has been described in association with vitiligo, other variations that may be found includes trichrome vitiligo, which presents with overlapping areas of hypopigmentation, depigmented and normal coloured skin. Quadrichrome vitiligo which may also aid the diagnosis of vitiligo is the occurrence of perifolicular repigmentation in association with trichrome vitiligo [2].

Koebner phenomenon is the development of skin lesion following injury in a patient that has similar lesion in other part of the body [3]. Opinion varies on whether koebner phenomenon could impede the surgical management of vitiligo, since the associated surgical injury at the donor site can initiate new vitiligo lesion. However in the stable state it is believed such injury may not induce new lesions [4]. While inflicting injury could results in the development of new lesions, it can also lead to the clearance or healing of an existing skin lesion. This phenomenon known as reverse koebner has been described in psoriasis [3].

Also fascinating was the description of skin lesion on the site of a healed or old scar by Wolf et al. This description was termed wolf's isotopic response [5]. This response has been observed in few healed dermatological lesions. Mankesh et al reported development of herpes zoster on stable lesion of a vitiligo [6]. A track of depigmented macules was observed on the two inferiorly located scarification mark (tribal mark) of both cheeks (Figs. 1a and 1b).

As in koebner phenomenon, the cause of Wolf's isotopic phenomenon is not known. However, viral induced neuroimmune dysfunction has been suggested because of the association of this phenomenon with herpes zoster. Other suspected causes are immune mediated,

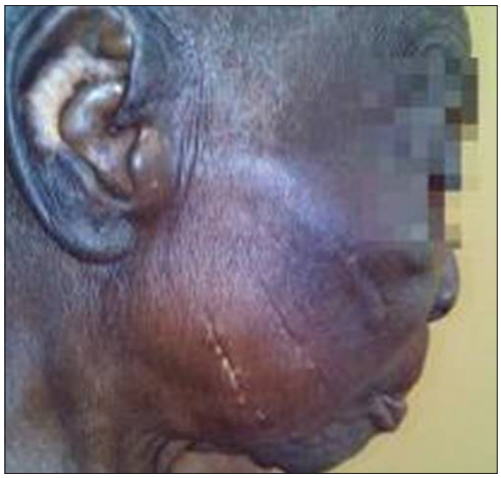

Figure 1a: A track of depigmentation on the inferior scars (tribal mark) of the right cheek.

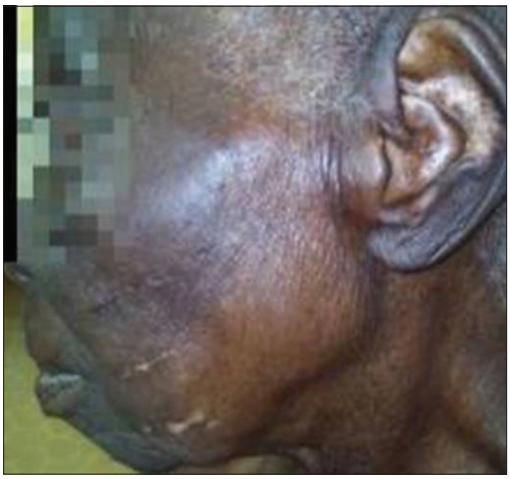

Figure 1b: A track of depigmentation on the inferior scars (tribal mark) of the left cheek.

neural and vascular dysfunction [5]. Most of the dermatoses which have been reported to demonstrate the wolf's isotopic phenomenon were related to the healed scars of herpes zoster infections [7]. However, in our patient, neither the healed scar (tribal mark) nor the developing lesions (vitiligo) were related to herpes zoster infection. The presence of the vitiligo on the scar of both cheeks also diminished the possibility of an association with herpes zoster which is likely to be dermatomal and unilateral. The healed scars of varicella, herpes simplex, scrofuloderma and striae distense have also been associated with wolf's isotopic response [4,8]. Our patient does present differently with the healed scar of a tribal mark.

While the cause of vitiligo is not known, viral theory has been suggested among the several theories proposed to explain its cause. Chronic hepatitis C infections and hepatitis B has been reported as in some patients

with vitiligo [9]. Although these were not present in our patient. Other virus in the herpes group such as herpes simplex, cytomegalovirus and Ebsein-Barr virus although suspected, have not been satisfactorily established as cause of vitiligo [9,10]. While the presence of any of these viruses would have favoured virally induced neuroimmune dysfunction as a probable mechanism of the wolf isotopic phenomenon, none of these viruses were however identified in our patients.

CONCLUSION

The practice / culture of incising the checks has been on the decline, the impact of the scar (tribal mark) may be well beyond the cosmetic nuisance it caused in the patient since it may induce wolf isotopic phenomenon as depicted by our patient. Corroborating this observation with further studies will add clinical signs and phenomenon aiding the clinical diagnosis of vitiligo.

REFERENCES

1. Van Geel N, Speeckaert R, De Wolf J, Bracke S, Chevolet I, Brochez L, et al. Clinical significance of Koebner phenomenon in vitiligo. Br J Dermatol. 2012;167:1017-24.
2. Kovacs SO. Vitiligo. J Am Acad Dermatol. 1998;38:647-66.
3. Thappa DM. The isomorphic phenomenon of Koebner. Indian J Dermatol Venereo Leprol. 2004;70:187-9.
4. Mulekar SV, Asaad M, Ghwish B, Al Issa A, Al Eisa A. Koebner Phenomenon in Vitiligo: Not Always an Indication of Surgical Failure. Arch Dermatol. 2007;143:799-816.
5. Wolf R, Brenner S, Ruocco V, Filioli FG. Isotopic response. Int J Dermatol. 1995;34:341-8.
6. Lal Gambhir M, Pandey K, Kaur T. Herpes zoster on segmental vitiligo: isotopic response? Our Dermatol Online. 2014;5:155-6.
7. Shemer A, Weiss G, Trau H. Wolf's isotopic response: A case of zosteriform lichen planus on the site of healed herpes zoster. J Eur Acad Dermatol Venereol. 2001;15:445-7.
8. Requena L, Kutzner H, Escalonilla P, Ortiz S, Schaller JS, Rohwedders A. Cutaneous reactions at sites of herpes zoster scars: an expanded spectrum. Br J Dermatol. 1998;138:161-8.
9. Akcan Y, Kavak A, Sertbas Y, Olut AI, Korkut E, Bicik Z, et al. The low seropositivity of hepatitis B virus in vitiligo patients. J Eur Acad Dermatol Venereol. 2006;20:110-11.
10. Toker SC, Sarycaoglu H, Karadogan SK, Mistik R, Baskan EB, Tunaly S. Is there any relation between vitiligo and cytomegalovirus? J Eur Acad Dermatol Venereol. 2007;21:141-2.

Source of Support: Nil, **Conflict of Interest:** None declared.

Case Report

Dermoscopic surprises in a series of 6 cases

Subrata Malakar, Purva Mehta, Samipa Mukherjee, Surit Malakar

Rita Skin Foundation, Kolkata, India

Corresponding author: Dr. Purva Mehta, E-mail: purvamehta86@gmail.com

ABSTRACT

Dermoscopy is a non invasive technique which can be a fantastic diagnostic tool in dermatology. Here we present a series of six cases where a dermoscopy threw light on the clinical diagnosis of lesions. Case 1A, 1B and 1C presented with singular papular lesions which led us to differential diagnosis of viral infections, seborrheic keratoses etc. However, on dermoscopy all three cases exhibited a white mass with a keratin plug and peripheral hair pin blood vessels. Our second case presented with a nodule on the nose leading us to a diagnosis of an intradermal nevus. Dermoscopy of this lesion demonstrated the presence of arborizing vessels thus indicating something far more sinister than a nevus. Case 3 was a female who presented with a small asymptomatic lobulated mass leading us to consider either seborrheic keratosis or dermatofibroma as diagnosis. But the dermoscopy correctly showed the presence of lacunae and a whitish veil which established the final diagnosis. Our final case presented with a greyish nodule suggestive of dermatofibroma. On dermoscopy, the presence of cerebriform structures and comedo like openings on the background of a white scar like patch highlighted the superimposition of another lesion on the existing dermatofibroma. Our cases prove the utility of dermoscopy as a diagnostic tool in clinical dermatology.

Key words: Dermoscopy; Hair pin vessels; Arborizing vessels

INTRODUCTION

Dermoscopy has revolutionised the non invasive methodology of clinical diagnosis in the field of dermatology. It not only exhibits the subsurface features invisible to the naked eye but also guides us to an accurate diagnosis. Here, we present a conundrum of several cases where the discrepancy between our clinical suspicion and the actual diagnosis was highlighted by the simple yet effective use of a dermoscopy.

CASE REPORT

Case 1A

A 40 year old male presented to us with a lesion on the upper lip since a few years. The lesion was asymptomatic and static in nature. On cutaneous examination, there was a singular, firm, sessile, skin coloured papular lesion measuring 0.5 X 0.5 cm in size, with two to three hair protruding from it (Fig. 1).

On the basis of clinical examination we came to a differential diagnosis of compound nevus, verruca vulgaris, molluscum contagiosum and seborrheic keratosis. On dermoscopy, there was a white mass with central yellow keratin crusts surrounded by a paler dull white structureless zone. Blood spots were also noticeable in the centre of the white keratin mass. At the periphery of the mass there was a radial disribution of hair pin blood vessels (Fig. 2).

Thus the dermoscopic examination clinched the diagnosis of keratoacanthoma.

Case 1B

A 35 year old female patient presented to us with a lesion on the nose since a couple of years. The lesion was asymptomatic in nature and static in size. Cutaneous examination revealed a single, firm, pea sized, brown to black coloured sessile papule on the nose (Fig. 3).

How to cite this article: Malakar S, Mehta P, Mukherjee S, Malakar S. Dermoscopic surprises in a series of 6 cases. Our Dermatol Online. 2018;9(1):51-56.
Submission: 15.02.2017; **Acceptance:** 06.07.2017
DOI: 10.7241/ourd.20181.15

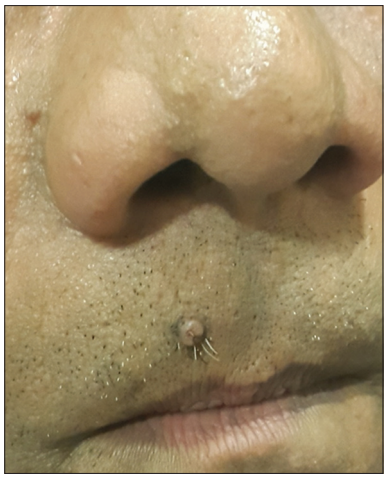

Figure 1: Singular, firm, sessile, skin coloured papular lesion on the upper lip.

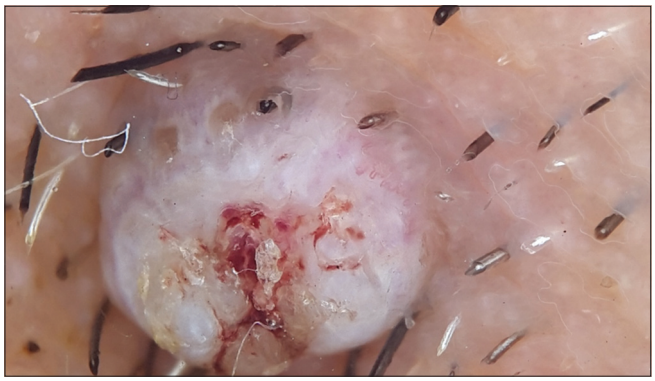

Figure 2: White coloured structure with central yellow keratin crusts and blood spots with hair pin blood vessels (arrow) arranged along the periphery of the structure.

Considering the clinical appearance of the lesion, we thought of seborrheic keratosis, compound nevus, verruca vulgaris and solitary fibrous papule of the nose as differential diagnosis. To confirm our clinical suspicion we used a dermoscopy. On dermoscopic examination, there was a dome shaped white mass. At the centre of this dome shaped mass, there was a keratin plug which was surrounded by a white structureless zone. At the periphery of the mass, we observed hair pin blood vessels (Fig. 4).

This fulfilled most of the dermoscopic diagnostic criteria for keratoacanthoma and a final diagnosis of solitary keratoacanthoma was made.

Case 1C

A 43 year old male presented with a lesion on his left forearm since few months. The lesion was essentially asymptomatic in nature with no change in size. Cutaneous examination revealed a solitary, skin coloured dome shaped nodule with central scaling (Fig. 5).

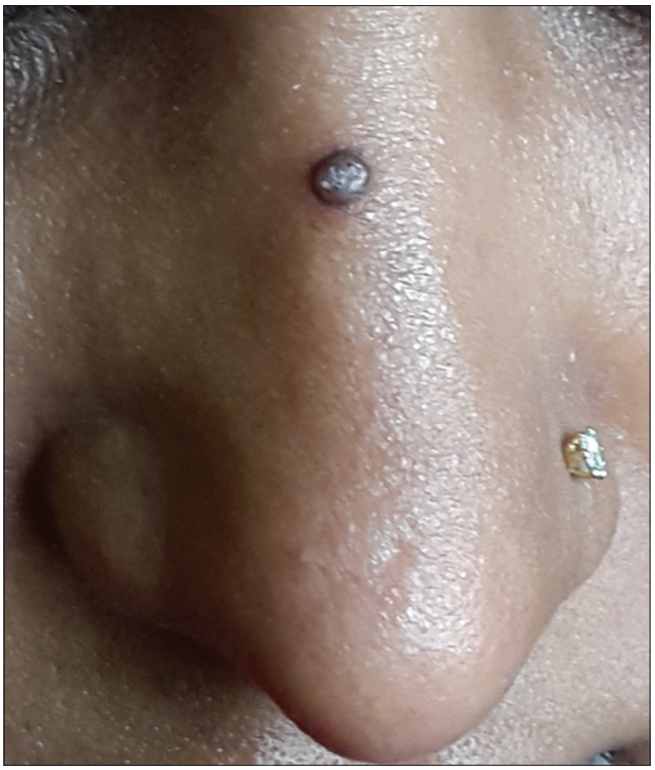

Figure 3: Single, firm, pea sized, brown to black coloured sessile papule on the nose.

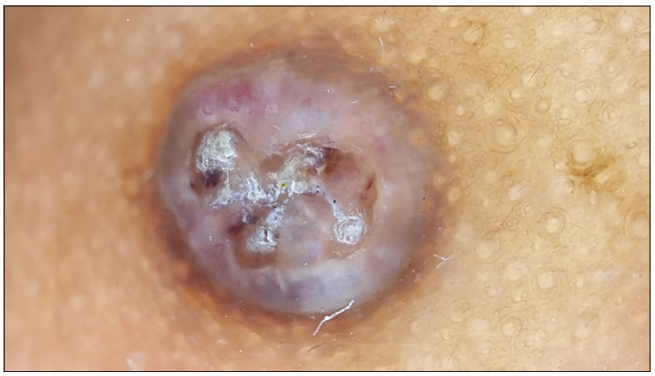

Figure 4: Dome shaped mass with central keratin and peripheral hair pin vessels (arrow).

Clinical appearance led us to molluscum contagiosum or verruca vulgaris as differential diagnosis. Dermoscopy, however revealed a surprisingly different picture. On dermoscopic examination, there was a white mass with central yellow keratin surrounded by a white structureless zone (Fig. 6).

A dermoscope yet again surprised us as it confirmed that the lesion was a keratoacanthoma and ruled out our clinical suspicions completely.

Case 2

A 45 year old male presented to us with a lesion on the nose since a few months. The lesion was asymptomatic in nature but had gradually increased in size over the last one month. On cutaneous examination, there was a solitary, skin coloured, ovoid nodule measuring 1.5 X 1.5 cms on the nose (Fig. 7).

The differentials that came to our mind were intradermal nevus, solitary angiofibroma and solitary fibrous papule of the nose.

However, the non invasive technique of dermoscopy had a surprise in store. Dermoscopy of the nasal lesion revealed arborising telangiectatic vessels coursing throughout the lesion. These vessels were branching at irregular intervals into thin capillaries and were bright red in colour. On closer examination, dermoscopy also highlighted that these arborizing vessels were sharp in focus and their borders were abruptly cut off (Fig. 8).

The dermoscopic picture was diagnostic of basal cell carcinoma. Arborising vessels are not a dermoscopic feature of either nevus, angiofibroma or solitary fibrous papule of nose. Dermoscopy thus eliminated all our clinical suspicions and led us to an accurate diagnosis. The patient was then subjected to an excision biopsy and the excised specimen was sent for histopathological examination.

Histological analysis showed nests of basaloid epithelial cells in the dermis with hyperchromatic nucelii and a peripheral palisading pattern all embedded in fibrous septae. Keratin pearls were also present in the dermis. Thus, histopathology confirmed our dermoscopic findings and labelled the lesion to be keratotic basal cell carcinoma (Fig. 9).

Case 3

A 22 year old female presented to us with a lesion on the right knee since several years. The lesion was essentially asymptomatic and stable in size. Cutaneous examination revealed a singular, gray to brown coloured, lobulated mass measuring 1 cm X 0.5 cm in size on the right knee (Fig. 10).

Clinical appearance of the lesion led us to a differential diagnosis of seborrheic keratosis and dermatofibroma. However, the use of dermoscopy, yet again proved valuable in unmasking the accurate diagnosis. On dermoscopy, there were several, round to oval well demarcated red to blue lacunae with a whitish veil (Fig. 11).

The dermoscopic feature was diagnostic of angiokeratoma ruling out all our clinical suspicions.

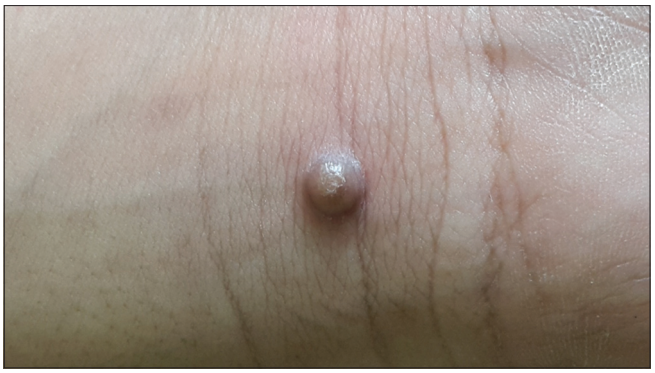

Figure 5: Solitary, skin coloured dome shaped nodule with central scaling.

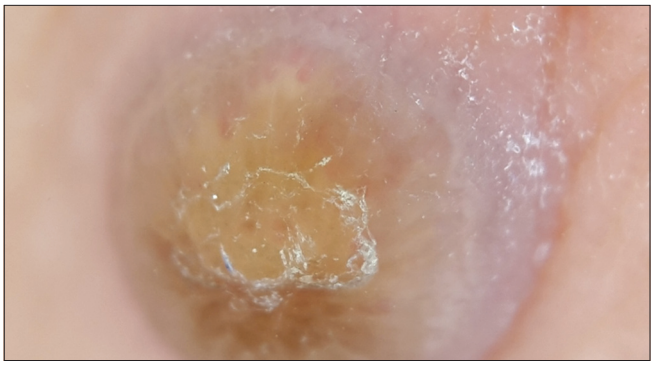

Figure 6: White coloured mass with central yellow keratin (arrow) surrounded by a white structureless zone.

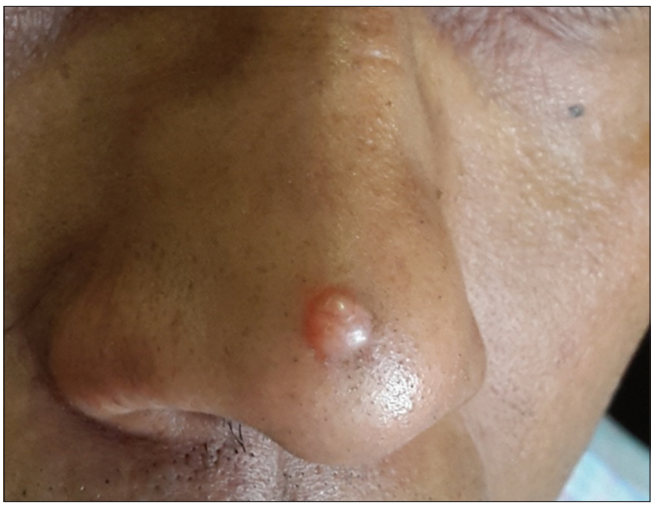

Figure 7: Solitary, skin coloured, ovoid papulonodule on the nose.

Case 4

A 57 year old female came with complaints of a lesion on the left thigh which was present since several years. She had no symptoms regarding the lesion and it was static in size. On clinical examination, there was a violaceous to grey nodule measuring 1 X 0.5 cms in size which was firm in consistency (Fig. 12).

The clinical appearance of the lesion was suggestive of dermatofibroma. However, the dermoscopy as always had more to convey. Dermoscopic examination revealed cerebriform structures with comedo like openings on the background of a white scar like patch (Fig. 13).

DISCUSSION

Epiluminescence microscopy in these 3 cases was an eye opener as the clinical picture and the actual diagnosis were miles apart. The white mass with central blood spots and keratin crusts along with the characteristic peripheral arrangement of hair pin blood vessels is diagnostic of keratoacanthoma [1]. Also, the peripheral arrangement of hair pin blood vessels favours a diagnosis of keratoacanthoma over seborrheic keratosis in which the hair pin vessels are evenly distributed throughout the lesion [2]. The use of dermoscopy ruled out one of our clinical suspicions of compound nevus as comma vessels; which are a key dermoscopic feature of intradermal melanocytic nevi were missing [3]. The dermoscopic vascular pattern of homogenous dots and globules, red to black in colour was absent ruling out verruca vulgaris [4]. The absence of crown vessels at the periphery in a radial distribution ruled out another clinical differential diagnosis of molluscum contagiosum [5].

The presence of hair around the lesion in case 1A was intriguing. That could be attributed to the hesitancy of the patient to shave or trim that particular area owing to the presence of the lesion.

Keratoacanthoma and squamous cell carcinoma are quite indistinguishable clinically and dermoscopically. However, the presence of central keratin favours a diagnosis of keratoacanthoma over squamous cell carcinoma. This finding is crucial as it correlates to a central keratin plug on histopathology of keratoacanthoma [1].

Dermoscopy is an excellent non invasive tool as it not only maginifies the subtle characteristics of a lesion but also throws light on the vascular patterns of the lesion. Identification of the vascular pattern is often imperative for the diagnosis of basal cell carcinoma as most of them are non pigmented. Arborising branching vessels which are hallmark for basal cell carcinoma are defined as large calibre vessels which are in focus and branch into finer secondary vessels. Arborising branching vessels are a dermoscopic feature of both basal cell carcinoma and adnexal tumours. However the clinical picture went against the diagnosis of an adnexal tumour as the lesion was solitary and larger in size whereas adnexal tumours tend to be multiple and smaller in size. The dermoscopy also helps to pinpoint the location of the

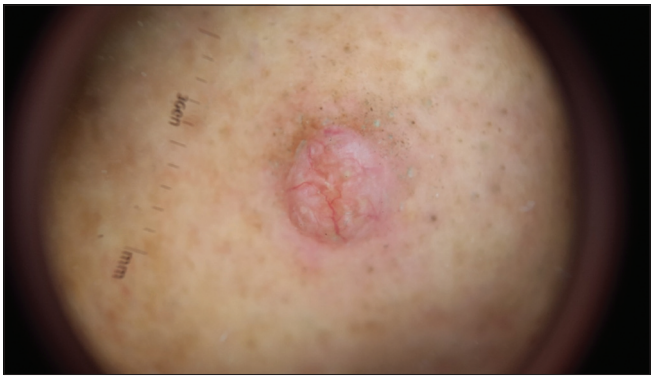

Figure 8: Arborising telangiectatic vessels (arrow) coursing throughout the lesion.

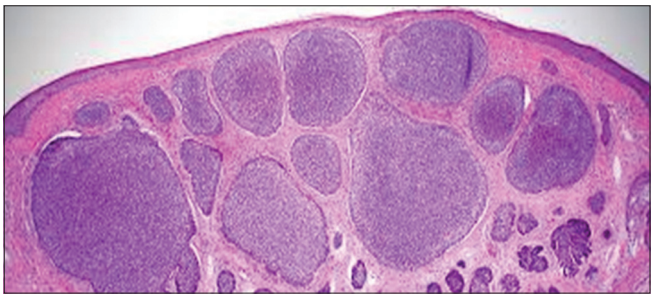

Figure 9: Nests of basaloid cells in the dermis with hyperchromatic nuclei and a peripheral palisading pattern.

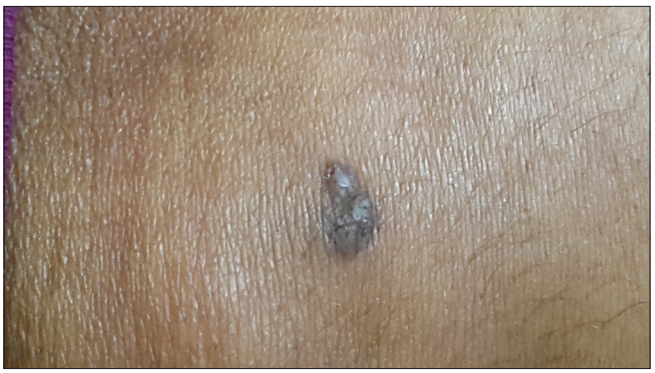

Figure 10: Singular, soft to firm, grey brown lobulated mass on the right knee.

blood vessels by highlighting the colour of the vessels and their characteristic morphology and architectural arrangement. The linear pattern of the blood vessels in our case confirmed their superficial location in the dermis as deeper dermal vessels would have appeared as pin point dots. The linearity of the blood vessels also suggested that they ran parallel to the skin surface where as blood vessels that ran perpendicular to the skin surface would have been viewed as dots or loops. Also the vessels were bright red in colour, prominent to the eye and "in focus" reaffirming their location in the upper dermis. On the other hand, connective tissue in the dermis causes dispersion of light and this would make deeper dermal vessels appear as pink dots, less prominent and out of focus [2].

Dermoscopy once again confirmed that clinical appearances are often misleading and appreciation of subsurface features can lead us to a correct diagnosis. The presence of red to blue lacunae with a whitish veil are diagnostic of angiokeratomas on dermoscopy. In this case, there was absence of hair pin vessels which are a diagnostic hallmark for seborrheic keratosis. The absence of dotted, comma or hairpin vessels ruled out our clinical suspicion of dermatofibroma [6]. Also the diagnostic dermoscopic features of dermatofibroma like pigment network and central white patch were missing [7]. The lacunae in angiokeratomas histologically correspond to dilated vessels which are either partially or completed thrombosed in the dermis. Hyperkeratosis and acanthosis are the histological markers for the whitish veil found on dermoscopy [8].

Dermoscopy thus revealed that in addition to our clinical diagnosis of dermatofibroma, there was a lesion of seborrheic keratosis which was superimposed on top of the dermatofibroma. There are several patterns of dermatofiroma on dermoscopy. Out of all the patterns, peripheral delicate pigment like network with central white scar like patch is the most common. However, in some cases, dermatofibromas may exhibit only a white scar like patch with no pigment network as in our case. The white scar like patch is a sharply demarcated but irregularly defined white area. It histologically correlates to fibrosis in the papillary dermis [9]. Comedo like openings and milia like cysts are the classical diagnostic criteria for seborrheic keratosis on dermoscopy. However, apart from the classical criteria, presence of other criteria like cerebriform structures or brain like appearance improves the diagnostic accuracy of seborrheic keratoses. The presence of multiple fissures contribute

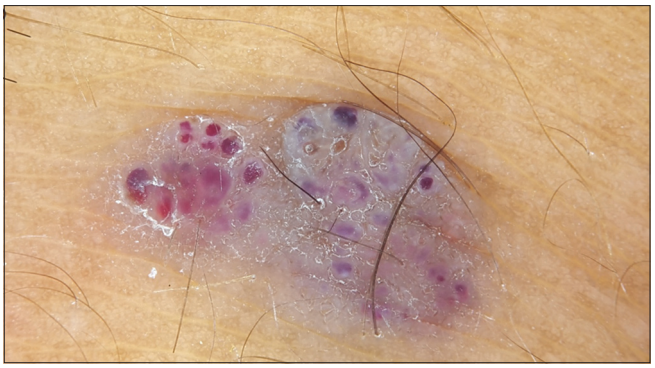

Figure 11: Well demarcated, round to oval, red to blue lacunae (arrow) with a whitish veil.

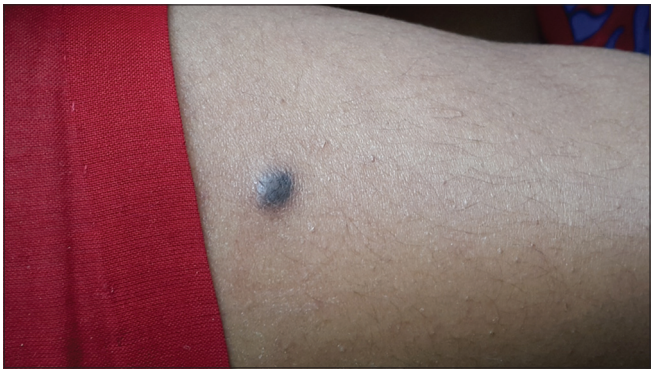

Figure 12: Single, violaceous to grey, firm nodule on the left thigh.

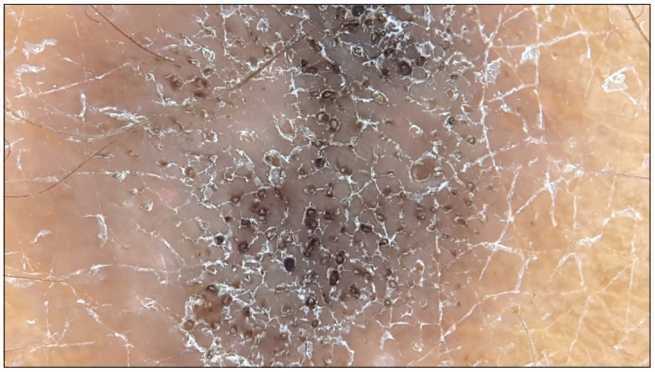

Figure 13: Cerebriform structures (red arrow) with comedo like openings (black arrow) against a background of scar like white patch (blue arrow).

CONCLUSION

We cannot further emphasize the importance of dermoscopy in clinical practice. In all our cases, dermoscopy took us by surprise as the dermoscopic diagnosis was vastly different than what met the eye. In each case, dermoscopy revealed surprising findings underlining the fact that dermatological lesions have heterogenous and atypical appearances and clinical acumen alone may not be sufficient. In such cases, the simple use of a non invasive technique like dermoscopy

can do wonders to lead us to an accurate and informed diagnosis. We beseech the dermatologiocal community to use a dermoscopy as a regular out patient tool as the outcome is often astonishing.

REFERENCES

1. Rosendahl C, Cameron A, Argenziano G, Zalaudek I, Tschandl P, Kittler H. Dermoscopy of Squamous Cell Carcinoma and Keratoacanthoma. Arch Dermatol. 2012;148:1-7.
2. Zalaudek I, Kreusch J, Giacomel J, Ferrara G, Catricalà C, Argenziano G. How to diagnose non pigmented skin tumours: A review of vascular structures seen with dermoscopy. Part I. Melanocytic skin tumours. J Am Acad Dermatol. 2010;63:361-74.
3. Argenziano G, Zalaudek I, Corona R, Sera F, Cicale L, Petrillo G, et al. Vascular structures in skin tumours. A dermoscopic study. Arch Dermatol. 2004;140:1485-19.
4. Bae JM, Kang H, Kim HO. Differential diagnosis of plantar wart from corn, callus and healed wart with the aid of dermoscopy. Br J Dermatol. 2009;160:220-2.
5. Zalaudek I, Kreusch J, Giacomel J, Ferrara G, Catricalà C, Argenziano G. How to diagnose non pigmented skin tumours: A review of vascular structures seen with dermoscopy. Part II. Non melanocytic skin tumours. J Am Acad Dermatol. 2010;63:377-86.
6. Martin JM, Bella-Navarro R, Jorda E. Vascular patterns in Dermoscopy. Actas Dermosifiliogr. 2012;103:357-75.
7. Arpaia N, Cassano N, Vena GA. Dermoscopic patterns of dermatofibroma. Dermatol Surg. 2005;31:1336-9.
8. Zaballos P, Daufi C, Puig S, Argenziano G, Moreno-Ramirez D, Cabo H, et al. Dermoscopy of solitary angiokeratoma: a morphological study. Arch Dermatol. 2007;143:318-25.
9. Zaballos P, Puig S, Llambrich A, Malvehy J. Dermoscopy of Dermatofibromas: A Prospective Morphological Study of 412 Cases. Arch Dermatol. 2008;144:75-83.
10. Braun RP, Rabinovitz HS, Krischer J. Dermoscopy of Pigmented Seborrheic Keratosis: A Morphological Study. Arch Dermatol. 2002;138:1556-60.

Source of Support: Nil, **Conflict of Interest:** None declared.

Case Report

Preauricular full-thickness skin grafting in medial canthal reconstruction

Rafael Corredor-Osorio

Corredor Ocular Center of Specialized Ophthalmology. Av. Bolívar, CC Las Acacias, local 31, Valera (Trujillo), Venezuela

Corresponding author: Rafael Corredor-Osorio, MD., E-mail: raficorredor@yahoo.com

ABSTRACT

Basal cell carcinoma in medial canthal is a surgical challenge to oculoplastic surgeon. We report a case an 80 –year-old woman who presented with a vegetative tumor in the right inferior medial canthus that increased slowly in size over the past two years. An excisional biopsy from the tumor was suggestive of a basal cell carcinoma. A full-thickness excision of the tumor within the oncologic safety limits, was performed. A wide range of reconstruction techniques should be customized to the individual patient. In this case, the use of a preauricular full. Thickness skin graft was a favorable option, without complications, and with acceptable functional and cosmetic results. The aim of the treatment is to restore anatomy, functional and cosmetic of the patients.

Key words: Basalcellcarcinoma; Medial canthal region; Full-thickness skin graft; Eyelid reconstruction

INTRODUCTION

Periocular skin tumors are the most common tumour encountered in ophthalmic practice. Basal cell carcinoma (BCC) is the most common malignant eyelid tumour; it has a low risk for metastasis but considerable invasive potential [1]. BCC of periocular area are localized in the inferior eyelid, medial canthus and superior eyelid [2]. Complete surgical excision remains the "gold" standard of treatment it produces excellent results if the tumour is completely removed [1]. Reconstruction of the medial canthal defect created after removal of tumour is the challenge to the oculoplastic surgeon.

Reconstructive techniques can be classified considering the anatomical area requiring treatment: superior eyelid, inferior eyelid, and inner or external canthus [3]. Simplifying, we can distinguish: direct wound closure, "laisser faire", free skin grafts, and different types of skin flaps [3,4]. Direct closure is reserved to very small defects, 'laisser faire' can lead to a remarkable extent of undesired scarring and a cosmetically unfavorable outcome. Free skin grafts require a healthy, well-perfused transplant bed. In case of very deep defects, especially if the defects reach the surface of the bone, free skin grafts are unsuitable. The risk of graft necrosis is high in these situations, and furthermore grafts of the thin skin, for example from the upper eyelids, can lead to a remarkable retraction of the reconstructed region. Finally the risk of hypertrophy of the free skin transplant is highest when transferred into the medial canthus. For these reasons, is that free skin grafts might be even used too often [3]. By definition, a skin flap differs from a skin graft because it consists not only of skin but also of subcutaneous tissue with its subdermal plexus of vessels. Although it is completely raised from the underlying tissue, it is still connected by at least one side to the surrounding skin and fat. It is because of the vessels contained in this pedicle that the flap can preserve its own blood supply, independent of the site on which it is placed [4].

Full thickness skin grafts (FTSG) are composed of epidermis and the entire dermis [5,6].Full-thickness eyelid defects often lead to conjunctival irritation, keratopathy, conjunctival inflammation, corneal ulceration, and even blindness [7]. FTSG are nowfrequently used by plastic surgeons as anterior lamellasubstitutes in eyelid reconstruction surgery,

How to cite this article: Corredor-Osorio R. Preauricular full-thickness skin grafting in medial canthal reconstruction. Our Dermatol Online. 2018;9(1):57-61.
Submission: 08.03.2017; **Acceptance:** 22.05.2017
DOI: 10.7241/ourd.20181.16

providing tissuewith similar color, texture, and thickness.The periocularareа is considered a suitable host, having a rich vascularsupply for capillary regrowth, as well as collagen producingfibroblasts which help in graft adherence [1,2]. This successfulcombination of graft and host has subsequently made itwidely used in eyelid reconstruction surgery after trauma, burns, and tumour removal [6].The aim of the present report was to present the reconstructive techniquein inferior medial canthus with preauricular full-thicknessskin and here we showed the illustration of the respective technique.

CASE REPORT

An 80 year-old woman presented to us a complaint of an asymptomatic tumor located in the right inferior medial canthus for two years. The lesion is1.1cm x 0.9 cm in size, with central ulceration, was insidious onset increased in size (Fig. 1). Excisional biopsy of the lesion was suggestive of basal cell carcinoma. In this type of tumor and full-thickness excision is important.

OPERATIVE PROCEDURE

The procedure is performed under local anesthesia with intravenous sedation and magnification. Surgical excision margins were traced from the lesion border, with a margin of normal skin of 5 mm with a marking pencil, before the subcutaneous injection of 50% bupivacaine 0.5% and 50% lignocaine 2% with epinephrine (concentration, 1 in 200.000). A # 15 Bard-Parker blade is used to inside the tumor. A full-thickness is carried gradually deeper until all tumor is excised, with a margin of normal skin of a least 5 mm. Bleeding is stopped completely prior to graft placement. (Fig. 2). A template of the defect and a marking pen is used to make an outline around the template.The template is placed over preauricular area and traced with marking pen (Fig. 3a). The graft is 20 percent larger than the defect, to allow contracture of the graft. The site is injected subcutaneously with 50% bupivacaine 0.5% and 50% lignocaine 2% with epinephrine (concentration, 1 in 200.000) to supply hemostasis and hydrodynamically facilitate the dissection.

Next, we began harvesting the right preauricular full-thickness skin graft by making skin incisions using a #15 Bard-Parker blade. We then proceeded with dissection immediately in a subdermal plane

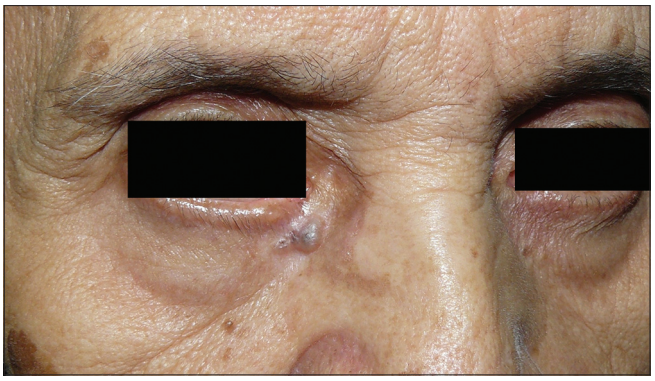

Figure 1: Preoperative Basal cell carcinoma of the medial canthal region.

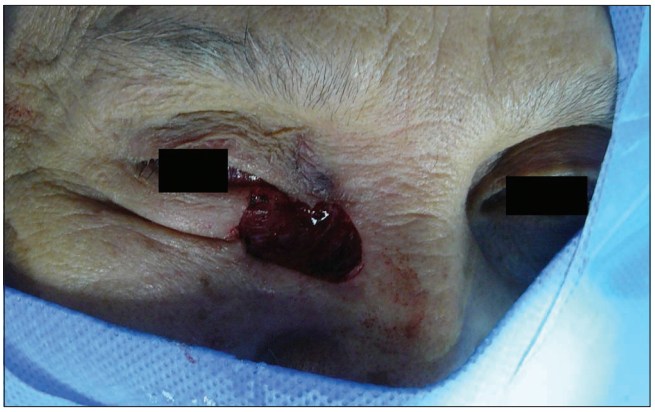

Figure 2: The bleeding points were cauterized. Meticulous hemostasis is achieved prior to graft.

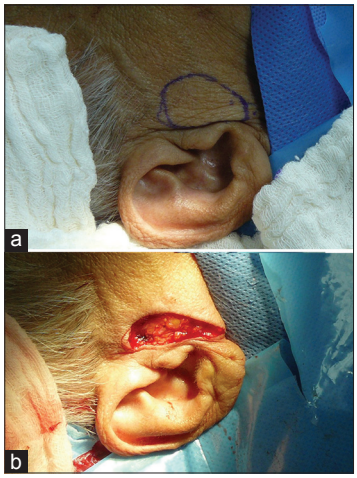

Figure 3: (a) Preparation of a preauricular full-thickness skin graft, (b) Preauricular full thickness skin donor area.

with minimal fat along the skin graft. The thin full-thickness skin graft was removed and its base resected with Westcott scissors (Fig. 3b). We then draped over the surgeon's glovedfinger a dermis up, and all subcutaneous fatty tissue is trimmed away. The graft is transferred andsutured into recipient site con 6/0 nylon sutures. Every third suture is long left (Figs. 4a and 4b).

Stab incisions are made in the graft to allow blood to drain. A thin layer of antibiotic ointmentis placed over graftand other layer antibiotic ointment-impregnated gauze, is applied tightly over graft with the long sutures tied over it. The traction suture is fixed to the brow. Ointment is used to coat the bolster and two compressive eye pads are applied to eyelid. The area preauricular is closed with 6-0 nylon sutures.

The dressing, bolster, and traction are removed in 4 days. The skin sutures are removed in 10 days (Fig. 5). The final histopathology confirmed the tumor asa nodular basal cell carcinoma with tumor-free margins

DISCUSSION

Skin grafting is the oldest form of tissue reconstruction known. Texts documenting the use of skin grafts for soft tissue reconstruction date back 2500 years. The first known description was found in India, in which a skin graft was used to reconstruct an amputated nose.

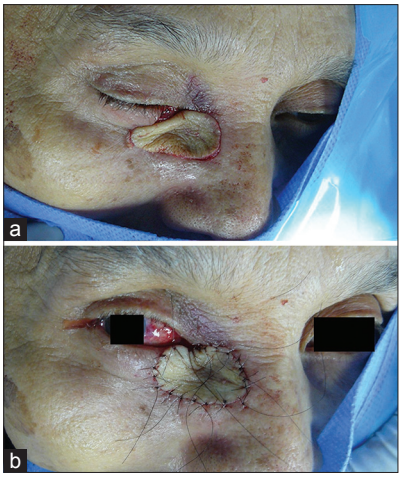

Figure 4: (a) Full thickness skin graft inset onto inferomedial canthus, (b) Appearance of defect after reconstruction with ipsilateral preauricular skin graft.

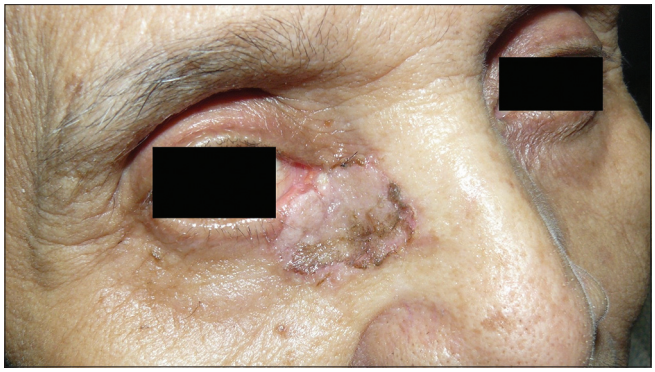

Figure 5: Two weeks follow-up results.

Modernization of the technique started to come about in the 19th century, with descriptions of the pinch graft in 1869 and the FTSG in 1875 [8].

The main advantages of FTSG areaviability, low metabolic requirementand resistance totrauma.Skin grafts go through a unique process of healingin the host site. The first phase, which lasts 24 hours, is anischemic stage (called "plasmatic imbibition"), followed byan edematous stage in which the graft gains up to 40% in weight, and finally revascularization of the graft ("inosculation"), which becomes apparent within 48–72 hours aftergrafting. The blood supply to the graft comes from recipientbed ("bridging phenomenon") [6].

Because the eyelid is a layered structure, appropriate layered reconstruction is essential, with the goal towards restoring periocular function and minimizing any postsurgical complications [9].

The skin grafts can be classified according to their thickness. The most frequently used graft is the Wolfe-Krause graft (0.80–1.00 mm), taken from the skin with a scalpel. Other grafts are the thin-skin grafts, such as the Ollier-Thiersh graft (0.20–0.35 mm), and the middle-thickness grafts such as the Blair-Brown (0.40–0.60 mm) or Padgett (0.60–0.80 mm) grafts. Both thin-skin and middle-thickness grafts can only be taken with the use of a dermatome [3]. When used in periocular reconstruction they are usually harvested from several possible donor sites (upper lid, preauricular, retroauricular, neck, clavicular and supraclavicular, and inner brachial area) yielding different graft thicknesses accordingly [6].

The preauricular region is donor site of choice forsmaller defects on the upper two-thirds of the nose. The preauricular skin is a better color match compared with postauricular or supraclavicular skin. Harvesting the graft is much easier and better tolerated in a mildly sedated patient [8]. Bell finds the skin is in fact superior in quality to the postauricular graft. The donor site scar is minimal, because the typical person requiring a graft of this sort usually has a significant excess of skin on the cheek. The donor site morbidity is also much reduced. With the traditional postauricular skin graft, the patient's glasses often irritate the incision line. The largest area her taken to date measures 55 mm × 25 mm. Also, she found that the time required to perform this procedure is about one-half of that required to harvest postauricular [10].

Success of skin transplantation depends on graft revascularization. The blood supply to the graft comes from recipient bed. Therefore, important conditions for graft revascularization are rich vascular supply of recipient bed and very close contact between graft and recipient surface [1].

The early complications are mainly bleeding with hematoma formation beneath the graft, infection, or seroma formation. These complications may prevent graft adherence to the underlying wound bed, prolong the ischemic phase, compromise the graft's vascular supply, and result in graft failure [6].

Other possible reasons for graft failure are, infection, or graft movement. In the relevant literature, the most common early postoperative complication after skin transplantation is hematoma formation [1]. To prevent it, we made multiples stab incisions on the graft to create pathways for blood drainage.

The long term complications are mainly cosmetic orfunctional and result from color and texture mismatch,hyper- or hypopigmentation, graft hypertrophy, and graftcontraction [6].Usually the color of the graft is mixed, with dark and light spots and with time (after a week) it appears vital, light pink in color. If there are signs of ischemia after the first week, we can wait for 3 to 6 weeks, because survival rate is better than expected. A black graft signifies partial or total graft failure and necrosis. Risk for necrosis increased in cases with very thick graft with remaining subcutaneous fat tissue [1]. Graft contraction is secondary to centripetal movement of the unapposed elastic fibres, resulting in variable degrees ofshrinkage. The factors influencing shrinkage are mainly elasticity of the donor site and graft thickness. Graft contraction is believed to be more prominent as the thickness of the graft decreases, but it is generally thought that FTSG contract minimally in humans [6].

Graft hypertrophy was most common in medial canthal defect reconstruction compared with other periocular sites [3, 6]. The exact mechanism for graft hypertrophy is not fully understood, and it probably represents aberration in the process of wound healing, which includes cell proliferation, inflammation, and increased synthesis of cytokines and extracellular matrix proteins [6]. There are different treatment approaches that include observation,pressure garments, massage and silicone gel sheets and intralesional injection of steroids [1,6]. The most common agents used are triamcinolone acetonide and triamcinolone diacetate which may be combined withpulsed dye lasers. Other possible treatment modalities are dermabrasion (such as aluminium oxidecrystals, acids, liquid nitrogen, and others) or laser CO2 resurfacing which may also improve texture and color abnormalities [6].

It is well known that all grafts contract, once immediately after excision from donor site andagain after revascularization. Primary shrinking is due to contraction of dermal elastic fibers, secondaryshrinking is result of myofibroblast activity.

In cases with FTSG primary shrinking is moreprominent than secondary. Contraction canbe overcome by massage with a steroid ointment for one month after surgery [1].

Reconstruction of medial canthal after large tumourexcision is possible to perform with different surgical procedures. The surgical procedure must be individualized for each patient. A full- thickness excision of tumor is necessary. In our patient we prefer to use FTSG for reconstruction of anterior lamella of the eyelid, because this technique allows us to achieve recovery of the eyelid without any facial scars. In the present case, the preauricular area was the donor site. We prefer to use preauricular donor skin because the harvesting the graft is much easier and better tolerated in a mildly sedated patient, the donor site scar is minimal and the time required to perform this procedure is short.

Success of a skin graft attach depends on certain conditions: Avoid bleeding with formation of hematoma by moderate use of cautery. To prevent it, we made multiples stab incisions on the graft to create ways for blood drainage and a bolster placed over graft to push the skin against the recipient bed for 4 days, along ice compresses. Excess skin graft was trimmed. Normal lid position and functions are very important for eye protection and eye function. Aesthetic result after surgery is important not only for the patient, but also for the surgeon [1].

Medial canthal region reconstruction should be performed with preauricular FTSG considering color and tissue match and is useful alternative technique for the reconstruction of small defects. It can be performedunder local anesthesia obtaining satisfactory results cosmetically and functionally. The donor site scar is minimal. A simple surgical technique and

acceptable donor site morbity are further advantages of this preauricular FTSG. Preauricular skin as a FTSG may provide a similar excellent tissue match in select cases.

Consent

The examination of the patient was conducted according to the Declaration of Helsinki principles written informed consent was obtained from the patient for publication of this article and any accompanying image.

REFERENCES

1. Zlatarora ZI, Nenkova BN, Softova EB. Eyelid reconstruction with full thickness skin grafts after carcinoma excision. Folia Med (Plovdiv). 2016.1;58:42-7.
2. Rahmi D, Mehmet B, Ceyda B, Sibel O. Management of the large upper eyelid defects with Cutler-Beard Flap.J Ophthalmol. 2014;2014:424567.
3. Bertelmann E, Rieck P, Guthoff R. Medial canthal reconstruction by a modified glabellar flap. Ophthalmologica. 2006;220:368-71.
4. Guido A, Actis GR. Reconstruction of the upper eyelid with flaps and free grafts after excision of basal cell carcinoma. Case Rep Ophthalmol. 2001;2:347-53.
5. Rathore DS, Chickadasarahilli S, Crossman R, Mehta P, Ahluwalia HS. Full thickness skin grafts in periocular reconstruction: long-term outcomes. Ophthal Plast Reconst Surg. 2014;30:517-20.
6. Leibovitch I, Huilgol SC, Hsuan JD, Selva D. Incidence of host site complications in periocular full thickness skin grafts. Br JOphthalmol.2005;89:219–22.
7. Wang YC, Dai HY, Xing X, Lv C, Zhu J, Xue CY. Pedicled lower lid-sharing flap for full-thickness reconstruction of the upper eyelid. Eye.2014;28:1292-6.
8. Weathers WM, Bhadkamkar M, Wolfswinkel EM, Thornton JF. Full-thickness skin grafting in nasal reconstruction Semin Plast Surg. 2013;27:90-5.
9. Hayano SM, Whipple KM, Korn BS, Kikkawa DO. Principles of periocular reconstruction following excision of cutaneous malignancy.J Skin Cancer. 2012;2012:438502.
10. Bell MS. Past the postauricular graft. Can J Plast Surg. 2008;16:95-6.

Source of Support: Nil, **Conflict of Interest:** None declared.

Case Report

A surprising palmar nevus: A case report

Rana Rafiei[1], Seyyedezeinab Azimi[2], Alireza Sheibani[2], Behnam Rafiee[3], Sara Najirad[4]

[1]Fellow Ship of Dermatopathology, Skin Research Center, Guilan University of Medical Sciences, Razi Hospital, SardareJangal Street, Rasht, Iran, [2]Skin Research Center, Guilan University of Medical Sciences, Razi Hospital, SardareJangal Street, Rasht, Iran, [3]Department of Pathology, NYU Winthrop Hospital, New York, USA, [4]Nassau University Medical Center, Department of Internal Medicine, 2201 Hempstead turnpike, East Meadow, NY, USA

Corresponding author: Rana Rafiei, MD., E-mail: rafieirana2@gmail.com

ABSTRACT

Raised palmar or plantar nevus especially in white people is an unusual feature. We present an uncommon palmar compound nevus in a 26-year-old woman with a large diameter (6 mm) which had a collaret-shaped margin. In histopathologic evaluation intralymphatic protrusions of nevic nests were noted. This case was surprising to us for these reasons: size, shape, location and histopathology of the lesion. Palmar nevi are usually junctional (flat) and below 3 mm diameter and intra lymphatic protrusion or invasion in nevi is an extremely rare phenomenon.

Key words: Palmar; Nevus; Intralymphatic

INTRODUCTION

Plantar nevi are more prevalent than palmar nevi especially in dark skin subjects. The raised nevi are more common on plantar surface [1]. Kopf reported that 9% of people had a pigmented lesion on the sole and 5.8% of subjects had a pigmented lesion on the palms with equal frequency in both sexes [2] but Gary, et al. mentioned that acral nevi were more prevalent in women with light skin subjects [1].

CASE REPORT

We present herein a 26-year-old woman with Fitzpatrick phototype IV with a dome-shaped nodule with a collaret-shaped margin on her right palmar area from childhood which had about 6 mm diameter. Focal linear blue-gray pigmentations were seen on the surface (Fig. 1). She complained of a vague pain on the lesion during hand-working or palpation. She mentioned pigmentation of the lesion was more prominent during childhood and then gradually decreased. She had no history of trauma or foreign body inoculation.

In physical examination direction of skin lines were quite different on the lesion compared to adjacent skin and separated from it by a collaret. She also had a pigmented macule with 3 millimeter diameter near this lesion. There were two junctional nevi on her trunk too.

Skin biopsy of the palmar lesion was made with differential diagnoses of adnexal tumors, traumatic neuroma and foreign body granuloma. Histopathologic studies confirmed focal lentiginous proliferation of melanocytes at dermo-epithelial junction associated with circumscribed and symmetrical mass of melanocytic component which consisted of dermal nevic nests that showed expected maturation of bland-looking nevic cells with dermal fibroplasia. Eccrine duct and neural fibers were entrapped by nevic cells. In superficial part of the lesion intralymphatic protrusions of nevic nests were noted which were confirmed by immunohistochemistry study (Figs. 2 and 3).

Unfortunately dermatoscopy of the lesion was not done before skin biopsy.

How to cite this article: Rafiei R, Azimi S, Sheibani A, Rafiee B, Najirad S. A surprising palmar nevus: A case report. Our Dermatol Online. 2017;9(1):62-64.
Submission: 12.05.2017; **Acceptance:** 18.07.2017
DOI: 10.7241/ourd.20181.17

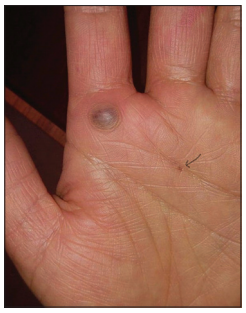

Figure 1: A pigmented dome-shaped nodule is seen on the palmar surface; also a tiny pigmented macule is pointed by an arrow.

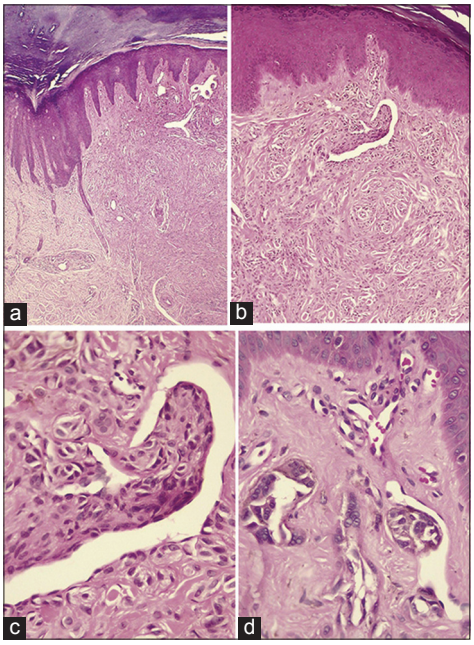

Figure 2: (a) Dermal mass of melanocytic components which consist of nevic nests with dermal fibroplasia and entrapment of eccrine duct and neural fibers by nevic cells. (b-d) In superficial part of this lesion intralymphatic protrusions of nevic nests are noted. (H & E, original magnification a: x40, b: x100, c, d: x400).

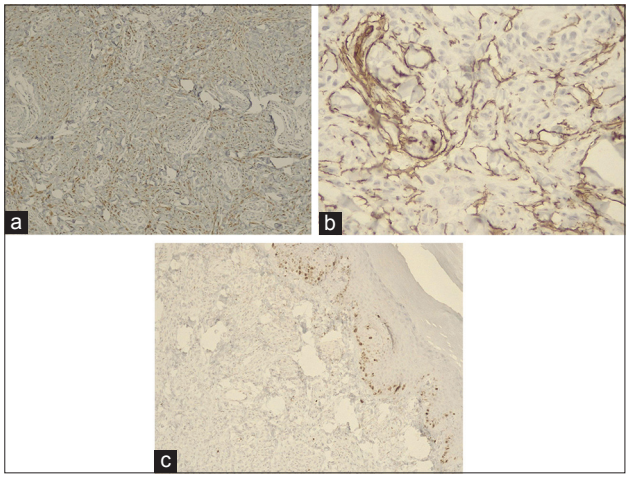

Figure 3: Immunohistochemistry evaluations show: (a) Melanocytic nesting (HMB45 staining), (b) lymphatic channel formations (CD31 staining) and c) low mitotic rate of the nevic cells (Ki67 staining) in favor of a benign melanocytic lesion.

DISCUSSION

Palmar and plantar melanocytic nevi are more common in dark skin patients, women, age younger than 50 years and in subjects who have more atypical nevi. The greatest diameter of palmar nevi in white subjects has been 0.5 - 3 mm and only 3% of palmar nevi are raised. They usually have light brown pigmentation. Plantar nevi are more common than palmar nevi and usually have compound nevic features [1]. Size, dome-shaped feature with a collaret view, low pigmentation and pain of the lesion in our case, prompted us not to think initially about palmar nevus.

Acral melanocytic nevus may have special histopathologic findings which are different from other areas. These unusual findings include single pagetoid spread of melanocytes without atypia, pigmentation of cornified layer, syringotropism, lymphocytic inflammation and dermal fibroplasia which might be misdiagnosed as melanoma but melanoma is characterized by high number of atypical cells and mitotic figures [3].

Intralymphatic protrusion or lymphatic invasion of nevic cells is a rare incidental event which probably could be better seen with more tissue sections [4]. This phenomenon has been reported in 2.7%- 6.5% of nevi which might be under-diagnosed because of focal manifestation. Pseudolymphatic spaces in nevic structures are usually characterized by papillary projections in dermal nevi which are covered by cuboidal nevic cells instead of flattened endothelial cells, so they should be differentiated from true lymphatic spaces. Leblebici, et al. reported lymphatic invasion of nevic cells in 10 out of 369 cases with nevi. These 10 cases aged 7 to 33 years and they had compound or intradermal nevus. Lower detection of lymphatic invasion in nevi should be considered due to limited sections and rapid diagnosis for nevus samples. Intralymphatic nevic aggregates might be lost during tissue processing for immunohistochemical study [5]. Up to now this phenomenon has no prognostic significance and could be explained by shifting of nevic cells resulted from mechanical forces toward lymphatic spaces [4].

In conclusion our case had a benign compound nevus on the palmar surface which clinically and histopathologically surprised us.

REFERENCES

1. Palicka GA, Rhodes AR. Acral melanocytic nevi: prevalence and distribution of gross morphologic features in white and black adults. Arch Dermatol. 2010;146:1085-94.
2. Boyd AS, Rapini RP. Acral melanocytic neoplasms: a histologic analysis of 158 lesions. J Am Acad Dermatol. 1994;31:740-5.
3. Hosler GA, Moresi JM, Barrett TL. Nevi with site-related atypia: a review of melanocytic nevi with atypical histologic features based on anatomic site. J Cut Pathol. 2008;35:889-98.
4. Kim HS, Lee SH, Moon HS, Kim YW. Intradermal melanocytic nevus with lymphatic nevus cell embolus: A case report. Oncol Letters. 2014;7:331-3.
5. Leblebici C, Kelten C, Gurel MS, Hacıhasasanoglu E. Intralymphatic nevus cells in benign nevi. Ann Diag Pathol. 2016;25:1-6.

Source of Support: Nil, **Conflict of Interest:** None declared.

Case Report

Immune response in a regressing compound dysplastic nevus

Ana Maria Abreu Velez[1], Charles J Douchy[2], Michael S. Howard[1]

[1]*Georgia Dermatopathology Associates, Atlanta, Georgia, USA.* [2]*North Atlanta Dermatology, Duluth, Georgia, USA*

Corresponding author: Ana Maria Abreu Velez, E-mail: abreuvelez@yahoo.com

ABSTRACT

Atypical (dysplastic) melanocytic nevi are considered for many as an intermediate step in a clinicopathologic spectrum. Regression is often seen. A 45 year old male presented with a hyperpigmented macule on the patient's back. Biopsies for hematoxylin and eosin (H&E) examination and immunohistochemistry (IHC) analysis were performed. The H&E staining demonstrated a compound dysplastic nevus. IHC stain shows stains with galectin 3, CD45, B-cell lymphoma 2 cyclooxygenase-2 ribosomal protein S6-ps240 (RIBO), CD68 and tyrosinase. Some stains were not only present in the tumor, but around it. We described a case of compound dysplastic nevi with a likely effectual early antitumoral response avoiding the growth to melanoma. The fundamental mechanism has not been elucidated, but our findings indicate a mix of inflammatory as well as immune response mediators maybe involved in the immune-based obliteration of melanocytes.

Keywords: Compound dysplastic nevus; Galectin 3; Ribosomal protein S6-ps240; BCL-2.

INTRODUCTION

Atypical (dysplastic) melanocytic nevi are considered for many as an intermediate step in a clinicopathologic spectrum from acquired melanocytic nevi to malignant melanoma.[1,2] Sometimes these nevi seem to be "self-regressing", but the manner in which the immune system produces these changes remains unknown. For many years, it has been thought that the immune response in melanocytic and other skin cancers was "not effective", and/or absent or anergic [1].

CASE REPORT

A 45 year old male presented for a skin examination. The dermatologist noted a hyperpigmented macule on the patient's back, and a skin biopsy for hematoxylin and eosin (H&E) and immunohistochemistry (IHC) analysis was obtained.

Skin biopsies were taken for histology (H&E) studies, for immunohistochemistry (IHC) and for direct immunofluorescence studies (DIF); our techniques were performed as previously described [2].

Immunohistochemistry (IHC), Single and Double Color

For our IHC testing, we utilized a dual endogenous peroxidase blockage, with the addition of a Dako Envision dual link (to assist in chromogen attachment). Our IHC staining was performed as previously described, using either single or double color techniques [2]. We then applied the chromogen 3,3-diaminobenzidine, and counterstained with hematoxylin. The samples were run in a Dako Autostainer Universal Staining System. Positive and negative controls were consistently performed. The staining was performed as previously described [2]. We performed IHC utilizing multiple monoclonal and polyclonal antibodies from Dako (Carpinteria, California,

How to cite this article: Abreu Velez AM, Douchy CJ, Howard MS. Immune response in a regressing compound dysplastic nevus. Our Dermatol Online. 2018;9(1):65-67.

Submission: 16.03.2017; **Acceptance:** 17.05.2017

DOI: 10.7241/ourd.20181.18

USA). We utilized the following mouse anti-human monoclonal antibodies: We utilized immune system cell markers, and other markers investigating cellular processes such as growth, proliferation, motility, and survival including galectin 3, CD45, B-cell lymphoma 2 (BCL-2), cyclooxygenase-2 (COX-2), ribosomal protein S6-ps240 (RIBO), CD68 and tyrosinase.

RESULTS

The H&E staining demonstrated a melanocytic neoplasm, with melanocytes present as nests and single cells located along the dermal/epidermal junction (Fig. 1a, black arrow) (100X). Mild cytologic atypia was seen within these cells, but pagetoid spread of melanocytes was not appreciated. The melanocytes displayed bridging between adjacent rete ridges, and lamellar fibroplasia of collagen was present. The lesion appeared free of the specimen borders in the sections examined.

Tyrosinase was positive in the dysplastic nevi (Fig. 1b, brown staining; red arrow) (200X). Galectin 3 was also positive in melanocytic areas, mostly displaying cytoplasmic staining. COX-2 staining was positive on inflammatory cells around dermal vessels (Fig. 1c, red staining; black arrow) (200X). Fig. 1d shows colocalization of CD45 positive cells in red (red arrow) and COX-2 positive cells in brown (black arrow) (200X). RIBO and BCL-2 were both positive colocalizing in the dysplastic nevus and in the inflammatory cells under it. A few cells positive for CD68 were noted under the dysplastic nevus (image not shown), indicating the presence of antigen presenting cells in this area.

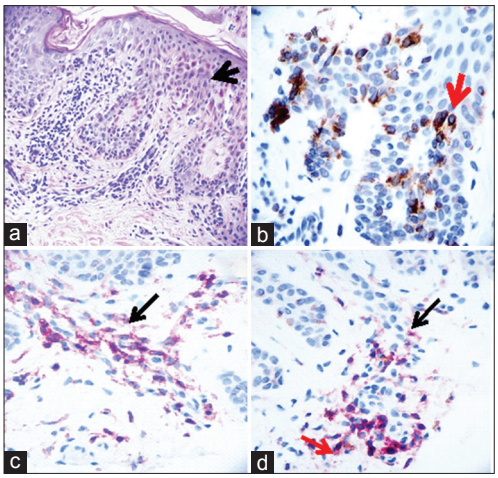

Figure 1: a. The H&E staining demonstrated a melanocytic neoplasm, with melanocytes present as nests and single cells located along the dermal/epidermal junction (black arrow) (100X). Mild cytologic atypia was seen within these cells, but pagetoid spread of melanocytes was not appreciated. b. Positive IHC stain with tyrosinase was positive in the dysplastic nevi, brown staining; red arrow) (200X). c. Double color IHC stain shows a positive IHC stain with galectin 3 was positive in the melanocytes, mostly displaying cytoplasmic staining (brown stain). COX-2 staining was positive on inflammatory cells around dermal vessels (red staining; black arrow) (200X). d. shows colocalization of positive double color with IHC CD45 in red (red arrow) and COX-2 positive cells in brown (black arrow) (200X).

DISCUSSION

In this case we were able to see interactions between the melanocytic cells, the innate immune response, and the inflammatory response. Innate immunity is thought to provide a rapid, incomplete antimicrobial host defense until acquired immunity develops. COX-2 positive staining indicates an innate immunity response. The antigen presenting cells (CD68 staining) likely potentiate a specialized immune response, in combination with the CD45 positive cells.

Galectin-3 is a member of the lectin and the beta-galactoside binding protein families. Galectin plays a role in cell-cell adhesion, cell-matrix interactions and macrophage activation, among other functions [3,4]. Other authors had studied the presence of galectin 3 in differential melanocytic lesions, and concluded that strong galectin 3 expression was associated with an improved overall survival from melanocytic lesions. Other studies had shown contradictory results, showing that melanocytes accumulate galectin-3 with tumor progression, particularly in the nuclei [3,4]. Here Galectin 3 is likely allowing a flux of the immune cells into the nevus. On the other hand, BCL-2 regulates cell death (apoptosis), by either inducing (pro-apoptotic) or inhibiting (anti-apoptotic) functions [5]. BCL-2 expression in dysplastic nevi likely signals an immune response against the nevus by apoptosis, and/or pro-apotosis [5].

In regards to the positivity of COX-2, it represents an inducible enzyme involved in the production of prostaglandins and thromboxanes during inflammation. There is evidence of COX-2 acting to induce flux of immune cells into melanocytic lesions. However, other lines of evidence indicate that increased expression of COX-2 plays a functional role in the development and progression of malignant melanocytic cells [6]. We suggest that COX-2 and BCL-2 roles could change on a case-by case basis, either promoting immunity and/or inhibiting it in dysplastic nevi. Given the fact that most pre-melanoma and melanoma lesions are quickly excised, verification of these precise functions would require creating melanoma cell line animal models,

then testing the markers throughout melanoma progression.

In conclusion, here we present some inflammatory and immune response in a regressing dysplastic nevus that maybe an example of an efficient early antitumoral response preventing the development of neoplasia. The immunosurveillance of this compound dysplastic nevi seem to play of major importance given the possibility to progress to melanoma. Specifically, the area around the tumor and the immune system cells includes an innate and a specialized immune response as well as inflamation.

Abbreviations

Hematoxylin and eosin (H&E), immunohistochemistry (IHC), ribosomal protein S6-ps240 (RIBO), B-cell lymphoma 2 gene (BCL-2), cyclooxygenase-2 (COX-2).

ACKNOWLEDGEMENT

Jonathan S. Jones, HT(ASCP) at Georgia Dermatopathology Associates provided excellent technical assistance.

REFERENCES

1. Clark WH Jr, Elder DE, Guerry D 4th, Epstein MN, Greene MH, Van Horn M. A study of tumor progression: The precursor lesions of superficial spreading and nodular melanoma. Hum Pathol. 1984;15:1147–65.
2. Abreu Velez AM, Googe PB Jr, Kim J, Howard MS. Basal cell carcinoma with sebaceous differentiation markers. North Am J Med; 2015.7:275-80.
3. Brown ER, Doig T, Anderson N, Brenn T, Doherty V, Xu Y, et al. Association of galectin-3 expression with melanoma progression and prognosis. Eur J Cancer. 2012;48:865-74.
4. Prieto VG, Mourad-Zeidan AA, Melnikova V, Johnson MM, Lopez A, Diwan AH, et al. Galectin-3 expression is associated with tumor progression and pattern of sun exposure in melanoma. Clin Cancer Res. 2006;12:6709-15.
5. Becker JC, thor Straten P, Andersen MH. The Paradoxical association between Bcl-2 expression and prognosis: Does the immune system make the difference? Cancer Res. 2005;65:7.
6. Goulet AC, Einsphar JG, Alberts DS, Beas A, Burk C, Bhattacharyya A, et al. Analysis of cyclooxygenase 2 (COX-2) expression during malignant melanoma progression. Cancer Biol Ther. 2003;2:713-8.

Source of Support: Georgia Dermatopathology Associates, Atlanta, Georgia, USA, **Conflict of Interest:** None declared.

Case Report

Giant congenital melanocytic nevus coexisting with an asymmetric posture

Funda Tamer[1], Mehmet Eren Yuksel[2]

[1]Department of Dermatology, Ufuk University School of Medicine, Ankara, Turkey, [2]Department of General Surgery, Aksaray University School of Medicine, Aksaray, Turkey

Corresponding author: Dr. Funda Tamer, E-mail: fundatmr@yahoo.com

ABSTRACT

Congenital nevus is a melanocytic proliferation that is present at birth. When the diameter of a congenital melanocytic nevus is 20 cm or greater, it is called giant congenital melanocytic nevus. A giant congenital melanocytic nevus harbors the risk of malignant transformation. Moreover, the risk of malignant transformation increases with increasing lesion size. Furthermore, various abnormalities like scoliosis, spina bifida, atrophy and asymmetry of extremities can coexist with congenital nevi. Hereby, we present a 4-year-old Caucasian female child with a giant congenital melanocytic nevus on her trunk associated with postural asymmetry. The lesion depicted here had a characteristic clinical appearance, however the surface of the nevus had verrucous and hairy areas despite the patient's young age. The patient was evaluated for clinical signs of possible malignant changes, and regular dermatoscopic follow-up was recommended.

Key words: Congenital; Melanocytic nevus; Postural asymmetry

INTRODUCTION

A giant congenital nevus is a rare melanocytic lesion with an incidence of 1:20.000. It tends to be more common in women than men. It occurs during embryogenesis as a result of neuroectodermal abnormalities. Giant congenital melanocytic nevus clinically presents as an asymptomatic, brown-black colored, well defined lesion with hypertrichosis. Predilection sites are trunk, head and extremities. However, it can affect any part of the body surface [1].

Congenital nevi are classified according to their size. A congenital melanocytic nevus less than 1.5 cm in diameter is called small congenital melanocytic nevus. A congenital nevus with a size of between 1.5 cm-19.9 cm in diameter is called medium congenital melanocytic nevus. A giant congenital melanocytic nevus is greater than 20 cm in size. The patients with congenital melanocytic nevus should undergo regular clinical evaluation and dermatoscopic examination because of the risk of malignant transformation [2].

CASE REPORT

A 4-year-old Caucasian female child was admitted for further clinical evaluation of the hyperpigmented plaque on her trunk. The patient had this hyperpigmented lesion since birth and the lesion increased in size proportionally to the growth of her body. The lesion first appeared as a large brown patch with a smooth surface, however it became hairy and raised in time. Furthermore, an elevated lesion occured on the nevus within the last 6 months. The patient was otherwise healthy. She did not have any neurologic signs or symptoms. The family history was unremarkable. The dermatologic examination of the patient revealed a brown-black colored, hairy, round plaque with sharp borders which covered the neck, shoulders, right arm, chest, abdominal area and the upper back. The right lateral aspect of the lesion was ulcerated and elevated. In addition to the congenital nevus, multiple, small, hyperpigmented, round macules measuring 1 mm to 10 mm were observed on the trunk. Asymmetrical appearance of the neck, shoulders, and the trunk was

How to cite this article: Tamer F, Yuksel ME. Giant congenital melanocytic nevus coexisting with an asymmetric posture. Our Dermatol Online. 2017;9(1):68-70.
Submission: 24.05.2017; **Acceptance:** 16.07.2017
DOI: 10.7241/ourd.20181.19

noted (Figs. 1 and 2). Dermatoscopic examination revealed homogenous pigmentation, milia-like cysts, hair follicles and perifollicular hypopigmentation. Thus, the diagnosis of congenital melanocytic nevus was made based on the clinical and dermatoscopic features. A skin biopsy and histopathological examination of the ulcerated lesion were recommended to exclude a malignant transformation. Therefore, the patient was referred to the plastic and reconstructive surgery department.

DISCUSSION

Congenital nevus is a benign melanocytic lesion which presents at birth. However, 78% of the patients with giant congenital nevus also have small cutaneous hyperpigmented lesions which are called satellite lesions. Moreover, diffuse lipomatosis, cranial bone hypertrophy, limb atrophy, skeletal asymmetry, hyperplasia and hypoplasia of soft tissue, scoliosis, urinary tract anomaly, capillary malformation, café au lait spot, Mongolian spot and fibroepithelial polyp have been reported in patients with giant congenital melanocytic nevus previously [1]. In addition, Gorai et al. presented a giant congenital melanocytic nevus with occipital encephalocele in a 5-month-old male child in India [3]. Recently, Goyal et al. reported a 20-year-old female with a giant congenital nevus presenting as a large vulvar mass [4].

The risk of development of malignant melanoma in a giant congenital nevus varies from 1.8% to 45% [5]. Patients with the age of 3 to 5 years, patients with three or more lesions and lesions greater than 20 cm have higher risk of malignant transformation. A giant congenital nevus may become darker and thicker, moreover it can develop a papular, verrucous surface with time. However, it should be kept in mind that focal growth, ulceration, dark pigmentation, pruritus, pain and bleeding can be the warning signs of malignant transformation [5]. Furthermore, benign proliferative nodules which occur in congenital melanocytic nevi should be considered in differential diagnosis of malignant melanoma both clinically and histopathologically [6]. Su Han et al. reported a newborn with a giant congenital nevus with benign proliferative nodules on the genitalia which resembled a congenital malignant melanoma [7].

A giant congenital nevus may be associated with proliferation of melanocytes in the central nervous system which is called neurocutaneous melanosis. The risk of neurocutaneous melanosis in patients with giant congenital nevus is 3%-12%. Neurocutaneous melanosis may clinically present with increased intracranial pressure, seizures, motor deficits, myelopathy and radiculopathy [8].

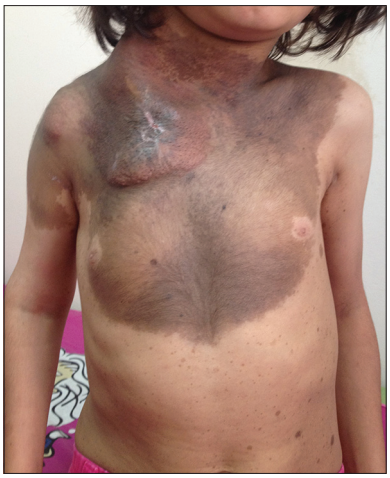

Figure 1: Well demarcated, oval, hairy, hyperpigmented plaque on the neck, chest, shoulders and right arm. Asymmetrical appearance of the trunk and atrophy of the upper extremities. Multiple hyperpigmented macules on the abdomen.

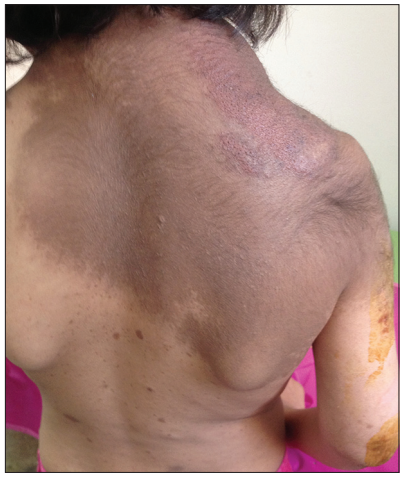

Figure 2: Well demarcated, oval, hyperpigmented plaque with brown-orange colored plaques and hypertrichosis on the upper back. Multiple hyperpigmented macules on the lower back.

Giant congenital nevi on the extremities can reduce the limb size as a result of infiltration of nevus cells in subcutaneous tissue [1]. Therefore, our patient had reduced diameter of the right upper extremity that caused an asymmetrical posture. However, our main concern was the possible risk of malignant transformation arising from the giant congenital nevus of the patient.

CONCLUSION

In conclusion, a giant congenital melanocytic nevus harbors the risk of malignant transformation. Giant congenital nevi can lead to body shape disturbance even in childhood. Because of the risk of malignant transformation, giant congenital nevi should be carefully evaluated.

REFERENCES

1. Viana AC, Gontijo B, Bittencourt FV. Giant congenital melanocytic nevus. An Bras Dermatol. 2013;88:863-78.
2. Tannous ZS, Mihm MC Jr, Sober AJ, Duncan LM. Congenital melanocytic nevi: Clinical and histopathologic features, risk of melanoma, and clinical management. J Am Acad Dermatol. 2005;52:197-203.
3. Gorai S, Saha M, Seth J. Giant congenital melanocytic nevus with occipital encephalocele: A very rare association. Indian J Dermatol. 2016;61:224-6.
4. Goyal M, Kriplani A, Mahey R, Kachhawa G, Yadav R, Singh G. Giant congenital melanocytic nevus presenting as a huge vulvar mass: A rare case. Taiwan J Obstet Gynecol. 2017;56:109-11.
5. Arneja JS, Gosain AK. Giant congenital melanocytic nevi. Plast Reconstr Surg. 2009;124:1e-13e.
6. Vergier B, Laharanne E, Prochazkova-Carlotti M, de la Fouchardière A, Merlio JP, Kadlub N, et al. Proliferative nodules vs melanoma arising in giant congenital melanocytic nevi during childhood. JAMA Dermatol. 2016;152:1147-51.
7. Han JS, Won CH, Chang SE, Lee MW, Choi JH, Moon KC. Giant congenital melanocytic nevus with proliferative nodules mimicking a congenital malignant melanoma. Ann Dermatol. 2014;26:554-6.
8. Sawicka E, Szczygielski O, Żak K, Pęczkowski P, Michalak E, Bekiesińska-Figatowska M. Giant congenital melanocytic nevi: Selected aspects of diagnostics and treatment. Med Sci Monit. 2015;21:123-32.

Source of Support: Nil, **Conflict of Interest:** None declared.

Case Report

Squamous cell carcinoma arising over seborrhoeic keratosis - A rare presentation

Mrinal Gupta

Consultant Dermatologist, Treatwell Skin Centre, Jammu, India

Corresponding author: Dr. Mrinal Gupta, E-mail: drmrinalgupta@yahoo.com

ABSTRACT

Seborrhoeic keratoses (SKs)are common skin lesions that occur with increasing age. Usually they have a benign course but varying degrees of squamous atypia have been seen. Bowenoid transformation of benign SKs into squamous cell carcinoma in situ has been documented but the development of basal or squamous cell carcinoma in a seborrhoeic keratosis is rare. Herein, we report a case of squamous cell carcinoma arising over a long-standing seborrhoeic keratosis in 70-year old male, which was managed with a wide surgical resection.

Key words: Seborrhoeic keratosis; Squamous cell carcinoma; Malignant transformation; Skin malignancy; Atypia

INTRODUCTION

Seborrheic keratoses (SKs) are the most common benign epidermal tumor of the skin commonly arising in middle-aged individuals. Genetics, sun exposure, and infection have all been implicated as possible factors. Males and females are equally affected and there is little tendency to spontaneous disappearance. Usually they run a benign course but rarely malignancies like basal cell carcinoma (BCC), melanoma and nonmelanoma skin cancers can arise [1,2]. Keratoacanthoma, malignant melanoma, and trichilemmal carcinoma have also been described [2,3]. Herein, we report a case of squamous cell carcinoma arising over a long-standing seborrhoeic keratosis in 70-year old male, which was managed with a wide surgical resection.

CASE REPORT

A 70-year-old man presented with history of a pigmented growth over pubic region for the last 25 years. Over the last one year, there was development of a protuberant mass over the lesion. The mass was gradually progressive and was associated with pain, ulceration and serosanguinous discharge. The patient was a known diabetic and hypertensive and gave history of significant weight loss over the last one year. On examination, a well defined exophytic mass, around 3 cm in diameter, was present over the pubic area. The surface of the lesion was ulcerated with fissuring and examination of the base revealed a hyperpigmented plaque of size 1 cm from which the lesion appeared to be arising (Fig. 1). Systemic examination revealed inguinal lymphadenopathy. The patient was advised complete excision of the lesion which was later on performed by a surgeon and the lesion was subjected to histopathological examination. Histopathology of the lesion revealed thickened epidermis with full thickness dysplasia, hyperchromatic nuclei, abnormal mitoses with areas of maturation forming parakeratotic horny pearls and individually keratinized cells, confirming the diagnosis of squamous cell carcinoma (Fig. 2).

The patient was asymptomatic after surgical excision and there was no recurrence of the lesion after six months of follow-up.

DISCUSSION

SKs are the most common benign tumors of the skin, commonly seen among the elderly and the middle-aged. The higher prevalence of SKs on sun-exposed

How to cite this article: Gupta M. Squamous cell carcinoma arising over seborrhoeic keratosis - A rare presentation. Our Dermatol Online. 2018;9(1):71-72.
Submission: 31.03.2017; **Acceptance:** 29.08.2017
DOI: 10.7241/ourd.20181.20

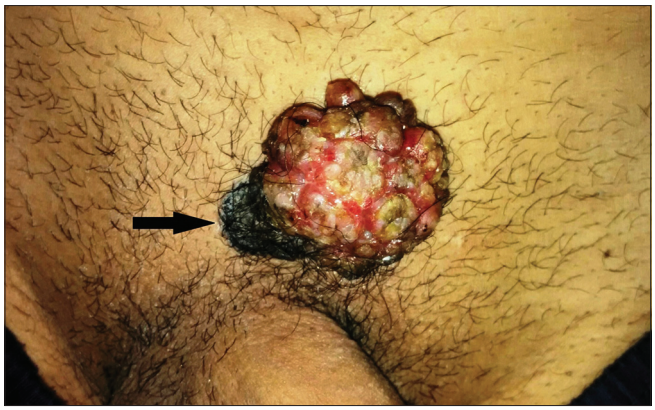

Figure 1: Well defined exophytic mass arising over a hyperpigmented plaque (arrow) in the pubic region.

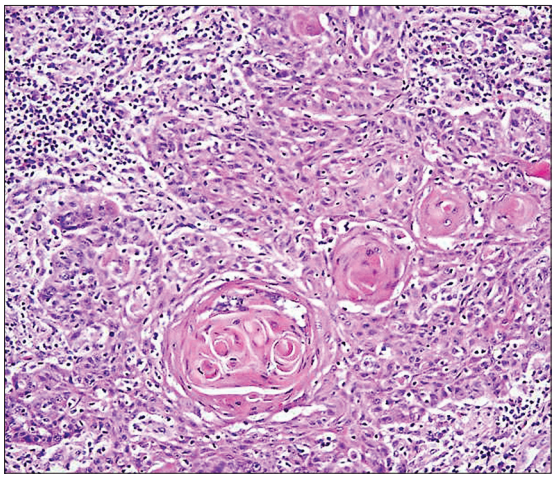

Figure 2: Histopathology showing pleomorphism, hyperchromatic nuclei, and abnormal mitoses with areas of maturation forming parakeratotic horny pearls (H&E 100X).

skin implies a possible causative role of sunexposure. SKs have also been found to demonstrate irregularities in the expression of the apoptosis markers p53 and Bcl-2, but so far no genetic locus or chromosomal imbalance has been detected. Usually SKs have a benign course but varying degrees of squamous atypia have been seen [2]. Malignant transformation, though uncommon, is known to occur in skin types I-III. The incidence of this varies from 0.14% to 7%, with higher frequencies being found in those studies where only the clinically suspicious lesions were biopsied [2-4]. Although it is likely that most of these lesions represent collision tumors, malignant transformation of SKs into basal cell carcinomas, squamous cell carcinomas, and melanomas can occur rarely. The most common type of malignancy arising in SK is variably reported as BCC, squamous cell carcinoma (SCC) *in-situ* and invasive SCC. Keratoacanthoma, malignant melanoma, and trichilemmal carcinoma have also been described to arise over SKs [2,3].

The most common histological subtype of SK in which malignancies arise is acanthotic type and the most common type of BCC seen is superficial spreading type [4]. In some cases, histology of the lesion shows tumor cells lying adjacent but separately from SK cells, which is termed as a "Collision tumor" or a "Compound tumor" [1]. Malignant transformation in SKs is usually seen among the elderly over the photoexposed sites like head and neck. It has been postulated that different cancers associated with SKs developed from the three different types of cells that constituted SKs, that is, BCC develops from basaloid cells, SCC from the spinous cells, and malignant melanoma from melanocytes [3].

This report highlights the rare but potentially life threatening risk of malignant transformation of SKs and the dermatologists should be well aware of the risk and timely biopsy of suspicious lesions of SK should be performed as they may mark the onset of malignant transformation.

REFERENCES

1. Vun Y, De'Ambrosis B, Spelman L, Muir JB, Yong-Gee S, Wagner G, et al. Seborrhoeic keratosis and malignancy: Collision tumor or malignant transformation? Australas J Dermatol. 2006;47:106-8.
2. Lim C. Seborrhoeic keratoses with associated lesions: A retrospective analysis of 85 lesions. Australas J Dermatol. 2006;47:109-13.
3. Cascajo CD, Reichel M, Sanchez JL. Malignant neoplasms associated with seborrheic keratoses. An analysis of 54 cases. Am J Dermatopathol. 1996;18:278-82.
4. Maize JC, Snider RL. Nonmelanoma skin cancers in association with seborrheic keratoses. Clinicopathologic correlations. Dermatol Surg. 1995;21:960-2.

Source of Support: Nil, **Conflict of Interest:** None declared.

Our Dermatology Online

Case Report

Pilomatricoma of the eyelid

Tasleem Arif, Syed Suhail Amin, Dinesh Raj

Department of Dermatology, STDs and Leprosy, Jawaharlal Nehru Medical College (JNMC), Aligarh Muslim University (AMU), Aligarh, India

Corresponding author: Dr. Tasleem Arif, E-mail: dr_tasleem_arif@yahoo.com

ABSTRACT

Pilomatricoma is an uncommon benign tumor considered to be harmatoma of hair matrix. Here we present a case of 27 year old male patient who had solitary swelling over the right upper eyelid. On the basis of clinical and histopathological background, the diagnosis of pilomatricoma was made.

Key words: Hair matrix; Hamartoma; Pilomatricoma

INTRODUCTION

Pilomatricoma was first described by Albert Hippolyte Malherbe and J. Chenantais as calcifying epithelioma in 1880 A.D [1]. Later on, in 1949 Lever and Griesemer suggested the hair matrix cells to be the origin of the tumor and finally in 1961 Forbis and Helwig proposed the currently accepted name "pilomatricoma" [2,3].

Clinically, the lesion appears as a slowly enlarging, irregularly shaped, rock hard, nodular, non tender mass freely movable over the subcutaneous tissue. The skin usually has reddish to blue discoloration due to dilated blood vessels and chalky white nodules may be seen through the skin. There is typically no history of inflammation or trauma [4]. In this article we present a case of pilomatricoma involving the eyelid.

CASE REPORT

A 27 years old male presented to the hospital with a small painless nodular lesion in the right upper eyelid for 5 years. The history of the patient revealed no pain, previous inflammation or trauma. On examination, a small, round, non-tender, rock hard, nodule was present on right upper eyelid (Figs. 1 and 2). There was hair shaft emanating from the summit of the nodule. It had normal skin color, but chalky white nodules could be seen through the healthy appearing skin. The patient was referred to ophthalmology department where the lesion was excised and sent for histopathological examination which confirmed the diagnosis of pilomatricoma showing a biphasic population composed of basaloid germinative cells and eosinophil shadow cells with a few foci of dystrophic calcification.

DISCUSSION

Pilomatricoma is an ectodermic tumour originating from pluripotential precursors of hair matrix cells. It can present at any age. It demonstrates a bimodal peak presentation during 1st and 6th decades of life, about 40% of cases occur in patients younger than 10 years of age and 60% of cases occur within the first two decades of life. Its more common in females than in males [5]. Clinically, it manifests as asymptomatic, benign solitary, soft and friable to hard nodule measuring 0.5 cm to 5.0 cm. It is subcutaneous slow growing tumor which may or may not be attached to the skin and mobile over underlying structures. It may also present as multiple and nodular pattern in 2% - 10% of the cases. An activation of β catenin gene CTNNBI mutation may be the cause for development of familial pilomatricoma [6]. Multiple and familial pilomatricomas are associated with Steinert's myotonic dystrophy, Gardner Syndrome, Turner Syndrome

How to cite this article: Arif T, Amin SS, Raj D. Pilomatricoma of the eyelid. Our Dermatol Online. 2017;9(1):73-74.
Submission: 28.05.2017; **Acceptance:** 20.08.2017
DOI: 10.7241/ourd.20181.21

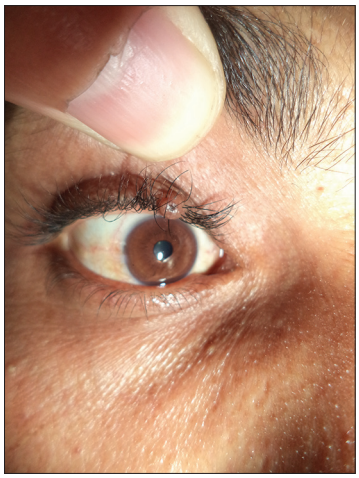

Figure 1: A single nodule present over the upper eyelid margin with hair shaft emanating from the centre of the nodule.

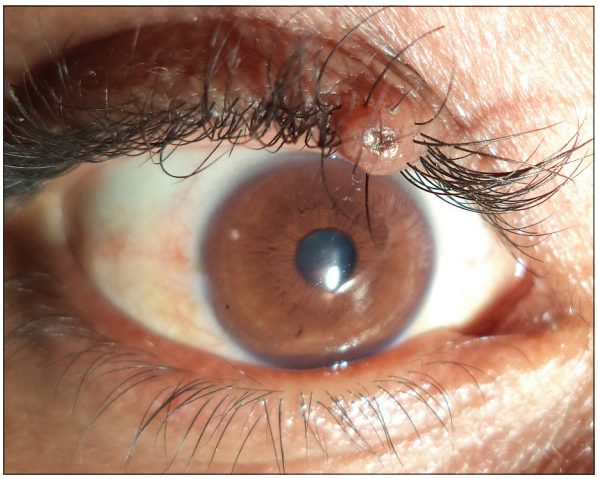

Figure 2: Closer view of the pilomatricoma of the upper eyelid showing hair shaft emerging from the summit of the nodule.

and Trisomy 9 [7]. Among lesions that need to be differentiated from a pilomatricoma include epidermal inclusion cyst, sebaceous adenoma, dermoid cyst, epidermoid cyst and vascular tumors.

Histologically, pilomatricoma is characterized by a mass made up by basaloid cells in periphery, ghost cells in central part and calcification and sometimes ossification. The ghost cells represent necrotic areas of previously vital basaloid cells. The calcification and ossification areas appear progressively in necrotic areas. Ghost cells are pathognomic of pilomatricoma[8].

Presenting age of 27 years, eyelid affliction, male sex and absence of any predisposing factors like trauma make our case an uncommon presentation of pilomatricoma and hence reported.

REFERENCES

1. Malherbe, A. and Chenantais, J. Note Sur L'epitheliome calcifie des glades sebacees. Programme Med. 1888;8:826-8.
2. Lever WF, Griesemer RD. Calcifying epithelioma of Malherbe; report of 15 cases, with comments on its differentiation from calcified epidermal cyst and on its histogenesis. Arch Derm Syphilol. 1949;59:506-18.
3. Forbis R Jr, Helwig EB. Pilomatrixoma (calcifyng epithelioma) Arch Dermatol. 1961;83:606-18.
4. AbaloLojo JM, CameselleTeijeiro J, Gonzalez F. Pilomatrixoma: late onset in two periocular cases. Ophthal Plast Reconstr Surg. 2008;24:60-2.
5. Taaffe A, Wyatt EH, Bury HP. Pilomatrixoma (Malherbe):A clinical and histo pathologic survey of 78 cases. Int. J Dermatol. 1988;27:477-80.
6. Chan, E.F., Gat, U., Mc Niff, J.M. and Fuchus, E. A Common Human Skin Tumor Is Caused by Activating Mutation of β-Catenin. Nature Genetics, 1999;21:410-13.
7. Aslan G, Erdogan B, Akoz T, Gorgu M, Seckin S, Terzioglu A. Multiple occurrence of pilomatrixoma. Plast Reconstr Surg Sept. 1996;98:510-3.
8. Passi N, Chawla U, Jyoti, Khurana AK. Pilomatrixoma of eyelid in a middle aged. Nepal J Ophthalmol. 2011;3:88-90.

Source of Support: Nil, **Conflict of Interest:** None declared.

Review Article

Androgenic alopecia and dutasteride in hair mesotherapy: A short review

Estela B Busanello, Elias Turcatel

Research Institute Ana Carolina Puga, NEPUGA, Ribeirão Preto, SP, Brasil

Corresponding author: Dr. Estela B Busanello, E-mail: busanello.estela@gmail.com

ABSTRACT

Androgenic alopecia (AGA) is the most common cause of patterned hair loss in predisposed men and women. AGA is a multifactorial and polygenetic condition, affecting up to 80% of men and 40-50% of women during life. AGA is characterized by a gradual reduction of the anagen and increase in telagen phase, leading to a progressive follicle miniaturization. As a consequence, terminal hairs are converted into vellus hairs decreasing hair density. The pathophysiology of AGA is heterogeneous and highly complex. A diverse combination of genetical factors, endocrine abnormalities, circulating androgens, drugs, diet and microinflammation in hair follicles of each individual are related to this condition. However, it is well known that androgens are the major modulators of male AGA but their specific action on female AGA is still under debate. Circulating testosterone is converted by 5α-reductase in 5α-dihydrotestosterone (DHT) in the periphery, a decrease of anagen phase occur, anticipating catagen phase in a complex process involving apoptosis as probably microinflammation. In AGA treatment, mesotherapy is being used with 5α-reductase inhibitors, especially dutasteride, injected directly on scalp. Thus, this updated review summarized the injectable use of dutasteride based on data available on PubMed until March 2017. Dutasteride, a second-generation inhibitor of 5α-reductase is more potent than finasteride due to the capability of inhibit types 1 and 2 of the enzyme. The efficacy and safety of hair mesotherapy with dutasteride were reported by distinct groups and the best results were achieved when this compound was used in combination with other substances, increasing hair growth. This result could be explained by the multifactorial pathophysiology of AGA, involving hair follicle sensitivity to DHT and microinflammation. Therefore, a multi-therapeutic approach seems to be more effective in AGA management. In conclusion, more studies are needed to establish protocols and to evaluate long- term dutasteride injections.

Key words: Androgenic alopecia; Dutasteride; Mesotherapy.

INTRODUCTION

Androgenic alopecia (AGA) is the most common cause of patterned hair loss in predisposed men and women. AGA is a multifactorial and polygenetic condition, affecting 80% of Caucasian men and 40-50% of Caucasian women during life [1-3]. In Asian and African populations, the prevalence descrease to about 14% in men [4,5].

AGA is characterized by a gradual reduction of the anagen and increase in telagen phase, leading to a progressive follicle miniaturization. As a consequence, terminal hairs are converted into vellus hairs decreasing hair density. The patterned male hair loss is classified in seven degrees according to the stage, firstly described by Hamilton in the 1950s [1] and improved later by Norwood [6]. Two years later, Ludwig described the female hair loss scale [7].

Mesotherapy, that employs multiple microinjections of a mixture of compounds into the mesoderm, is a cosmetic tool used worldwide. In AGA treatment, mesotherapy is being used with 5α-reductase inhibitors, especially dutasteride, injected directly on scalp. Thus, this updated review summarized the injectable use of dutasteride based on data available on PubMed until March 2017.

How to cite this article: Busanello EB, Turcatel E. Androgenic alopecia and dutasteride in hair mesotherapy: A short review. Our Dermatol Online. 2017;9(1):75-79.
Submission: 28.04.2017; **Acceptance:** 18.09.2017
DOI: 10.7241/ourd.20181.22

Pathophysiology of AG

The pathophysiology of AGA is heterogeneous and highly complex. A diverse combination of genetical factors, endocrine abnormalities, circulating androgens, drugs, diet and microinflammation in hair follicles of each individual are related to this condition [8-10].

Despite that the inheritance mode is unknown, several gene polymorphisms were found in AGA. Mutations in 5α- reductase, aromatase, estrogen receptor α and others have been related on literature [9,11-14]. However, the strongest association with AGA development is made when genetic alterations occur in androgenic receptors. These alterations increase androgenic receptors expression especially in frontal and vertex regions [15], explaining the patterned hair loss [16].

It is well known that androgens are the major modulators of male AGA but their specific action on female AGA is still under debate [17-19]. Circulating testosterone is converted by 5α-reductase in 5α-dihydrotestosterone (DHT) in the periphery. This reductase present 3 isoforms: types 1, 2 and 3 [20,21]. Type 1 is mainly found in the skin, especially hair follicles, sweat and sebaceous glands [22,23] whereas type 2 is predominantly located in male genitalia and prostate but is also found in the inner root sheath of hair follicles [24]. DHT, which present 10 times more affinity to androgen receptors compared to testosterone, binds to these receptors in genetically predisposed hair follicles, impairing hair cycle. The landmark decrease of anagen phase occur, anticipating catagen phase in a complex process involving apoptosis as probably microinflammation [10,25]. The involvement of hair follicle microinflammation in AGA is being reported since the 1970s. This process that occurs at least in one-third of AGA cases [10,26-29] initiates at infundibulum mediated by bacteria, UV irradiation, chemical and/or mechanical stress. Keratinocytes rapidly respond to stressors releasing interleukin-1α (IL-1α) [30,31] that was shown to inhibit hair growth *in vitro* [32-34]. A transcriptional cascade is activated, increasing pro-inflammatory cytokines (IL-1α, IL-1β, TNFα), chemokines (IL-8, MCPs), collagenases and others. Fibroblasts also respond to pro-inflammatory factors [35] and cellular defenses (neutrophils, T cells, Langerhans cells) are mobilized [36,37]. The inflammation usually persists and may lead to tissue remodeling via collagenases, generating a perifollicular fibrosis [10] and also to apoptosis that has been recently related to follicle miniaturization [25].

Diagnosis of AGA

The classic male pattern hair loss can be identified based on the Norwood scale however, a differential diagnosis is crucial to better evaluate this condition. Family history of baldness and the observation of a transition from large, thick, pigmented to thinner, shorter and nonpigmented vellus hairs are strong indicatives of this condition [38]. Thrichoscopy can be useful to evaluate the alteration in hair diameter [39] and the presence of inflammation and erythema on scalp should also be considered [38]. In women, polycystic ovary syndrome, congenital adrenal hyperplasia and other disorders related to hormonal metabolism are often related do AGA [40].

The physical examination is the landmark to diagnose AGA but some laboratory exams may help in patient assessment. The analysis of testosterone metabolism and thyrotropin levels can be useful to correlate AGA with hormones disorders when suspected [38,41]. Alteration in iron metabolism and nutricional deficiencies may also be involved in AGA [38].

Dutasteride and the management of AGA

The complex pathophysiology is a challenge in AGA treatment and, for this reason, the stop of progression and further thinning are the main goal. In addition, there is only two FDA-approved therapies: finasteride, a type II 5α-reductase inhibitor that present well documented sexual adverse effects and minoxidil, a vasodilator that may present unwanted hair grow [42].

Dutasteride, a second-generation inhibitor of 5α-reductase is more potent than finasteride due to the capability of inhibit types 1 and 2 of the enzyme. This leads to a 90% reduction of DHT serum levels whereas finasteride reduces only 70% [43]. The firsts short-term studies comparing dutasteride to finasteride emerged at the 2000s [44-46]. Olsen et al showed that 24 weeks dutasteride 2.5 mg is more efficient than finasteride 5 mg in men with AGA [44]. Similarly, dutasteride 0.5 mg was also more potent than finasteride 1 mg [46].

The safe and efficacy of dutasteride was also observed in long-term studies. A six-months phase III study showed tolerability and improvement of hair growth in AGA patients receiving 0.5 mg/day dutasteride [45]. Recently, Chung and coworkers showed that dutasteride for more than 6 years was safe and increased terminal, vellus and total hair count in male AGA patients [47]. On

the other hand, adverse effects to those presented by finasteride (alterations on erectile, ejaculatory functions and fertility) and its long half life (4 weeks) [42] are the main factors that contribute to the reluctance on the use of dutasteride in AGA. Thus, the local administration of dutasteride by mesotherapy and a consequent reduction of systemic side effects is a relevant tool on AGA treatment [48].

Hair mesotherapy

Mesotherapy consists in intradermal injections of pharmacological substances in a specific body region with minimal or no systemic effects [49]. This minimally invasive technique was introduced by Michael Pistor in 1958 to treat asthma but the patient's hear loss was also resolved. More than 50 years later, mesotherapy has been used in the treatement of hair loss, cellulite, wrinkles, scar reduction, melasma, and fat deposits. The combination of pharmaceuticals, vitamins, enzymes and other bioactive substances vary according to the indication since there is no standardized formulation [49,50].

Hair mesotherapy, also called mesohair, is used to treat alopecia with injections directly on affected areas of scalp of patients with AGA up to type IV on Norwood-Hamilton classification [51]. The objective is to improve local circulation and stimulate hair follicle environment by providing nutrients. There are few scientific studies showing an improvement of patterned hair loss and despite the lack of a standardized protocols, some chemicals are commonly used: finasteride, dutasteride, minoxidil, biotine, dexpanthenol and minerals.

The efficacy and safety of hair mesotherapy with dutasteride were reported by distinct groups [48,52,53]. In this regard, Abdallah and coworkers showed that a dutasteride-containing preparation (dutasteride 5 mg, D-panthenol 500 mg, biotin 20 mg and pyridoxine 200 mg in a final volume of 10 mL) increased hair count in man with hair loss. A reverse correlation between hair loss duration and scored hair improvement was also observed in this study [48]. Increased hair diameter, thickness and other aspects were also found using mesotherapy in women with alopecia but using the same dutasteride-containing preparation [52]. The main question that arose from these early studies was regarding the specific role of dutasteride on these effects since the solutions also contained several vitamins. Thus, Sobhy and colleagues recently compared mesotherapy sessions with the same dutasteride-containing solution as previous works with pure dutasteride and saline in men. A trichogram analysis showed that the best result was achieved when dutasteride was used in combination with other substances, increasing hair growth [53]. This result could be explained by the multifactorial pathophysiology of AGA, involving hair follicle sensitivity to DHT and microinflammation. Therefore, a multi-therapeutic approach seems to be more effective in AGA management.

Besides being generally safe, hair mesotherapy may present undesirable effects. Some studies reported patchy hair loss [54] and cicatricial alopecia [55] after the injections. Multifocal scalp abscesses with fat necrosis was also reported [56]. These cases underlie the possible risks of hair mesotherapy, emphasizing the importance of the professional experience and the cocktail composition.

CONCLUSION

Hair mesotherapy is being increasingly used by dermatologists and hair specialists in several countries and is a good alternative to manage AGA. Better results are achieved when dutasteride-containing solutions are used and mesotherapy are early initiated. However, more studies are needed to establish protocols and to evaluate long- term dutasteride injections.

REFERENCES

1. Hamilton JB. Patterned loss of hair in man; types and incidence. Ann N Y Acad Sci. 1951;53:708-28.
2. Birch MP, Messenger AG. Genetic factors predispose to balding and non-balding in men. Eur J Dermatol. 2001;11:309-14.
3. Gan DC, Sinclair RD. Prevalence of male and female pattern hair loss in Maryborough. J Investig Dermatol Symp Proc. 2005;10:184-9.
4. Lee WS, Lee HJ. Characteristics of androgenetic alopecia in asian. Ann Dermatol. 2012;24(3):243-52.
5. Bas Y, Seckin HY, Kalkan G, Takci Z, Citil R, Önder Y, et al. Prevalence and types of androgenetic alopecia in north Anatolian population: A community-based study. J Pak Med Assoc. 2015;65:806-9.
6. Norwood OT. Male pattern baldness: classification and incidence. South Med J. 1975;68:1359-65.
7. Ludwig E. Classification of the types of androgenetic alopecia (common baldness) occurring in the female sex. Br J Dermatol. 1977;97:247-54.
8. Randall VA. Androgens and human hair growth. Clin Endocrinol (Oxf). 1994;40:439-57.
9. Ellis JA, Harrap SB. The genetics of androgenetic alopecia. Clin Dermatol. 2001;19:149-54.
10. Mahé YF, Michelet JF, Billoni N, Jarrousse F, Buan B, Commo S, et al. Androgenetic alopecia and microinflammation. Int J Dermatol. 2000;39:576-84.

11. Ha SJ, Kim JS, Myung JW, Lee HJ, Kim JW. Analysis of genetic polymorphisms of steroid 5alpha-reductase type 1 and 2 genes in Korean men with androgenetic alopecia. J Dermatol Sci. 2003;31:135-41.
12. Hayes VM, Severi G, Padilla EJ, Morris HA, Tilley WD, Southey MC, et al. 5alpha-Reductase type 2 gene variant associations with prostate cancer risk, circulating hormone levels and androgenetic alopecia. Int J Cancer. 2007;120:776-80.
13. Sawaya ME, Price VH. Different levels of 5alpha-reductase type I and II, aromatase, and androgen receptor in hair follicles of women and men with androgenetic alopecia. J Invest Dermatol. 1997;109:296-300.
14. Oh HS, Smart RC. An estrogen receptor pathway regulates the telogen-anagen hair follicle transition and influences epidermal cell proliferation. Proc Natl Acad Sci U S A. 1996;93:12525-30.
15. Banka N, Bunagan MJ, Shapiro J. Pattern hair loss in men: diagnosis and medical treatment. Dermatol Clin. 2013;31:129-40.
16. Ellis JA, Stebbing M, Harrap SB. Polymorphism of the androgen receptor gene is associated with male pattern baldness. J Invest Dermatol. 2001;116:452-5.
17. Olsen EA. Female pattern hair loss. J Am Acad Dermatol. 2001;45:S70-80.
18. Ioannides D, Lazaridou E. Female pattern hair loss. Curr Probl Dermatol. 2015;47:45-54.
19. Torres F, Tosti A. Female pattern alopecia and telogen effluvium: figuring out diffuse alopecia. Semin Cutan Med Surg. 2015;34:67-71.
20. Kaufman KD. Androgen metabolism as it affects hair growth in androgenetic alopecia. Dermatol Clin. 1996;14:697-711.
21. Godoy A, Kawinski E, Li Y, Oka D, Alexiev B, Azzouni F, et al. 5α-reductase type 3 expression in human benign and malignant tissues: a comparative analysis during prostate cancer progression. Prostate. 2011;71:1033-46.
22. Sato T, Sonoda T, Itami S, Takayasu S. Predominance of type I 5alpha-reductase in apocrine sweat glands of patients with excessive or abnormal odour derived from apocrine sweat (osmidrosis). Br J Dermatol. 1998;139:806-10.
23. Thiboutot D, Harris G, Iles V, Cimis G, Gilliland K, Hagari S. Activity of the type 1 5 alpha-reductase exhibits regional differences in isolated sebaceous glands and whole skin. J Invest Dermatol. 1995;105:209-14.
24. Chen W, Zouboulis CC, Orfanos CE. The 5 alpha-reductase system and its inhibitors. Recent development and its perspective in treating androgen-dependent skin disorders. Dermatology. 1996;193:177-84.
25. Ramos PM, Brianezi G, Martins AC, da Silva MG, Marques ME, Miot HA. Apoptosis in follicles of individuals with female pattern hair loss is associated with perifollicular microinflammation. Int J Cosmet Sci. 2016;38:651-4.
26. Lattanand A, Johnson WC. Male pattern alopecia a histopathologic and histochemical study. J Cutan Pathol. 1975;2:58-70.
27. Jaworsky C, Kligman AM, Murphy GF. Characterization of inflammatory infiltrates in male pattern alopecia: implications for pathogenesis. Br J Dermatol. 1992;127:239-46.
28. Whiting DA. Diagnostic and predictive value of horizontal sections of scalp biopsy specimens in male pattern androgenetic alopecia. J Am Acad Dermatol. 1993;28:755-63.
29. Young JW, Conte ET, Leavitt ML, Nafz MA, Schroeter AL. Cutaneous immunopathology of androgenetic alopecia. J Am Osteopath Assoc. 1991;91:765-71.
30. Lee RT, Briggs WH, Cheng GC, Rossiter HB, Libby P, Kupper T. Mechanical deformation promotes secretion of IL-1 alpha and IL-1 receptor antagonist. J Immunol. 1997;159:5084-8.
31. Kupper TS, Groves RW. The interleukin-1 axis and cutaneous inflammation. J Invest Dermatol. 1995;105:62S-6S.
32. Harmon CS, Nevins TD. IL-1 alpha inhibits human hair follicle growth and hair fiber production in whole-organ cultures. Lymphokine Cytokine Res. 1993;12:197-203.
33. Philpott MP, Sanders D, Kealey T. Cultured human hair follicles and growth factors. J Invest Dermatol. 1995;104:44S-5S.
34. Mahé YF, Buan B, Billoni N, Loussouarn G, Michelet JF, Gautier B, et al. Pro-inflammatory cytokine cascade in human plucked hair. Skin Pharmacol. 1996;9:366-75.
35. Smith RS, Smith TJ, Blieden TM, Phipps RP. Fibroblasts as sentinel cells. Synthesis of chemokines and regulation of inflammation. Am J Pathol. 1997;151:317-22.
36. Huber AR, Kunkel SL, Todd RF, Weiss SJ. Regulation of transendothelial neutrophil migration by endogenous interleukin-8. Science. 1991;254:99-102.
37. Nakamura K, Williams IR, Kupper TS. Keratinocyte-derived monocyte chemoattractant protein 1 (MCP-1): analysis in a transgenic model demonstrates MCP-1 can recruit dendritic and Langerhans cells to skin. J Invest Dermatol. 1995;105:635-43.
38. Shapiro J, Wiseman M, Lui H. Practical management of hair loss. Can Fam Physician. 2000;46:1469-77.
39. Chiramel MJ, Sharma VK, Khandpur S, Sreenivas V. Relevance of trichoscopy in the differential diagnosis of alopecia: A cross-sectional study from North India. Indian J Dermatol Venereol Leprol. 2016;82:651-8.
40. Ramos PM, Miot HA. Female Pattern Hair Loss: a clinical and pathophysiological review. An Bras Dermatol. 2015;90:529-43.
41. Vincent M, Yogiraj K. A Descriptive Study of Alopecia Patterns and their Relation to Thyroid Dysfunction. Int J Trichology. 2013;5:57-60.
42. Rogers NE, Avram MR. Medical treatments for male and female pattern hair loss. J Am Acad Dermatol. 2008;59:547-66; quiz 67-8.
43. Clark RV, Hermann DJ, Cunningham GR, Wilson TH, Morrill BB, Hobbs S. Marked suppression of dihydrotestosterone in men with benign prostatic hyperplasia by dutasteride, a dual 5alpha-reductase inhibitor. J Clin Endocrinol Metab. 2004;89:2179-84.
44. Olsen EA, Hordinsky M, Whiting D, Stough D, Hobbs S, Ellis ML, et al. The importance of dual 5alpha-reductase inhibition in the treatment of male pattern hair loss: results of a randomized placebo-controlled study of dutasteride versus finasteride. J Am Acad Dermatol. 2006;55:1014-23.
45. Eun HC, Kwon OS, Yeon JH, Shin HS, Kim BY, Ro BI, et al. Efficacy, safety, and tolerability of dutasteride 0.5 mg once daily in male patients with male pattern hair loss: a randomized, double-blind, placebo-controlled, phase III study. J Am Acad Dermatol. 2010;63:252-8.
46. Gubelin Harcha W, Barboza Martínez J, Tsai TF, Katsuoka K, Kawashima M, Tsuboi R, et al. A randomized, active- and placebo-controlled study of the efficacy and safety of different doses of dutasteride versus placebo and finasteride in the treatment of male subjects with androgenetic alopecia. J Am Acad Dermatol. 2014;70:489-98.e3.
47. Chung HC, Lee S, Lee WS. Long-term efficacy and safety of the dual 5-alpha reductase blocker dutasteride on male androgenetic alopecia patients. J Dermatol. 2016.
48. Abdallah M, El-Zawahry K, Besar H. Mesotherapy using dutasteride-containing solution in male pattern hair loss: a controlled pilot study. PALD. 2009; 20:137-45.
49. Sivagnanam G. Mesotherapy - The french connection. J Pharmacol Pharmacother. 2010;1:4-8.
50. Atiyeh BS, Ibrahim AE, Dibo SA. Cosmetic mesotherapy: between scientific evidence, science fiction, and lucrative business. Aesthetic Plast Surg. 2008;32:842-9.
51. Price VH, Menefee E, Sanchez M, Ruane P, Kaufman KD. Changes in hair weight and hair count in men with androgenetic alopecia after treatment with finasteride, 1 mg, daily. J Am Acad Dermatol. 2002;46:517-23.
52. Moftah N, Abd-Elaziz G, Ahmed N, Hamed Y, Ghannam B, Ibrahim M. Mesotherapy using dutasteride-containing preparation in treatment of female pattern hair loss: photographic, morphometric and ultrastructural evaluation. J Eur Acad Dermatol Venereol. 2013;27:686-93.
53. Sobhy N, Aly H, El Shafee A, El Deeb M. Evaluation of the

effect of injection of dutasteride as mesotherapeutic tool in treatment of androgenetic alopecia in males. Our Dermatol Online. 2013;4:40-5.

54. El-Komy M, Hassan A, Tawdy A, Solimon M, Hady MA. Hair loss at injection sites of mesotherapy for alopecia. J Cosmet Dermatol. 2017.
55. Duque-Estrada B, Vincenzi C, Misciali C, Tosti A. Alopecia secondary to mesotherapy. J Am Acad Dermatol. 2009;61:707-9.
56. Kadry R, Hamadah I, Al-Issa A, Field L, Alrabiah F. Multifocal scalp abscess with subcutaneous fat necrosis and scarring alopecia as a complication of scalp mesotherapy. J Drugs Dermatol. 2008;7:72-3.

Source of Support: Nil, **Conflict of Interest:** None declared.

Clinical Image

Onychomatrichoma

Patricia Chang[1], Tyson Meaux[2]

[1]Department of Dermatology, Hospital General de Enfermedades IGSS and Hospital Ángeles, Guatemala, [2]Resident of LSU Dermatology, Hospital General de Enfermedades IGSS and Hospital Ángeles, Guatemala

Corresponding author: Dr. Patricia Chang, E-mail: pchang2622@gmail.com

40-year-old female referred by her general practitioner for treatment of a fungus on the nail of the left index finger. The lesion had been present for five years and previously treated with fluconazole for 6 months without improvement.

Physical examination revealed an onychopathy localized to the nail of the left index finger, characterized by a yellowish discoloration, thickening, onycholysis, and splinter hemorrhages (Fig. 1), dermoscopic examination showed dimples of distal nail plate (Fig. 2a and b). The remainder of the physical examination was unremarkable.

No significant past medical or family history. dimples of distal nail plate

The lesion had been present for five years, and began with changes in the color of the nail and asymptomatic thickening of its edge. The patient was diagnosed with onychomycosis and treated without observed changes, and therefore he was referred to our department.

With this clinical data, the diagnosis of onychomatricoma was made (Fig. 1) dermoscopic panoramic view of the distal nail plate with small cavities (Fig. 2a) and dermoscopic close up of the small cavities at the free edge of the nail (Fig. 2b) and biopsy was performed of the free border of the nail plate was performed. Hematoxylin and eosin staining revealed the presence of keratin-filled cavities (Fig. 3).

First described by Baran and Kint in 1992, onychomatricoma is a rare, benign, usually painless tumor of the nail matrix. It characterized by digitiform projections from the matrix that also leads to changes of the nail plate. Women in the 5th decade of life are most commonly affected [1]. Clinically, one or multiple fingernails may contain the tumor simultaneously. Physical exam findings include xanthonychia, ungula hyperkeratosis, splinter hemorrhages and longitudinal transverse over-curvature of the nail plate [1-3]. A frontal view of the nail typically reveals multiple holes in the thickened free margin. Tumors may affect the entire nail matrix and nail plate, with the authors of one article suggesting the name "giant onychomatricomas" for this variant [4]. Potentially misleading clinical

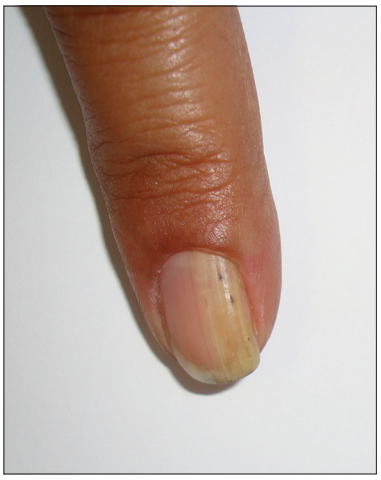

Figure 1: Nail of the left index finger, characterized by a yellowish discoloration, thickening, onycholysis, and splinter hemorrhage.



Figure 2: (a) Dermoscopic panoramic view of the distal nail plate with small cavities. (b) Dermoscopic close up of small cavities at the free edge of the nail.

How to cite this article: Chang P, Meaux T. Onychomatrichoma. Our Dermatol Online. 2017;9(1):80-81.
Submission: 10.04.2017; **Acceptance:** 23.10.2017
DOI: 10.7241/ourd.20181.23

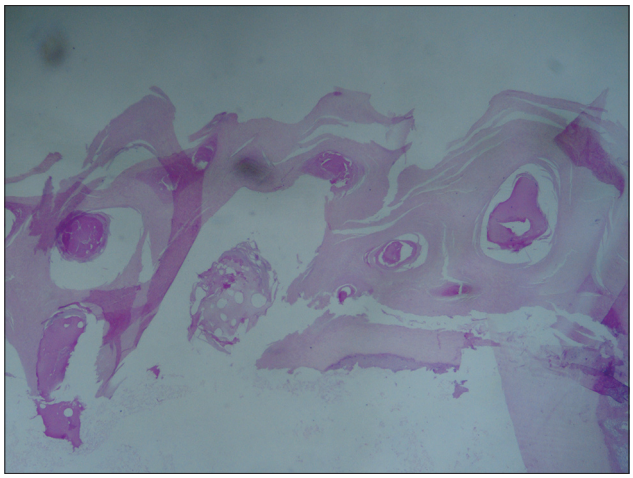

Figure 3: Histopathology of the nail plate revealed the presence of keratin-filled cavities.

findings, such as verrucous surface, total dystrophy of the nail unit, and a pseudofibrokeratoma appearance, have been reported as well. Thus, differential diagnoses may include verruca or Bowen's disease, squamous cell carcinoma, and fibrokeratoma, respectively [5,6]. Diagnosis is often clinical, however histopathologic examination is required in less obvious cases, such as those mentioned above. Excision is usually curative.

As mentioned previously, onychomatricoma is a benign tumor with a fairly straightforward clinical diagnosis in most cases, if the clinician is aware of its existence. The rarity of this entity and possible confusion due to less than classic clinical presentation may require further workup. Diagnosis may not be obvious until surgery is performed, at which point the typical filiform projections are more visible [4]. Pathologists may be faced with making the diagnosis without the nail plate, as it is often not submitted. In these cases, histologic findings are characterized by a pedunculated fibroepithelial tumor reminiscent of a fibrokeratoma on longitudinal section. Distinguishing features include epithelial-lined invaginations around optical cavities and a stroma organized in 2 layers. A good potential marker of onychomatricoma is antibody AE13, specific to trichocytic keratins Ha 1-4 [7]. Immunohistochemistry can also be helpful. Onychomatricoma typically exhibits positive staining for CD34, epithelial membrane antigen, S-100, actin, and desmin [6]. Keratinization is without a granular layer [3]. Although considered a benign lesion, onychomatricoma may have malignant potential. Complete excision recommended to avoid recurrence [2].

REFERENCES

1. Tavares GT, Chiacchio NG, de Souza MV. Onychomatricoma: a tumor unknown to dermatologists. An Bras Dermatol. 2015;90:265-7.
2. Chang P, Meaux T. Onicomatricoma. Informe de un caso. DCMQ. 2015;13:162-4.
3. Tosti A, Piraccini BM. Nail Disorders In: Bolognia JL, Jorizzo JL, Schaffer JV, eds. Dermatology. 3rd ed. Philadelphia, PA: Elsevier Saunders; 2012: chap 71:1145.
4. Estrada-Chavez G, Vega-Memije ME, Toussaint-Caire S, Rangel L, Dominguez-Cherit J. Giant onychomatricoma: report of two cases with rare clinical presentation. Int J Dermatol. 2007;46:634-6.
5. Perrin C, Baran R, Balaguer T, Chignon-Sicard B, Cannata GE, Petrella T, MichielsJF. Onychomatricoma: new clinical and histological features. A review of 19 tumors. Am J Dermatopathol. 2010;32:1-8.
6. Fraga GR, Patterson JW, McHargue CA. Onychomatricoma: report of a case and its comparison with fibrokeratoma of the nailbed. J Dermatopathol. 2001;23:36-40.
7. Perrin C, Baran R, Pisani A, Ortonne JP, Michiels JF. The onychomatricoma: additional histologic criteria and immunohistochemical study. Am J Dermatopathol. 2002;24:199-203.

Source of Support: Nil, **Conflict of Interest:** None declared.

Letter to the Editor

Glabella: A susceptible area to tissue necrosis upon injection of hyaluronic acid filler

Kwon Osung, Chung Hyun, Park Joonsoo

Department of Dermatology, School of Medicine, Catholic University of Daegu, Namgu, Daegu, South Korea

Corresponding author: Joonsoo Park, M.D., Ph.D., E-mail: g9563009@cu.ac.kr

Sir,

Filler injection has become widely used to remove the appearance of wrinkles and reduce the skin folds. Recently hyauluronic acid has become the material of the choice for filler injection. Hyaluronic acid filler has advantages in its long lasting features, low immunogenicity, and reversibility. However, despite its advantages, hyaluronic acid can cause tissue necrosis with interruption of vascular supply from injected hyaluronic acid gel [1].

A 49-year-old woman presented with erythematous patches, vesicles, ecchymosis with ulceration on the glabella and forehead for few days (Fig. 1). The lesion developed after hyaluronic acid filler injection in local hospital. The patient was not involved with any dermatologic, immunologic past history. The punch biopsy was done from the ulcerative lesion. The biopsy of the lesion showed necrotic, ulcerated epidermis with lymphohistiocytic and neutrophilic infiltration in the dermis. Extracellular basophilic amorphous materials, which highly suggest injected hyaluronic acid gels were also observed (Fig. 2). The skin lesion was improved with residual scar after treating with steroids and antibiotics for 1 month.

A considerable number of case reports are published and concluded the glabella as a 'danger area' of tissue necrosis. Paucity of collateral circulation of vascular supply in glabella makes it vulnerable to tissue necrosis. The nature of heavy bleeding druing filler injection and acute onset of skin lesion were conclusive clues to a skin necrosis caused by hyaluronic acid as presented in this case [2].

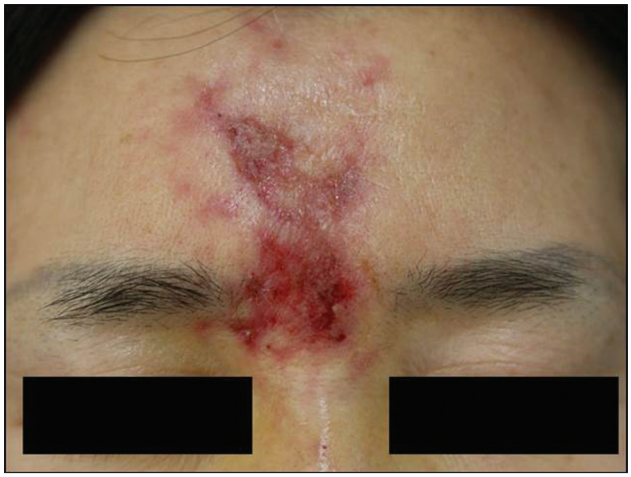

Figure 1: Clincal image of the patient presenting erythematous ulcerative patches on glabella.

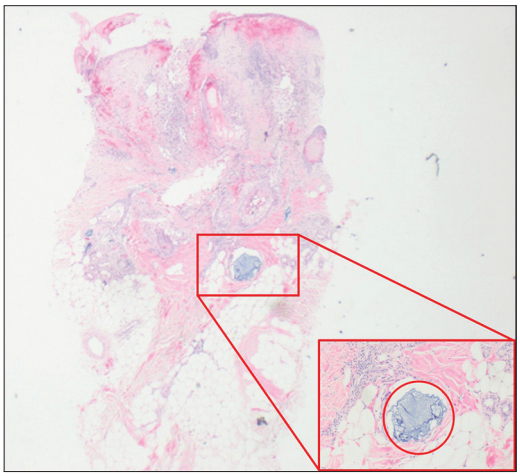

Figure 2: The histopathological examination shows ulcerative epidermis, extravasation of erythrocyte with lymphohistiocytic infiltration in dermis. Extracellular basophilic amorphous material in dermis is shown in inlet (red circle). (H&E x20, inlet H&E x100).

How to cite this article: Osung K, Hyun C, Joonsoo P. Glabella: A susceptible area to tissue necrosis upon injection of hyaluronic acid filler. Our Dermatol Online. 2018;9(1):82-83.

Submission: 18.10.2017; **Acceptance:** 18.11.2017

DOI: 10.7241/ourd.20181.24

In order to prevent vascular occlusion, the depth of filler injection around glabella should remain superficial and the needle point should be directed centrally. In addition, the injection must be delivered over two to three times rather than injecting it continuously. Regurgitation of the syringe is also critical to prevent vascular injury [3]. Upon suspicion of vascular occlusion, hot compression and 2% nitroglycerin should be delivered to restore blood flow. Moreover injection of hyaluronidase and low molecular weight heparin may be conducive to relive the occluded area [3,4]. Therapeutic options to consider in tissue necrosis include a number of measures from hot and cold compressions, antibiotics, steroids to laser and surgical revision in severe cases. The presented case showed improvement after applying topical steroids along with oral steroids and antibiotics. As filler procedures performed by non-dermatology medical providers, inadvertent use of hyaluronic acid increases which ultimately lead to vast number of tissue necrosis. The anatomical aspects of filler injection in areas such as the glabella and tip of the nose should require more precaution and regular follow-ups as these are more susceptible to tissue necrosis.

REFERENCES

1. Park TH, Seo SW, Kim JK, Chang CH. Clinical experience with Hyaluronic acid-filler complications. J Plast Reconstr Aesthet Surg. 2011;64:892-6.
2. Grunebaum LD, Bogdan Allemann I, Dayan S, Mandy S, Baumann L. The risk of alar necrosis associated with dermal filler injection. Dermatol Surg. 2009;35 Suppl 2:1635-40.
3. Joel L. Cohen Understanding, avoiding, and managing dermal filler complications. Dermatol Surg. 2008;34:S92-9.
4. Kassir R, Kolluru A, Kassir M. Extensive necrosis after injection of hyaluronic acid filler: case report and review of the literature. J Cosmet Dermatol. 2011;10:224-31.

Source of Support: Nil, **Conflict of Interest:** None declared.

Letter to the Editor

Symmetrical interdigital hyperkeratosis of the hands

Kwon Osung, Chung Hyun, Park Joonsoo

Department of Dermatology, School of Medicine, Catholic University of Daegu, Namgu, Daegu, South Korea

Corresponding author: Joonsoo Park, M.D., Ph.D., E-mail: g9563009@cu.ac.kr

Sir,

Symmetrical interdigital hyperkeratosis is a rare disorder described by Frei in 1923 [1]. He reported a case of a patient with congenital circumscribed hyperkeratosis of the interdigital spaces of the hands and feet. There was a slight hyperkeratosis on the dorsal aspects of some interphalangeal joints and on the elbows and knees. No keratoderma or hyperhydrosis of the palms and soles was observed. Frei named this condition "Congenital Symmetrical Interdigital Hyperkeratosis".

A 35-year-old man presented with a symmetrical keratoderma localized to the interdigital spaces of the fingers. Skin thickening was developed when he was 15 years old. There was no relevant family history. There were no occupational and traumatic factors those could have affected this condition. There were no symptoms or signs of preceding infections. On physical examination, there were dark brownish colored hyperkeratotic plaques on his both first, second, third interdigital spaces of hands and the lesions slightly extended over dorsal aspects of some metacarpophalangeal joints of hands (Fig. 1). At the palm, there were no keratoderma and hyperhidrosis. The finger nails were normal. Skin biopsy showed orthokeratotic hyperkeratosis, hypergranulosis, acanthosis (Fig. 2). Although he was treated with keratolytics, there was no response to keratolytics. Clinical and histological features were consistent with the diagnosis of symmetrical interdigital hyperkeratosis.

Since the first case was reported in 1923, few cases have been reported in the literatures. In 1990, Salamon reported a similar condition in a 19-year-old male [2]. The skin lesions were limited to the interdigital spaces of the hand. In 1993, Patrizi et al. reported the case of a 7-year-old female who showed symmetrical lesions of the second, third and fourth interdigital spaces of the hands [3]. In 1995, Di Lernia et al. reported a similar case of a 28-year-old male who showed symmetrical lesions of all the finger interdigital spaces of the hands [4]. In 2004, Raddadi reported the case of a 2-year-old female who showed similar clinical condition of previously reported cases [5]. Because there has been only few cases reported,

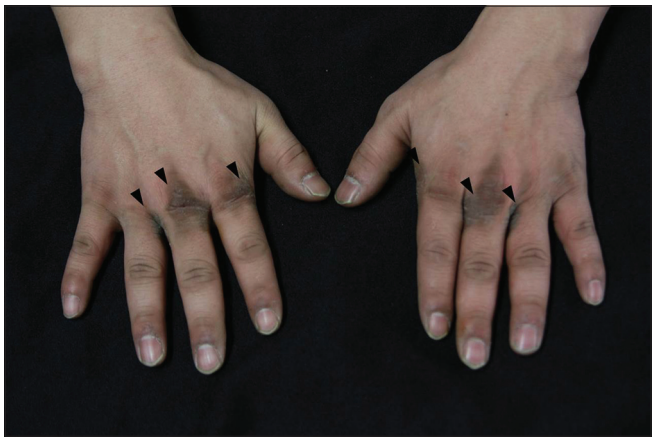

Figure 1: Symmetrical keratoderma localized to the interdigital spaces of the fingers.

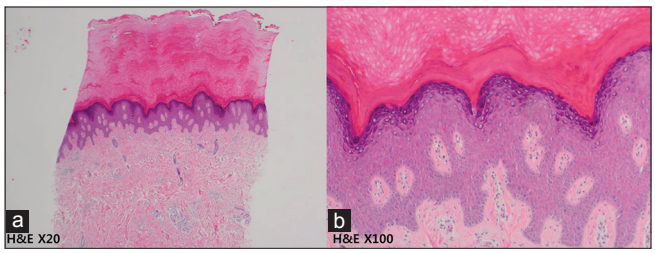

Figure 2: a) Histology revealed compacted orthokeratosis, hypergranulosis with variably elongated epidermis and without significant infiltration of inflammatory cells (H&E x20). b) Higher magnification revealed prominent acanthosis and papillomatous various of epidermis (H&E x100).

How to cite this article: Osung K, Hyun C, Joonsoo P. Symmetrical interdigital hyperkeratosis of the hands. Our Dermatol Online. 2018;9(1):84-85
Submission: 18.10.2017; **Acceptance:** 18.11.2017
DOI:10.7241/ourd.20181.25

the pathogenesis, clinical findings, and treatment of symmetrical interdigital hyperkeratosis. To put the various reports together, the disease occurs mainly from first decade to third decade with no occupational, traumatic, or irritant factor that could affect the lesion [6]. Clinically, it shows keratoderma on the both interdigital spaces of the hands and feet. In majority of cases, the lesions were limited to the fingers and didn't involve the entire hands. Salamon reported a case of symmetrical interdigital hyperkeratosis with scrotal tongue and highly arched palate, but there weren't any accompanied skin lesion or other lesions. Palm was not involved and did not accompany hyperhydrosis. Histological examination shows hyperkeratosis, hypergranulosis, and irregular acanthosis. The lesions responded poorly to the treatment such as topical steroid or keratolytics and this can be helpful to the diagnosis. Among reported cases, 2 cases had family history of the disease and feet were involved in both cases. Other 4 cases including this case were sporadic occurrence and localized exclusively to the hands. Despite the symmetrical interdigital hyperkeratosis is not well known, if appears to involve the foot in congenital type and sporadic type is limited to the hands. This could suggest that interdigital hyperkeratosis could be divided into two subtypes, congenital and sporadic, which show different clinical findings.

Considering the lack of insight and subjective symptom of disease, the prevalence of disease could be higher than it is reported. Evaluation of pathogenesis, specific findings, and treatment of disease with additional case reports is needed.

REFERENCES

1. Dimitropoulos VA. Dermatofibrosarcoma protuberans. Dermatol Ther. 2008;21:428-32.
2. Kovarik CL, Hsu M-Y, Cockerell CJ. Neurofibromatous changes in dermatofibrosarcoma protuberans: a potential pitfall in the diagnosis of a serious cutaneous soft tissue neoplasm. J Cutan Pathol. 2004;31:492-6.
3. Fiore M, Miceli R, Mussi C, Lo Vullo S, Mariani L, Lozza L, et al. Dermatofibrosarcoma protuberans treated at a single institution: a surgical disease with a high cure rate. J Clin Oncol. 2005;23:7669-75.
4. Heenan PJ. Tumor of the fibrous tissue involving the skin. In: Elder DE, Elenitas R, Johnson BL Jr, eds. Lever's histopathology of the skin. Philadelphia, PA: Lippincott Williams & Wilkins; 2005:979-1013.
5. Grouls V. Dermatofibrosarcoma protuberans: a variant myxoid. Pathol. 1984;5:226-30.
6. Reimann JD, Fletcher CD. Myxoid dermatofibrosarcoma protuberans: a rare variant analyzed in a series of 23 cases. Am J Surg Pathol. 2007;31:1371-7.

Source of Support: Nil, **Conflict of Interest:** None declared.

Letter to the Editor

Piloleiomiomas multiples

Patricia Chang[1], María Lucia Monzón Quintana[2], Gylari Calderón Pacheco[1]

[1]Department of Dermatology, Hospital General de Enfermedades IGSS and Hospital Ángeles, Guatemala, [2]Hospital General de Enfermedades IGSS and Hospital Ángeles, Guatemala

Corresponding author: Dr. Patricia Chang, E-mail: pchang2622@gmail.com

Sir

We are called to evaluate a 51-year-old patient with urticaria who is hospitalized in the Hematology ward for treatment of Non-Hodgkin lymphoma. On examination, she presents with lesions of urticaria. There is also presence of a disseminated dermatosis to the left anterior thorax (Fig. 1) and upper extremities mainly right arm. Such dermatosis is characterized by multiple brown, hard and 0.6cm nodular lesions (Figs. 2 and 3). The rest of the exam shows cytostatic-use secondary alopecia, melasma, nevi, and melanonychia in hands secondary to chemotherapy.

Other than the Non-Hodgkin lymphoma for which she is being treated now she has no other relevant medical history. Her family medical history is also negative.

She first noticed these lesions 20 years ago. They began as "little balls" in the right arm. At that moment, they weren't associated with any symptom such as pain or other. With time, they began growing and appearing in other parts of her body such as her chest. Nonetheless, she had never given them attention or became concerned about them.

With this information, the diagnosis of multiple piloleiomyoma is made. A skin biopsy of one of the nodules is taken to confirm the diagnosis. Biopsy results show an ill-defined, well delimited, without a capsule neoplasm comprised of spindle cells located in the dermis. At a greater magnification, it is seen that the cells are disposed in multiple directions and originate from the arrector pili muscle (Figs. 4 and 5). At a 40x it can also been seen that the cells that comprise the lesion have an eosinophilic cytoplasm and elongated nuclei (Fig. 6).

Leiomyomas are benign smooth muscle neoplasms [1]. They can appear in different areas of the body where this type of cells can be found. Their presence hast been described in the genitourinary tract, gastrointestinal tract and skin [2]. 95% of leiomyomas are found in the uterus [3]. On the other hand, 75% of extra-uterine leiomyomas are found on the skin. Skin leiomyomas represent 3-5% of all leiomyomas [4].

According to their origin, they can be classified in one of the 3 types of cutaneous leiomyomas [5]: piloleiomyomas, angioleiomyomas, and genital or nipple leiomyomas. Piloleiomyomas arise from the arrector pili muscle. On the other hand, angioleiomyomas originate from the dermal blood vessels and genital leiomyoma from the dartos, vulvar or areola. The most common type is the piloleiomyoma followed by the angioleiomyoma [6,7]. Because of their unique site of origin, each of them has different histologic characteristics [8].

Piloleiomyomas were first described in 1854 by Rudolf Virchow [9]. They are also known by the name of pilar leiomyoma. As mentioned above, they are benign smooth muscle neoplasms that originate from the arrector pili muscle.

They can appear at any age and in both men and women. They can also be solitary or multiple lesions [4]. Multiple lesions are more common and tend to appear at a younger age. Mean age at presentation is between the second and third decade of life [5]. A family history can be identified in some of the cases since their appearance can be spontaneous or familial with an autosomal dominant mode of inheritance [6]. Clinically, they present as papules or nodules with a 1-2cm diameter, violaceous or brown color, firm

How to cite this article: Chang P, Monzón Quintana ML, Pacheco GC. Piloleiomiomas multiples. 2018;9(1):86-88.
Submission: 17.02.2017; **Acceptance:** 29.06.2017
DOI: 10.7241/ourd.20181.26

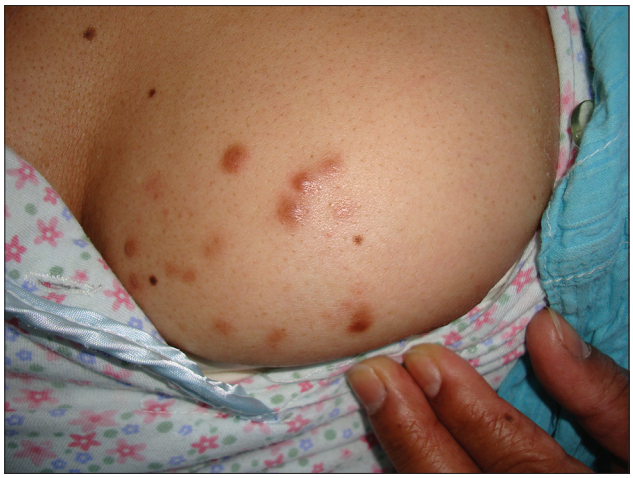

Figure 1: Nodules in left anterior thorax.

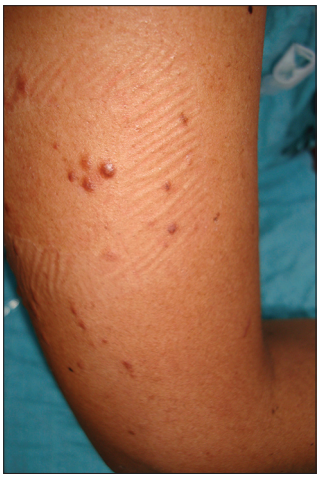

Figure 2: Multiple flesh-brown nodules in right arm.

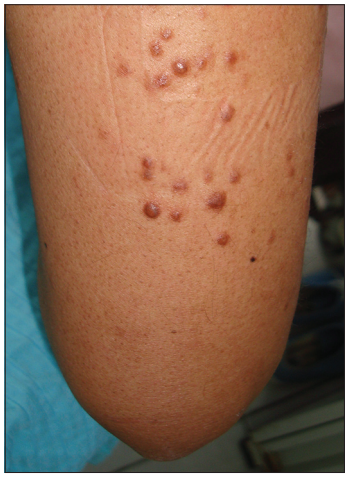

Figure 3: Multiple flesh-brown nodules in right arm.

consistency and smooth surface [7]. When there are multiple lesions they can appear following a linear or dermatomal distribution [4]. They can be found in different parts of the body [9]. The most frequently

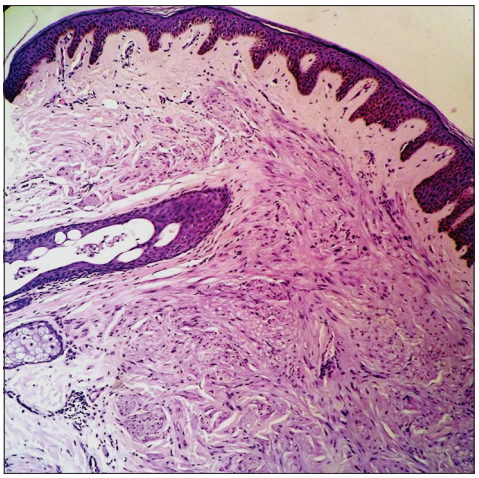

Figure 4: Well delimited, unencapsulated neoplasm in dermis comprised of bundles of spindle cells. 40x magnification.

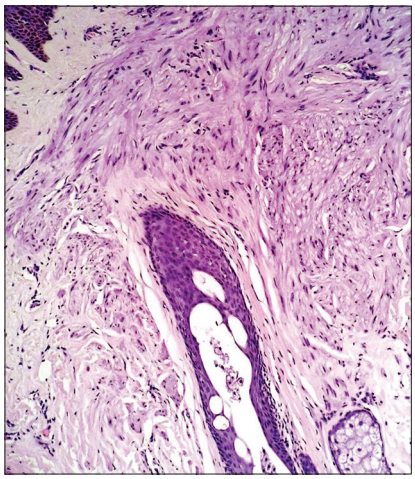

Figure 5: At a greater magnification, it can be appreciated that spindle cells are disposed in bundles following different directions and originate in the arrector pili muscle.

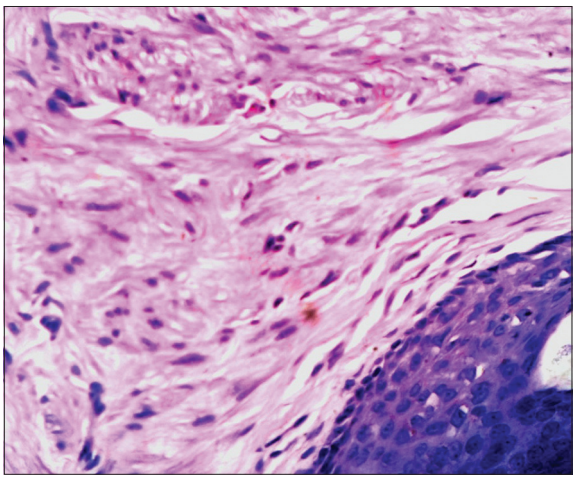

Figure 6: At a 40x magnification it can be appreciated that cells are spindle-shaped, and contain an eosinophilic cytoplasm with elongated nuclei.

affected areas are extremities and trunk [5]. In the first place, they tend to appear in the extensor and proximal

areas. Less than 1% of piloleiomyomas are found in the face or neck [4].

With time, there can appear new lesions and they also tend to grow [2]. They are painful in most cases [9]. Such sensation varies in intensity and duration. It can appear spontaneously or following trauma, pressure, cold temperatures or emotional stress [6,10]. The exact mechanism by which pain is caused is unknown. It has been suggested that it is the result of pressure on nerve fibers or the contraction of the muscle fibers that comprise it [2].

Differential diagnoses include: leiomyosarcoma, dermatofibroma, neurofibroma, smooth muscle hamartoma, schwannoma, angioleiomyoma, and others [6].

Definite diagnosis is made by biopsy [10]. Findings in such procedure include the presence of an ill-defined neoplasm located in the reticular dermis separated from the epidermis by an unaffected area [5]. The lesion is comprised by bundles of muscle fibers intermixed with collagen fibers [6]. The muscle fiber nuclei present important characteristics: small, central position, spindle-shaped and with blunt edges [3]. There is no presence of cellular atypia, mitosis or necrosis [10]. Smooth muscle presence can be confirmed with certain stains such as SMA, Masson trichrome and desmin.

Treatment options are variable and several aspects must be considered before deciding the best approach. Examples of such aspects include: the number and location of lesions, presence or abscence of pain or other symptoms and the patient expectations. In the case of solitary or few lesions associated with mild or no pain, chirurgic excision of the lesions is an adequate approach. Nonetheless, it is important to consider that lesions can reappear [6]. When there are multiple lesions, chirurgic excision is also an option but only for the most painful. Management of pain can include use of nitroglycerin, phenoxybenzamine and nifedipine [10]. Other treatment approaches but with limited efficaciousness include CO2 laser, cryotherapy, electrocoagulation, and others [2].

Piloleiomyomas can be associated with other medical conditions, which makes the need for a complete general evaluation important. They have been associated with uterine leiomyomas and renal cell carcinoma. When they are associated with the first, it is known as Reed syndrome [11]. The association with renal cell carcinoma is important since it tends to be aggressive in its presentation.

REFERENCES

1. Elgendy A, alshawadfy E, Ali E. Pilar leiomyoma located on the back: a case report. J Clin Exp Dermatol Resch. 2015;6:1-3.
2. Hoyt B, Tschen J, Cohen P. Solitary pilar leiomyoma of the nasal dorsum: case report and literature review. Indian J Dermatol. 2015;60:82-4.
3. Dutto S, Dupuy S, Achenbach R, Pittaro E, Jorge M, Sánchez G. Piloleiomiomas multiples. Rev Argent Dermatol. 2015;*96*:36-42.
4. Sousa M, Farias C, Santos I, Rocha R, Dias F, Sá H. Piloleiomyoma with segmental distribution- case report. Ann Bras Dermatol. 2015;90:170-80.
5. Young S, Park J, Gyo H, Yong C. A case of multiple piloleiomyoma on the shoulder. Arch Aesthetic Plast Surg. 2015;21:81-4.
6. Horia Morariu S, Suciu M, Alexandru Badea M. Multiple asymptomatic cutaneous pilar leiomyoma versus spontaneus eruptive keloids- a case report. Rom J Morphol Embryol. 2016;57:283-7.
7. Vaithy A, Kotasthane D. Cutaeneous leiomyoma: case study with review of literature on rare variants and clinical behavior. Int J Pharm Bio Scien. 2015;6:907-13.
8. Qadir F, Omprakash S, Dharm C, Kumari S. Cutaneous leiomyoma of scalp: a rare case report with review of literature. Int J Res Med Scienc. 2015;3:993-7.
9. Pandey I, Gupta A. Reed's syndrome: rare tumor disarray. J Post Gynecol Obstet. 2015;3:84-7.
10. Young S, Ho J, Gyo H, Yong C. A case of multiple piloleiomyoma on the shoulder which is mistaken for keloid. Arch Aesthetic Plast Surg. 2015;21:81-4.
11. Rajdeo R, Shrivastava A, Shrikhande A. Multiple cutaneous piloleiomyoma with uterine fibroids (Reed's syndrome): a rare case report. Int J Clin Bio Res. 2015;1:66-9.

Source of Support: Nil, **Conflict of Interest:** None declared.

Letter to the Editor

Six cases of purpuric eruptions induced by epidermal growth factor receptor inhibitors

Tomoko Hiraiwa, Yuka Hanami, Toshiyuki Yamamoto

Department of Dermatology, Fukushima Medical University, Hikarigaoka 1, Fukushima 960-1295, Japan

Corresponding author: Dr. Tomoko Hiraiwa, E-mail: toishi@fmu.ac.jp

Sir,

Erlotinib (Tarceva®) and gefitinib (Iressa®) are novel oral tyrosine kinase inhibitors targeting epidermal growth factor receptor (EGF-R). A number of skin reactions have been induced, however, purpuric eruption is rare. We report six cases of purpuric lesions some of which exhibited clinically mimicking Henoch-Schönlein purpura that occurred after treatment with EGF-R inhibitors for lung cancers. Two were men and four were women, and the mean age was 67.8 years (range: 60 to 80 year old). Clinical presentations are shown in Fig. 1, and the summary of cases is shown in Table 1. On physical examination, all cases had many small purpuric lesions with a diameter of 1-2 mm on the lower extremities, and trunk was also involved in one case. All of the cases were palpable purpura. Five cases had pustules in the center of purpuric lesions, and xerosis was observed in all cases. Erlotinib was thought to be the causative agent in three cases, two of them were switched from gefitinib to erlotinib, whereas other three cases were due to gefitinib. The duration ranged between 2 weeks and 6 months (mean: 2.9 months) after starting EGF-R inhibitors. Histopathological examination was performed in four cases, which revealed mild infiltrate of lymphocytes around the capillaries and extravasation of red blood cells in the upper dermis (Fig. 2), but there were no finding of leukocytoclastic vasculitis. Direct immunofluorescence was performed in one case, and there was no deposition of immunoglobulins. Skin eruptions were spontaneously improved by only interruption of the causative drugs, almost within 1 week. Platelet counts and coagulation profiles were within normal ranges in all cases. Four cases showed a favorable response to EGF-R inhibitors. By contrast,

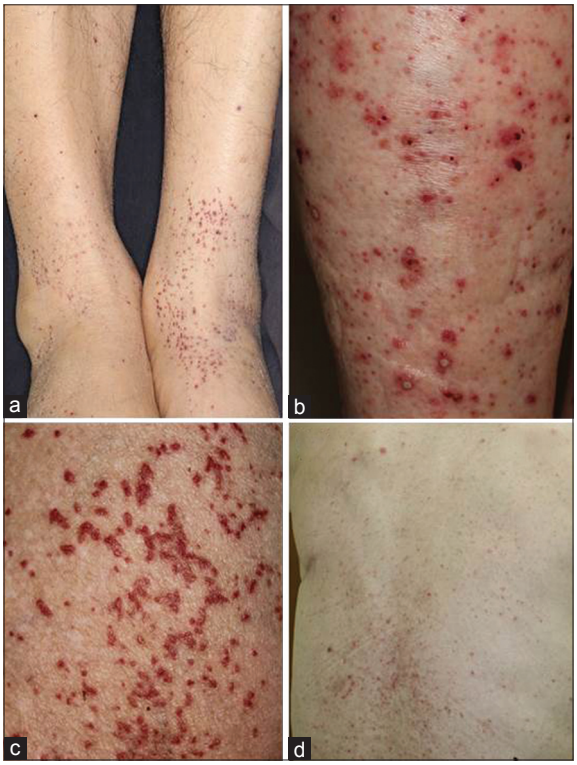

Figure 1: A significant number of palpable purpuric lesions on the lower leg (a-c). Pustular lesions are also seen (b). Purpuric lesions spread on the back (d).

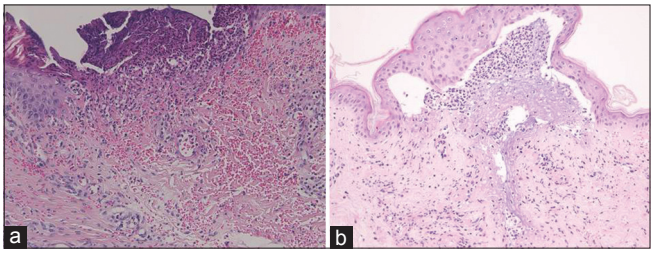

Figure 2: Histopathological findings from papulopustular lesions show neutrophilic infiltration and a neutrophilic abscess in the epidermis (a, b). Extravasation of erythrocytes and perivascular lymphocytes are seen in the upper dermis (H-E stain, magnification x200).

How to cite this article: Hiraiwa T, Hanami Y, Yamamoto T. Six cases of purpuric eruptions induced by epidermal growth factor receptor inhibitors. Our Dermatol Online. 2018;9(1):89-90.

Submission: 15.02.2017; **Acceptance:** 30.05.2017

DOI: 10.7241/ourd.20181.27

Table 1: Characteristics of patients presenting with purpuric lesions during EGF-R inhibitor treatmen

Case	Age	Sex	Primary illness	EGF-R inhibitor (Dose, Duration)	Prior use	Site	Pustule	Xerosis	Other	Histopathological findings	
										Vasculitis	IF
1	68	F	Lung cancer	Erlotinib (150 mg/day, 2 weeks)	Gefitinib	Lower legs	+	+	paronychia	-	-
2	71	F	Lung cancer	Erlotinib (150 mg/day, 2 months)	Gefitinib	Legs	+	+	-	-	n.d.
3	60	M	Lung cancer	Gefitinib (250 mg/day, 3 months)	-	legs abdomen chest	+	+	-	n.d.	n.d.
4	64	M	Lung cancer	Gefitinib (250 mg/day, 3 weeks)	-	Ankles	-	+	Paronychia	-	n.d.
5	64	F	Lung cancer	Gefitinib (250 mg/day, 5 months)	-	Legs	+	+	Paronychia, acneform eruption of the head and face	-	n.d.
6	80	F	Lung cancer	Erlotinib (100 mg/day, 6 months)	-	Legs	+	+	Acneform eruption of the face	n.d.	n.d.

in 2 cases, EGF-R inhibitors started after multiple metastases occurred, and both of them died.

To date, several cases of purpuric eruptions after treatment with gefitinib have been reported, among which leukocytoclastic vasculitis was observed in 4 cases, whereas association with erlotinib have been reported in only a few cases [1]. Our cases did not show vasculitis, and three out of the four cases did not present with folliculitis even by serial cut sections. EGF-R is expressed by endothelial cells in the skin, and thus EGF-R inhibitor altered the vessel morphology, vascular dilation, and vascular permeability [2,3]. Therefore, inhibition of EGF-R on the endothelial cells of cutaneous vessels may contribute to the induction of minor vascular impairment, ectatic vessels, and extravasation of erythrocytes, leading to purpuric eruptions. Other possibilities such as occlusive vasculopathy of the subcutaneous vascular system, and increased platelet aggregation and thromboxane levels have been suggested [4]. Additionally, neutrophils may also be attracted to the epidermis *via* chemoattractants, forming pustules. EGF-R inhibitors-induced purpura occurs along with xerosis and pustules most frequently on the lower limbs, but rarely arises on the trunk at the early phase from initiation of therapies with EGF-R inhibitors. Among 6 cases presented here, favorable effects of EGF-R inhibitors were confirmed in 4 cases. Whether the development of purpuric eruptions are related to good response to EGF-R inhibitors or not should be determined in the future, accumulating more number of cases.

REFERENCES

1. Yamamoto T. Erlotinib-induced adverse skin reactions. Open Allergy J. 2013;6:22-9.
2. Van Doorn R, Kirtschig G, Scheffer E, Stoof TJ, Giaccone G. Follicular and epidermal alterations in patients treated with ZD1839 (Iressa), an inhibitor of the epidermal growth factor receptor. Br J Dermatol. 2002;147:598-601.
3. Cerniglia GJ, Pore N, Tsai JH, Schultz S, Mick R, Choe R, et al. Epidermal growth factor receptor inhibition modulates the microenvironment by vascular normalization to improve chemotherapy and radiotherapy efficacy. PLoS One2009;4:e6539.
4. Kurokawa S, Yamaguchi K. Kinoshita Y, Muramatsu M, Komiyama Y, Nomura S. Gefitinib affects functions of platelet and blood vessels via changes in prostanoids balance. Clin Appl Throm Hemost. 2005;11:429-34.

Source of Support: Nil, **Conflict of Interest:** None declared.

Letter to the Editor

Urticaria from penicillin as the sole clue to acute onset of disabling arthritis

Brittany Urso[1], James A. Solomon[1,2,3]

[1]University of Central Florida College of Medicine, Orlando Florida, USA, [2]University of Illinois College of Medicine, Urbana Illinois, USA, [3]Ameriderm Research, Ormond Beach Florida, USA

Corresponding author: Brittany Urso, E-mail: Brittany.Urso@knights.ucf.edu

Sir,

Many patients suffer from diseases of unknown cause, while the cause surrounds them disguised by deceptive labelling terms. Patients with rashes from fragrances will continue to suffer despite using "unscented" skin products and soaps which contain fragrances under the label of "essential oils". They may react also to natural food/plant sources of the fragrance. Cinnamic aldehyde, a common contact allergen derived from cinnamon, and Balsam of Peru are used to make fragrances for perfumes, skin products, and tobacco. Despite 70% of drugs being food/plant derivatives, the natural source of a drug is often overlooked as clinically important in assessing "drug" allergens [1].

Report of a Case

We present a healthy 35-year-old nurse with a history of urticaria from penicillin who suddenly developed polyarthralgias over a 3-month period. Since she could no longer jog, nor even climb one flight of stairs and had failed to respond to medications, she planned to take a medical leave of absence and move onto the first floor of her house. She had been seen by several rheumatologists who, after an extensive workup with blood tests and radiology exam, were unable to identify the etiology of this acute arthritis nor to find a medication which controlled her symptoms. She was emphatic that she had not taken any penicillin, nor related medications, prior to the onset of this event. She denied any hypersensitivities or significant changes in her lifestyle, exposures, or diet associated with this period aside from her family hosting a French exchange student for the last 4-months. After discussing the patient's penicillin allergy with her, as well as the way penicillin was discovered, it was mentioned that penicillin is a common contaminant of any aging naturally rotting substance [2]. With this, she realized a potential source of her arthritis. To lessen the exchange student's homesickness, she purchased aged cheeses for everyone to eat after school. With the acknowledgement that cheese is a natural source of penicillin, she changed her diet and within 2 weeks her polyarthralgias resolved [2].

DISCUSSION

The goal of this paper is to reinforce the idea that, especially in patients with atypical treatment resistant disease, there may be a hidden etiology which triggers the patient's condition. The clue to such may include a history of an adverse cutaneous reaction. Although it is well recognized that many medications are derived from plant, animal, or mineral natural sources, what may not be considered is that reaction to medications also may indicate reactions to the food sources of these medications [3]. These reactions to the natural sources of medications may be more likely in patients who have had severe reactions to the medication, suggesting that a molar exposure lower than required for therapeutic effect can elicit an adverse immune response [4].

REFERENCES

1. Kiec-Swierczynska M, Krecisz B, Swierczynska-Machura D. [Contact allergy to fragrances]. Med Pr. 2006;57:431-7.
2. Laich F, Fierro F, Martin JF. Production of penicillin by fungi growing on food products: identification of a complete penicillin gene cluster in Penicillium griseofulvum and a truncated cluster in Penicillium verrucosum. Appl Environ Microbiol. 2002;68:1211-9.

How to cite this article: Urso B, Solomon JA. Urticaria from penicillin as the sole clue to acute onset of disabling arthritis. Our Dermatol Online. 2018;9(1):91-92.
Submission: 08.07.2017; **Acceptance:** 20.10.2017
DOI: 10.7241/ourd.20181.28

3. Zeng ZP, Jiang JG. Analysis of the adverse reactions induced by natural product-derived drugs. Br J Pharmacol. 2010;159:1374-91.
4. Aronson JK, Ferner RE. The law of mass action and the pharmacological concentration-effect curve: resolving the paradox of apparently non-dose-related adverse drug reactions. Br J Clin Pharmacol. 2016;81:56-61.

Source of Support: Nil, **Conflict of Interest:** None declared.

Letter to the Editor

Phytophotodermatitis following the use of Ammi Majus Linn (Bishop's weed) for vitiligo

Imane Alouani[1], Nadia Fihmi[1], Nada Zizi[1,2], Siham Dikhaye[1,2]

[1]Department of Dermatology, Mohammed 6 University Hospital of Oujda - Medical School of Oujda, Mohammed First University of Oujda, Morocco, [2]Laboratory of Epidemiology, Clinical Research and Public Health, Medical School of Oujda, Mohammed First University of Oujda, Morocco

Corresponding author: Dr. Imane Alouani, E-mail: alouani01@gmail.com

Sir,

Phytophotodermatitis (PPD) is a well-known entity that is causes by sequential exposure to certain species of plants and then to sunlight. In our social context where many patients resort to use herbal medicine, we report a case of a phytophotodermatitis following the use of Ammi majus L. as a treatment of vitiligo.

A 46 years old patient was presenting vitiligo since the age of 15. After having a "prescription" from a radio show, she applied a mix of Ammi majus leaves, also known as Bishop's weed, and Anacyclus pyrethrum on her vitiligo skin lesions and then exposed herself directly to the sunlight. One day later, she developed a burning sensation, pain, itch and erythema on her vitiligo patches, she subsequently developed multiple bullae (Fig. 1). A diagnosis of phytophotodermatosis was made, with a complete resolution of her symptoms after symptomatic treatment.

Phyotophotodermatitis is a cutaneous phototoxic inflammatory eruption resulting from contact with light-sensitizing botanical substances and long-wave ultraviolet radiation [1]. Those substances usually contain furocoumarins. The intensity of the induced phototoxic reaction depends upon a number of factors. Many studies and case reports have described different plants with a different ability to cause a phototoxic reaction.

Amongst the family of the Apiaceae, the Ammi majus Linn, used by our patient, is well-known for its photo-toxic and photo-allergic properties [2]. Its content of coumarin is ranging from 50 to 900mg per 100g [3]. It was responsible of a dermal-epidermal cleavage, leading to apparition of vesicles and bullae. Two other cases of phytophotodermatitis by using Ammi majus L. were reported in literature [1-4]. Other authors described cases of urticaria, allergic rhinitis and ocular toxicity after the use of this plant [5].

On the other hand, and since the 13th century, the Egyptians have used a powder prepared from the fruit of this plant for the treatment of leukodermas. However, the powder of Ammi Majus Linn, just like that of Ammi Visnaga, provoked such undesirable manifestations as headache, nausea, vomiting, diarrhea, gastric burning and, when given in very strong doses, even nephritis and coma [6].

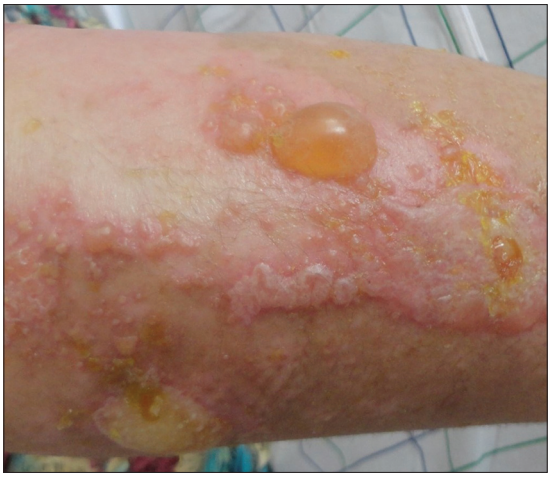

Figure 1: Image of the arm of the patient showing erythema and bullae on vitiligo patches.

How to cite this article: Alouani I, Fihmi N, Zizi N, Dikhaye S. Phytophotodermatitis following the use of Ammi Majus Linn (Bishop's weed) for vitiligo. Our Dermatol Online. 2018;9(1):93-94.

Submission: 24.06.2017; **Acceptance:** 31.08.2017

DOI: 10.7241/ourd.20181.29

Nowadays, with the easy access to information, the anarchic recourse to herbal remedies can be dangerous for our patients. The use of phytotherapy should be cautious without scientific studies proving the efficiency and the safety of the plants use.

REFERENCES

1. Benhiba H, Hamada S, Ennouhi MA, HAssam B, Ihrai H. Phytodermatoses ou brûlures chimiques: attention aux plantes dangereuses. Ann Dermatol Venereol. 2011;138:131.
2. Ossenkoppele PM, Van der Suis WG. Phototoxicdermatitis following the use of Ammi majus fruit for Vitiligo. Ned Tijdschr Geneeskd. 1991;135:478-80.
3. Dollahite JW, Younger RL, Hoffman GO. Photosensitization in cattle and sheep caused by feeding Ammi majus. Am J Vet Res. 1978;39:193-7.
4. Kavli G, Volden G. Phytophotodermatitis. Photodermatol. 1984;1:65-75.
5. Kiistala R, Mäkinen-Kiljunen S, Heikkinen K, Rinne J, Haahtela T. Occupational allergic rhinitis and contact urticaria caused by bishop's weed (Ammi majus). Allergy. 1999;54:635-9.
6. Sidi E. Bourgeois-Gavardin J. The Treatment of Vitiligo with Ammi Majus Linn: A Preliminary Note. J of Invest Dermatol. 1952;5:391-5.

Source of Support: Nil, **Conflict of Interest:** None declared.

Letter to the Editor

Calcinosis cutis mimicking xanthoma: A case report

Balachandra S Ankad[1], Arun T Miskin[2], Mahantesh K Math[3], Punit S Sakhare[1]

[1]Department of Dermatology, S N Medical College, Bagalkot, Karnataka, India, [2]Department of Pathology, S N Medical College, Bagalkot, Karnataka, India, [3]Sai Plastic Surgery Center, Bagalkot, Karnataka, India

Corresponding author: Dr. Balachandra S Ankad, E-mail: drbsankad@gmail.com

Calcinosis cutis (CC) is deposition of calcium salts in the skin. It is of four types i) dystrophic, ii) metastatic, iii) idiopathic and iv) iatrogenic [1]. Idiopathic CC is cutaneous calcification of unknown cause with normal serum calcium. Subepidermal calcified nodule and tumoral calcinosis are idiopathic forms of calcification [2].

Here authors present a case of idiopathic CC mimicking as xanthoma. A 45 year female presented with asymptomatic lesion on the right cheek for the past 8 months. There was no history of trauma or preexisting skin lesion. On examination, yellowish plaque with rough surface and irregular but well defined borders (Fig. 1). There were no similar lesions elsewhere on the body. Xanthoma and solar elastolysis were considered as differentials. Laboratory investigation revealed normal blood analysis including lipid profile. Skin biopsy was done and it was not suggestive of either xanthoma or solar elastolysis. Tissue was stained with Von Kossa for calcium salts (Fig. 2). Presence of calcium deposits was ascertained and provisional diagnosis of CC was made. Relevant investigations were carried out to know the cause of CC. Serum calcium, phosphate, and parathyroid hormone levels were normal. Based on the biochemical analysis and histopathology, idiopathic CC was made. Excision was done without recurrence (Fig. 3). Commonly, CC presents as chalky white plaque wherein diagnosis of CC is predictable [3]. Yellowish color of the lesion was misleading the scenario in this case. Hence, when asymptomatic yellowish plaque is encountered, CC should also be kept in differentials with xanthoma.

Figure 1: Yellowish plaque on the right cheek.

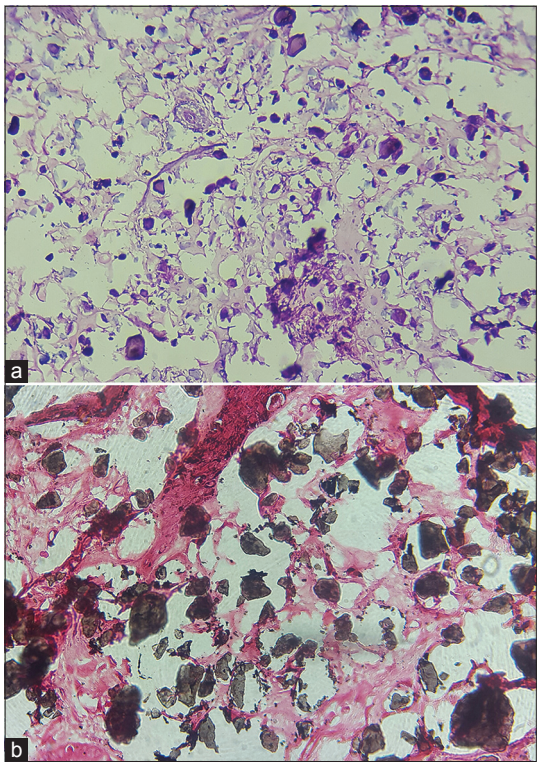

Figure 2: Calcium deposits in the dermis. (Panel 'a'10x, H & E) and calcium deposits with Von Kossa (Panel 'b' 40x).

How to cite this article: Ankad BS, Miskin AT, Math MK, Sakhare PS. Calcinosis cutis mimicking xanthoma: A case report. 2018;9(1):95-96.
Submission: 02.02.2017; **Acceptance:** 21.10.2017
DOI: 10.7241/ourd.20181.30

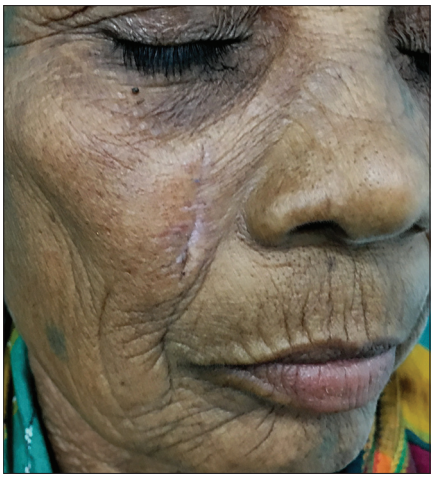

Figure 3: Post operative scar good healing.

This case is reported because of yellowish color which was mimicking xanthoma.

Consent

The examination of the patient was conducted according to the Declaration of Helsinki principles.

REFERENCES

1. Muddegowda PH, Lingegowda JB, Ramachandrarao RK, Konapur PG. Calcinosis Cutis: Report of 4 Cases. J Lab Physicians. 201;3:125-6.
2. Sardesai VR, Gharpuray MB. Calcinosis cutis. Indian J Dermatol Venereol Leprol. 2003;69:45-6.
3. Kayhan TC, Temiz P, Ermertcan AT. Calcinosis cutis on the face. Indian J Dermatol Venereol Leprol. 2009;75:180-1.

Source of Support: Nil, **Conflict of Interest:** None declared.

Letter to the Editor

Behçet's disease diagnosed by pregnancy-exacerbated genital ulcers

Nobuyuki Kikuchi, Takako Miura, Toshiyuki Yamamoto

Department of Dermatology, Fukushima Medical University, Public university in Fukushima, Japan

Corresponding author: Prof. Toshiyuki Yamamoto, E-mail: toyamade@fmu.ac.jp

Sir,

A 35-year-old female visited our hospital, complaining of painful lesions on the lower extremities. She denied prior sore throat or upper airway infection. Physical examination showed a few tender, subcutaneous nodules with redness on the surface of the bilateral lower legs (Fig. 1a). Pyrexia, joint pain and mucous lesions were not observed. Laboratory data showed an increased level of C-reactive protein (CRP) (1.57 mg/dl), but were otherwise normal. Histological examination revealed septal panniculitis showing infiltration of neutrophils and mononuclear cells in the dermis and subcutaneous tissues (Figs. 1b and c). Vasculitis was not observed. This was the first time that she had developed painful subcutaneous nodules, and she denied both frequent oral aphthae and previous history of genital ulcer. One year later, she became pregnant for the first time and visited our department complaining of genital ulcers at the week 31 of pregnancy (Fig. 2a). A biopsy specimen taken from her ulcerative labia majora showed a number of neutrophils throughout the dermis (Fig. 2b). Laboratory examination showed elevated levels of white blood cell counts (11,000/μl) and C-reactive protein (0.99 mg/dl). Serum IgD was elevated (27.5 mg/dl, normal <9.0). Liver and renal functions were normal, and anti-nuclear antibodies, anti-SS-A, and anti-SS-B antibodies were all negative. Results of the phthalmological examination were normal.

The present case initially developed erythema nodosum, and one year later, during pregnancy, she developed genital ulcers and was diagnosed with incomplete type Behçet's disease (BD). The influence of pregnancy on BD is controversial. In some cases, remissions or no significant influences have been reported [1-3], while exacerbation of BD has been reported in other cases [4-6]. In cases of worsening BD, mucocutaneous ulcerations seem to predominate during the second and third trimesters of pregnancy [3,5]. Consistent with this, our case also developed genital ulcers during the late phase of her first pregnancy.

Although pregnancy does not affect the natural development of BD in general, in an analysis of six reviews series, BD flares occurred in about 30% of the pregnancies, [3]. The main symptoms during BD flares were oral ulceration (58.3%), and genital ulceration (44.4%), followed by skin lesions (25%) and ocular inflammation (5.6%). In a case series of 44 pregnancies in patients with BD, remission was observed in more than half of the patients, whereas exacerbation was seen in 12 pregnancies (27.3%) [2]. Oral ulcers were the most frequently reported symptom that increased in intensity and severity, but other signs such as genital ulcers, eye

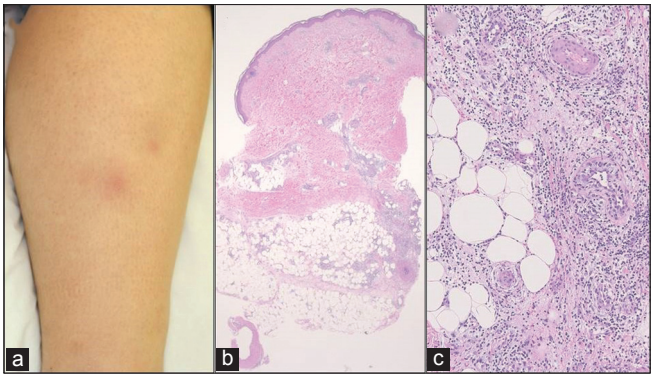

Figure 1: (a) Tender, erythematous subcutaneous nodules on the lower leg. (b) Histological features showing lobular panniculitis. (c) Higher magnification showing dense infiltration of the mononuclear cells and neutrophils.

How to cite this article: Kikuchi N, Miura T, Yamamoto T. Behçet's disease diagnosed by pregnancy-exacerbated genital ulcers. Our Dermatol Online. 2017;9(1):97-98.

Submission: 20.04.2017; **Acceptance:** 18.07.2017

DOI: 10.7241/ourd.20181.31

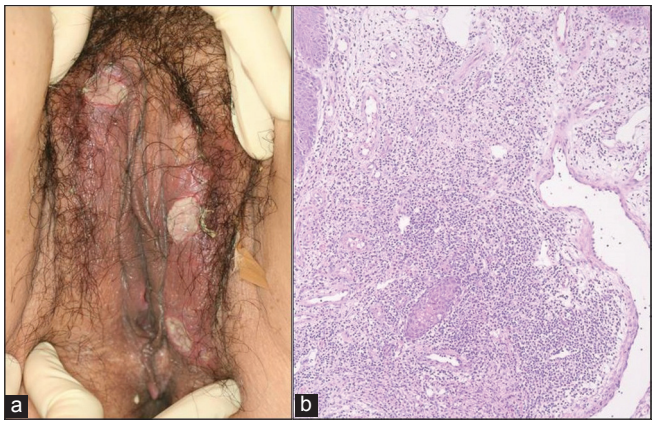

Figure 2: (a) Multiple painful ulcers on the labia majora. (b) Histological features showing numerous neutrophil infiltration throughout the dermis.

inflammation and arthritis have also been reported. In another series of 16 cases, the number of worsening BD during pregnancy was greater than remission [6]. In the same series, deep and frequent genital ulcers were most frequently observed (n=7), and one patient was diagnosed with BD during pregnancy, like our case. Similar to our case, a previous report showed a case with vaginal ulcers appearing during pregnancy, which healed immediately after delivery, suggesting the effects of progesterone withdrawal [5]. BD has been considered to show a Th1-polarized response. Many studies have suggested a predominant Th2-type immunity during pregnancy. Thus, pregnancy-induced immune conditions may inhibit a Th1-shifted imbalance [7], which may generally lead to remission in BD. On the other hand, tumor necrosis factor- α (TNF-α) increases with pregnancy development, which may contribute to the amelioration of BD. Furthermore, interleukin-10 (IL-10) production decreases in the third trimesters of pregnancy, resulting in an increase in the concentrations of inflammatory cytokines [8]. Taken together, the effects of pregnancy on the activity of BD are various, and differ depending on each individual case.

Consent

The examination of the patient was conducted according to the Declaration of Helsinki principles.

REFERENCES

1. Jadaon J, Shushan A, Ezra Y, Sela H, Ozcan C, Rojansky N. Behçet's disease and pregnancy. Acta Obstet Gynecol Scand. 2005;84:939-44.
2. Uzun S, Alpsoy E, Durdu M, Akman A. The clinical course of Behçet's disease in pregnancy: a retrospective analysis and review of the literature. J Dermatol. 2003;30:499-502.
3. Noel N, Wechsler B, Nizard J, Costedoat-Chalumeau N, Boutin du LT, Dommergues M, et al. Behçet's disease and pregnancy. Arthritis Rheum. 2013;65:2450-6.
4. Ben-Chetrit E. Behçet's syndrome and pregnancy: course of the disease and pregnancy outcome. Clin Exp Rheumatol. 2014;32:S93-8.
5. Farrag OA, Al-Sulciman SA, Bella H, Al-Omari H. Behçet's disease in pregnancy. Aust NZ J Obstet Gynecol. 1987;27:161-3.
6. Gül Ü. Pregnancy and Behçet's disease. Arch Dermatol. 2000;136:1063-4.
7. Saito S, Nakashima A, Shima T, Ito M. Th1/Th2/Th17 and regulatory T-cell paradigm in pregnancy. Am J Rep Immunol. 2010;63:601-10.
8. Moreli JB, Ruocco AMC, Vernini JM, Rudge MVC, Calderon IMP. Interleukin 10 and tumor necrosis factor-alpha in pregnancy: aspects of interest in clinical obstetrics. ISRN Obstet Gynecol. 2012;2012:230742.

Source of Support: Nil, **Conflict of Interest:** None declared.

Letter to the Editor

Systemic Lupus Erythematosus and the broken dental tool

Brittany Urso[1], Katelyn M. Updyke[1], James A. Solomon[1,2,3]

[1]University of Central Florida College of Medicine, Orlando Florida, USA, [2]University of Illinois College of Medicine, Urbana Illinois, USA, [3]Ameriderm Research, Ormond Beach Florida, USA

Corresponding author: Brittany Urso, E-mail: Brittany.Urso@knights.ucf.edu

Systemic Lupus Erythematosus (SLE) is an autoimmune condition which can be exacerbated by many factors, many of which are unknown. While flares can be controlled with medications, we often are unsure of their cause which makes disease maintenance difficult. It is possible that investigation of a patient's habits, lifestyle, and diet may provide clues which make disease maintenance, and even remission, possible.

We present a 40-year-old female with a medical history of Systemic Lupus Erythematosus (SLE) associated with contact allergies to nickel, and drug reactions to penicillin, tetracycline, clindamycin, erythromycin, and sulfa. Her first SLE episode occurred following a weekend at a tomato harvest and subsequent episodes followed upper respiratory tract symptoms treated with antibiotics. These episodes resolved spontaneously. A dentist breaking a stainless steel tool, lodging the tip within her tooth, precipitated 2 years of chronic fatigue, joint pains, butterfly rash, peripheral edema, irritable bowel, and general malaise. Her ANA titer was > 1:640 and homogeneous suggesting a drug eruption.

On physical exam, the patient had a butterfly rash and urticarial papules and plaques on her trunk and extremities in a distribution corresponding to areas in contact with metal.

Detailed history of her first SLE episodes were associated with ingesting dozens of tomatoes as well as with taking aspirin with antibiotics. To investigate her allergies, a lymphocytic activation assay was performed under laminal flow hoods, using RPMI media without bovine serum, penicillin or streptomycin. The assay revealed lymphocyte activation to 10^{-9}-10^{-18} molar to penicillin, salicylates, nickel, cobalt, chrome, and sulfonamide. Additionally, the reaction to salicylates was at 10^{-9} molar but was 10^{-18} molar to Bayer Aspirin™ tablet; (n.b.: the tablet combines salicylates with metal fillers).

Table 1: Foods containing high amounts of salicylates, the foods listed are common sources of salicylates [1]

Foods containing higher amounts of salicylates	
Aspirin	Curry powder
Tomatoes	Paprika
Berries	Thyme
Dried fruits	Garam masala
Rosemary	Tea
Licorice candy	Peppermint candy

Table 2: Common sources of nickel within food, foods cooked within stainless steel cookware, such as those listed, are sources of food containing nickel [2]

Common sources of nickel within food
Food cooked using stainless steel cookware
Flash frozen vegetables
Pasteurized milk products
Fresh, non-Kosher chicken

The patient noted significant improvement with dietary restriction of salicylate and nickel containing foods, including tomatoes, as well as avoidance of nickel containing cookware, which not only includes base metal cookware but also stainless steel (Table 1 and 2) [1,2]. Photosensitivity resolved when she avoided food sources of psoralens. Additionally, removal of the dental tool fragment and metal restorations (multiple stainless steel root canal crowns) was associated with complete remission. As result, through careful analysis of the patient's habits, lifestyle, and diet, we were able to determine and control triggers, such as salicylates,

How to cite this article: Urso B, Updyke KM, Solomon JA. Systemic Lupus Erythematosus and the broken dental tool. Our Dermatol Online. 2018;9(1):99-100.
Submission: 30.06.2017; **Acceptance:** 31.08.2017
DOI: 10.7241/ourd.20181.32

nickel, and drugs which induce photosensitivity, which precipitated her SLE flare.

REFERENCES

1. Swain AR, Dutton SP, Truswell AS. Salicylates in foods. J Am Diet Assoc. 1985;85:950-60.
2. Kamerud KL, Hobbie KA, Anderson KA. Stainless steel leaches nickel and chromium into foods during cooking. J Agric Food Chem. 2013;61:9495-501.

Source of Support: Nil, **Conflict of Interest:** None declared.

Letter to the Editor

Overlapping of Sturge Weber syndrome and Klippel Trenaunay syndrome: A new case report

Imane Alouani[1], Houssam Bkiyar[2], Siham Dikhaye[1], Brahim Housni[2], Nada Zizi[1]

[1]Department of Dermatology, Mohammed 6 University Hospital of Oujda - Medical School of Oujda, Mohammed First University of Oujda, Morocco, [2]Department of Intensive Care, Mohammed 6 University Hospital of Oujda - Medical School of Oujda, Mohammed First University of Oujda, Morocco

Corresponding author: Dr. Imane Alouani, M.Sc., E-mail: alouani01@gmail.com

Sir,

Sturge Weber syndrome (SWS) is a mesodermal phakomatosis characterized by meningo-facial angiomas with cerebral calcification. Klippel Trenaunay syndrome (KTS) is another very rare type of phakomatosis with cutaneous angiomas, varicose veins and enlargement of soft tissue or bones. Overlap between SWS and KTS is very rarely encountered. We report a case of 4-year-old girl with overlapping features of both SWS and KTS.

We report the case of a 4-year-old female patient with history of epilepsy and development delay, who presented a complex congenital neurocutaneous syndrome with symmetrical port-wine stain of the face, neck, trunk and arms (Fig. 1). There was also a hemangioma of the right thigh, knee and leg with thigh hypertrophy (Fig. 2). Computerizing tomography showed cerebral atrophy with bilateral leptomeningeal calcifications (Fig. 3).

In our case, the patient presented congenital vascular malformations with port wine hemangioma and leptomeningeal calcifications, leading to a diagnosis of SWS. Known also as Sturge-Weber-Krabbe syndrome or Sturge-Weber-Dimitri, it is neuro-oculo-cutaneous syndrome classically associated with port wine stain in the ophthalmic division of the trigeminal nerve, ipsilateral occipital leptomeningeal angiomata, and inconstant glaucoma and vascular eye abnormalities. It was first described by Sturge in 1879 in a 6-years-old child with epilepsy, facial hemangioma and glaucoma. Weber reported in 1992 cerebral calcifications in patients presenting the same symptomatology [1]. The bilateral and extensive presentation of the hemangioma and neurological involvement as in our case is unusual. It is correlated to poor prognosis. Even though the ocular involvement is a part of the definition of SWS, it is not found in 65% of cases [2].

On the other hand, the patient presented a limb hypertrophy with hemangioma, which yielded a diagnosis of another vascular syndrome: KTS. Diagnosis criteria are: extensive cutaneous vascular malformation of a limb, congenital or acquired varicosities of the same limb and tissue or bone hypertrophy of the same limb [3]. Its incidence is about 1:100.000.

During the last 30 years, there have been more than 40 sporadic case reports of association of these two syndromes suggesting an overlap syndrome with genetic

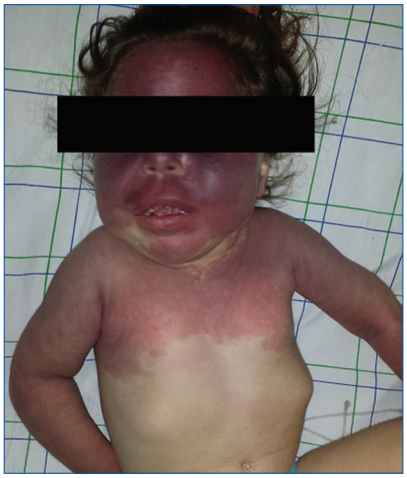

Figure 1: Extensive symmetrical port-wine stain of the face, neck, trunk and arms.

How to cite this article: Alouani I, Bkiyar H, Dikhaye S, Housni B, Zizi N. Overlapping of Sturge Weber syndrome and Klippel Trenaunay syndrome: A new case report. Our Dermatol Online. 2018;9(1):101-102.

Submission: 05.06.2017; **Acceptance:** 10.06.2017

DOI: 10.7241/ourd.20181.33

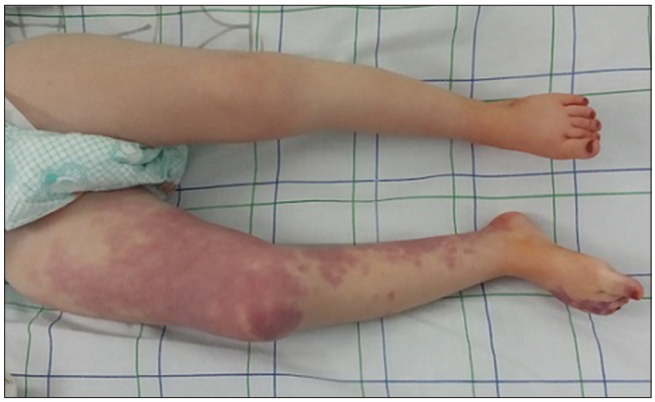

Figure 2: Hemangioma of the right thigh, knee and leg with thigh hypertrophy.

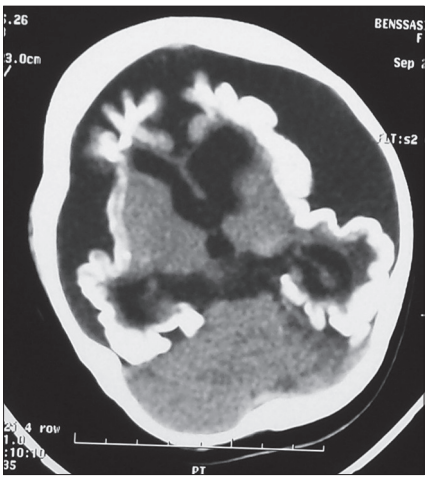

Figure 3: Computerizing tomography showing cerebral atrophy with bilateral leptomeningeal calcifications.

abnormalities. Pietruschka suggested that the SWS and KTS are different expressions of the same disease [4]. Sharma agreed with this hypothesis and suggested that the syndromes should be named neurocutaneous angioma [5].

Recently, Happle postulated a concept for the genetic basis of sporadic congenital abnormalities with capillary malformations, the "lethal gene" theory [6]. The phenomenon that one organism is composed of genetically different cell populations derived from a genetically homogeneous zygote is called mosaicism. These sporadic congenital abnormalities are not hereditary and the cutaneous lesions are distributed in a mosaic pattern usually following the lines of Blaschko [6,7].

Our observation shows again the phenotypic complexity of phakomatoses. These syndromes can result with severe neurological and vascular complications.

REFERENCES

1. Maruani A. Syndrome de Sturge-Weber. Presse Med. 2010;39:482-6.
2. Comi A. Update on Sturge-Weber syndrome: diagnosis, treatment, quantitative measures, and controversies. Lymphat Res Biol. 2007;5:257-64.
3. Verhelst H, Coster RV. Neuroradiologic findings in a young patient with characteristics of Sturge-Weber syndrome and Klippel-Trenaunay syndrome. J Child Neurol. 2005;20:911-3.
4. Pietruschka G. Zur Symptomatik der Syndrome nach Sturge-Weber and Klippel-Trenaunay. Klin Monatsbl Augenheilkd 1960;137:545–57.
5. Sharma P, Arya AV, Azad RV. Unusual retinal manifestation in a combination of Sturge-Weber and Klipplel-Trenaunay syndrome – a case report. Indian J Ophthalmol. 1990;38:195–7.
6. Happle R. Lethal genes surviving by mosaicism: a possible explanation for sporadic birth defects involving the skin. J Am Acad Dermatol. 1987;16:899-906.
7. Vissers W, Van Steensel M, Steijlen P, Renier W, Van De Kerkhof P, Van Der Vleuten C. Klippel-Trenaunay syndrome and Sturge-Weber syndrome: variations on a theme? Eur J Dermatol. 2003;13:238–41.

Source of Support: Nil, **Conflict of Interest:** None declared.

Letter to the Editor

Scleredema adultorum of Buschke in a child confirmed by special stains

Abhineetha Hosthota[1], Renu Kothottil[1], Seema Hegde Subraya[2]

[1]*Department of Dermatology, The Oxford Medical College, Hospital & Research Center, Yadavanahalli, Bangalore, India,*
[2]*Department of Pathology, The Oxford Medical College, Hospital & Research Center, Yadavanahalli, Bangalore, India*

Corresponding author: Dr. Abhineetha Hosthota, E-mail: abhineethahosthota@yahoo.com

Sir,

Scleredema adultorum of Buschke is an uncommon condition with unknown pathophysiologic characteristics. It is a misnomer as the condition can occur in childhood.Sudden onset after infection, insidious onset with paraproteinemias and those preceded by diabetes are the three types of scleredema [1].

Scleredema is characterized by diffuse shiny, symmetrical, non pitting and woody induration of skin. It usually begins on back, sides of neck and spreads to face, shoulders, arms, thorax and becomes generalized. The hands, feet and genetalia are usually spared [2]. There is no sharp demarcation between normal and abnormal skin. Wrinkling occurs when the skin is compressed between the thumb and index finger, indicating that the epidermis is spared. Disease reaches its peak in 1-2 weeks, may continue to spread for 2-3 months in some instances. History of diverse infections, from a few days to 6 weeks prior to onset is observed in 65-90% of cases [3]. Common infections are influenza, tonsillins pharyngitis, measles, mumps, scarlet fever, impetigo or cellulitis, prior streptococcal infections [3]. We report a case of scleredema confirmed by special stains in a male child.

A 6 years old boy presented with diffuse hardening of the skin on face, neck and upper trunk of 1 month duration. It was followed by 10 days after the acute febrile illness. The genitals and legs remained uninvolved. Past and family history was insignificant. Examination revealed shiny, symmetrical woody induration of the skin with no sharp line of demarcation between involved and uninvolved areas. There was lack of expression on face however, the movements of chest and abdomen were not affected. There was no clinically detectable systemic abnormality.

Haematological and urine examination was normal. Erythrocyte sedimentation rate (ESR) was raised (35 mm/h), absolute eosinophil count (AEC): 540 cells/cumm. Anti Nuclear antibody (ANA), lupus erythematosus (LE) phenomenon and anti streptolysin O (ASO) titre were negative. Chest X-ray showed streaky interstial opacities.

Histopathological examination showed no epidermal changes. Increase in the thickness of reticular dermis with separated collagen fibres were observed (Figs. 1a and b). Von Geisson stain showed swollen collagen bundles (Fig. 2a). Alcian blue (pH 2.5) stain shows deposition of mucin on the surface of collagen fibres and in the interfibrillar spaces (Fig. 2b).

Various differential diagnosis like scleredema, scleromyxedema and scleroderma were considered in our case. Histopathology of scleredema, epidermis and appendages are unaffected (Fig. 1a). There is thickening of reticular dermis with increased collagen fibres extending upto subcutaneous tissue (Fig. 1b). Where as flattening of epidermis, atrophy of pilosebaceous unit with marked proliferation of fibroblasts and increased collagen seen in upper and mid dermis in scleromyxedema. On Von Geisson stain, scleredema shows swollen collagen fibres separated from one another (Fig. 2a). In scleromyxedema collagen fibres are arranged in worled pattern. On Alcian blue staining, mucin deposition is seen on the surface of

How to cite this article: Hosthota A, Kothottil R, Subraya SH. Scleredema adultorum of Buschke in a child confirmed by special stains. Our Dermatol Online. 2018;9(1):103-104.
Submission: 24.06.2017; **Acceptance:** 29.08.2017
DOI: 10.7241/ourd.20181.34

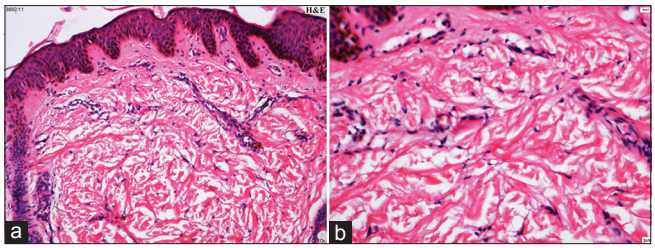

Figure 1: (a) Epidermis is normal with increased thickness of reticular dermis, (b) Increased collagen fibres in dermis.

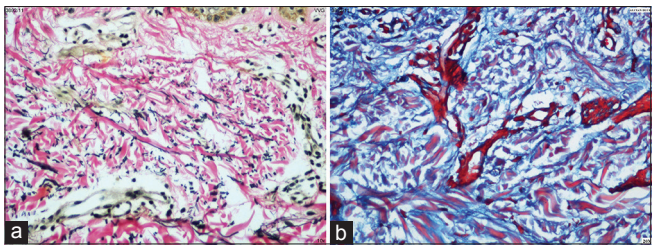

Figure 2: (a) Von Geisson stain: Swollen collagen fibres, (b) Alcian Blue: Mucin deposition in dermis.

collagen fibres in scleredema (Fig. 2b). However, in scleromyxedema deposits are seen in the upper and mid dermis [4].

In our case acute febrile illness could have triggered scleredema in a 6 years old boy. Scleredema is confirmed by clinical findings, histopathology and use of special stains for collagen and mucin.

Scleredema is a rare connective tissue disorder. It is characterized by the development of skin induration that resolves spontaneously [5]. It was originally described by Piffard in 1876. More common in children and females below the age of 20 years.

The pathogenesis of the condition is obscure, various causes have been proposed. These include immune sensitization phenomenon, hormonal stress reaction, lymphatic stasis, endocrine disturbance, enzyme dysfunction, dysautonomia [2]. Type I collagens and hyaluronate appear to be the major fibroblast products whose production is increased in scleraderma affected skin. The precise mechanisms for increased collagen and glycosaminoglycans production in sclerederma is uncommon [3].

Scleredema is a self limiting condition that resolves within 6 months to 2 years [3]. There is no effective treatment. Low dose oral steroids, intralesional corticosteroids, amoxicillin 750 mg and clavulinic acid 75 mg for 3 months with beneficial results [6]. Ciclosporin, electron beam therapy, PUVA using poralen cream, UVA1, extracorporel photopheresis and low dose methotrexate are more recent suggestions [7]. Since it is a self resolving condition, our patient was treated symptomatically and significant improvement is noted.

Histopathology and special stains are helpful for diagnosis of scleredema. This case is been reported because of the paucity of documented cases in Indian literature and establishes the significance of histopathology and special stains in the diagnosis of scleredema.

REFERENCES

1. Mittal RR, Gill SS, Arun S. Nodular amyloidosis associated with scleredema of Buschke. Ind J Dermatol Venereol Leprol. 1992;58:285-6.
2. Basavaraj KH, Prakash BG. Scleredema of Buschke. Ind J Dermatol. 1996;41:102-3.
3. Gupta V, Kumar M, Tripati AM. Ind J Dermatol Venereol Leprol. 1995;61:185-6.
4. Cole HG, Winkelmann RK. Acid mucopolysaccharide staining in scleredema. J Cutan Pathol. 1990;17:211-3.
5. Singhal A, Ghandhi V, Bhattacharya SN. Scleredema adultorum of buschke associated with non-scarring alopecia of scalp. Ind J Dermatol Venereol Leprol. 1999;65:38-9.
6. Sayal SK, Sanghi S. Scleredema. Ind J Dermatol. 2003;48:184.
7. Anneli RB, Smith L, Zone JJ. Scleredema adultorum of buschke Treated With Radiation. Arch Dermatol. 2003;139:780-4.

Source of Support: Nil, **Conflict of Interest:** None declared.

Letter to the Editor

Lipomembranous changes (membrano-cystic lesions) in the extremities of a patient with systemic sclerosis

Natsuko Matsumura, Toshiyuki Yamamoto

Department of Dermatology, Fukushima Medical University, Fukushima, Japan

Corresponding author: Prof. Toshiyuki Yamamoto, E-mail: toyamade@fmu.ac.jp

Sir,

We herein describe a case of nodular cystic fat necrosis (NCFN) that occurred in the forearm of a patient with systemic sclerosis (SSc). Of interest, lipomembranous changes were also observed in the biopsy specimens taken from the forearm and the finger.

An 83-year-old woman was referred to our department on suspicion of SSc, during admission in the respiratory medicine department. She had had surgery one year previously for breast cancer. Physical examination showed mildly swollen fingers with nail fold bleeding (Fig. 1a). Further examination revealed a solitary bony-hard, mobile subcutaneous nodule, sized 10-mm in diameter located on the edematous forearm (Fig. 1b). A biopsy specimen from the finger showed thickened collagen bundles in the dermis (Fig. 2a), and lipomembranous changes in the subcutaneous tissues (Fig. 2b). Another biopsy from the forearm showed edematous dermis with slightly thickened collagen bundles in the lower dermis, with lipomembranous changes in the subcutis (Figs. 2c and 2d). The nodule of the forearm was simultaneously removed, which histologically revealed a well-circumscribed tumor composed of degenerated fat cells with lipomembranous lesions surrounded by a thin fibrous capsule (Figs. 2e and 2f). Laboratory data showed normal liver and renal function and an increased level of KL-6 (3581 U/ml; normal <500). Antinuclear

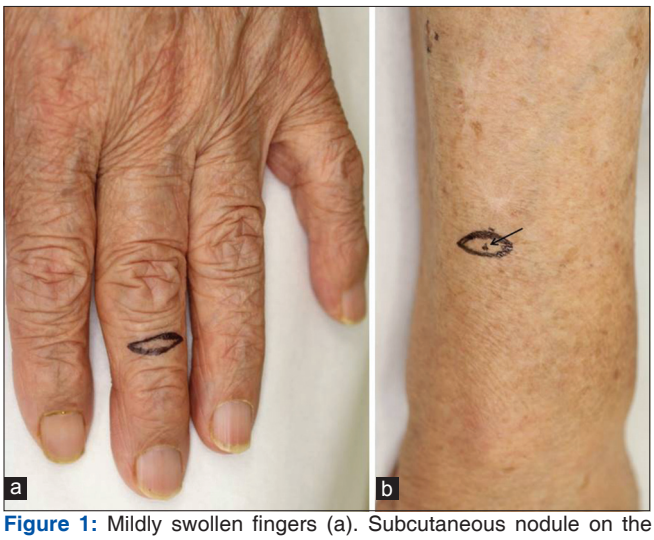

Figure 1: Mildly swollen fingers (a). Subcutaneous nodule on the forearm (arrow) (b).

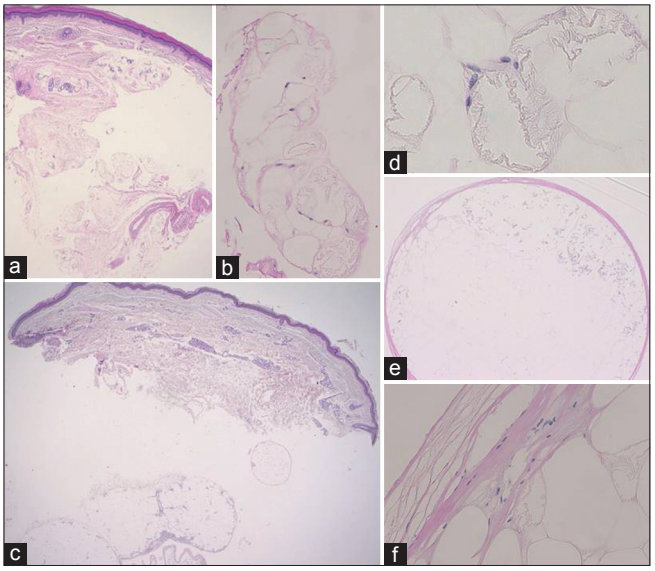

Figure 2: Histology of the biopsy specimen from the finger (a), with lipomembranous changes in the subcutaneous tissues (b). Another biopsy from the forearm showed slightly thickened collagen bundles in the lower dermis (c), with lipomembranous changes in the subcutis (d). A nodule on the forearm was a well-circumscribed tumor (e), showing lipomembranous changes within the nodule (f).

How to cite this article: Matsumura N, Yamamoto T. Lipomembranous changes (membrano-cystic lesions) in the extremities of a patient with systemic sclerosis. 2018;9(1):105-106.

Submission: 05.06.2017; **Acceptance:** 02.07.2017

DOI: 10.7241/ourd.20181.35

antibodies (1:80), and anti-centromere antibodies (17 U/ml; normal <10) were detected in the serum, whereas antibodies against Scl-70, U1RNP, SS-A, SS-B, DNA, ds-DNA, Sm, PR3-ANCA, and MPO-ANCA were all negative or within normal limits. Lung computed tomography showed interstitial fibrosis. Also, she had reflux esophagitis.

NCFN most commonly occurs on the lower extremities. Histology shows multiple, non-viable adipocytes surrounded by condensed fibrous tissues, along with lipomembranous changes [1,2]. Lipomembranous changes are sometimes associated with vascular diseases or connective tissue diseases due to the interruption of the blood supply in the subcutaneous tissues [3]. Snow et al. reported three cases of morphea in their series, which presented with lipomembranous changes on the morpheaform plaques of the back, legs, and calf [4]. To date, only a few cases of SSc similar to ours were reported [5,6]. In one case, mobile nodules appeared on the forearm, and histological examination revealed NCFN [5]. Furthermore, lipomembranous changes were observed in the biopsy specimens taken from the forearm. In another case, a biopsy from the abdominal hard hyperchromic plaque with coalescent and painful nodules revealed lipomembranous panniculitis [6]. In the present case, lipomembranous changes were observed in the specimens from both forearm and finger unrelated with the lesion of NCFN. Therefore, it is suggested that lipomembranous changes are associated with SSc-related conditions. SSc skin shows pronounced vascular changes in the subcutis, such as a paucity of blood vessels, thickening and hyalinization of the vessel walls, and narrowing of the lumen. Such changes may be predisposed for the induction of lipomembranous changes due to ischemia. However, reports of similar cases are few, and therefore, other factors may be associated with the induction of lipomembranous changes. Alternatively, those features involved in the subcutis may have been underestimated in SSc.

Consent

The examination of the patient was conducted according to the Declaration of Helsinki Principles.

Written informed consent was obtained from the patient for publication of this article.

REFERENCES

1 Ahn SK, Lee BJ, Lee SH, Lee WS. Nodular cystic fat necrosis in a patient with erythema nodosum. Clin Exp Dermatol. 1995;20:263-5.

2 Pujol RM, Wang CY, Gibson LE, Su WP. Lipomembranous changes in nodular-cystic fat necrosis. J Cutan Pathol. 1995;22:551-5.

3 Snow JL, Su WP. Lipomembranous (membranocystic) fat necrosis: clinicopathologic correlation of 38 cases. Am J Dermatopathol. 1996;18:151-5.

4 Snow JL, Su WP, Gibson LE. Lipomembranous (membranocystic) changes associated with morphea: a clinicopathologic review of three cases. J Am Acad Dermatol. 1994;31:246-50.

5 Toritsugi M, Yamamoto T, Nishioka K. Nodular cystic fat necrosis with systemic sclerosis. Eur J Dermatol. 2004;14:353-5.

6 Almeida MS, Lima SC, Carvalho LL, Almeida JV, Santos LG, Rolim JR, et al. Panniculitis: an unusual cutaneous manifestation of systemic sclerosis. J Cutan Pathol. 2010;37:1170-3.

Source of Support: Nil, **Conflict of Interest:** None declared.

Comment: Lipomembranous changes (membrano-cystic lesions) in the extremities of a patient with systemic sclerosis

by **Natsuko Matsumura, Toshiyuki Yamamoto**

author: Dr. Daisuke Tsuruta PhD, E-mail: dts211@gmail.com

Department of Dermatology, Kurume University School of Medicine, and Kurume University Institute of Cutaneous Cell Biology, Kurume, Fukuoka, Japan

The paper described a possibly rare manifestation of systemic sclerosis (SSc). First of all, skin biopsy for SSc is often problematic and challenging, because of the fear of failure in wound closure. This is known to be caused by vasculature paucity. So, especially for internists, they hesitate to do biopsy. Lipomembranaous changes (LMC) are rarely reported in SSc. LMC are also reported in morphea. Both SSc and morphea mimic each other for skin manifestations, but they are known to be different from the pathomechanical point of view. So, although the pathomechanism of LMC is still unknown, I speculate that LMC may be come from fibrosis commonly found in both SSc and morphea. Further accumulation of cases will elucidate the true pathomechanism of LMC.

How to cite this article: Tsuruta D. Comment: Lipomembranous changes (membrano-cystic lesions) in the extremities of a patient with systemic sclerosis. 2018;9(1):107-107.

Submission: 05.06.2017; **Acceptance:** 10.06.2017

Historical Article

Eponyms in dermatology literature linked to fibromatoses

Ahmad Khalid Al Aboud

King Saud bin Abdulaziz University For Health Sciences, Jeddah, Saudi-Arabia

Corresponding author: Dr. Ahmad Khalid Al Aboud, E-mail: amoa65@hotmail.com

ABSTRACT

Fibromatoses comprise a broad group of benign fibroblastic proliferations of similar microscopic appearance .These conditions might be seen in the dermatology practice. Some of the fibromatoses conditions are best known eponymously. The aim in this short communication is to shed some lights on the eponyms in dermatology literature linked to fibromatoses.

Key words: Dermatology; Diseases; Fibromatoses; Eponyms

Fibromatoses comprise a broad group of benign fibroblastic proliferations of similar microscopic appearance whose biologic behavior is intermediate between that of benign fibroblastic lesions and fibrosarcoma [1].

The fibromatoses can be divided into two major groups with several subdivisions. These 2 groups are; superficial (fascial) fibromatoses and deep (musculoaponeurotic) fibromatoses. The biologic behavior is more aggressive in the latter group [1].

Some conditions of fibromatoses not usually seen by dermatologists like retroperitoneal fibrosis, a disease characterized by sclerotic tissue in the periaortic or periiliac retroperitoneum that encases adjacent structures. The most common symptoms of the disorder include abdominal or flank pain, weight loss, fatigue, and urinary frequency.

But, it may present with kidney failure, hypertension, deep vein thrombosis, and other obstructive symptoms. It is, also named Ormond's disease, after John Kelso

Table 1: Selected eponymous conditions in dermatology literature linked to fibromatoses

Eponymous conditions in dermatology literature linked to fibromatoses	Remarks
Dupuytren's disease [1,3-5]	Also known as palmar fibromatosis or Dupuytren's contracture. It is the most common type of fibromatosis. Although it is named for Baron Guillaime Dupuytren, who operated on the condition in 1831, there are much earlier descriptions of this lesion. Baron Guillaume Dupuytren (1777-1835), [Fig. 2], was a French anatomist and military surgeon. He gained much esteem for treating Napoleon Bonaparte's hemorrhoids. He was the richest doctor of the France. Dupuytren dies in age of 58 due to the pleural empyema, but he refused surgery. Before that he had brain stroke, from which he never recover, although he continue with lectures.
Ledderhose's disease [1,6,7]	Also known as Plantar fibromatosis or Morbus Ledderhose. It is a fibrous proliferation arising within the plantar fascia end exhibits typical clinical nodular features. Although Dupuytren recognized that a process similar to that occurring with palmar aponeurosis could involve plantar aponeurosis, it was Madelung who reported the first isolated case of plantar fi bromatosis in 1875.The condition was described in more detail, later, by Ledderhose in 1897. Georg Ledderhose (1855-1925), [Fig. 3], was a German surgeon.
Peyronie's disease [8]	Known as chronic inflammation of the tunica albuginea (CITA), it is a connective tissue disorder involving the growth of fibrous plaques in the soft tissue of the penis, causing erectile dysfunction. It is named after François Gigot de La Peyronie (1678-1747) (Fig. 4), the first surgeon to Louis XV.

How to cite this article: Al Aboud AK. Eponyms in dermatology literature linked to fibromatoses. Our Dermatol Online. 2018;9(1):108-109.
Submission: 30.09.2017; **Acceptance:** 25.11.2017
DOI: 10.7241/ourd.20181.37

Figure 1: John Kelso Ormond (1886-1978).

Figure 3: Georg Ledderhose (1855-1925).

Figure 2: Baron Guillaume Dupuytren (1777-1835).

Figure 4: François Gigot de La Peyronie (1678-1747).

Ormond (1886-1978), (Fig. 1), an American urologist who rediscovered the condition in 1948 [2].

It is not uncommon to encounter cases of fibromatoses, in dermatology practice. Some of the fibromatoses conditions are best known eponymously.

The aim in this short communication is to shed some lights on the eponyms in dermatology literature linked to fibromatoses.

In table 1 We listed selected eponymous conditions in dermatology literature linked to fibromatoses.

REFERENCES

1. Weiss SW, Goldblum JR. Fibromatoses. In: Enzinger and Weiss's soft tissue tumors. 5th ed. St Louis: Mosby; 2008. p. 237–56.
2. Khosroshahi A, Carruthers MN, Stone JH, Shinagare S, Sainani N, Hasserjian RP, et al. Rethinking Ormond's disease: "idiopathic" retroperitoneal fibrosis in the era of IgG4-related disease. Medicine (Baltimore). 2013;92:82-91.
3. Glicenstein J. [Dupuytren's disease – the story of an eponym]. Chir Main. 2012;31:107-12.
4. Bumbasirević MZ, Palibrk T, Lesić AR, Durasić LM. [Baron Gijom Dipitren, Guillaume Dupuytren (1777-1835)]. Acta Chir Iugosl. 2011;58:15-9.
5. Alzahrani FD, Khogair H, Al Aboud K, Althebyani A, Althebyani A. Eponyms in dermatology literature linked to general surgery. SMU Med J. 2017;4:30-6.
6. Omor Y, Dhaene B, Grijseels S, Alard S. Ledderhose Disease: Clinical, Radiological (Ultrasound and MRI), and Anatomopathological Findings. Case Rep Orthop. 2015;2015:741461.
7. Veith NT, Tschernig T, Histing T, Madry H. Plantar fibromatosis-topical review. Foot Ankle Int. 2013;34:1742-6.
8. Al Aboud K , Al Aboud D, Munshi S, Halawi AA. Eponyms in andrology. Basic Clin Androl. 2014;24:7.

Source of Support: Nil, **Conflict of Interest:** None declared.



Our Dermatology Online

www.odermatol.com

1.2018 (09.January.2018)