Volume 7, Number 4, October 2016
p. 377 - 495
Issue online since Monday October 10, 2016

ISSN: 2081-9390
DOI: 10.7241/ourd

Our Dermatology Online

www.odermatol.com

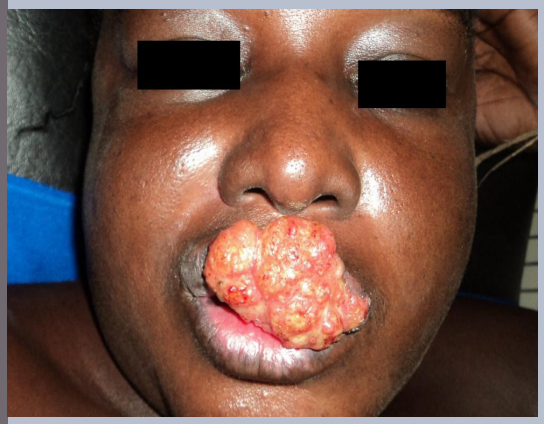

- Patricia Chang, Kathia Domínguez
Onicopatias en ancianos. Reporte de 71 casos

- Rana Rafiei, Hojat Eftekhari, Arash Daryakar, Nahid Nickhah, Behnam Rafiee
Eccrine porocarcinoma: a case report and brief review of the literature

- Muriel Sidnoma Ouédraogo, Nina Korsaga/Somé, Aimé Sosthène Ouédraogo, Nomtondo Amina Ouédraogo, Gilbert Patrice Tapsoba, Tarcissus Konsem, Jean-Baptiste Andonaba, Jean Sakandé, Pascal Niamba, Adama Traoré
Epidermoid carcinoma involving on chronic ulcer of the upper lip in a patient infected with HIV

- Alexandra K. Alexandrova, Vera A. Smolyannikova, Varvara A. Filatova, Olga K. Alexandrova
Protein p16 role in seborrheic keratosis

Editorial Pages

e-ISSN: 2081-9390
DOI: 10.7241/ourd

Quarterly
Our Dermatol Online

published since 01/06/2010 years

www.odermatol.com

Editor in Chief:
Piotr Brzeziński, MD Ph.D

Address:
ul. Braille'a 50B, 76200 Słupsk, Poland
tel. 48 692121516, fax. 48 598151829
e-mail: **brzezoo77@yahoo.com**

Publisher:
Our Dermatology Online

Address:
ul. Braille'a 50B, 76200 Słupsk, Poland
tel. 48 692121516, fax. 48 598151829
e-mail: **brzezoo77@yahoo.com**

Associate Editor:
Ass. Prof. Viktoryia Kazlouskaya (USA)

Indexed in:

Universal Impact Factor for year 2012 is = 0.7319
system of opinion of scientific periodicals INDEX COPERNICUS (8,69)
(Academic Search) EBSCO
(Academic Search Premier) EBSCO
MNiSW (kbn)-Ministerstwo Nauki i Szkolnictwa Wyższego (7.00)
DOAJ (Directory of Open Acces Journals)
Geneva Foundation for Medical Education and Research (GFMER), Google Scholar, Open J-Gate, NewJour,
International Committee of Medical Journal Editors (ICMJE), Genamics JournalSeek, Hinari,
Bielefeld Academic Search Engine (BASE), WorldCat, e -journal, WorldWideScience.org, National Science Library,
LibSearch, Sciencegate, Virtual Science Library (VSL), Wanfang Data, COnnecting REpositories (CORE),
CAB Abstracts, Global Health, Journal Indexed in Directory of Research Journals Indexing,
OAIster: The Open Access Initiative, OAJSE - Open Access Journals Search Engine, Scirus

Previous website:	issue 1.2010	www.ndermatol.like.pl
	since issue 2.2010 to issue 3.2011	www.odermatol.like.pl
	since issue 4.2011	www.odermatol.com
Previous shortcut:	since issue 1.2010 to issue 3.2011	N Dermatol Online
	since issue 4.2011	Our Dermatol Online

Open access journal:

This is an open access journal which means that all content is freely available without charge to the user or his/her institution. Users are allowed to read, download, copy, distribute, print, search, or link to the fullor texts of the articles in this journal without asking prior permission from the publisher or the author.

Our Dermatology Online is a international journal that publishes original contributions in the field of dermatology, including papers on biochemistry, morphology and immunology of the skin.

The journal is among the few not related to dermatological associations or belonging to respective societies which guarantees complete independence. Offers a platform for review articles in areas of interest for dermatologists.

OurDermatologyOnline offers article in English as well as in other languages. This is in accordance with the BOAI definition of open access.

Editorial Board

Abdel-Naser, Mohamed Badawy, Prof. (Egypt)
Abdul-Lateef Mousa Haider, MD (Iraq)
Al Aboud Khalid, MD (Saudi Arabia)
Al-Kamel Mohamed A., MD (Yemen)
Al-Mashaleh Manal Sulaiman, MD (Jordan)
Abreu-Velez Ana Maria, Prof. (USA)
Abreu Hilda, MD (Urugway)
Adaskevich Uladzimir, Prof. (Belarus)
Afifi Mustafa, MD (United Arab Emirates)
Aghaei Shahin, Ass. Prof. (Iran)
Akpaka Patrick Eberechi, Prof. (Trinidad and Tobago)
Akyshbayeva Kulbarshin, Prof. (Kazakhstan)
Amichai Boaz, MD (Israel)
Arakelyan Hayk S. Prof. (Armenia)
Arenas Roberto, Prof. (Mexico)
Arif Tasleem, MD (India)
Asuquo Maurice Efana, Prof. (Nigeria)
Auto James, Ass. Prof. (Solomon Islands)
Fatou Barro-Traoré, Prof. (Burkina Faso)
Christian Muteba Baseke, MD (Democratic Republic of the Congo)
Bharti Rakesh, MD (India)
Bonifaz Alexandro, Prof. (Mexico)
Borowska Katarzyna, Ass. Prof. (Poland)
Borruto Franco, Prof. (Monaco)
Bouadjar Bakar, Prof. (Algeria)
Bukhari Iqbal A., Prof. (Saudi Arabia)
Cabo Horacio, Prof. (Argentina)
Chamcheu Jean Christopher, Ph.D (USA)
Chang Patricia, MD Ph.D (Guatemala)
Chihanga Simon, MD (Botswana)
Choon Siew Eng, MD (Malaysia)
Chuh An Tung Antonio, Prof. (Hong Kong)
Crump Vincent, MD (New Zealand)
Daboul Mohamed Wael, MD (Syria)
Daisley Hubert, Prof. (Trinidad and Tobago)
Darlenski Razvigor, MD Ph.D (Bulgaria)
Diouf Assane, Ass. Prof. (Senegal)
Dobrev Hristo, Prof. (Bulgaria)
Doganay Mehmet, Prof. (Turkey)
Dong Huiting, Prof. (China)
Dori Geme Urge, PhD (Ethiopia)
Draganita Ana Maria, MD PhD (Romania)
Drljević Irdina, MD, Ph.D. Ass. Prof. (Bosnia and Herzegovina)
Dubakienė Rūta, Prof. (Lithuania)
Edwards Carl, Ass. Prof. (USA)
Elhassan Elizabeth, MD (Senegal)
Farkas Arpad, MD PhD (Hungary)
Fernandez-Flores Angel, MD Ph.D (Spain)
Fortuna Giulio, Ass. Prof. (USA)
Gołąb Elżbieta, Prof. (Poland)
Gómez Cuevas Alina, Prof. MD (Nicaragua)
Grattan Clive (United Kingdom)
Grivcheva-Panovska Vesna, Prof. (Macedonia)
Guzmán Antonio, MD (Paraguay)
Hashimoto Takashi, Prof. (Japan)
Hassan Iffat, Prof. (India)
Hegyi Vladimir, Prof. (Slovakia)
Hidalgo-Matlock Benjamin, MD (Costa Rica)
Hysi Katerina, MD (Albania)
Janjua Shahbaz, MD (Pakistan)
Jeseňák Miloš, Ass. Prof. (Slovakia)
Jeewon Rajesh, Ph.D. (Mauritius)
Jordán Rodriguez Ramiro, Prof. (Bolivia)
Julian Rolando, Prof. (El Salvador)
Kaszuba Andrzej, Prof. (Poland)
Kaštelan Marija, Prof. (Croatia)
Katsambas Andreas, Prof. (Greece)
Khawaja Shakeel Ahmed, PhD (Eritrea)
Kibbi Abdul-Ghani, Prof. (Lebanon)
Kossi Metowogo, Ph.D (Togo)
Kuiate Jules-Roger, Prof. (Cameroon)
Lan Cheng-Che E., Ass. Prof. (Taiwan)
Lopez-Granja Jorge, MD (Belize)
Lotti Torello, Prof. (Italy)
Mahassadi Alassan Kouamé, Ass. Prof. (Côte d'Ivoire')
Mahdi Juma Husain Ali, MD (Bahrain)
Maibach Howard I., Prof (USA)
Maio Paula, MD (Portugal)
Mekokishvili Lali, Prof. (Georgia)
Mikkelsen Carsten Sauer, MD (Denmark)
Mourad Mokni, Prof. (Tunisia)
Mota Luiz Alberto Alves, Prof. (Brazil)
Mrisho Fatma, MD (Tanzania)
Muvunyi Claude Mambo, MD (Rwanda)
Ndugwa Christopher, Prof. (Uganda)
Nedelciuc Boris, Ass. Prof. (Moldova)
Nhlengethwa Winnie, Prof. (Swaziland)
Nigam Pramod Kumar, Prof. (India)
Nikolic Milos, Prof. (Serbia)
Nowicki Roman, Prof. (Poland)
Nwabudike Lawrence Chukwudi, MD Ph.D (Romania)
Odeh Samuel, Prof. (Gabon)
Olszański Romuald, Prof. (Poland)
Oranje Arnold, Prof. (Netherlands)
Parajuli Sudip, MD (Nepal)
Parvin Rukhsana, MD (Bangladesh)
du Plessis Jeanetta, Prof. (South Africa)
Puri Neerja, MD (India)
Pusahai-Riman Paula, BSc, MS (Papua New Guinea)
Qurashi Mohd, MD (Sudan)
Riedl Elisabeth, Ass. Prof. (Austria)

Editorial Board

Ríos Yuil José Manuel, Prof. (Panama)
Ranotsi Amelia, PhD (Lesotho)
Rubio-Texeira Marta Ph.D. (Belgium)
Rusnak Martin, Prof. (Slovakia)
Sayad Ibrahim, Prof. (Kuwait)
Sharquie Khalifa E., Prof. (Iraq)
Shawa Mary, MD (Malawi)
Shkilna Mariia, MD Ph.D (Ukraine)
Sinclair Rodney Daniel, Prof. (Australia)
Singh Harjeet, MD (Qatar)
Slavic Vjerolsva, MD PhD (Montenegro)
Srinivasan Sundaramoorthy, Prof. (India)
Sumathipala Gayan Saranga, MD (Sri Lanka)
Tapia Felix J., Ass. Prof. (Venezuela)
Tatu Alin, MD (Romania)
Beigi Pooya Khan Mohammad, Prof. (Canada)
Teixeira Roni Leonardo, MD (Brazil)
Tincopa-Wong Oscar Wilfredo, MD (Peru)
Tresh Amani, MD (Libya)
Tylewska-Wierzbanowska Stanisława, Prof. (Poland)
Uraga Pazmiño Enrique, MD (Ecuador)
Usha Rani Anaparthy, Prof. (India)
Valdebran Manuel, MD (Dominican Republic)
Vok Marko, MD (Slovenia)
Win Oo Soe, MD (Myanmar)
Wollina Uwe, Prof. (Germany)
Wortsman Ximena, Ass. Prof. (Chile)
Yamamoto Toshiyuki, Prof. (Japan)
Yuil de Ríos Emma, MD (Panama)
Zabielski Stanisław, Prof. (Poland)
Zawar Vijay, Prof (India)

Contents

Brief Reports

Protein p16 role in seborrheic keratosis 377
Alexandra K. Alexandrova, Vera A. Smolyannikova, Varvara A. Filatova, Olga K. Alexandrova

Stevens–Johnson syndrome and toxic epidermal necrolysis in an academic hospital setting: a 5-year retrospective study 381
Ewa Stocka-Łabno, Natalia Gabzdyl, Magdalena Misiak-Galazka, Małgorzata Pawłowska-Kisiel, Tomasz Łazowski, Lidia Rudnicka

Onicopatias en ancianos. Reporte de 71 casos [Nail diseases in elderly. Report of 71 cases] 385
Patricia Chang, Kathia Domínguez

Case Reports

Eccrine porocarcinoma: a case report and brief review of the literature 391
Rana Rafiei, Hojat Eftekhari, Arash Daryakar, Nahid Nickhah, Behnam Rafiee

Giant solitary trichoepithelioma with desmoplasia on histopathology: An unusual finding 394
Sundeep Chowdhry, Shikha Gupta, Anand K. Verma, Jagbir Singh, Paschal D'souza, Manish S. Jain

Solitary eccrine syringofibroadenoma: a case report showing papillary tubular adenoma-like features 397
Toshiyuki Yamamoto, Keiko Miura, Hiroo Yokozeki

Eccrine hidradenoma of the breast: distinct pathological lesion mimicking a carcinoma 400
Olfa El Amine El Hadj, Marwa Mhiri, Aida Goucha, Jameleddine Ben Hassouna, Olfa Adouni, Khaled Rahal, Ahmed El May, Amor Gamoudi

Bazex-syndrome with esophageal cancer 403
Sebastian Boldt, Uwe Wollina

Cutis verticis gyrata secondary to cerebriform intradermal nevus 406
Olcay Er, Seray Külcü Çakmak, Serra Kayaçetin, Emine Tamer, Ferda Artüz

Granular cell tumour: An uncommon tumour of Schwann cell origin 409
Anup Kumar Tiwary, Yashwant Anant Lal, Dharmendra Kumar Mishra

Multiple eruptive dermatofibromas occuring in a patient under hemodialysis 412
Sarra Ben Rejeb, Amen Dhaoui, Dorra Ben Ghachem, Asmahane Souissi, Khadija Bellil

Cutaneous metastasis heralding invasive ductal carcinoma of the breast in a 33 year old patient 415
Crystal R. Lenz, Kirk A. Middleton

Keratoacanthoma of the nose coexisted with xeroderma pigmentosum in a Yemeni child: A rare case 419
Mohamed Ahmed Al-Kamel

Basal cell carcinoma of the skin with clear cell differentation: A report of two cases 422
Vladimír Bartoš, Tatiana Bulejčíková

Pigmented basal cell carcinoma: A rare clinical variant treated with excision and grafting 427
Manjunatha Puttaiah, Deekshith Rajmohan, Shishira R. Jartarkar

Carcinome épidermoïde sur ulcère chronique de la lèvre supérieure chez une patiente infectée par le VIH [Epidermoid carcinoma involving on chronic ulcer of the upper lip in a patient infected with HIV] 431
Muriel Sidnoma Ouédraogo, Nina Korsaga/Somé, Aimé Sosthène Ouédraogo, Nomtondo Amina Ouédraogo, Gilbert Patrice Tapsoba, Tarcissus Konsem, Jean-Baptiste Andonaba, Jean Sakandé, Pascal Niamba, Adama Traoré

Aggressive angiomyxoma of the vulva - A rare entity 436
Archana Shivamurthy, Padmapriya Jaiprakash, Lavanya Paramasivam

Contents

A case of multiple lipomas coexisting with angiolipomas: Familial multiple lipomatosis or a distinct entity? 439
Funda Tamer, Mehmet Eren Yuksel

Palisaded encapsulated neuroma: an uncommon tumour at uncommon location 442
Anup Kumar Tiwary, Shyam Sundar Chaudhary, Dharmendra Kumar Mishra

Lupus and pulmonary nodules consistent with bronchiolitis obliterans organizing pneumonia induced by carbamazepine in a man 445
Awatef Kelati, Salim Gallouj, Mariame Meziane, Fatima Zahra Mernissi

Miliaria pustulosa misdiagnosed as a case of acne vulgaris 448
Iqbal Bukhari, Aala Alayoubi, Muhannad Alzahrani

Cutaneous actinomycosis. A case report 451
Tomasz Wasyłyszyn, Katarzyna Borowska

Aïnhum: aspects cliniques, radiographiques et thérapeutiques à propos de 3 cas [Ainhum: clinical, radiographic and therapeutic aspects, about 3 cases] 453
Amina Nomtondo Ouédraogo, Patrick Wendpouiré Hamed Dakouré, Maodo Ndiaye, Seraphine Zeba/Lompo, Fagnima Traoré, Sayouba Tinto, Sidnoma Muriel Ouédraogo, Patrice Gilbert Tapsoba, Pascal Niamba, Fatou Barro-Traoré, Adama Traoré

Maladie de Kawasaki: Premier cas togolais chez un enfant de 3 ans [Kawasaki Disease: First observation in a Togolese child 3 years old] 459
Koussake Kombaté, Julienne Noudé Teclessou, Bayaki Saka, Nadiédjoa Kokou Douti, Abla Séfako Akakpo, Abas Mouhari-Touré, Garba Mahamadou, Palokinam Pitche

Review Article

Una pequeña puesta al día sobre la tricotilomanía [A brief update on trichotillomania] 465
Julio Torales, Beatriz Di Martino Ortiz

Clinical Image

Cutaneous myasis in trophic leg ulcers 472
Patricia Chang, Gustavo Adolfo Oliva Vega, Edlin Mayté Lizama Auyón

Historical Images

Hibernoma of cervical region 475
Chidambharam Choccalingam

Folliculosebaceous cystic hamartoma 477
Leila Bouhaja, Meriam Jones, Soumaya Rammeh

Letters to the Editor - An Observation

An interesting case of neurofibroma of face 479
Sreekar Harinatha, Arjun Cukkemane, Vickey Katheria

Molusco contagioso y SIDA [AIDS and molluscum contagiosum] 482
Patricia Chang, Edlin Mayté Lizama Auyón

Letters to the Editor

Neurothekoma of the scalp 485
Olfa El Amine El Hadj, Leila Bouhajja, Aida Goucha, Jameleddine Ben Hassouna, Wafa Rekik, Ahmed El May, Amor Gamoudi

Calcifying fibrous tumor of axillary region 487
Olfa El Amine El Hadj, Leila Bouhajja, Aida Goucha, Jameleddine Ben Hassouna, Ahmed El May, Amor Gamoudi

Contents

A rare clinic type of angiokeratoma: angiokeratoma circumscriptum naeviforme 489
Esra Arı, Seray Külcü Çakmak, Ayşe Yılmaz Çiftçi, Emine Tamer, Ferda Artüz

An epidermal cyst mimicking a breast tumor in a male patient: A case report 492
Mehmet Eren Yuksel, Funda Tamer

Herpes zoster in patients with systemic lupus erythematosus 494
Maria Bibiana Leroux

Brief Report

Protein p16 role in seborrheic keratosis

Alexandra K. Alexandrova[1], Vera A. Smolyannikova[1], Varvara A. Filatova[1], Olga K. Alexandrova[2]

[1]Department of Pathological Anatomy, Russian Ministry of Health I.M. Sechenov First Moscow State Medical University, Moscow, Russia, [2]Department of Infectious Diseases and Epidemiology, Kuban State Medical University, 350063, Sedin street 4, Krasnodar, Russia

Corresponding author: Dr. Alexandra K. Alexandrova, E-mail: veter278@rambler.ru

ABSTRACT

Introduction: Seborrheic keratosis (SK) is a disease of unknown etiology and pathogenesis. Keratomas grow slowly for years. Their number grows significantly with age in some patients, resulting in cosmetic defect, while separate elements remain in others not disturbing them subjectively. Details of the cell cycle destruction by the SK are not revealed despite a number of studies. It is controversial whether tumor suppressor protein p16 influences growth and development of the tumor elements. **Materials and Methods:** An immunohistochemistry test with monoclonal antibodies to p16 was accomplished, 20 SK served as a material for the test, which were obtained from patients with multiple SK - 10 people, and single SK (not more than 10 elements on the skin) - 10 people. Clinical examination of patients was being conducted, using data from the anamnesis of concomitant somatic pathology. **Results:** Intense cytoplasmic and nuclear staining of tumor cells was revealed by individuals with multiple SK in 70% by immunohistochemical test with monoclonal antibodies to p16, 30% of the staining was moderate, diffuse. A positive reaction with antibody to p16 was diffuse, weak by patients with single SK in 80% of the cases, stain of the single cells of the basal layer nucleus was recorded, in 20% the colour of the cells cytoplasm was intense, but as separate focuses. The presence of insulin resistance was revealed from anamnesis by all patients with multiple SK. Insulin resistance by patients with single SK was detected in 2 cases. **Conclusions:** The connection was found between the intensity of the p16 expression and the prevalence of SK. Given the presence of insulin resistance in the anamnesis of patients with multiple SK, an assumption was made about an indirect effect of the p16 expression on hyperinsulinemia. The presence of focal intense reactions with antibodies to p16 by patients with single SK can serve as a predictor of eruptions dissemination in future.

Key words: Seborrheic keratosis; Immunohistochemistry; Tumor suppressor protein p16; Insulin

INTRODUCTION

Seborrheic keratosis (SK) is a benign epithelial tumor, occurring mostly in patients after 35-40 years old, with unclear etiology. The role of such factors as increased sun exposure, carcinogens, human papilloma virus, genetic predisposition has not been proven in the development of SK [1,2]. Immunohistochemictry test (IHC test) conducted to examine cell cycle regulators (cyclin-dependent kinases and their inhibitors, growth factors) disclosed violations of the cell cycle by SK. The details of violations however remained unclear [3,4].

A theory of keratinocytes "aging" finds more supporters when seborrheic keratoses. The aging prevents unlimited and uncontrolled growth of damaged cells, thereby preventing degeneration, but on the other hand, increasing the cells resistance to apoptosis [5]. The main genes responsible for the process of "aging" are genes which produce proteins p16 and p53. In human body the p16 is encoded by the gene CDKN2A, located on chromosome 9 (9p21.3) [5-7]. The protein p16 was discovered by researchers in 1993 [8]. This gene is involved in the development of both sporadic and familial melanoma, glioma, when lung cancer, T-cell leukemia. In addition, p16 is currently studying as a

How to cite this article: Alexandrova AK, Smolyannikova VA, Filatova VA, Alexandrova OK. Protein p16 role in seborrheic keratosis. Our Dermatol Online. 2016;7(4):377-380.

Submission: 04.02.2016; **Acceptance:** 19.04.2016

DOI:10.7241/ourd.20164.103

prognostic biomarker for patients with squamous cell carcinoma of the oropharynx, cervical cancer [9,10].

The ρ16/INK4 gene is a tumor suppressor gene belonging to the group of "cell cycle guardians". At the molecular level, the effect of the p16 protein is based on the inhibition of the cell cycle regulators [11]. During the G_1 phase, the activity of cyclin-dependent kinases in a growing cell (*Cdk*) is blocked until the cell starts the next cell cycle [12].

Inhibitors of cyclin-dependent kinases are divided into two main families: Cip/Kip and INK4. The INK4 family inhibitors block the Cdk4 and Cdk6 cyclin-dependent kinases which control the G_1 cell cycle phase. The Cip/Kip family inhibitors block the cyclin-dependent kinase in conjunction with cyclin [7]. The p16 protein is a cyclin-dependent kinase inhibitor participating in the Rb/cyclinD/cdk4/p16INK4a biochemical pathway [13]. p16 is bound to kinases such as CDK4 and CDK6, and this complex upsets the interaction between kinases and cyclin D [14]. Inhibition of the functions of the cyclin-dependent kinases results in the hypophosphorylation of the pRB protein which reduces the expression of E2F-dependent genes and blocks cell transition from phase G1 to phase S ensuring cell division and proliferation control [9,15]. Many sources confirm that disturbances in the G_1 phase and G_1/S control point result in uncontrolled tumor growth [12]. It is shown by experiments that a reduced expression of p16 results in pRB hyperphosphorylation [14]. In malignant tumors, cells overcome an increased expression of the p16 gene through its inactivation, by using hypermethylation or deletion. Thus, the effect of that gene and its product, the p16 protein, combines differently directed processes: oncogenesis and aging, fixing them at the opposite ends. At one end, hypermethylation, mutations, and deletions of p16 result in gene control disruption and cancer development through disrupted cell cycle control. Conversely, p16 activation through DNA damage results in its accumulation in tissues, suppressed proliferative activity, and cellular senescence [15].

MATERIALS AND METHODS

Twenty tumors were used as study materials which were surgically removed from 10 patients with multiple SKs (more than 10 elements) and 10 patients with single SKs. The SK diagnosis was made on the basis of the results of clinicopathologic studies. The age of the sick people varied from 46 to 75 years, with women prevailing (70%). The most typical elements of seborrheic keratosis on the body skin were selected for studies, a maximum of 2 cm in diameter, flat, moderately pigmented, with a hyperkeratotic surface. The operational material was fixed in the 10% neutral buffered formalin solution, with subsequent preparation of paraffin blocks. The sections were stained with haematoxylin and eosin. Primary monoclonal antibodies of p16 were used for IHC tests, at a dilution of 1:200 (Novocastra Laboratories Ltd.). The IHC reaction results were evaluated by color intensity (pronounced, moderate, weak) and by prevalence of cytoplasmic or nuclear staining.

RESULTS

High-grade diffused cytoplasmic response of antibodies to p16 was reported for 7 patients from the group having multiple SKs (70%) (Fig. 1). In 3 cases (30%), moderate-intensity cytoplasmic staining of the entire tumor tissue was identified. Also, nuclear expression of p16 was present in all cases, essentially for basal layer cells.

For the group having single SKs, weak diffused cytoplasmic staining of tumor cells was reported for 8 persons (80%), with a positive response in individual nuclei (Fig. 2). Intensive focal staining of the cell cytoplasm was noted in 20% of cases. It was established from the patients' medical histories that all patients having multiple SKs were insulin resistant, with 5 persons followed up for pancreatic diabetes. There were 2 insulin resistance cases registered for the persons having single SKs.

DISCUSSION

Different foreign authors treat differently the p16 expression difference and its role in the cell cycle. It is considered that p16 expression increases substantially with age which may be a marker of cellular senescence at the molecular level [16,17]. We did not reveal any clear-cut relation between age and a more pronounced p16 expression in our study; both patient groups were equal in terms of age structure which gives no reason to believe that an increased p16 is primarily explained by age. Nor was the opinion that p16 is a possible malignant transformation marker for SK elements confirmed. Thus, in studying 17 cases of seborrheic

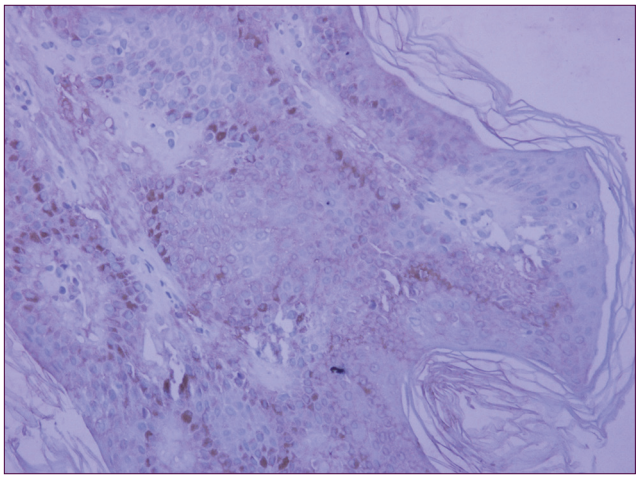

Figure 1: Expression of monoclonal antibodies to p16 for a multiple-SK patient.

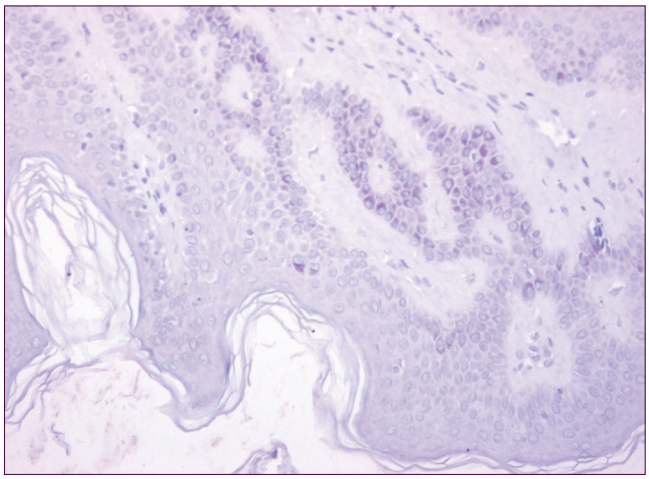

Figure 2: Expression of monoclonal antibodies to p16 for a single-SK patient.

keratosis with signs of Bowenoid transformation, Wu YH et al. discovered an increased expression of p16 and p21 in cells which is also typical for the Bowen disease and Bowenoid papulosis. It was suggested that they study p16 for patients having seborrheic keratosis to identify possible malignant transformation of elements [5]. In our opinion, for that suggestion to be made, there should be other undoubted morphological signs of a malignancy in place. Other publications, in particular, Nakamura S. et al., revealed a pronounced expression of the p16 protein in all tumor cells for skin samples from the SK affected area and associated it with a disrupted cell cycle, blocking of the cell S phase entry, and their premature aging, i.e. with apoptosis inhibition, rather than with possible malignant transformation [3]. However, in the study by Brueks et al. of 10 acantholytic nevus cases of the acanthotic and irritated types, the p16 protein expression level was medium and, in the author's opinion, has no significant role in SK pathogenesis [4].

The results of our study showed the following distinctive feature: a significant expression of p16, both cytoplasmic and nuclear, was reported for 70% of the persons having multiple SKs who were also diagnosed to be insulin resistant. A question arises concerning a possible indirect effect of hyperinsulinemia on p16 expression. Literature contains data indicating an increased level of p16 in the pancreatic gland during aging which inhibits proliferation of beta cells and reduces their ability to respond to damage. This is one of the possible development mechanisms for "old age" diseases, such as pancreatic diabetes, CAD, apoplectic attack, etc. In our opinion, hyperinsulinemia causes an increased proliferative activity of cells entailing an increased expression of the p16 suppressor protein and kinase inhibitor.

CONCLUSIONS

Based on p16 expression, one can assess the occurrence of rashes for SK patients, given its substantial amount identified for the persons having multiple elements. We consider the presence of an intensive focal reaction with antibodies to p16 for 2 single SK patients as a marker of further disease progression and the number of tumors eventually increasing. The interrelation between an increased expression of p16 and insulin resistance requires a further study to better understand the disease pathogenesis and expand treatment options.

Statement of Human and Animal Rights

All procedures followed were in accordance with the ethical standards of the responsible committee on human experimentation (institutional and national) and with the Helsinki Declaration of 1975, as revised in 2008.

Statement of Informed Consent

Informed consent was obtained from all patients for being included in the study.

REFERENCES

1. Hafner C, Vogt T. Seborrheic keratosis. J Dtsch Dermatol Ges. 2008;6:664-77.
2. Hafner C, Vogt T, Landthaler M, Müsebeck J. Somatic FGFR3 and PIK3CA mutations are present in familial seborrhoeic keratoses.

Br J Dermatol. 2008;159:214-7.
3. Nakamura S, Nishioka K. Enhanced expression of p16 in seborrhoeic keratosis; a lesion of accumulated senescent epidermal cells in G1 arrest. Br J Dermatol. 2003;149:560-5.
4. Bruecks AK, Kalia S, Trotter MJ. Overexpression of p27KIP1 in seborrheic keratosis. J Cutan Med Surg. 2007;11:174-8.
5. Wolff K, Goldsmith LA. Fitzpatricks Dermatology in General Medicine. Seventh edition, McGraw-Hill Medical, 2012
6. Wu YH, Hsiao PF, Chen CK. Seborrheic Keratosis With Bowenoid Transformation: The Immunohistochemical Features and Its Association With Human Papillomavirus Infection. Am J Dermatopathol. 2015;17:24-5.
7. Harvey LM. Molecular Cell Biology. 6th. New York City: W.H. Freeman and Company, 2008.
8. Liggett WH, Sidransky D. Role of the p16 tumor suppressor gene in cancer. J Clin Oncol. 1998;16:1197–206.
9. Serrano M, Lee H, Chin L, Cordon-Cardo C, Beach D, DePinho RA. Role of the INK4a locus in tumor suppression and cell mortality. Cell. 1996;85:27.
10. Cioffi-Lavina M, Chapman-Fredricks J, Gomez-Fernandez C, Ganjei-Azar P, Manoharan M, Jorda M. P16 expression in squamous cell carcinomas of cervix and bladder. Appl Immunohistochem Mol Morphol. 2010;18:344-7.
11. Nobori T, Miura K, Wu DJ, Lois A, Takabayashi K, Carson DA. Deletions of the cyclin-dependent kinase-4 inhibitor gene in multiple human cancers. Nature. 1994;368:753-55.
12. Morgan D. The Cell Cycle: Principals of Control. London: New Science Press LTD, 2007.
13. Dyson N, Baiman A. Oncogenes and cell proliferation. Curr Opin Genet Dev. 1999;9:11-4.
14. Rosso AA, Tong L, Lee JO, Jeffrey PD, Pavletich NP. Struktural basis for inhibition of the ciklin-dependent kinase Cdk6 by the tumour suppressor p16/INK4A. Nature. 1998;395:237-43.
15. Rayess H, Wang MB, Srivatsan ES. Cellular senescence and tumor suppressor gene p16. Int J Cancer. 2012;130:171-4.
16. Liu Y, Sanoff HK, Cho H, Burd CE, Torrice C, Ibrahim JG, et al. Expression of p16(INK4a) in peripheral blood T-cells is a biomarker of human aging. Aging Cell. 2009;8:439-48.
17. Roussel MF. The INK4 family of cell cycle inhibitors in cancer. Oncogene. 1999;18:5311-12.

Copyright by Alexandra K. Alexandrova, et al. This is an open access article distributed under the terms of the Creative Commons Attribution License, which permits unrestricted use, distribution, and reproduction in any medium, provided the original author and source are credited.
Source of Support: Nil, **Conflict of Interest:** None declared.

Brief Report

Stevens–Johnson syndrome and toxic epidermal necrolysis in an academic hospital setting: a 5-year retrospective study

Ewa Stocka-Łabno[1], Natalia Gabzdyl[1], Magdalena Misiak-Galazka[1], Małgorzata Pawłowska-Kisiel[1], Tomasz Łazowski[2], Lidia Rudnicka[1]

[1]Department of Dermatology, Medical University of Warsaw, Warsaw, Poland, [2]Department of Anaesthesiology and Intensive Care, Medical University of Warsaw, Warsaw, Poland

Corresponding author: Lidia Rudnicka, MD, PhD., E-mail: lidiarudnicka@gmail.com

ABSTRACT

Introduction: Toxic epidermal necrolysis and Stevens–Johnson syndrome are acute life-threatening mucocutaneous reactions to drugs. The aims of the study were to identify these drugs and characterize population prone to these reactions. **Materials and Methods:** Data including demographics, culprit drug, clinical characteristics, course of disease, treatment given, and therapeutic responses were retrospectively collected from medical records of 31 patients admitted to Department of Dermatology from January 2009 to December 2014. **Results:** Drugs most commonly involved in Stevens–Johnson syndrome were antimicrobials: ciprofloxacin, doxycycline, cefuroxime, trimethoprim, amoxicillin, clindamycin, co-trimoxazole (50% of patients) and nonsteroidal anti-inflammatory drugs: ibuprofen, naproxen, metamizole, piroxicam (29% of patients). Drugs involved in toxic epidermal necrolysis were antimicrobials: sulfasalazine, co-trimoxazole, cefuroxime, clindamycin (71% of patients) and anticonvulsants: lamotrigine (29% of patients). The comorbidities' characteristic for the group of patients affected by toxic epidermal necrolysis were psychiatric and autoimmune disorders. The most common complication was infection. Two patients died and in both cases the cause of death was sepsis. **Conclusions:** The study indicates that in observed population drugs with the highest risk of most severe reactions are lamotrigine (anticonvulsant) and antimicrobials (most commonly sulfonamides), therefore it is advisable to consider carefully administration of these drugs, especially to patients with history of autoimmune reactions.

Key words: Stevens-Johnson syndrome; Toxic epidermal necrolysis; Adverse drug reaction; Retrospective study

INTRODUCTION

Toxic epidermal necrolysis (TEN) and Stevens–Johnson syndrome (SJS) are acute life-threatening mucocutaneous reactions usually to drugs characterized by extensive necrosis and detachment of the epidermis plus widespread erythematous or purpuric macules or flat atypical lesions [1] (Fig. 1).

These two conditions are severity variants of an identical process of epidermal necrolysis (EN) that differs only in the final extent of body surface involved: below 10% in SJS, from 10 to 30% in overlap SJS/TEN and above 30% of the body surface in TEN [1,2].

EN is a rare condition. The overall incidence of SJS and TEN was estimated at 1 to 6 cases per million person-years and 0.4 to 1.2 cases per million person-years, respectively [1].

The skin reactions are mediated by cytotoxic T-cells activated in response to the culprit drug. Among more than 100 different drugs implicated, the associated with the highest risk are: antibacterial sulfonamides, aromatic anticonvulsants, allopurinol, oxicam nonsteroidal

How to cite this article: Stocka-Łabno E, Gabzdyl N, Misiak-Galazka M, Pawłowska-Kisiel M, Łazowski T, Rudnicka L. Stevens–Johnson syndrome and toxic epidermal necrolysis in an academic hospital setting: a 5-year retrospective study. Our Dermatol Online. 2016;7(4):381-384.

Submission: 07.04.2016; **Acceptance:** 24.07.2016

DOI: 10.7241/ourd.20164.104

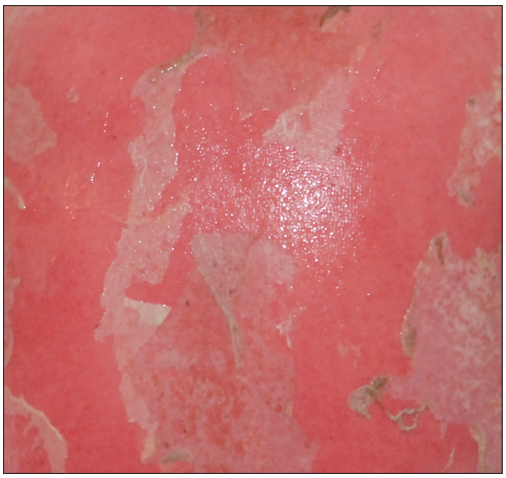

Figure 1: Detachment of the epidermis in toxic epidermal necrolysis. By courtesy of Marek Opala.

anti-inflammatory drugs (NSAIDs), lamotrigine, and nevirapine [1,3].

The treatment is based on prompt withdrawal of the culprit drug and supportive care similar to burns treatment. It is advisable to transfer patients with extensive and rapidly progressing reactions to an intensive care unit (ICU) or a burn centre. Steroids administration is controversial due to their expected effect of decreasing the adverse reaction on one hand and increasing susceptibility to infection on the other hand. Other medicaments considered are: cyclosporine A, intravenous immunoglobulin (IVIG), anti-TNF. Pharmacotherapy includes antibiotics when infection is suspected [1,3].

The main aims of the study were to identify drugs with the highest risk of causing most severe adverse reactions and to attempt to characterize groups of patients with high risk of developing EN.

MATERIALS AND METHODS

The medical records of SJS/TEN patients hospitalized at Department of Dermatology in The Infant Jesus Teaching Hospital in Warsaw, Poland between 2009 and 2014 were retrospectively reviewed. Based on the Algorithm for Assessment of Drug Causality in Stevens–Johnson Syndrome and Toxic Epidermal Necrolysis (Alden) [4] in 31 patients drug causality was established. Other causes of skin reactions observed among those patients were excluded as less probable.

Among patients with drug induced SJS/TEN the following variables were observed: patient characteristics (age, gender, ethnicity, comorbidities), culprit drug, time interval between drug intake and onset of symptoms (latent period), drug reaction observed, factors associated with severity of illness (SCORTEN) [5], systemic complications, length of hospital stay, treatment given, and outcomes. The SCORTEN scale includes: age, malignancy, tachycardia, initial percentage of epidermal detachment, serum urea, serum glucose and bicarbonate. Since bicarbonate levels are not routinely determined in our department, that value was excluded and modified score for toxic epidermal necrosis (mSCORTEN) was calculated [5,6].

RESULTS

Twenty four patients were diagnosed with drug associated SJS and 7 with TEN over a 5-year study period.

Patient Characteristics

The patients' age ranged from 19 to 87 years, with a median of 41 years. The gender distribution was 20 females (65%) to 11 males (35%), but the difference was not statistically significant (two-sided p-value = 0.074).

Twenty nine patients were Polish, one Russian, one Ukrainian. All patients were Caucasian.

A total number of eighteen (75%) patients with SJS had comorbidities. The most common comorbidities were hypertension (20%), asthma and allergies (ingested, contact and inhaled allergy) (16%), thyroid diseases (16%). All of TEN patients (7/7) had comorbidities including: psychiatric disorders (bipolar affective disorder, paranoid schizophrenia (43%)), autoimmune disorders (ankylosing spondylitis, psoriasis vulgaris, rheumatoid arthritis, Hashimoto's thyroiditis (57%)), asthma and allergies (43%), or hypertension (43%).

Culprit Drugs (Table 1)

SJS was caused most frequently by antimicrobials (50% of patients) and NSAIDs (29% of patients). In other cases the culprit drugs were: antifungal medication (two patients), angiotensin-converting enzyme (ACE) inhibitor (one patient), carbamazepine (one patient) and unithiol (one patient).

Most common causative agents in TEN were likewise antimicrobials (71%), especially sulfonamides and

anticonvulsant – lamotrigine (29%).

The latent period ranged from 1 to 30 days. In 40% of cases it was shorter than 5 days, in 55% between 5 and 28 days and in 4% longer than 28 days. The average latent period was 7 days. NSAIDs had the average latent period of 3 days, antimicrobials of 8 days, antifungals 1 day and anticonvulsants 12 days.

Complications, Length of Stay and Outcomes

Fifteen patients (48%) had increased levels of inflammatory markers including C-reactive protein (CRP), erythrocyte sedimentation rate (ESR) or white blood cell count (WBCs). Six of them had neutrophilia. Three patients (10%) had transaminitis. One case of SJS was complicated by bacterial conjunctivitis. Additionally two cases of TEN had vascular complications: thrombophlebitis and varicose vein bleeding.

The average length of stay of SJS and TEN patients on the dermatology unit was 7.5 days and 16.3 days, respectively.

Table 1: Culprit drugs

Drug (s)	Nr of SJS cases	Nr of TEN cases
Antimicrobials	12	5
Ciprofloxacin	2	
Doxycycline	2	
Clindamycin	1	1
Amoxicillin	1	
Amoxicillin and Clavulanate	1	
Cefuroxime	2	1
Trimethoprim	2	
Sulfamethoxazole+trimethoprim	1	1
Sulfasalazine		2
NSAIDs	7	
Naproxen	1	
Ibuprofen	4	
Metamizole	1	
Piroxicam	1	
Antifungals	2	
Fluconazole	1	
Miconazole	1	
Anticonvulsants	1	2
Carbamazapine	1	
Lamotrigine		2
Others	2	
Enalapril	1	
Unithiol	1	

There were no Cases of Mortality among SJS Patients

Three TEN patients (43%) were transferred to ICU (Intensive Care Unit). Two of them died of sepsis caused by Methicillin-resistant Staphylococcus aureus (MRSA) and Extended spectrum beta-lactamase (ESBL)-producing bacteria. One of the patients who died had high (3) and the other low (1) mSCORTEN factor at the time they had been admitted to hospital (Table 2).

Treatment

Twenty SJS patients received systemic steroids, 18 topical steroids, 18 antihistamines and 11 antibiotics whereas 5 TEN patients received systemic steroids, 5 cyclosporine, 6 antibiotics, 2 IVIG and 1 plasmapheresis. The most intensive treatment (IVIG, cyclosporine, systemic steroids and antibiotics) received the two patients with reaction to anticonvulsants (lamotrigine).

DISCUSSION

The analysis of the population of patients shows that the SJS has much higher morbidity rate than TEN (24 SJS to 7 TEN patients). In both groups patients fall into two age categories: from 19 to 44 and from 57

Table 2: Values of mSCORTEN among TEN patients. One point is given for each of six criteria present at the time of admission (age >40 years, associated malignancy, heart rate >120 beats/min, detached body surface >10%, serum BUN >27 mg/dl, serum glucose >250 mg/dl)

Drug	Age	Cancer	Heart rate (BPM)	Detached body surface (%)	Serum BUN (mg/dL)	Serum glucose (mg/dL)	mSCORTEN value	Risk of mortality (%)	Outcomes
Lamotrigine	34	No	85	>10	20	118	1	3-12	
Lamotrigine	34	No	88	>10	19	135	1	3-12	Transfer to ICU, death
Sulfasalazine	37	No	120	>10	28	113	3	35-58	Transfer to ICU
Cefuroxime	71	No	78	>10	88	159	3	35-58	Transfer to ICU, death
Clindamycin	76	No	75	>10	53	109	3	35-58	
Sulfasalazine	30	No	70	>10	11	84	1	3-12	
Sulfamethoxazole+trimethoprim	85	No	76	>10	38	119	3	35-58	

to 87 years. The most common comorbidities in SJS group (hypertension, allergy, thyroid disease) closely mirror those in general population though the share of comorbidities with immune system malfunction draws attention.

The comorbidities characteristic for the TEN group are psychiatric and autoimmune disorders.

Due to genetic factors the epidemiology and causative drugs differ significantly in different ethnic populations [5,6].

In our study drugs most commonly involved in SJS were antimicrobials and NSAIDSs and in TEN antimicrobials and anticonvulsants which corresponds with results of other European studies [7,8]. Most of these drugs are evaluated as high or significant risk drugs in EuroSCAR study [9]. The culprit drugs in case of the two patients who died were lamotrigine and cefuroxime.

The most common complication was infection. Among TEN patients only one out of seven did not require antibiotics. In two cases the infection led to death.

So far no single major HLA-related genetic risk factor was identified for lamotrigine-induced severe cutaneous adverse reactions (SCARs) among patients of European origin [10]. However success in establishing correlation between reactions to carbamazepine and HLA-B*1502 allele [11] encourages continuation of the studies.

CONCLUSION

The study indicates that in observed population the drugs with the highest risk of most severe reactions are lamotrigine and antimicrobials (most commonly sulfonamides). Due to cases of mortality and necessity of long hospitalization and expensive treatment it is advisable to consider carefully administration of these drugs especially to patients with history of autoimmune reactions.

REFERENCES

1. Valeyrie-Allanore LL, Roujeau J. Chapter 40. Epidermal Necrolysis (Stevens–Johnson Syndrome and Toxic Epidermal Necrolysis). In: Fitzpatrick's Dermatology in General Medicine, 8e. Goldsmith LA, Katz SI, Gilchrest BA, Paller AS, Leffell DJ, Wolff K. (eds). NY: McGraw-Hill, New York. 2012: 439-48.
2. Bastuji-Garin S, Rzany B, Stern RS, Shear NH, Naldi L, Roujeau JC. Clinical classification of cases of toxic epidermal necrolysis, Stevens-Johnson syndrome, and erythema multiforme. Arch Dermatol. 1993;129:92-6.
3. Mockenhaupt M. Severe cutaneous adverse reactions. In: Braun-Falco's Dermatology. Burgdorf W, Plewig G, Wolff H, Landthaler M, (eds). Springer, Heidelberg. 2009: 473-84.
4. Sassolas B, Haddad C, Mockenhaupt M, Dunant A, Liss Y, Bork K, et al. ALDEN, an Algorithm for Assessment of Drug Causality in Stevens–Johnson Syndrome and Toxic Epidermal Necrolysis: Comparison With Case–Control Analysis. Clin Pharmacol Ther. 2010;88:60-8.
5. Bastuji-Garin S, Fouchard N, Bertocchi M, Roujeau JC, Revuz J, Wolkenstein P. SCORTEN: a severity-of-illness score for toxic epidermal necrolysis. J Invest Dermatol. 2000;115:149–53.
6. Sun J, Liu J, Gong Q-L, Ding GZ, Ma LW, Zhang LC, et al. Stevens–Johnson Syndrome and toxic epidermal necrolysis: a multi-aspect comparative 7-year study from the People's Republic of China. Drug Des Devel Ther. 2014;8:2539-47.
7. Weinand C, Xu W, Perbix W, Lefering R, Maegele M, Rathert M, et al. 27 years of a single burn centre experience with Stevens-Johnson syndrome and toxic epidermal necrolysis: analysis of mortality risk for causative agents. Burns. 2013;39:1449-55.
8. Dao R-L, Su S-C, Chung W-H. Recent advances of pharmacogenomics in severe cutaneous adverse reactions: immune and nonimmune mechanisms. Asia Pacific Allergy. 2015;5:59-67.
9. Mockenhaupt M, Viboud C, Dunant A, Naldi L, Halevy S, Bouwes Bavinck JN, et al. Stevens–Johnson syndrome and toxic epidermal necrolysis: assessment of medication risks with emphasis on recently marketed drugs: the EuroSCAR-study. J Invest Dermatol. 2008;128:35-44.
10. Kazeem GR, Cox C, Aponte J, Messenheimer J, Brazell C, Nelsen AC, et al. High-resolution HLA genotyping and severe cutaneous adverse reactions in lamotrigine-treated patients. Pharmacogenetics and Genomics. 2009;19:661-5.
11. Tangamornsuksan W, Chaiyakunapruk N, Somkrua R, Lohitnavy M, Tassaneeyakul W. Relationship between the HLA-B*1502 allele and carbamazepine-induced Stevens-Johnson syndrome and toxic epidermal necrolysis: a systematic review and meta-analysis. JAMA Dermatol. 2013;149:1025-32.

Copyright by Ewa Stocka-Łabno, et al. This is an open access article distributed under the terms of the Creative Commons Attribution License, which permits unrestricted use, distribution, and reproduction in any medium, provided the original author and source are credited.

Source of Support: Nil, **Conflict of Interest:** None declared.

Brief Report

Nail diseases in elderly. Report of 71 cases

Patricia Chang, Kathia Domínguez

Department of Dermatology, Hospital General de Enfermedades IGSS and Hospital Ángeles, Guatemala

Corresponding author: Dra Patricia Chang, E-mail: pchang2622@gmail.com

ABSTRACT

Introduction: The nails present various changes and diseases due to age, and the elderly are no exception to this. **Aims:** To learn about the most frequent nail diseases in elderly patients of our hospital unit. **Methodology:** A descriptive study was performed on patients hospitalized at Hospital General de Enfermedades IGSS in medical services during February and March 2015, to investigate the occurrence of nail diseases in hands and feet of elderly patients. All the patients had a complete exam of finger and toe nails. **Results:** The alterations detected in fingernails were: onychorrhexis, 36 (22.99%); half-and-half nails, 5 (5.75%); Leukonychia apparent, 3 (3.45%), onychoschizia, 3 (3.45%); proximal fold hematoma due to oximeter, 3 (3.45%); onycholysis, 3 (3.45%); splinter hemorrhages, 3 (3.45%); pterygium, 2 (2.30); worn-down nails, 2 (2.30); onychodystrophy, 1 (1.15%); nail biting, 1 (1.15%); parrot beak nails, 1 (1.15%), Beau's lines, 1 (1.15%); paronychia, 1 (1.15%); trauma, 1 (1.15%); Beau's ridges, 1 (1.15%). At feet level the alterations found were: onychomycosis, 31 (29.52%); onychogryphosis, 16 (15.24%); pterygium, 8 (7.62%); overriding toes, 5 (4.76%); platonychia, 5 (4.76%); pincer nails, 4 (3.81%); frictional melanonychia, 4 (3.81%); onychorrhexis, 4 (3.81%); onychodystrophy, 4 (3.81%); hematoma, 3 (2.86%), onycholysis, 2 (1.90%), koilonychias, 2 (1.90%), Beau's ridges, 2 (1.90%); Onychomadesis, 1 (0.95%); tile-shaped nails, 1 (0.95%); longitudinal groove, 1 (0.95%); distal nail embedding, 1 (0.95%); anonychia, 1 (0.95%); micronychia, 1 (0.95%); pachionychia, 1 (0.95%); dyschromia, 1 (0.95%). **Conclusions:** The alterations of finger and toe nails in the elderly are not exclusive of this group as they occur in the general population except that in the elderly, the most frequent are onychorrhexis in hands and onychogryphosis in feet.

Key words: Elderly; Nails; Onychogryphosis; Onychomycosis

How to cite this article: Chang P, Domínguez K. Nail diseases in elderly. Report of 71 cases. Our Dermatol Online. 2016;7(4):385-390.
Submission: 08.02.2016; **Aceptance:** 11.04.2016
DOI:10.7241/ourd.20164.105

Brief Report

Onicopatias en ancianos. Reporte de 71 casos

Patricia Chang, Kathia Domínguez

[1]*Department of Dermatology, Hospital General de Enfermedades IGSS and Hospital Ángeles, Guatemala*

Corresponding author: Dra Patricia Chang, E-mail: pchang2622@gmail.com

RESUMEN

Antecedente: Las uñas presentan diferentes cambios y enfermedades según la edad y las de los ancianos no son la excepción. **Objetivos:** Conocer las onicopatías más frequentes en ancianos en nuestra unidad hospitalaria. **Metodologia:** Se realizó un estudio descriptivo en pacientes hospitalizados del Hospital General de Enfermedades IGSS de los servicios de Medicina durante los meses de febrero y marzo del año dos mil quince para estudiar la presencia de las onicopatías en pacientes ancianos de manos y pies. A todos los pacientes se les realizo examen completo de las uñas de las manos y de los pies. **Resultados:** Las alteraciones detectadas en las uñas de las manos fueron: onicorrexis 36 (22.99%), uñas mitad-mitad 5 (5.75%); leuconiquia aparente 3 (3.45%), onicosquicia 3 (3.45%), hematoma PNF 3 (3.45%), onicólisis 3 (3.45%), uñas en astilla 3 (3.45%), pterigión 2 (2.30), uña brillosa 2 (2.30), onicodistrofia 1 (1.15%), onicofagia 1 (1.15%), uñas en pico de loro 1 (1.15%), surco lineal 1 (1.15%), perionixis 1 (1.15%), trauma 1 (1.15%), surcos de Beau 1 (1.15%). A nivel de los pies, las alteraciones encontradas fueron: onicomicosis 31 (29.52%), onicogrifosis 16 (15.24%), pterigión 8 (7.62), ortejo montado 5 (4.76%), platoniquia 5 (4.76%), uñas en pinza 4 (3.81%), melanoniquia friccional 4 (3.81%), onicorrexis 4 (3.81%), onicodistrofia 4 (3.81%), hematoma 3 (2.86%), onicólisis 2 (1.90%), coiloniquia 2 (1.90%), surcos de Beau 2 (1.90%), onicomadesis 1 (0.95%), uñas en teja 1 (0.95%), estría longitudinal 1 (0.95%), encajamiento distal 1 (0.95%), anoniquia 1 (0.95%), microniquia 1 (0.95%), paquioniquia 1 (0.95%), discromía 1 (0.95%). **Conclusiones:** Las alteraciones de las uñas de las manos y de los pies en ancianos no son exclusivas de éstos ya que son vistas en la población normal excepto que en los ancianos es mas frecuente la onicorrexis en manos y la onicogrifosis en pies.

Palabras claves: Vejez; Uñas; Onicorrexis; Onicogrifosis; Onicomicosis

INTRODUCCIÓN

Los efectos insidiosos del envejecimiento pueden detectarse en personas que, incluso en ausencia de enfermedades, al comenzar el envejecimiento se inicia el declive progresivo de muchas funciones fisiológicas y morfológicas, en general los cambios físicos en los órganos sin olvidarnos, claro, de los anexos de la piel ya que las uñas de las manos se vuelven más quebradizas, en tanto que las de los pies, se tornan gruesas y opacas.

Estos cambios característicos de las uñas, forman parte del proceso natural del envejecimiento el cual, según la Asociación Internacional de Psicogeriatría (IPA), se clasifica en: adulto mayor joven 55–64 años, adulto mayor maduro 65–74 años, adulto mayor 75–84 años, ancianos mayores de 85 años, nonagenarios y centenarios.

MATERIAL Y MÉTODOS

Se realizó un estudio descriptivo en pacientes hospitalizados del Hospital General de Enfermedades IGSS de los servicios de Medicina durante los meses de febrero y marzo del año dos mil quince para estudiar la presencia de las onicopatías en pacientes ancianos de manos y pies sin importar motivo de hospitalización. A todos los pacientes se les realizo examen completo de las uñas de las manos y de los pies. El diagnóstico fue hecho por el primer autor del estudio.

RESULTADOS

Se estudiaron un total de 71 pacientes, 51 del sexo masculino (71.83%) y 20 del femenino (28.17%); los grupos de edad fueron distribuidos acorde a

How to cite this article: Chang P, Domínguez K. Onicopatias en ancianos. Reporte de 71 casos. Our Dermatol Online. 2016;7(4):385-390.
Submission: 08.02.2016; **Acceptance:** 11.04.2016
DOI:10.7241/ourd.20164.105

la clasificación de la Asociación Internacional de Psicogeriatría 55-64: 17 (23.94%), 65-74: 27 (38.02%), 75-84: 15 (21.12%) y mayores de 85 años: 12 (16.90%).

En nuestro estudio se evaluaron 71 personas, incluyendo hombres y mujeres, de los pacientes que estaban hospitalizados en los servicios de medicina. El paciente anciano más joven tenía 60 años y el de mayor edad 89 años.

Los motivos de hospitalización fueron: enfermedad renal crónica: 15 (21.13%); diabetes mellitus: 7 (9.86%); neoplasias: 7 (9.86%); insuficiencias cardíacas: 6 (8.45%); hemorragia gastrointestinal superior: 5 (7.04%); alteraciones pulmonares: 5 (7.04%); hepatopatías: 4 (5.63%), Sepsis: 3 (4.22%); enfermedades hematológicas 3 (4.22%); cálculo renal: 2 (2.81%); evento cerebro vascular: 2 (2.81%); litiasis vesical: 2 (2.81%); obstrucción por adherencias: 2 (2.81%); retención de azoados: 1 (1.40%); ictiosis vulgar: 1 (1.40%); urticaria: 1 (1.40%), prurito senil: 1 (1.40%); peritonitis: 1 (1.40%); pancreatitis: 1 (1.40%).

De los 71 pacientes, 50 (70.42%) presentaron cambios en las uñas de las manos y 63 (88.73%) en las de los pies.

Las alteraciones detectadas en las uñas de las manos fueron: onicorrexis 36 (22.99%) (Fig. 1), uñas mitad-mitad 5 (5.75%) (Fig. 2); leuconiquia aparente 3 (3.45%), onicosquicia 3 (3.45%) (Fig. 3), hematoma del pliegue proximal por el uso del oxímetro 3 (3.45%) (Fig. 4), onicólisis 3 (3.45%), hemorragias en astilla (Fig. 5) 3 (3.45%), pterigión 2 (2.30), uña brillosas por rascado 2 (2.30), onicodistrofia 1 (1.15%), onicofagia 1 (1.15%), uña en pico de loro 1 (1.15%), surco lineal 1 (1.15%), perionixis 1 (1.15%), trauma 1 (1.15%), surcos de Beau 1 (1.15%).

Figure 1: Dferentes aspecto de la onicorrexis en uñas de manos.

A nivel de los pies, las alteraciones encontradas fueron: onicomicosis 31 (29.52%) (Fig. 6), onicogrifosis 16 (15.24%) (Fig. 7), pterigión (Fig. 8) 8 (7.62), ortejo montado y platoniquia (Fig. 9) 5 (4.76%), (4.76%), uñas en pinza 4 (3.81%), melanoniquia friccional 4 (3.81%), onicorrexis 4 (3.81%), onicodistrofia 4 (3.81%), hematoma 3 (2.86%), onicólisis 2 (1.90%), coiloniquia 2 (1.90%), Surcos de Beau 2 (1.90%) (Fig. 10), onicomadesis 1 (0.95%) (Fig. 11), uñas en teja 1 (0.95%), estría longitudinal 1 (0.95%), encajamiento

Figure 2: Uas mitad mitad por insuficiencia renal crónica.

Figure 3: Oicosquicia y onicorrexis.

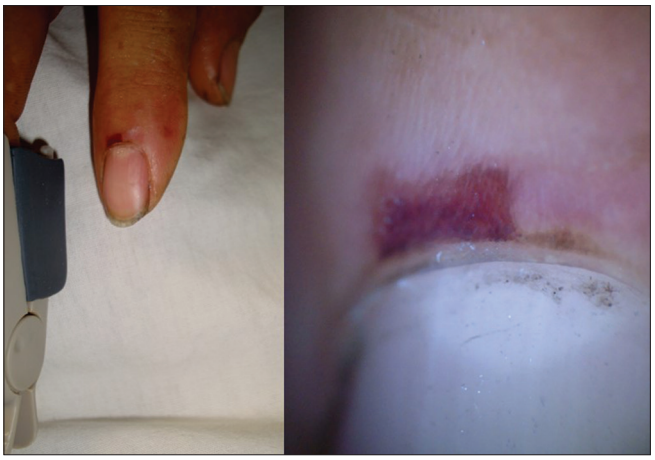

Figure 4: Hematoma del pliegue proximal por el uso de oxímetro.

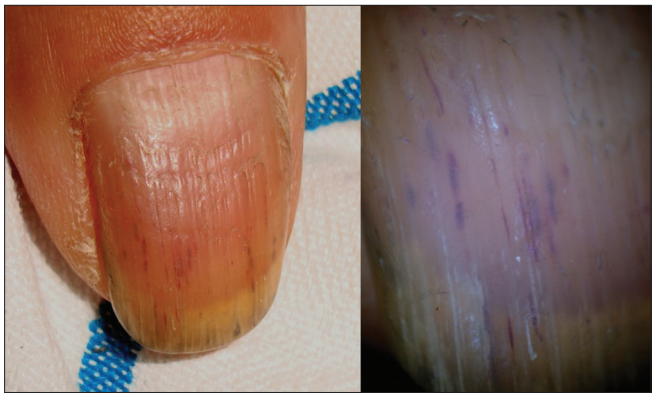

Figure 5: Hemorragias en astilla asociado a insuficiencia renal crónica.

Figure 6: Dferentes tipos de onicomicosis.

Figure 7: Onicogrifosis.

distal 1 (0.95%), anoniquia 1 (0.95%), microniquia 1 (0.95%), paquioniquia 1 (0.95%), discromía 1 (0.95%) (Tabl. 1).

DISCUSIÓN

Los trastornos en la función de las uñas ocurre de forma similar, tanto en mujeres como en hombres, en adultos de edad avanzada especialmente después de los 65 años.

Figure 8: Pterigión dorsal.

Figure 9: Ortejo montado con platoniquia.

Figure 10: Surcos de Beau en primer ortejo izquierdo.

Esto ocurre, además del proceso cronológico normal, a partir de cambios estructurales locales, (articulaciones, los músculos, los tendones, los huesos, los nervios y los receptores, el suministro de sangre, la piel y uñas) [1] patrones de la marcha, traumas repetidos, tipo de calzado, cuidado incorrecto del pie que es mucho más frecuente el descuido por parte del género masculino y diversas enfermedades que pueden afectar la salud de las uñas.

El crecimiento lineal de las uñas disminuye aproximadamente 0.5% por año entre las edades comprendidas de 20 a 100 años [2]. El crecimiento

Figure 11: Onicomadesis primer ortejo derecho.

Tabla 1: Onicopatías de manos y pies en ancianos

Alteraciones ungueales	Uñas de manos		Alteraciones ungueales	Uñas de pies	
	No.	%		No.	%
Normales	21	22.99	Normales	7	6.67
Onicorrexis	36	41.38	Onicomicosis	31	29.52
Uñas Mitad Mitad	5	5.75	Onicogrifosis	16	15.24
Leuconiquia aparente	3	3.45	Pterigión	8	7.62
Onicosquicia	3	3.45	Ortejo montado	5	4.76
Hematoma Pliegue proximal por oxímetro	3	3.45	Platoniquia	5	4.76
Onicólisis	3	3.45	Uñas en pinza	4	3.81
Hemorragias en Astilla	3	3.45	Melanoniquia friccional	4	3.81
Pterigión	2	2.30	Onicorrexis	4	3.81
Uña brillosa	2	2.30	Onicodistrofia	4	3.81
Onicodistrofia	1	1.15	Hematoma	3	2.86
Onicofagia	1	1.15	Onicólisis	2	1.90
Uña en pico de loro	1	1.15	Coiloniquia	2	1.90
Surco lineal	1	1.15	Surcos de Beau	2	1.90
Perionixis	1	1.15	Uñas en Teja	1	0.95
Trauma	1	1.15	Onicomadesis	1	0.95
Surcos de Beau	1	1.15	Estría longitudinal	1	0.95
			Encajamiento distal	1	0.95
			Anoniquia	1	0.95
			Microniquia	1	0.95
			Paquioniquia	1	0.95
			Discromía	1	0.95

predomina en las uñas de las manos, siendo la tasa normal de crecimiento de placa ungueal en promedio de 3.0 y 1.0 mm/mes en uñas de manos y pies respectivamente [3] al igual que en la extremidad dominante, probablemente debido a un menor trauma, acelera el crecimiento de las uñas [4]. El espesor promedio normal de las uñas en mujeres es de 0.6 mm y en hombres de 1.65 mm [3]. Sin embargo con el envejecimiento, el espesor de la placa ungueal se debilita en las uñas de la manos y se tornan más gruesas y secas, opacas y de superficie menos lisa en los pies. El contenido de calcio y hierro de las uñas en el envejecimiento se aumenta y disminuye, respectivamente [5].

Las alteraciones ungueales en la vejez se deben a la reiteración de agresiones externas y se atribuye en parte a la arterioesclerosis sin necesidad de evidencia de obliteración de los vasos. Es importante también recordar que en el anciano se torna dificultoso llevar a cabo cuidados higiénicos y la influencia que causa sobre el organismo el consumo de ciertos medicamentos y de ciertas enfermedades como las hepáticas, cardíacas, tiroideas y nefropatías.

Los cambios seniles relacionados con la morfología de la superficie de la uña, incluye alteraciones en el espesor, contorno por la disminución de la curvatura longitudinal y el aumento de la convexidad transversal [3], superficie y coloración.

Las estrías longitudinales también llamada onicorrexis es una onicopatía asociada a la senilidad puede acompañarse en ocasiones con fragilidad distal, las pueden adquirir diferentes formas como son la platoniquia, coiloniquia como resultado del adelgazamiento de la uña y uñas en pinza [3].

En la coloración de la uña se puede observar que varía desde coloración blanca, amarilla, marrón o gris con aspecto opaco y pálido. Una coloración peculiar observada en torno a la quinta parte de las personas mayores de 70 años de edad son las uñas napolitanas, que se caracteriza por lúnula ausente, además de 3 bandas horizontales de color blanco (proximal), rosa (medio) y opaco (distal) [3].

La lúnula, aunque no es visible en todos los dedos, se observa más consistentemente en las uñas del dedo pulgar, índice y en las de los pies, estudios revelan que el tamaño de la lúnula disminuye con la edad y son poco visibles o ausentes esto se ha notado previamente como un cambio de uñas relacionada con el envejecimiento en las personas de avanzada edad [2].

Los capilares de las uñas muestran frecuentes distorsiones en las personas a partir de los 70 años la cual puede explicar las hemorragias en astilla, que son más comúnmente traumáticas en los ancianos, de color negro y situado en el tercio medio o distal de la uña [5]. Las hemorragias en astilla ocasionada por enfermedades sistémicas son a nivel proximal y de color rojo.

La onicomicosis es también una afección ungueal prevalente en ancianos. Es la infección más común de las uñas, representando la mitad de todas las enfermedades ungueales presentando ocasionalmente hoyuelos profundos [6], siendo la onicomicosis subungueal distal y lateral la más común [3].

La onicogrifosis, trastorno caracterizado por la hipertrofia y la curvatura excesiva de las uñas, también conocidas como cuerno de carnero [7]. Las uñas reducen su velocidad de crecimiento, aumentan su grosor y se vuelven opacas y más duras por aumento proporcional de la queratina [7,8], por traumatismos o trastornos vasculares periféricos, pero más a menudo secundaria a la negligencia y el fracaso para cortar las uñas durante largos períodos de tiempo [7]. Su frecuencia radica en uñas de los pies, aunque también se han reportado en uñas de las manos. Se observa con mayor frecuencia por trastornos de la edad avanzada [9].

Onicólisis, mas frecuente por traumatismos, debido a la separación de la lámina del lecho ungueal que progresa del extremo distal a proximal [5].

La onicosquicia y la onicorrexis son alteraciones del plato ungueal que condicionan la fragilidad de las uñas [6,9] causada por constantes traumatismo, siendo directamente afectada por la edad del paciente.

Los dedos en garra o camptodactilia o campodactilia, presenta una tasa del 60 al 80% según los estudios, en personas de 70 años [9,10]. Afecta habitualmente al segundo y quinto dedo y a menudo es bilateral [10]. Según el tipo de garra, se establecen diferentes zonas pro tuberales en las que se forma las voluminosas y dolorosas hiperqueratosis en las personas ancianas que no pueden llevar a cabo una cotidiana higiene podal. Etiológicamente se describen la garra congénita, garra secundaria a una patología y la más importante, dentro de las personas ancianas, la de origen funcional la cual se origina por mala mecánica del pie [11].

Las deformidades de los ortejos pueden asociarse con hallux valgus o juanetes el cual es un padecimiento progresivo presentándose así en el pie geriátrico [12], de esta manera el ángulo del hueso metatarsiano se modifica debido a factores hereditarios y uso de calzado inadecuado con punta estrecha y fundamentalmente con tacón alto, ya que comprime el primer ortejo y lo empuja hacia el segundo produciendo así el aplanamiento de la uña, onicólisis, onicodistrofia y coiloniquia. Por tales características se documenta más en mujeres de mayor edad.

Statement of Human and Animal Rights

All procedures followed were in accordance with the ethical standards of the responsible committee on human experimentation (institutional and national) and with the Helsinki Declaration of 1975, as revised in 2008.

Statement of Informed Consent

Informed consent was obtained from all patients for being included in the study.

BIBLIOGRAFÍA

1. Carmeli E, Patish H, Coleman R. The aging hand. J Gerontol A Biol Sci Med Sci. 2003;58:146-52.
2. Rao S, Banerjee S, Ghosh SK, Gangopadhyay DN, Jana S, Mridha K. Study of Nail changes and Nail Disorders in the Elderly. Indian J Dermatol. 2011;56:603-6.
3. Lina Abdullah RN, Ossama Abbas MD. Common nail changes and disorders in older people Diagnosis and management. Canadian Family Physician February 2011:57:173-81.
4. Mark E. Williams MD. Examining the Fingernails When Evaluating Presenting Symptoms in Elderly Patients. MedScape.
5. Singh G, Haneef NS, Uday A. Nail changes and disorders among the elderly. Indian J Dermatol Venereol Leprol. 2005;71:386-92.
6. Chang P. Las alteraciones de la superficie del plato ungueal. DermatologíaCMQ 2012;10:51-9.
7. Chang P. Onychogryphosis. Our Dermatol Online. 2011;2:227-8.
8. Gac EH. Algunos cambios asociados al envejecimiento. Bolet Escuel Med. 2000;29:1-2.
9. Ruiz Álvarez A, Pinar Manzanetb JM. Valoración y prevención de los problemas de los pies del anciano. JANO. 2007;1:15-21
10. Rotés Mas MI, González Trapote L. El pie en crecimiento Rev Esp Reumatol. 2003;30:516-35.
11. Arriagada J. La historia de la "Sociedad Pro Ayuda del Niño Lisiado" y de los "Institutos Teletón". Rev Med Clin Condes. 2014;25:389-92.
12. Llontop Vite C, Temple R. Consideraciones sobre el tratamiento del Hallus Valgus. Anal Facult Med. 1967;50:e4.

Copyright by Patricia Chang, et al. This is an open access article distributed under the terms of the Creative Commons Attribution License, which permits unrestricted use, distribution, and reproduction in any medium, provided the original author and source are credited.

Source of Support: Nil, **Conflict of Interest:** None declared.

Case Report

Eccrine porocarcinoma: a case report and brief review of the literature

Rana Rafiei[1], Hojat Eftekhari[2], Arash Daryakar[3], Nahid Nickhah[2], Behnam Rafiee[4]

[1]Fellow ship of Dermatopathology, Skin Research Center, Guilan University of Medical Sciences, Razi Hospital, Rasht, Iran, [2]Skin Research Center, Guilan University of Medical Sciences, Razi Hospital, Rasht, Iran, [3]Gastrointestinal and Liver Research Center, Guilan University of Medical Sciences, Razi Hospital, Sardare Jangal St., Rasht, Iran, [4]University of Texas, MD Anderson Cancer Center, 1515 Holcombe blvd. B4.4512, Houston, TX, 77030, USA

Corresponding author: Rana Rafiei, MD., E-mail: rafieirana@yahoo.com

ABSTRACT

Eccrine Porocarcinoma is a rare, slow growing malignant tumor of eccrine sweat gland. The most common site of this tumor is lower extremity. It is characterized histologically by anaplastic cells with eccrine ductal structures which may be adjacent to a benign eccrine poroma. We present here a case of Eccrine Porocarcinoma in lower extremity, with a brief review of the literature.

Key words: Eccrine carcinoma; Malignant eccrine poroma; Porocarcinoma; Eccrine poroma

INTRODUCTION

Eccrine Porocarcinoma (EPC) was first described by Pinkus and Mehregan in 1963 [1]. It is a rare malignant tumor but a fairly common type among eccrine carcinomas [2]. EPC may arise denovo but often develops from a benign eccrine poroma [3]. It usually presents on the extremities and head in old patients as asymptomatic, reddish, ulcerated nodule or plaque [4]. In 60% of cases EPC lesions occur on the lower extremities [1]. Trauma and occupational radiation exposure may have a role in tumor development [5,6].

Special immunohistochemical (IHC) staining is essential for a definite diagnosis [1]. EPC may be purely intraepidermal or invasive. Lymphovascular invasion and distant metastasis could be seen in cases of the Invasive tumors. High mitotic rates, presence of lymphovascular invasion and tumor thickness more than 7 mm could be associated with poor prognosis [7].

CASE REPORT

A 64-year-old male was visited in dermatology outpatient clinic at Razi Hospital, Rasht, Iran. He had a dome-shaped reddish nodule without any symptoms or bleeding tendency on medial aspect of his right lower leg which first appeared 8 months ago. In addition there was an inflamed scaly erythematous nodule adjacent to it (Fig. 1).

In clinical examination there were two nodules: a 3cm × 3 cm reddish scaly firm nodule and a 1.5cm × 1.5cm soft nodule without pigmentation or pain, about 5 cm above the right medial malleus.

Our patient had no history of trauma, radiation or contact with agrotoxic agents. He was doing well and the lesions developed denovo without any preexisting lesion in this region. The patient had a history of topical antibiotic therapy with no improvement.

In physical examination there was no organomegaly or lymphadenopathy. Clinical differential diagnoses were squamous cell carcinoma, melanoma, adnexal tumors and metastatic lesions. Skin biopsy was made from two sites: the larger firm nodule and the smaller inflamed nodule.

Pathological study of the larger lesion revealed a neoplastic skin tissue with overlying elongated epidermis composed

How to cite this article: Rafiei R, Eftekhari H, Daryakar A, Nickhah N, Rafiee B. Eccrine porocarcinoma: a case report and brief review of the literature. Our Dermatol Online. 2016;7(4):391-393.

Submission: 08.02.2016; **Acceptance:** 30.05.2016

DOI:10.7241/ourd.20164.106

of interconnection strands of atypical epithelial poroid tumor cells with large vesicular nuclei, prominent nucleoli and acidophilic cytoplasm bearing cytoplasmic vacuolization, PAS positive hyaline globule like structures, cystic and duct like spaces without decapitation secretion, focal squamous differentiation with pushing border down to deep dermis. Numerous mitoses were evident. Surrounding dermis showed prominent plasmacytic infiltration (Figs. 2a and b).

In IHC study tumor cells were diffusely positive for pancytokeratin. Carcinoembryonic antigen (CEA) was positive more in ductal and cystic structures. Epithelial membrane antigen (EMA) was positive in vacuolated as well as ductal and cystic structures (Figs. 2 c-e). S100 and HMB45 were negative in tumor cells. All of these findings were more compatible with EPC. Pathologic study of the smaller lesion was more compatible with inflamed eccrine poroma.

Figure 1: Two dome-shaped reddish nodules on medial aspect of the right lower leg.

Other laboratory tests and ultrasound examinations of the abdomen and pelvis were normal. Past medical history was negative. Tumoral lesion was excised with a safe margin of 15 millimeters and skin graft was done by a plastic surgeon. Pathologic study after total excision reported tumor free margins with pushing border down to deep dermis without subcutaneous involvement, so sentinel lymph node biopsy was not done. After 6 months follow up the patient was doing well without any recurrence.

Prior to the study, patient gave written consent to the examination and biopsy after having been informed about the procedure.

DISCUSSION

Our patient was interesting because he was simultaneously involved with benign eccrine poroma and EPC on the lower extremity. EPC is a sweat gland carcinoma and arise from the lower portion of intraepidermal eccrine ducts [8]. EPC incidence is estimated between 0.005% and 0.01% of cutaneous tumors. Benign eccrine poroma is more common on the palms and soles which have the highest concentration of eccrine glands, contrary to EPC which usually occurs on the lower extremity (44%), trunk (24%) or head (18%). EPC diagnosis is dependent on either significant

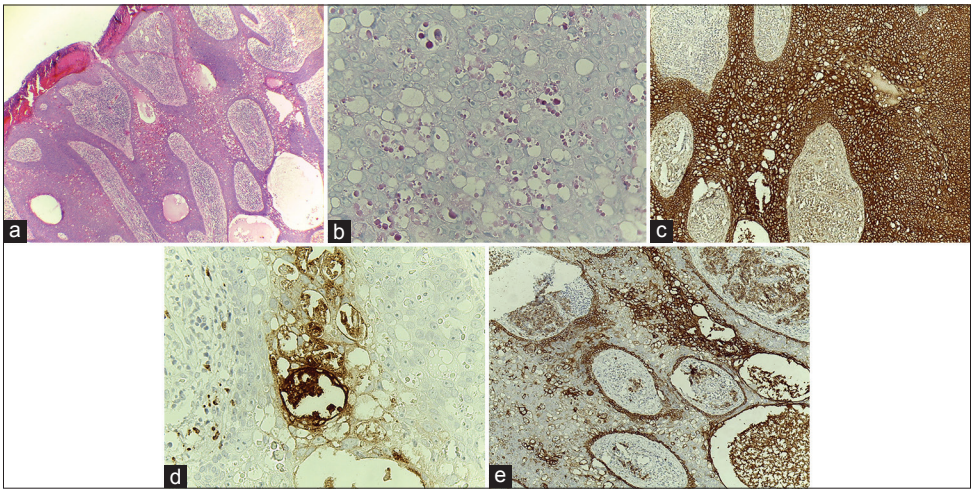

Figure 2: (a, b) Elongated epidermis composed of interconnection strands of atypical epithelial poroid tumor cells with PAS positive hyaline globule like structures, cystic and duct like spaces with pushing border down to deep dermis. (A: hematoxylin-eosin, original magnification x 10 – B: PAS staining, original magnification x 40). (c) In IHC study tumor cells were diffusely positive for pan cytokeratin. (Original magnification x 10). (d) In IHC study, CEA was positive more in ductal and cystic structures. (Original magnification x 40). (e) In IHC study, EMA was positive in vacuolated as well as ductal and cystic structures. (Original magnification x 10).

cytologic pleomorphism or an invasive growth pattern in a tumor with eccrine differentiation. Presence of eccrine type ducts is mandatory for diagnosis of EPC [7]. It often develops from or adjacent to a preexisting benign eccrine poroma with a longstanding history or even from a seborrheic keratosis [1,3,7] so all benign poromas should be totally removed (1), but in one case report, all cases developed denovo [8]. It is estimated that 18% of poromas go on to change to EPC after a mean of 8.5 years [3]. It was interesting to us because our patient did not have any preexisting lesion and both lesions (EPC and benign inflamed poroma) developed simultaneouly eight months before the first visit. EPC might be entirely epidermal or could be able to extend in to dermis; which both of them have cystic lumina [1]. The prognosis of this tumor is still questionable but recent reports have predicted more indolent behaviors [8]. Several metastatic tumors have been reported especially in primarily misdiagnosed cases [9-11]. In another report, half of the patients had inaccurate primary diagnosis [12].The most important differential diagnoses of EPC are inflamed poroma, Bowen's disease, Paget's disease, amelanotic melanoma, metastatic adenocarcinoma. IHC studies with using antibodies to CEA and EMA should be performed for detecting ductal structures and PAS staining should be done for detecting PAS-positive cuticle to rule out metastatic adenocarcinoma [1]. In a clinicopathologic study of 69 EPC cases mature well-formed eccrine ducts with eosinophilic luminal cuticle were observed in 68% of cases and immature intracytoplasmic lumina was reported in 32% of cases. Lymphovascular invasion was present in 15% of cases [7]. Squamous differentiation (5% of cases) and keratin pearl formation were reported in EPC, similarly to squamous cell carcinoma [1,7]. In case of our patient squamous differentiation, ductal formation and intracytoplasmic lumina were seen, and the tumor had pushing border in to the dermis but there were not any infiltrative growth pattern and lymphovascular invasion.

The gross size of a tumor has no significant association with the prognosis [12]. Tumor depth greater than 7 mm, mitotic rate higher than 14 mitoses per high power field, infiltrative growth pattern and lymphovascular invasion are indicators of poorer prognosis [1,7]. EPC is usually treated by surgical excision with a safe margin of approximately 2 cm [8], which is 80% curative [2]. Due to lymphatic spread of EPC, sentinel lymph node biopsy might help us to detect subclinical lymph node involvement [8] but the role of lymphadenectomy is still questionable [2]. Chemotherapy and radiation have no place in treating metastatic disease [9].

Consent

The examination of the patient was conducted according to the Declaration of Helsinki principles.

Abbreviations and Acronyms

(EPC): Eccrine Porocarcinoma; (IHC): Immuno histochemical; (CEA): Carcinoembryonic antigen; (EMA): epithelial membrane antigen; (CK): Cytokeratin; (PAS): Periodic acid-Schiff; (HMB45): Human melanoma black 45

REFERENCES

1. Brown Jr CW, Dy LC. Eccrine porocarcinoma. Dermatologic therapy, 2008;21:433-8.
2. Lozano Orella JA, Valcayo Penalba A, San Juan CC, Vives Nadal R, Castro Morrondo J, Tunon Alvarez T. Eccrine Porocarcinoma: Report of Nine Cases. Dermatol Surg. 1997;23:925-8.
3. Sawaya JL, Khachemoune A. Poroma: a review of eccrine, apocrine, and malignant forms. Int J Dermatol. 2014;53:1053-61.
4. Bottles K, Sagebiel RW, McNutt NS, Jensen B, Deveney K. Malignant Eccrine Poroma; Case Report and Review of the Literature. Cancer. 1984;53:1579-85.
5. Requena L, Sanchez M, Aguilar A, Ambrojo P, Yus ES. Malignant metastatic eccrine poroma.Dermatologica. 1990:180:177-80.
6. Ruffliex C, Ramelet A. Porocarcinoma eccrine. Dermatologica 1985:170:202-6.
7. Robson A, Greene J, Ansari N, Kim B, Seed PT, McKee PH, et al. Eccrine porocarcinoma (malignant eccrine poroma): a clinicopathologic study of 69 cases. Am J Surg Pathol. 2001;25:710-20.
8. Shiohara J, Koga H, Uhara H, Takata M, Saida T. Eccrine porocarcinoma: clinical and pathological studies of 12 **case**sJ Dermatol. 2007;34:516-22.
9. Marone U, Caracò C, Anniciello AM, Di Monta G, Chiofalo MG, Di Cecilia ML, et al. Metastatic eccrine porocarcinoma: report of a case and review of the literature.World J Surg Oncol. 2011;9:32.
10. Goel R, Contos MJ, Wallace ML. Widespread metastatic eccrine porocarcinoma. J Am Acad Dermatol. 2003;49(5 Suppl):S252-4.
11. Barzi AS, Ruggeri S, Recchia F, Bertoldi I. Malignant metastatic eccrine poroma. Dermatol Surg. 1997;23:267-72.
12. Luz Mde A, Ogata DC, Montenegro MF, Biasi LJ, Ribeiro LC. Eccrine porocarcinoma (malignant eccrine poroma): a series of eight challenging cases. Clinics (Sao Paulo). 2010;65:739-42.

Copyright by Rana Rafiei, et al. This is an open access article distributed under the terms of the Creative Commons Attribution License, which permits unrestricted use, distribution, and reproduction in any medium, provided the original author and source are credited.
Source of Support: Nil, **Conflict of Interest:** None declared.

Our Dermatology Online

Case Report

Giant solitary trichoepithelioma with desmoplasia on histopathology: An unusual finding

Sundeep Chowdhry[1], Shikha Gupta[1], Anand K Verma[2], Jagbir Singh[1], Paschal D'souza[1], Manish S Jain[3]

[1]Department of Dermatology, ESI PGIMSR, Basaidarapur, Ring Road, New Delhi-110015, India, [2]Department of Pathology, ESI PGIMSR, Basaidarapur, Ring Road, New Delhi-110015, India, [3]Department of Plastic Surgery, ESI PGIMSR, Basaidarapur, Ring Road, New Delhi-110015, India

Corresponding author: Dr Shikha Gupta, E-mail: dr_shikhaarora@yahoo.co.in

ABSTRACT

Trichoepithelioma is a well-recognized hamartoma of hair germ clinically presenting as solitary or multiple papules. Uncommonly, it may present as a large solitary lesion, termed as giant solitary trichoepithelioma (GST). A 50-year old man presented with a large, pedunculated mass over the root of nose obstructing visual field. It was excised and sent for histopathological examination. H&E staining revealed in addition to characteristic features of trichoepithelioma, a desmoplastic hypocellular stroma. After taking into account the clinical and histopathological features, a diagnosis of GST was made. This case is the first case to the best of authors' knowledge describing desmoplastic stroma in a case of GST. It is also noteworthy because it reports the largest GST described so far over the nose.

Key words: Desmoplasia; Giant solitary trichoepithelioma; Trichoepithelioma

INTRODUCTION

Giant solitary trichoepithelioma (GST) is an uncommon variant of trichoepithelioma which usually occurs on thigh and perianal region and measures several centimetres in diameter [1]. Only 18 cases of giant solitary trichoepithelioma (GST) have been described so far across the world, the largest measuring 17 × 8 cm [2]. Four of these have been reported to occur in the nasal area, the largest of which measured 3 × 2.5 cm [3].

The histopathology is similar to classical trichoepithelioma, which is characterized by horn cysts and aggregates of basaloid cells in superficial dermis. The stroma surrounding these aggregates characteristically has moderate number of fibroblasts[1]. However, hypocellular desmoplastic stroma, a unique feature of the desmoplastic variant of trichoepithelioma (DTE), has not yet been described in GST, to the best of the authors' knowledge.

The authors describe here a case of GST, the largest reported so far in the nasal region with a histological feature of desmoplastic, hypocellular stroma, which initially led to diagnostic dilemma.

CASE REPORT

A 50 year old man presented with a mass over the root of nose for past five years. It was insidious in onset, asymptomatic, initially of pea-size and gradually increased to reach the size of a tennis ball. Initially unperturbed, the patient sought medical advice when the swelling caused obstruction of vision owing to its large size. There was no history of trauma at the site. Past history and family history were unremarkable.

On examination, a well-defined pedunculated mass of size 10 × 8 × 6 cm was seen arising from the root of nose adjacent to right medial canthus having a pedicle measuring 3 × 2 cm (Fig. 1). The surface was

How to cite this article: Chowdhry S, Gupta S, Verma AK, Singh J, D'souza P, Jain MS. Giant solitary trichoepithelioma with desmoplasia on histopathology: An unusual finding. Our Dermatol Online. 2016;7(4):394-396.

Submission: 19.02.2016; **Acceptance:** 09.04.2016

DOI:10.7241/ourd.20164.107

irregular with few erosions, areas of depigmentation, hyperpigmentation, crusting and atrophic scarring. On palpation, it was non-tender, firm in consistency and on manipulation, expressed scanty serous discharge. The swelling was attached to the overlying skin though not fixed to underlying structures. There was no significant lymphadenopathy. The visual acuity, slit lamp & fundoscopic examinations were within normal limits, however due to its massive size, the lesion obstructed most of the visual field of the right eye and simultaneously resulted in deviation of the nasal tip to left side.

The differential diagnoses considered were basal cell carcinoma, large acrochordon, squamous cell carcinoma and solitary giant trichoepithelioma.

The lesion was excised under local anaesthesia and grafting was performed with donor skin taken from right thigh. The excised specimen was sent for histopathological examination. The H&E staining of the non- ulcerated base of the lesion revealed a benign adnexal tumor with uniform basaloid cells arranged in islands as well as in narrow strands (Fig. 2a). There was continuity with epidermis at few places. The surrounding stroma was characteristically desmoplastic showing hypocellular tissue with fibrosis (Fig. 2b). There was homogenously eosinophilic collagen along with mild inflammatory infiltrate in superficial and mid dermis composed predominantly of lymphocytes. Pilar differentiation with some abortive hair follicles was seen (Fig. 2c). Also several horn cysts were present. Foreign body giant cell reaction was appreciable at few sites (Fig. 2b). The margins were tumor free. Immunohistochemical (IHC) markers cytokeratin (CK) 5/6 and CK 8 showed positive results with focal and weakly positive staining for Ber-EP4 and CK 20. Thus a histopathological diagnosis of trichoepithelioma with desmoplastic features was made.

The post-operative period was uneventful and the graft was well taken up (Fig. 3). There has been no recurrence one year after the surgery.

Prior to the study, patient gave written consent to the examination and biopsy after having been informed about the procedure.

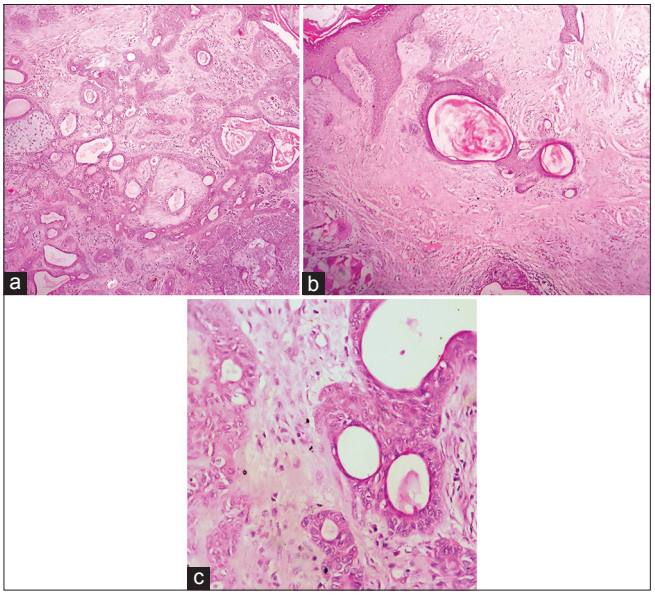

Figure 2: (a) Rare cellular areas showing basaloid cells arranged in islands and narrow strands (H&E 40x), (b) Marked desmoplasia, horn cysts, foreign body giant cell reaction seen in dermis. Focal chronic inflammatory infiltrate also seen (H&E 100x), (c) Basaloid cells in strands and forming abortive hair follicles at few places (H&E 400x).

Figure 1: A large mass arising from the root of the nose obstructing the visual field.

Figure 3: Well taken-up graft post excision.

DISCUSSION

Trichoepithelioma is a hamartoma of the hair germ which is said to represent the more mature end of the spectrum of trichoblastoma. It may present as either multiple lesions or a solitary nodule [4]. GST has been described as a rare variant of trichoepithelioma by some authors [1], while others classify it as a variant of trichoblastoma [4].

The histopathology of GST shows features of classical trichoepithelioma [4] which is characterized by islands of uniform basaloid cells with small keratinous cysts lined by stratified squamous epithelium. The stroma is prominent and loosely arranged. Epithelial structures resembling hair papillae or abortive hair follicles may be seen. Rupture of keratinous cysts with extrusion of keratinous debris may result in a small foreign- body granulomatous reaction in stroma, which was also observed in the present case. Immunohistochemical staining of trichoepithelioma reveals strong reactions for cytokeratins (CK) 5/6 and CK8. Ber-EP4 is positive focally in most trichoepitheliomas, contrasting with the usual diffuse staining in basal cell carcinoma [5].

On the other hand, DTE represents a distinct clinicopathological entity and is characterized clinically by a 3-8 mm, annular indurated lesion on face with depressed nonulcerated centre and histologically by a triad of narrow epithelial strands, horn cysts and desmoplastic stroma [1,4].

The management of GST includes excision of the lesion to confirm the diagnosis as well as to allay the discomfort associated with its large size. Local recurrence is exceptional [4]. Surgical excision with grafting was performed successfully in this patient.

It is imperative here to discuss the causes of 'desmoplasia' which is a process of fibrosis induced by activation of fibroblasts [6]. Desmoplastic changes have been reported to occur following inflammation [7], other types of tissue injury and neoplasm [6]. Inflammation is commonly associated with the multiple familial variant of trichoepithelioma, particularly the ones caused by CYLD gene mutations [8,9].

In the present case, it may be hypothesized that inflammation was in part responsible for the desmoplastic changes occurring in the stroma. The cause of the inflammation could be recurrent infections secondary to the surface erosions. However, it is difficult to conclusively comment on the same.

CONCLUSION

This case is being reported due to the unusually large size (the largest described so far over the nose and the 2nd largest GST described overall) of nasal trichoepithelioma as well as the histological evidence of hypocellular fibrotic stroma in a lesion clinically appearing as a GST. This finding has not been described previously in the literature which prompted the authors to report this case.

CONSENT

The examination of the patient was conducted according to the Declaration of Helsinki principles.

REFERENCES

1. Ahmed TSS, Priore JD, Seykora JT. Tumors of the Epidermal Appendages. In: Lever's Histopathology of the Skin (Elder DE, Elenitsas R, Johnson BL, Murphy GF, Xu G, eds), 10th edn. Philadelphia: Lippincott Williams & Williams. 2008; 857-861.
2. Oursin C, Krüger HJ, Sigmund G, Hellerich U. [MR imaging of a giant solitary trichoepithelioma of the skin]. [Article in German]. Radiologe. 1991;31:574-6. [as quoted in: Goyal S, Mahajan NC, Garg M, Goyal S. Giant Solitary Nodular Trichoepithelioma: A Case Report and Review of Literature. Arch Clin Exp Surg. 2012;1:58-60.]
3. Patrocinio LG, Damasceno PG, Patrocinio TG, Patrocinio JA. Solitary nasal trichoepithelioma. Braz J Otorhinolaryngol. 2008;74:637.
4. Calonje E. Tumours of the Skin Appendages. In: Rook's Textbook of Dermatology (Burns T, Breathnach S, Cox N, Griffiths C, eds), 8th edn. Oxford: Wiley-Blackwell. 2010; 53.8-53.10.
5. Weedon's Skin Pathology (Weedon D, ed). Chapter 33, Tumors of Cutaneous Appendages, 3rd edn. London: Churchill Livingstone-Elsevier. 2010; 760-762.
6. Ohtani H. Pathophysiologic significance of host reactions in human cancer tissue: desmoplasia and tumor immunity. Tohoku J Exp Med. 1999;187:193-202.
7. Stramer BM, Mori R, Martin P. The inflammation-fibrosis link? A Jekyll and Hyde role for blood cells during wound repair. J Invest Dermatol. 2007;127:1009-17.
8. Blake PW, Toro JR. Update of cylindromatosis gene (CYLD) mutations in Brooke-Spiegler syndrome: novel insights into the role of deubiquitination in cell signaling. Hum Mutat. 2009;30:1025-36.
9. Gray HR, Helwig EB. Epithelioma Adenoides Cysticum and Solitary Trichoepithelioma. Arch Dermatol. 1963;87:102-14.

Copyright by Sundeep Chowdhry, et al. This is an open access article distributed under the terms of the Creative Commons Attribution License, which permits unrestricted use, distribution, and reproduction in any medium, provided the original author and source are credited.
Source of Support: Nil, **Conflict of Interest:** None declared.

Our Dermatology Online

Case Report

Solitary eccrine syringofibroadenoma: a case report showing papillary tubular adenoma-like features

Toshiyuki Yamamoto[1], Keiko Miura[2], Hiroo Yokozeki[1]

[1]Department of Dermatology, Tokyo Medical and Dental University, 1-5-45 Yushima, Tokyo 113-8519, Japan, [2]Department of Pathology, Tokyo Medical and Dental University, 1-5-45 Yushima, Tokyo 113-8519, Japan

Corresponding author: Toshiyuki Yamamoto, MD, PhD., E-mail: toyamade@fmu.ac.jp

ABSTRACT

We herein describe a case showing eccrine syringofibroadenoma occurred on the dorsum of the right foot of a 46-year-old Japanese female. Histopathologic examination revealed anastomosing cords and strands of cuboidal epithelial cells extending from the epidermis to the upper dermis, with a number of well-defined ducts suggesting eccrine ductal origin. In addition, there were papillary tubular adenoma-like ductal structures lined by a few rows of epithelial cells with papillary projections into the lumen surrounded by fibrous stroma in the mid-dermis. It is of note that various histologic features showing different differentiation were seen in a single lesion of eccrine syringofibroadenoma.

Key words: Eccrine syringofibroadenoma; Papillary tubular adenoma; Foot

INTRODUCTION

Eccrine syringofibroadenoma (ESFA) is a rare tumor originated from eccrine ductal portion [1,2]. Clinically, ESFA presents a solitary papule, nodule or plaque to multiple lesions. Cases with multiple papular or macular lesions have been often associated with hereditary ectodermal dysplasia [3]. Recent findings have classified ESFA into several groups including, solitary ESFA, multiple ESFA with hydrotic ectodermal dysplasia, multiple ESFA without associated cutaneous findings, nonfamilial unilateral linear ESFA, and reactive ESFA associated with inflammatory or neoplastic dermatoses [4]. We report a case of solitary ESFA which histologically showed various degrees for sweat gland differentiation.

CASE REPORT

A 46-year-old Japanese woman presented with a solitary, 2.3×2.0 cm tumor involving the dorsum of her left foot over 10 years previously. The tumor was erosive, red-colored, and elastic hard (Fig. 1). She, as well as family members, did not have histories of ectodermal dysplasia. Laboratory examination denied diabetes mellitus. Histological examination of the totally resected tumor showed the anastomosing strands of cuboidal cells extending from the epidermis to the upper dermis (Fig. 2a). In addition, syringoma-like dilated eccrine sweat duct proliferation was also observed in the mid-dermis (Fig. 2a). The epithelial cords contained ductal structures lined by a few layers of flattened cells. Well-defines ductal structures were abundant with the proliferative cord cells (Fig. 2b). Furthermore, ductal structures were found in the mid-dermis surrounded by dense and hyalinized stroma (Fig. 2c), which were lined by two or more rows of epithelial cells that partially form papillary projections into the lumen (Fig. 2d). There was an inflammatory infiltrate of mononuclear cells in the upper dermis with an increased vascularity. Immunohistochemical study was performed by a standard avidin-biotin peroxidase technique. Formalin-fixed, paraffin-embedded sections were prepared on poly-L-lysin coated slides, dewaxed, rehydrated and rinced with phosphate buffered saline (PBS). Endogenous peroxidase activity was

How to cite this article: Yamamoto T, Miura K, Yokozeki H. Solitary eccrine syringofibroadenoma: a case report showing papillary tubular adenoma-like features. Our Dermatol Online. 2016;7(4):397-399.

Submission: 16.04.2016; **Acceptance:** 13.06.2016

DOI:10.7241/ourd.20164.108

Figure 1: Clinical appearance of the granulomatous tumor on the dorsa of the left foot.

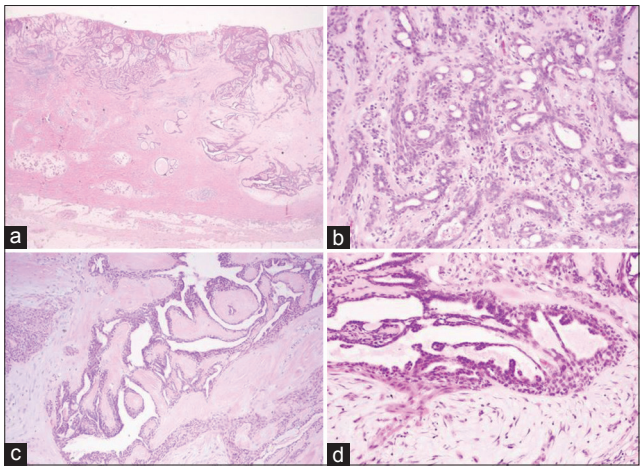

Figure 2: Histological view. (a) Lower magnification of tumors. The tumors are consisted of anastomosing epithelial cord strands. Syringoma-like dilated, eccrine duct proliferation is seen in the mid-dermis. (b) Well-defined ductal structures consisted of a few layers. (c) Proliferation of ductal structures lined by basaloid, elongated tumor cells surrounded by fibrous stroma. (d) Higher magnification. Elongated tumor cells are prominent into the lumen showing decapitation secretion.

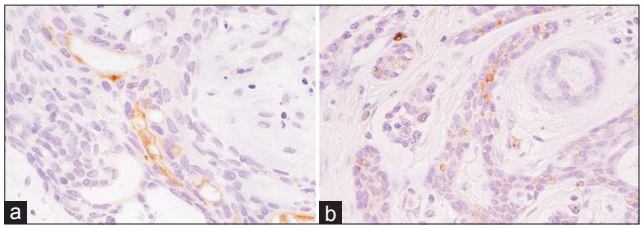

Figure 3: (a) Immunoreactive cells for CEA are seen in the ductal cells. (b) Immunoreactive cells for S-100 are seen in the epithelial cells.

blocked by treatment with 0.3 % H_2O_2 in methanol for 15 min. Sections were then incubated with the primary antibodies against S-100 and carcinoembryonic antigen (CEA) (Dakopatts, Dako Japan, Tokyo) at room temperature, followed by incubation with biotin-labeled secondary antibody, and finally avidin-biotin-peroxidase complex. Sections were developed with 3,3-diaminobenzidine solution, dehydrated, cleared and amounted. Negative controls were prepared with omitting of primary antibodies and by the substitution by isotype-matched control IgG. CEA was detected on the tumor cells of ductal wall (Fig. 3a). S-100 was detected on the cuboidal cells, whereas negative in the ductal structure of ESFA (Fig. 3b). The neoplastic cells were negative with monoclonal antibodies to desmin and vimentin.

DISCUSSION

ESFA have been reported to occur in association with inflammatory disorders such as bullous pemphigoid [5], erosive palmoplantar lichen planus [6], lepromatous leprosy [7], and diabetes mellitus [8,9]. In addition, reactive ESFA has also been reported to occur subsequently on the hyperkeratotic palms and soles [10-15]. Our patient had histories of neither those systemic diseases nor ectodermal dysplasia, but the nodule existed on the dorsum of the foot for long time, suggesting that the tumor was reactive to mechanical stimuli rather than the true neoplasm. In our case, it is of interest that papillary tubular adenoma-like differentiation was partially noted as well as typical ESFA. Papillary tubular adenoma was first described by Abenoza and Ackerman that includes both papillary eccrine adenoma and tubular apocrine adenoma [16]. The histological features are characterized by a relatively well-circumscribed dermal tumor containing numerous tubular and cystic structures with intradermal papillary projections surrounded by fibrous stroma. Thus far, more than 50 cases of ESFA have been reported, however, to our knowledge, ESFA showing papillary tubular adenoma-like lesions has not been reported. Although ESFA is an eccrine tumor, the presence of papillary projections and decapitation-like findings seen in our case favor apocrine lesions. Ishiko et al. [17] also reported the close association of both eccrine and apocrine tumor in a single tumor. On the other hand, two histopathological variants were noted in separate portion of ESFA occurred in one patient [18]. Moreover, syringoma-like dilated sweat duct was seen in the mid-dermis in our case. Sweat gland proliferation has been previously reported in a variety of inflammatory skin diseases, as well as benign and malignant neoplasms [19]. Hara et al. [20] also reported syringoma-like structures intimately associated with epithelial cords in ESFA. Thus, syringoid ductal

proliferation seems not to be rare. In this patient, ESFA occurred on the dorsum of the foot which is susceptible for chronic, recurrent stimuli. Since ESFA is suggested to occur reactively in response to mechanical stimuli, we speculate that various differentiation was also induced during repair process.

Consent

The examination of the patient was conducted according to the Declaration of Helsinki principles.

REFERENCES

1. Mascaro JM. Considerations sur les tumeurs fibro-epitheliales: le syringofibroadenoma eccrine. Ann Dermatol Syphiligr. 1963;90:143-53.
2. Lui H, Stewart WD, English JC, Wood WS. Eccrine syringofibroadenomatosis: a clinical and histologic study and review of the literature. J Am Acad Dermatol. 1992;26:805-13.
3. Hurt MA, Igra-Serfaty H, Stevens CS. Eccrine syringofibroadenoma (Mascaro): an acrosyringeal hamartoma. Arch Dermatol. 1990;126:945-9.
4. French LE. Reactive eccrine syringofibroadenoma: an emerging subtype. Dermatology. 1997;195:309-10.
5. Nomura K, Hashimoto I. Eccrine syringofibroadenomatosis in gtwo patients with bullous pemphigoid. Dermatology. 1997;195:395-8.
6. French LE, Masgrau E, Chavaz P, Saurat J-H. Eccrine syringofibroadenoma in a patient with erosive palmoplantar lichen planus. Dermatology. 1997;195:399-401.
7. Mehregan AH, Marufi M, Medenica M. Eccrine syringofibroadenoma (Mascaro): report of two cases. J Am Acad Dermatol. 1985;113:433-6.
8. Gambini C, Rongioletti F, Semino MT, Rebora A. Solitary eccrine syringofibroadenoma (or eccrine syringofibroadenomatous hyperplasia?) and diabetic polyneuropathy. Dermatology. 1996;193:68-9.
9. Utani A, Yabunami H, Kakuta T, Endo H, Shinkai H. Reactive eccrine syringofibroadenoma: an association with chronic foot ulcer in a patient with diabetes mellitus. J Am Acad Dermatol. 1990;41:650-1.
10. Starink TM. Eccrine syringofibroadenoma: multiple lesions representing a new cutaneous marker of the Schopf syndrome, and solitary non-hereditary tumors. J Am Acad Dermatol. 1997;36:569-76.
11. Alli N, Polat M, Çinar SL, Kulaçoglu S. Eccrine syringofibroadenoma. Eur J Dermatol. 2008;18:478-9.
12. Singh N, Chandrashekar L, Shakthi P, Thappa DM, Badhe BA, Sylvia MT. Reactive eccrine syringofibroadenomatosis presenting as bilateral plantar hyperkeratosis. Indian J Dermatol. 2015;60:403-5.
13. Tey HL. Characterizing the nature of eccrine syringofibroadenoma: illustration with a case showing spontaneous involution. Clin Exp Dermatol. 2009;34:e66-8.
14. Temnithikul B, Jerasutus S, Sudtikoonaseth P, Voravutinon N, Kootiratrakarn T, Kattipathananpong P. Eccrine syringofibroadenoma (ESFA): a report of two cases. Dermatol Pract Concept. 2016;6:5-8.
15. Bandyopadhyay D, Chattopadhyay S, Saha S. Reactive eccrine syringofibroadenoma on a leprous foot. Indian J Dermatol Venereol Leprol. 2015;81:64-6.
16. Abenoza P, Ackerman AB. Papillary tubular adenomas, in: Neoplasms with Eccrine Differentiation, 1st ed, Lea&Febgier, Philadelphia, London, 1990, pp353-70.
17. Ishiko A, Shimizu H, Inamoto N, Nakamura K. Is tubular apocrine adenoma a distinct clinical entity? Am J Dermatopathol. 1993;15:482-7.
18. Van Leeuwen RL, Lavrijsen APM, Starink TM. Eccrine syringofibroadenoma: the simultaneous occurrence of two histopathological variants (conventional and clear-cell type) in one patient. Br J Dermatol. 1999;141:947-9.
19. Mehregan AH. Proliferation of sweat ducts in certain diseases of the skin. Am J Dermatopathol. 1981;3:27-31.
20. Hara K, Mizuno E, Nitta Y, Ikeya T. Acrosyringeal adenomatosis (eccrine syringofibroadenoma of Mascaro): a case report and review of the literature. Am J Dermatopathol. 1992;14:328-39.

Copyright by Toshiyuki Yamamoto, et al. This is an open access article distributed under the terms of the Creative Commons Attribution License, which permits unrestricted use, distribution, and reproduction in any medium, provided the original author and source are credited.

Source of Support: Nil, **Conflict of Interest:** None declared.

Case Report

Eccrine hidradenoma of the breast: distinct pathological lesion mimicking a carcinoma

Olfa El Amine El Hadj[1], Marwa Mhiri[1], Aida Goucha[1], Jameleddine Ben Hassouna[2], Olfa Adouni[1], Khaled Rahal[2], Ahmed El May[1], Amor Gamoudi[1]

[1]Department of Pathology, Salah Azaiez Institute, Tunis, Tunisia, [2]Department of Carcinological Surgery, Salah Azaiez Institute, Tunis, Tunisia

Corresponding author: Dr. Olfa El Amine El Hadj, E-mail: olfaelamine@yahoo.fr

ABSTRACT

Eccrine hidradenoma (EH) is a rare benign cutaneous neoplasm, believed to arise from the distal excretory duct of the eccrine sweat glands. We report an exceptional lesion of eccrine hidradenoma localized to the breast and clinically mimicking a carcinoma of the breast. Aim: We aim to describe the pathological characteristics of this lesion. We report the case of a 59 year old woman. She presented with a right-sided breast nodule. Physical examination, found a mobile firm nodule retracting the skin. By ultrasound examination, the tumor was heterogeneous and measured 11 mm in great diameter. A local surgical excision of the nodule was performed. By histological exam, the diagnosis of EH was retained. The complement of immunohistochemistry was not requested. This tumor is usually confined to the dermis or subcutaneous layer without. EH of the breast is an uncommon site. Histopathological confirmation is necessary and wide excision of these tumors is the treatment of choice.

Key words: Breast; Eccrine hidradenoma; Benign tumor

INTRODUCTION

Eccrine hidradenoma is a rare benign cutaneous neoplasm, believed to arise from the distal excretory duct of the eccrine sweat glands. Its histogenesis is not well elucidated, therefore eccrine hidradenoma is also known as nodular hidradenoma, clear cell hidradenoma (CCH), eccrine acrospiroma, and eccrine sweat gland adenoma [1,2]. We report an exceptional lesion of eccrine hidradenoma localized to the breast and clinically mimicking a carcinoma of the breast. We aim to describe its pathological characteristics. Clinicians and pathologists should be aware of this lesion and do not confuse it with breast carcinomas.

CASE REPORT

We report the case of a female patient aged 59 years old with no particular disease history. She presented with a right-sided breast nodule dating of 6 months. Physical examination, found a mobile firm nodule retracting the overlying skin and measuring 10 mm in great diameter, sitting at the inferomedial inner quadrant. Left breast was normal, axillary and supraclavicular lymph nodes were free. Ultrasound examination, objectived an inferomedial right internal mammary nodule, measuring 11 mm large, heterogeneous and vascularized at the Doppler ultrasound examination. A local surgical excision of the nodule was performed. Grossly, we described a fragment measuring 2,5/1 cm, showing on cut section a well limited whitish firm nodule measuring 1 cm. Histological examination showed a well limited dermal nodule, encapsulated and not connected to the epidermis (Fig. 1). It is represented by compact lobules. The tumor cells are polygonal with eosinophilic cytoplasm and non atypic nuclei (Fig. 2). Characteristically, we noted the presence of some cavities filled with lacquered appearance. Some lobules

How to cite this article: El Amine El Hadj O, Mhiri M, Goucha A, Ben Hassouna J, Adouni O, Rahal K, El May A, Gamoudi A. Eccrine hidradenoma of the breast: distinct pathological lesion mimicking a carcinoma. Our Dermatol Online. 2016;7(4):400-402.

Submission: 23.02.2016; **Acceptance:** 15.04.2016

DOI:10.7241/ourd.20164.109

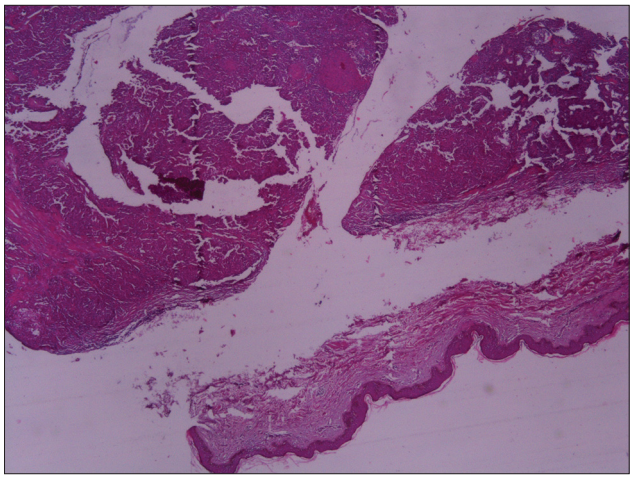

Figure 1: A well limited dermal nodule encapsulated and not connected to the epidermis.

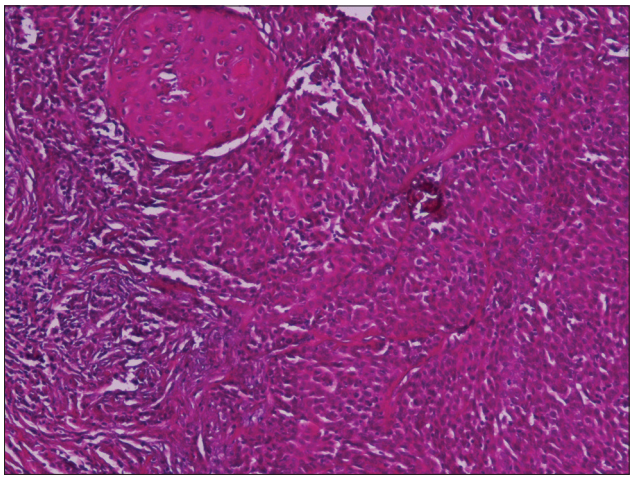

Figure 2: Tumor cells are polygonal with eosinophilic cytoplasm and non atypic nuclei.

showed squamous differenciation. The diagnosis of eccrine hidradenoma was retained. The complement of immunohistochemistry was not requested.

DISCUSSION

Eccrine hidradenoma's affected more frequently women than males [3]. It occurs commonly in middle-aged and older adults, and can be found anywhere on the body without predilection for a particular site [1]. However common reported sites of origin of CCH are face, upper extremity, axilla, trunk, thigh, the ear Lobule, scalp and pubic region [4]. Although several skin adnexal tumors arise in the breast tissue, CCH of the breast is an extremely rare entity [3,4]. It usually manifests as an asymptomatic, solitary, firm, cutaneous nodule, measuring between 5 and 20 mm in diameter. Several reports of giant eccrine hidradenoma can be found in the literature. The tumor is usually confined to the dermis or subcutaneous layer without involving the deep structures [1]. Its growth is slow, and a malignant change is rare [1].

Malignant transformation is extremely rare, and eccrine hidradenoma does not have a characteristic clinical appearance; therefore, differential diagnosis from other neoplasms, either benign or malignant, is only possible after a histopathological evaluation [1].

Usually, CCH is difficult to diagnose cytologically and in most studies, cytological diagno- sis was either unconclusive or misdiagnosed as breast tumor [4].

On histopathological examinations these tumours represent two types of cells, predominantly round cells with clear cytoplasm and polyhedral cells with rounded nucleus and slightly basophilic cytoplasm. The clear cells contain glycogen and Periodic Acid-Schiff-positive, diastase-resistant material, but no lipid. Focal cystic change also seen. Rarely some lesions show squamous differentiation which is observed in our case. Furthermore, malignant transformation is possible but extremely rare [3] and has been observed in only few cases [4]. However, neither clinical behavior nor histological features can predict malignant change. It can occur in case of inadequate excision. Compared to benign lesions malignant lesions has more tendencies to invade local tissue [3].

Although the exact mechanism of invasion by benign tumors has not yet been elucidated, benign tumor cells might invade into the deep structures along nerves such as the facial nerve and trigeminal nerve [1,2]. One report explained the mechanism of metastasis of benign tumors: the classical metastatic properties of malignant cells are the consequence of genetic abnormalities; conversely, benign metastasis can be explained by a mechanical "squeezing" of neoplastic cells into the lymph vessels after tumor overgrowth and/or trauma. Some autors speculate that the tumor cells might migrate along the lymphatics and/or by neurovascular permeation and forme a remote mass separated from the main tumor. Therefore, benign eccrine hidradenoma has a tendency to show features of a malignant tumor, such as regional metastasis and infiltration of the deep structures [1].

Immunohistochemistry (IHC) further aids in ruling other differentials. CCH shows reactivity for P63,

keratin, EMA, CEA, S-100 and Vimetin but negativity for alpha-SMA, CD-10, ER, PR [4].

Complete surgical excision with safe margins and regular follow-up is the treatment of choice for breast CCH [4].

CONCLUSION

CCH should be considered in the differential diagnosis of breast neoplasm on cytology. Awareness of these lesions on cytology is essential to prevent misdiagnosis and over treatment [4]. Histopathologic confirmation is necessary and wide excision of tumour is the treatment of choice [2].

Consent

The examination of the patient was conducted according to the Declaration of Helsinki principles. Written informed consent was obtained from the patient for publication of this article.

REFERENCES

1. Seung Hyun Oh, Chung Hun Kim, Euna Hwang. Giant Eccrine Hidradenoma Mimicking a Malignant Tumor of the Salivary Gland. Arch Surg Pathol. 2014;41):437-39.
2. Ohnishi I, Watanabe S. Histogenesis of clear cell hidradenoma: immunohistochemical study of keratin expression. J Culan Pathol. 1997;24:30-6.
3. Myreddy N, Pagatikaluva VR, Subbarayula ST, Gari SP, Gari BC. Clear Cell Hidradenoma of the Ear Lobule: An Unusual Site of Presentation. J Clin Diagn Res. 2015;9:ED20-1.
4. Sehgal S, Goyal P, Ghosh S, Mittal D, Kumar A, Singh S. Clear cell hidradenoma of breast mimicking atypical breast lesion: a diagnostic pitfall in breast cytology. Rare Tumors. 2014;6:5343. Rare Tumors 2014; volume 6:5343

Copyright by Olfa El Amine El Hadj, et al. This is an open access article distributed under the terms of the Creative Commons Attribution License, which permits unrestricted use, distribution, and reproduction in any medium, provided the original author and source are credited.

Source of Support: Nil, **Conflict of Interest:** None declared.

Case Report

Bazex-syndrome with esophageal cancer

Sebastian Boldt, Uwe Wollina

Department of Dermatology and Allergology, Academic Teaching Hospital Dresden-Friedrichstadt, 01067 Dresden, Germany

Corresponding author: Prof. Uwe Wollina, E-mail: wollina-uw@khdf.de

ABSTRACT

Skin diseases can be a first sign of internal malignancies. Acrokeratosis neoplastica or Bazex-syndrome is a rare obligatory paraneoplastic dermatosis. We report on a 51-year-old male patient who complaint about reduced physical working capacity, swelling of fingers and toes. He presented with non-itching violaceous erythemato-squamous lesions on nose, hands and feet. On examination we observed onychomadesis of finger nails. Thoracic computerized tomography disclosed a tumor mass in the distal esophagus. Endosonography with trans-esophageal fine-needle biopsy confirmed the diagnosis of esophageal squamous cell carcinoma. The knowledge of cutaneous paraneoplasias allows an earlier diagnosis of internal malignancies.

Key words: Paraneoplastic skin disease; Acrokeratosis neoplastica; Bazex-syndrome; Esophageal squamous cell carcinoma

INTRODUCTION

Human skin can be a mirror for internal disorders including malignancies. The cutaneous signs and symptoms may often precede the development of clinical tumor-associated complaints. The so-called cutaneous paraneoplasias will help to identify internal malignancies earlier [1].

We differentiate cutaneous paraneoplasias in facultative such as erythema gyratum repens and obligate such as acrokeratosis paraneoplastica. The latter is also known as Bazex-syndrome. Bazex et al. described the syndrome in 1965 in a patient with a larynx tumor [2]. In 75% of cases Bazex-syndrome develops before the diagnosis of malignancies. Its diagnosis should lead to a detailed search for cancer [3]. Associated tumors are mainly found in pharynx and larynx (48.6%), lungs (17.7%), and esophagus (10.6%) [2].

Here we report a 51-year-old male patient with Bazex-syndrome and esophageal squamous cell carcinoma (SCC).

CASE REPORT

A 51-year-old male patient was referred from the rheumatologist for diagnosis of cutaneous lesions, that developed during the last 5 months. He had a medical history for arterial hypertension, chronic obstructive pulmonary disease (COPD), and smoking. His medical family history was unremarkable.

He noticed a reduced physical working capacity. The patient also complaint about swelling of fingers and toes. He had neither arthritis nor arthralgia or morning stiffness, no dysphagia. Skin of nose, hands and feet presented with violaceous erythema and scaling (Fig. 1a and 1b). The lesions were not itching. Fingernails demonstrated onychomadesis (Fig. 2).

Laboratory investigations were unremarkable for routine lab, antinuclear antibodies, antibodies against extractable nuclear antigens, citrullin, rheumatoid factor. Neither cryoglobulins nor cold agglutinins were detected. Immune fixation was normal. Only minor iron-deficient anemia was noted.

He had no signs of vascular disorders.

How to cite this article: Boldt S, Wollina U. Bazex-syndrome with esophageal cancer. Our Dermatol Online. 2016;7(4):403-405.
Submission: 09.04.2016; **Acceptance:** 13.06.2016
DOI: 10.7241/ourd.20164.110

Figure 1: Acrokeratosis neoplastica (Bazex-syndrome). Violaceous erythemato-squamous lesions resembling psoriasis. (a) Nose. (b) Feet with edematous swelling of toes.

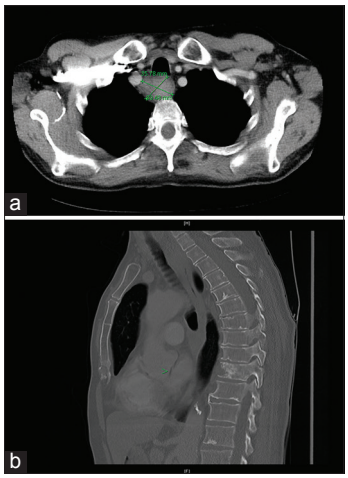

Figue 3: Computerized tomography of esophageal squamous cell carcinoma. (a) Transaxial view and (b) sagittal view. The arrow in (a) points to the tumor.

Figure 2: Hand in Bazex-syndrome with psoriasis-like cutaneous lesions and onychomadesis of nails.

Computerized tomography (CT) disclosed a tumor mass of the esophagus measuring about 36 x 39 mm (Figs. 3a and 3b). Endosonography with trans-esophageal fine-needle puncture was performed to obtain tissue for histopathology. The diagnosis of a squamous cell carcinoma (SCC) of the esophagus was confirmed.

Palliative chemotherapy or radiotherapy were suggested since the tumor could no longer been resected surgically.

DISCUSSION

Acrokeratosis neoplastica or Bazex-syndrome is a rare obligate paraneoplasia. The typical patient is older than 50 years of age. There is a male predominance. Tumors of upper airways and digestive tract are on top of malignancies associated with Bazex-syndrome [2-7]. Cutaneous symptoms resemble psoriasis with bluish or violaceous erythema and scaling, onychodystropy, and/or keratoderma. There is usually no pruritus. Typically, these lesions occur symmetrical on acral body parts like ears, nose, hands and feet [2-5]. Uncommon manifestations include flexural Bazex-syndrome, which was seen in a patient with tonsillar adenocarcinoma [6], or genital involvement [7]. Histopathology of cutaneous lesions is non-specific psoriasiform.

Our patient demonstrated onychomadesis of finger nails like the patient of Graves et al [7]. Other nail findings are subungual keratosis, yellowish discoloration, ridging, and onycholysis [2].

We detected an associated esophageal SCC. The patient had not reported any symptoms. Due to the size and topography of the tumor curative surgery was, however, no longer possible. Radiotherapy with cumulative doses between 50 to 70 Gy leads to 5-year survival rates of 23% [8].

In contrast to tumor therapy, treatment of cutaneous Bazex symptoms is of minor importance. Moisturizers and topical corticosteroids may be used but are not very effective. On the other hand, Bazex-syndrome disappears in more than 90% after successful tumor therapy [9] but in other cases Bazex-syndrome persists due to unknown reasons [10].

REFERENCES

1. Silva JA, Mesquita Kde C, Igreja AC, Lucas IC, Freitas AF, Oliveira SM, Costa IM, Campbell IT. Paraneoplastic cutaneous

manifestations: concepts and updates. An Bras Dermatol. 2013;88:9-22.
2. Bazex A, Salvador R, Dupré A, Christol B. Syndrome paranéoplasique à type d'hyperkératose des extrémités. Guérison après le traitement de l'épithélioma laryngé. Bull Soc Franc Derm Syph. 1965;72:182.
3. Bolognia JL. Bazex syndrome: acrokeratosis paraneoplastica. Semin Dermatol. 1995;14:84-9.
4. Thiel W, Plog B, Schreiber G, Wollina U. Paraneoplastic acrokeratosis (Bazex syndrome). Hautarzt. 1987;38:304-7.
5. Humphrey SR, Hussain AS, Chandran R, Wilson B, George B. Acute onset of acrokeratosis paraneoplastica (Bazex syndrome). JAMA Dermatol. 2015;151:677-8.
6. Ali M, Keir M, Dodd H, Cerio R. Flexural Bazex syndrome associated with tonsillar adenocarcinoma. J Drugs Dermatol. 2004;3:557-9.
7. Graves MS, Hardin ME, Davis LS. A case of Bazex syndrome with genital involvement. JAMA Dermatol. 2014;150:1368-70.
8. Chen DF, Yang ZY, Yin WB. Radiotherapy of 180 cases of operable esophageal carcinoma. World J Gastroenterol. 1997;3:123-6.
9. Dourmishev LA, Draganov PV. Paraneoplastic dermatological manifestation of gastrointestinal malignancies. World J Gastroenterol. 2009;15:4372-9.
10. Fasanmade A, Farrell K, Perkins CS. Bazex syndrome (acrokeratosis paraneoplastica): persistence of cutaneous lesions after successful treatment of an associated oropharyngeal neoplasm. Br J Oral Maxillofac Surg. 2009;47:138-9.

Copyright by Sebastian Boldt, et al. This is an open access article distributed under the terms of the Creative Commons Attribution License, which permits unrestricted use, distribution, and reproduction in any medium, provided the original author and source are credited.

Source of Support: Nil, **Conflict of Interest:** None declared.

Case Report

Cutis verticis gyrata secondary to cerebriform intradermal nevus

Olcay Er[1], Seray Külcü Çakmak[1], Serra Kayaçetin[2], Emine Tamer[1], Ferda Artüz[1]

[1]Dermatology Clinic, Ankara Numune Education and Research Hospital, Ankara, Turkey, [2]Pathology Clinic, Ankara Numune Education and Research Hospital, Ankara, Turkey

Corresponding author: Dr. Olcay Er, E-mail: olcayer88@gmail.com

ABSTRACT

Cutis vertisis gyrata is a rare skin disease characterized with convoluted folds and furrows formed from thickened skin of the scalp. There are primary and secondary forms of the disease. We report a 22-years-old male patient with cutis verticis gyrata associated with cerebriform intradermal nevus which represents a rare secondary form of the disease.

Key words: Cutis verticis gyrata; Secondary; Cerebriform intradermal nevus

INTRODUCTION

Cutis verticis gyrata is a rare disease, characterized by skin folds and grooves resembling the brain surface [1]. It is usually observed on the scalp but involvement of neck, legs, buttocks and scrotum have also been reported [2]. Basically, it has been classified as primary (essential and non-essential) and secondary cutis verticis gyrata. The primary essential form evolves from normal skin, on the other hand secondary forms can be associated with neoplasms, inflammatory diseases, systemic and congenital diseases [3]. Cutis verticis gyrata associated with cerebriform intradermal nevi is among the rare secondary forms. In this case report we present a case of cutis verticis gyrate secondary to intradermal nevus.

CASE REPORT

A 22-years-old healthy man was admitted to our clinic with complaints of curved areas of the scalp that he had noticed 4 years ago. There was no history of trauma and there was no similar complaints in the family. Physical examination revealed slightly hyperpigmented soft and deep folds in the right temporal region and occipital regions of the scalp, in an area of about 9x5 cm (Fig. 1). The lesions were asymptomatic with palpation. The nails and mucous membranes were normal. The examination of the neurological and ocular systems were normal. A skin biopsy was performed and the specimen was stained with hematoxylin and eosin (Fig. 2 and 3). Histopathological evaluation revealed intradermal nevi composed of nevus cells in the dermis in full thickness slot (Fig. 2). There was no cellular atypia. Solitary or clusters of nevus cells containing varying amounts of melanin in the dermis without a junctional component (Fig. 3). As a result of these symptoms the patient was diagnosed as cutis verticis gyrata secondary to intradermal nevus. The patient was referred to Plastic Surgery Clinic for total excision of the lesion.

Prior to the study, patient gave written consent to the examination and biopsy after having been informed about the procedure.

DISCUSSION

Cutis verticis gyrata; also known as pachyderma verticis girate, cutis verticis plicata and "bulldog" scalp syndrome was first described in 1837 by Jean-Louis-Marc Albert. The term cutis verticis gyratqa was first used in 1907 by Unna [4]. In 1953 Polana Butterworth was grouped cutis verticis gyrata in two groups as primary and secondary forms. The primary form is divided into two as essential and

How to cite this article: Er O, Külcü Çakmak S, Kayaçetin S, Tamer E, Artüz F. Cutis verticis gyrata secondary to cerebriform intradermal nevus. Our Dermatol Online. 2016;7(4):406-408.

Submission: 25.03.2016; **Acceptance:** 04.07.2016

DOI:10.7241/ourd.20164.111

Figure 1: The deep folds extending in the right temporal and occipital region.

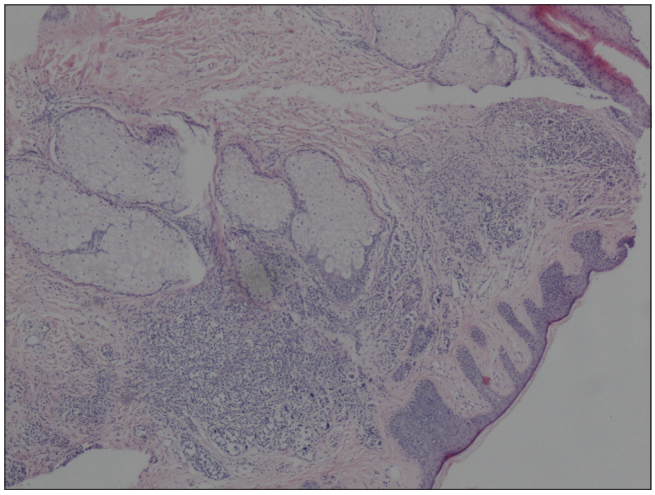

Figure 2: The nevus cell nests in all the dermis layers. (HEx40).

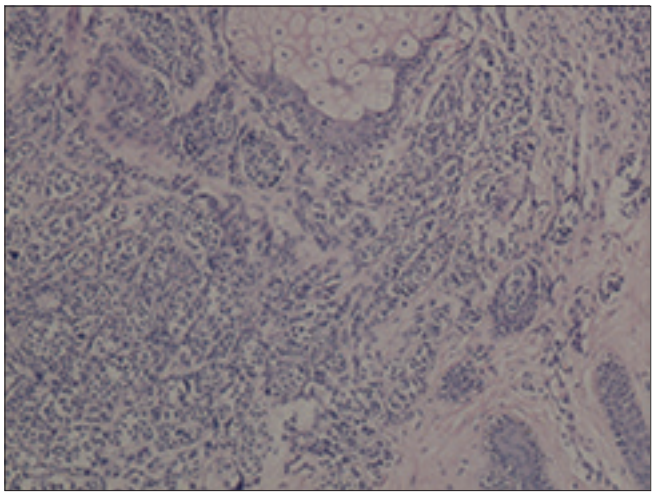

Figure 3: The nevus cell nests (HEX100).

non-essential. The primary essential form is mostly seen in men and the onset of the disease is during or after puberty [5]. It is not associated with any comorbidities. On the other hand the primary non-essential form is related with many neurological (microcephaly, mental retardation, cerebral palsy, epilepsy) or ophthalmologic (cataract, strabismus, blindness, retinitis pigmentosa) disorders [6].

The secondary form can be related with many disorders such as osteoarticular diseases (pachydermoperiostosis, acromegaly) that cause changes in the structure of the scalp, pituitary tumors, intracerebral aneurysm, amyloidosis, hypothyroidism, dermatofibroma, acanthosis nigricans, acne conglobata, cerebriform intradermal nevi, mucinosis, syphilis and diabetes mellitus type 2. Furthermore it may be associated with various syndromes such as Noonan syndrome, Beare-Stevenson syndrome, Ehlers-Danlos Syndrome, "Michelin tire baby" syndrome, Turner syndrome and fragile X syndrome [7].

Cerebriform intradermal nevus is a variant of congenital melanocytic nevus growing on the scalp. It usually occurs at birth or in the first year of life and it is more common in women [8-10]. The mechanism of the cerebriform appearance of the cerebriform intradermal nevi is not clear. It is thought to be due to changes in epidermis or multifocal hyperplasia of nevus cells [9]. It is usually seen as an assymetrical skin coloured or slightly pigmented tumor, usually localized on the parietal and occipital regions of scalp. It usually gradually expands over the years. The size may vary from 2 to 25 cm, sometimes even half or three quarters of the scalp can be affected [9]. There may be itching, tenderness, burning, recurrent infections, bleeding or musty smell [8]. The diagnosis is made by histopathological examination by observing nevus cells in the dermis. Nevus cells are well-defined slots or may be irregular and neuroid transformation may be present. The hair follicles may be normal or atrophic. Cerebriform intradermal nevus has potential for malignant melanoma transformation with a ratio of 4 to 5% [10]. Early diagnosis and surgical excision of the lesion is recommended because of malignant melanoma transformation risk and social, psychological repercussions of the disease.

In our case, a biopsy was taken from the lesion to exclude secondary causes and histopathological exmination was consistent intradermal nevus. The patient was referred to Plastic Surgery Clinic for the total excision of the lesion. It is important to recognize cutis verticis gyrate cases and to investigate the etiology. Cutis verticis gyrata secondary to cerebriform intradermal nevus has rarely been reported in the literature and the diagnosis should not be missed because of the risk of developing melanoma [10]. Our aim

in this case report is to create awareness and provide ease of diagnosis to clinicians about cerebriform intradermal nevus and cutis verticis gyrata.

Consent

The examination of the patient was conducted according to the Declaration of Helsinki principles.

REFERENCES

1. Alcántara González J, Truchuelo Díez MT, Carrillo Gijón R, Martín Diaz RM, Jaén Olasolo P. Cerebriform intradermal nevus presenting as secondary cutis verticis gyrata. Dermatol Online J. 2010;16:14.
2. Quaedvlieg PJ, Frank J, Vermeulen AH, Toonstra J, van Neer FJ. Giant ceribriform intradermal nevus on the back of a newborn. Pediatr Dermatol. 2008;25:43–6.
3. Chagn GY. Cutis verticis gyrata, underrecognized neurocutaneous syndrome. Neurol. 1996;47:573-5.
4. Polan S, Butterworth T. Cutis verticis gyrata. A review with report of seven new cases. Am J Ment Retard. 1953;57:613-31.
5. Lasser AE. Cerebriform intradermal nevus. Pediatr Dermatol. 1983;1:42-4.
6. Diven DG, Tanus T, Raimer SS. Cutis Verticis Gyrata. Int J Dermatol. 1991;30:710-2.
7. Larsen F, Birchall N. Cutis verticis gyrata: Three cases with different aetiologies that demonstrate the classification system. Australas J Dermatol. 2007;48:91-4.
8. Yazıcı AC, İkizoğlu G, Baz K, Polat A, Üstünsoy D. Serbriform intradermal nevüs. Pediatr Dermatol. 2007;24:141-3.
9. Tabata H, Yamakage A, Yamazaki S. serebriform intradermal nevus. Int J Dermatol. 1995;34:634.
10. Hayashi Y, Tanioka M, Taki R, Sawabe K, Kore-eda S, Utani A, et al. Malignant melanoma derived from cerebriform intradermal naevus. Clin Exp Dermatol. 2009;34:e840-2.

Copyright by Olcay Er, et al. This is an open access article distributed under the terms of the Creative Commons Attribution License, which permits unrestricted use, distribution, and reproduction in any medium, provided the original author and source are credited.

Source of Support: Nil, **Conflict of Interest:** None declared.

Our Dermatology Online

Case Report

Granular cell tumour: An uncommon tumour of Schwann cell origin

Anup Kumar Tiwary, Yashwant Anant Lal, Dharmendra Kumar Mishra

Department of Dermatology, Venereology and Leprosy, Rajendra Institute of Medical Sciences, Ranchi, India

Corresponding author: Dr. Anup Kumar Tiwary, E-mail: anup07tunnu07@gmail.com

ABSTRACT

Granular cell tumour is a rare soft tissue tumour of Schwann cell origin. This is usually solitary and benign but rarely can be multiple and malignant. Most commonly involved sites are tongue, skin and subcutaneous tissue but can occur at any site. Clinically, it can be misdiagnosed as dermal appendageal tumour or soft tissue tumour. Definitive diagnosis is made by histopathological examination demonstrating sheets of large polygonal or round,granular cells which are positive for S-100 on immunohistochemistry. Excisional biopsy is done as both diagnostic and curative purpose. Regular follow up is needed to look for recurrence and malignant transformation. Here we document a case of benign GCT in a 45 yrs old female.

Key words: Granular cell tumour; Schwann cell; Soft tissue tumour

INTRODUCTION

GCT is an uncommon tumour of Schwann cell origin with an incidence of 0.017%- 0.029%, first described by Abrikossoff as granular cell myoblastoma in 1926 [1-4]. It most commonly occur in tongue but can occur at any other sites presenting as an asymptomatic, solitary, flesh coloured, firm or hard nodule in middle aged persons [1]. In few cases,it can be multiple and rarely, malignant transformation has also been reported. Fine needle aspiration cytology (FNAC) or biopsy is done to obtain the sample and diagnosis is confirmed by distinctive histopathological features [2,3]. Excision with wide margin is recommended due to ill defined margins and risk of recurrence and malignancy.

CASE REPORT

A 45yrs old female presented with asymptomatic,solitary, well circumscribed, hyperpigmented, hard nodule of size 2.5 cm × 2.5 cm on right side of lower part of abdomen. One year back, it appeared as asymptomatic, skin coloured, small papule which gradually increased in size over 1 year up to the present size. Hyperkeratotic changes were seen on its surface. There was no history of trauma, infection or pre-existing dermatoses on the same site. No such family history was noted.

General physical and systemic examination was not remarkable. On local cutaneous examination, lesion was solitary, well circumscribed, hyperpigmented, dome shaped, mobile, non-tender, hard nodule (Fig. 1). There was no history of trauma, oozing or bleeding from the lesion or other cutaneous sites. Telangiectasia, ulceration or discharge was absent. Examination of mucosa, hairs, nails and teeth were also normal. Regional lymph nodes were not enlarged. All routine investigations and laboratory parameters were within normal limits and non contributory.

Excisional biopsy was done as both diagnostic and therapeutic measure. During excision, tumour was found to be ill defined and located in deep dermis with yellowish-white cut surface. It was completely excised with wide margins and specimen was sent for histopathological examination. Histopathology revealed non-encapsulated broad fascicles of tumour cells containing irregular sheets of large, round cells with indistinct borders surrounded by collagen and flattened

How to cite this article: Tiwary AK, Lal YA, Mishra DK. Granular cell tumour: An uncommon tumour of Schwann cell origin. Our Dermatol Online. 2016;7(4):409-411.
Submission: 09.02.2016; **Acceptance:** 02.04.2015
DOI:10.7241/ourd.20164.112

fibroblasts (Fig. 2). The cells had pale cytoplasm filled with abundant eosinophilic coarse granules, centrally or eccentrically placed small oval nuclei and within few cells, eosinophilic bodies with a clear halo called as 'pustule-ovoid bodies of milian' were seen (Fig. 3). Nuclear atypia, mitoses and necrosis were not seen. Based on these distinctive histopathological features, diagnosis of GCT was made. After excisional biopsy, wound was sutured with mersilk 3-0 and after healing of the wound, patient was advised to follow up biannually.

Prior to the study, patient gave written consent to the examination and biopsy after having been informed about the procedure.

Figure 1: Non-tender, well circumscribed, hyperpigmented, dome shaped, hard nodule.

DISCUSSION

GCT is a rare soft tissue tumour, previously thought to be of muscular origin but now accepted to be originated from Schwann cell due to strong positivity for S100 protein expression [2-5]. The common sites of predilection are tongue, skin and subcutaneous tissue. Other less common sites are nerve, breast, scalp, abdominal wall, back, extremities, inguinal region, lymph node, mediastinum, soft palate, orbit, salivary glands, respiratory tract, vulva and GIT [1-5] In the skin, it usually presents as single, painless, mobile, well circumscribed, slow growing, skin coloured, pink or greyish, firm or hard nodule with smooth or hyperkeratotic surface located in dermis or subcutaneous layer [1,2]. Its size varies between 5 mm-30 mm with a tendency to regress partially over the time. It is more common in females of 20-50 yrs of age group and in black population. Multiple GCT's have also been reported in less than 10% cases especially in children and may be associated with certain syndromes,malformations and carcinoma namely Noonan syndrome,Watson's syndrome, osteomuscular malformations, oculofacial alterations, neurofibromatosis, squamous cell carcinoma of esophagus, adenocarcinoma of prostate and small cell lung carcinoma [6]. Most cases show benign behaviour but on rare occasion, metastatic spread has been seen in 1-2% cases suggesting malignancy [2].

It was classified by Fanburg-Smith et al. as benign, malignant and atypical on the basis of six histopathologic criteria: increased mitotic activity (>2 mitoses/10 hpf at × 200 magnification), high nucleo-cytoplasmic ratio, nuclear polymorphism, necrosis, spindling of tumour cells and vesicular nuclei with prominent nucleoli [7]. Tumours

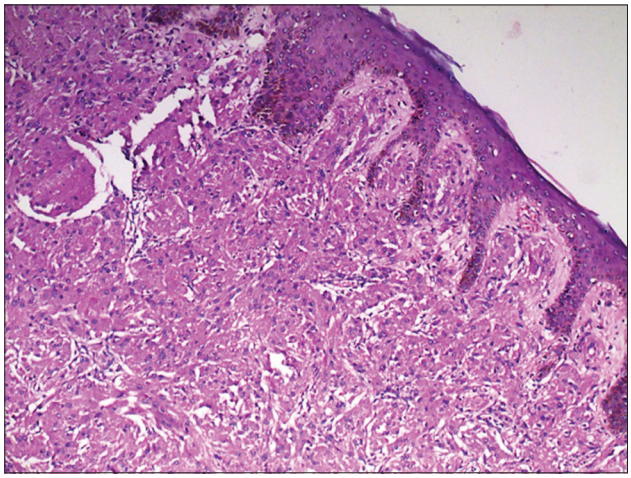

Figure 2: Broad fascicles of large, polygonal, tumor cells arranged in nests or sheets infiltrating the dermis and dermal structures. (H & E, x 10).

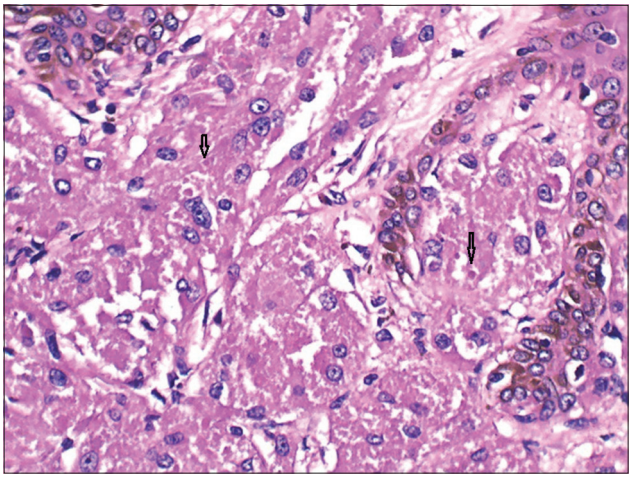

Figure 3: The tumor cells containing round-to-oval nuclei and small, eosinophilic granules uniformly filling the cytoplasm. (H & E, x 40) and eosinophilic ovoid bodies (pustulo-ovoid bodies of milian) are surrounded by a clear halo. (arrow).

fulfilling ≥3 criteria were classified as malignant, having one or two criteria as atypical and cases displaying none of the 6 criteria were classified as benign GCT.

Clinical picture is usually simulated by dermatofibroma, fibroxanthoma, lipoma, keratoacanthoma, neurofibroma, leiomyoma and leiomyosarcoma which needs to be ruled out on histopahologic evaluation [1-4]. On histopathology, H & E staining of sample of GCT of skin characteristically reveal non-encapsulated, irregular sheets of large round or polygonal cells with indistinct cytological borders containing abundantly eosinophilic, granular, pale staining cytoplasm and centrally or eccentrically located small, round or oval nuclei with fine chromatin and inconspicuous nucleoli [2-4,8]. The granularity of cytoplasm is due to massive accumulation of lysosomes which may sometimes be larger and surrounded by a clear halo called 'pustulo-ovoid bodies of Milian' [3,8]. Occasionally, cytological atypia, nuclear polymorphism and prominent nucleoli may be present. Non-specifically, epidermis is usually hyperplastic and may show downward proliferation forming horn pearl due to pseudocarcinomatous hyperplasia [5]. Other diseases which also needs to be differentiated by histopathology are rhabdomyoma, rhabdomyosarcoma, alveolar soft tissue sarcoma, schwannoma, paraganglioma, hibernoma and melanoma. IHC further aids in the correct diagnosis of GCT as granular cells are positive for S-100, neuron specific enolase, vimentin, periodic acid-schiff, inhibin-α, protein gene product 9.5 & CD 68 and negative for EMA, cytokeratin, desmin, myogenin, smooth muscle actin and HMB-45 [9].

FNAC should be done to make preoperative diagnosis and plan for wide local excision with safe margin due to poorly defined margins [3]. Further follow up is advised to the patients to look for any recurrence and malignant transformation. Adjuvant radiotherapy and chemotherapy may be tried in case of recurrent and metastatic forms of GCT respectively [10].

CONCLUSION

Having distinctive microscopic features, histopathological examination should always be done in case of any doubtful dermal soft tissue tumour to prevent the misdiagnosis of granular cell tumour and it is better be completely excised if accessible.

Consent

The examination of the patient was conducted according to the Declaration of Helsinki principles.

ACKNOWLEDGEMENTS

The authors sincerely thank Dr. Uday Khopkar for their contribution by giving valuable suggestion for the histopathological diagnosis.

REFERENCES

1. Korambayil PM. Granular cell tumour of the hand. Indian J Plast Surg. 2012;45:1602.
2. Loncar B, Marjanović K, Pauzar B, Staklenc B. Granular cell tumorclinically presented as lymphadenopathy. Coll Antropol. 2010;34:2613.
3. Chung SY, Noh WC, Jin MS, Lee SS, Koh JS. Fine needle aspiration cytology of granular cell tumor in breast -A case report. Korean J Cytopathol. 2007;8:15760.
4. Sung JW, Choi JH. Imprint cytology of granular cell tumorA case report. Korean J Cytopathol. 2007;8:17074.
5. Bielejeski TR. Granularcell tumor (myoblastoma) of the hand. Report of a case. J Bone Joint Surg Am. 1973;55:8413.
6. Golchai J, Zargari O, Paknejadi MB. Multiple granular cell tumor in a teenager: Report of a case and review of the literature. Acta Med Iran. 2004;42:22831.
7. Fanburg-Smith JC, Meis-Kindblom JM, Fante R, Kindblom LG. Malignant granular cell tumor of soft tissue: Diagnostic criteria and clinicopathologic correlation. Am J Surg Pathol. 1998;22:779-94.
8. Nasit JG, Chauhan S, Dhruva G. Granular cell tumor of hand presenting as subcutaneous nodule mimicking dermal adnexal tumor: A diagnosis by cytology. Indian Dermatol Online J. 2013;4:336
9. Weber-Cappuis K, Wildmann JJ, Kapanci Y. Histologic and immunohistochemical profiles of benign granular cell tumors. Report of 41 cases. Ann Pathol. 1995;15:198-202.
10. Kanat O, Yalcinkaya U, Akbunar T, Kurt E, Evrensel T, Manavoglu O. Gemcitabine plus paclitaxel may be a promising chemotherapy regimen for metastatic granular cell tumour. Clin Oncol (R Coll Radiol). 2008;20:93-6.

Copyright by Anup Kumar Tiwary, et al. This is an open access article distributed under the terms of the Creative Commons Attribution License, which permits unrestricted use, distribution, and reproduction in any medium, provided the original author and source are credited.
Source of Support: Nil, **Conflict of Interest:** None declared.

Case Report

Multiple eruptive dermatofibromas occuring in a patient under hemodialysis

Sarra Ben Rejeb[1], Amen Dhaoui[1], Dorra Ben Ghachem[1], Asmahane Souissi[2], Khadija Bellil[1]

[1]*Department of Pathology, FSI Hospital, La Marsa, Tunisia,* [2]*Department of Dermatology, FSI Hospital, La Marsa, Tunisia*

Corresponding author: Dr. Sarra Ben Rejeb, E-mail: sarrabenrejeb88@yahoo.fr

ABSTRACT

Dermatofibroma is a benign lesion of the skin, characterized by a fibroblastic proliferation. It is usually a solitary nodule, but some cases of patients diagnosed with multiple eruptive dermatofibromas have been reported. We herein describe another rare case of numerous ill-defined nodules occurring in a patient on long term-dialysis. Microscopic examination revealed typical features of dermatofibroma.

Key words: Multiple; Dermatofibroma; Pathology; Dermatology

INTRODUCTION

Dermatofibroma is a common benign skin tumor, most often occurring as a solitary lesion. Multiple eruptive dermatofibromas (MDF) have been reported is few cases. They are characterised by the presence of eruption reported within a short period of time of at least 15 lesions. This entity is commonly occurring on patients with underlying disease which is on more than 80% of cases an immune-mediated disease. In this report, we describe an additional case of multiple dermatofibromas.

CASE REPORT

A 70 year old woman presented with multiple (more than 15) yellowish and irregular papules and nodules developed within a period of 2 months (Fig. 1). They were distributed asymmetrically all over arms and thighs, ranging from 0.5 to 1 cm in diameter. She had medical history of chronic renal failure requiring regular dialysis since 10 years. There was no other systemic disease or any evidence of immunodeficiency.

Clinical examination revealed several firm, slightly raised yellowish nodules, ranging from 0.5 to 1 cm in diameter. The patient underwent excision-biopsy of a lesion of the arm.

Microscopic examination showed an epidermal hyperplasia with fibroblastic cell proliferation extending into the deep dermis. It was made of whorling fascicles of spindle cells with excessive collagen deposition (Figs. 2-4).

Ethics

This study was performed on human subjects; thus, all patients were aware of the presence of the study and they were fully informed about the drug and its side-effects.

DISCUSSION

Dermatofibroma (DF) is a benign fibrohistiocytic tumor which commonly occurs as a solitary lesion over lower extremities, more frequently in women than men. Few cases of multiple eruptive dermatofibromas have been reported accounting for less than 0.3% of all dermatofibromas.

Although the etiopathogeny of this entity is still unknown, they have been frequently reported in

How to cite this article: Ben Rejeb S, Dhaoui A, Ben Ghachem D, Souissi A, Bellil K. Multiple eruptive dermatofibromas occuring in a patient under hemodialysis. Our Dermatol Online. 2016;7(4):412-414.

Submission: 16.04.2016; **Acceptance:** 10.06.2016

DOI:10.7241/ourd.20164.113

Figure 1: Fistula for hemodialysis associated to Several irregular red papules in the arm.

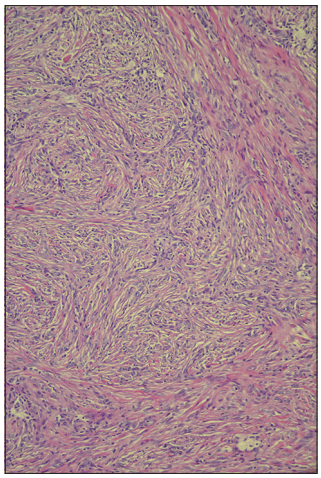

Figure 3: Fibroblastic proliferation showing storiform pattern. (HE x 200).

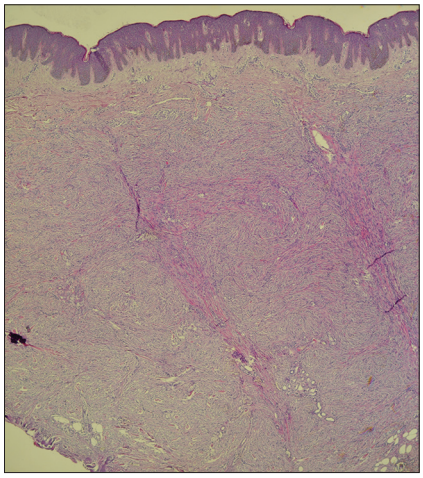

Figure 2: Epidermal hyperplasia with diffuse fibroblastic proliferation extendind in the deep dermis. (HE x 100).

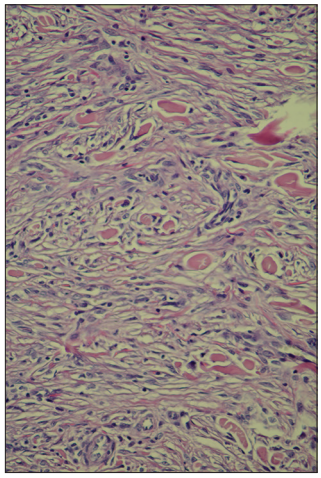

Figure 4: Fibroblastic proliferation mixed with bundles of collagen. (HE x 400).

association with autoimmune diseases or altered immune states, such as, in patients with HIV infection, lupus, chronic myelogenous leukemia, or organ transplant [1-4]. Aetiology of MDF is unknown. However, more than half of patients have underlying diseases, and more than 80% of the underlying diseases are immune mediated. MDF may be associated with autoimmune diseases or altered immune states, such as, in patients with HIV infection, lupus, dermatomyositis chronic myelogenous leukemia, or organ transplant. Also, Immunosuppressants drugs such as methotrexate and corticosteroids might cause MDF [5].

In this condition, multiple DF may be considered as a potential manifestation of an immune-mediated disease. Familial cases suggesting a genetic disorder have also been reported [6]. Our review of literature revealed that 22 of 72 subjects were otherwise healthy [7].

In this report, we describe the case of multiple DF occurring in a patient on dialysis for chronic renal failure but without any evidence of other immunosuppressive condition.

To our knowledge, this association has not been reported previously.

Many authors have defined "multiple dermatofibromas" as the presence of at least 15 lesions appeared in a short period of time [8]. Given that incipient cases might be omitted, appearance of 5 to 8 dermatofibromas in 4 months has been proposed as sufficient to establish diagnosis. They are predominantly occurring on women and usually asymptomatic lesions, but itching has been reported in some cases. Eruptive dermatofibromas generally present characteristic pathologic features

distinguishable from the sporadic cases. They are commonly showing a poorly circumscribed lesion epidermal hyperplasia, prominent bundles of collagen and a diffuse proliferation of fibroblastic cells. It may present a storiform pattern extending into the deep dermis and subcutaneous tissues.

CONCLUSION

Because of its frequent association to immune-related disease, diagnosis of multiple eruptive DermatoFibroma should always lead us to rule out an underlying systemic diseases or the possibility of immunodeficiency of the patient. However, in our case, investigations didn't reveal any evidence of systemic disease or immune deficiency. Possibility of immune disorder due to dialysis may be considered.

Consent

The examination of the patient was conducted according to the Declaration of Helsinki principles. Written informed consent was obtained from the patient for publication of this article.

REFERENCES

1. Kanitakis J, Carbonnel E, Delmonte S, Livrozet JM, Faure M, Claudy A. Multiple eruptive dermatofibromas in a patient with HIV infection: case report and literature review. J Cutan Pathol. 2000;27:54-6.
2. Yamamoto T, Sumi K, Yokozeki H, Nishioka K. Multiple cutaneous fibrous histiocytomas in association with systemic lupus erythematosus. J Dermatol. 2005;32:645-9.
3. Alexandrescu DT, Wiernik PH. Multiple eruptive dermatofibromas occurring in a patient with chronic myelogenous leukemia. Arch Dermatol. 2005;141:397-8.
4. Kovach BT, Sams HH, Stasko T. Multiple atypical fibroxanthomas in a cardiac transplant recipient. Dermatol Surg. 2005;31:467-70.
5. Huang PY, Chu CY, Hsiao CH. Multiple eruptive dermatofibromas in a patient with dermatomyositis taking prednisolone and methotrexate. J Am Acad Dermatol. 2007; 57:S81-4.
6. Yazici AC, Baz K, Ikizoglu G, Koca A, Kokturk A, Apa DD. Familial eruptive dermatofibromas in atopic dermatitis. J Eur Acad Dermatol Venereol. 2006;20:90-2
7. Her Y, Ku SH, Kim KH. A case of multiple eruptive dermatofibromas in a healthy adult. Ann Dermatol. 2014;26:539-40.
8. Baraf CS, Shapiro L. Multiple histiocytomas: report of a case. Arch Dermatol. 1970;101:588-90.

Copyright by Sarra Ben Rejeb, et al. This is an open access article distributed under the terms of the Creative Commons Attribution License, which permits unrestricted use, distribution, and reproduction in any medium, provided the original author and source are credited.

Source of Support: Nil, **Conflict of Interest:** None declared.

Case Report

Cutaneous metastasis heralding invasive ductal carcinoma of the breast in a 33 year old patient

Crystal R. Lenz, Kirk A. Middleton

18th Medical Group, Kadena Air Base, Japan

Corresponding author: Dr. Crystal R. Lenz, E-mail: Crystal.Lenz.2@us.af.mil

ABSTRACT

Cutaneous metastatic carcinoma is an unusual clinical finding, with an estimated overall incidence of 5.3%. While it is more frequently found in association with breast cancer than visceral malignancies, it is rarely identified until late in the course of the disease, and quite uncommonly as the heralding manifestation of the underlying malignancy. Because of the prevalence in breast cancer, it is important for primary care clinicians and dermatology specialists alike to be aware of this potential presentation, and able to identify such cutaneous manifestations both in the post breast reconstruction patient as well as the rare patient in which cutaneous manifestations arise as the first indication of the underlying malignancy. This case presentation is an example of the latter situation, with infiltrating ductal carcinoma (IDC) of the breast presenting as a small erythematous skin nodule in a young healthy patient with no known risk factors for breast cancer and no initial radiographic abnormalities to indicate presence of the underlying malignancy at the time of dermatologic evaluation. A review of the relevant literature is included to highlight key concepts.

Key words: Breast cancer; Cutaneous metastases; Invasive ductal carcinoma

INTRODUCTION

Breast cancer is the second most common malignancy among women (after non-melanoma skin cancer), with a lifetime risk of 13% [1,2]. Breast cancer is also the malignancy in which cutaneous metastases are most likely to manifest. While cutaneous metastases is generally regarded as a rare occurrence, with prevalence of 0.7 to 9 percent of all visceral malignancies, the documented incidence in breast cancer is as high as 23.9% [2]. Cutaneous metastasis is also typically seen as a late occurrence in the progression of metastatic disease [3], but there are exceptions to this rule as well, such as the case presented below in which the cutaneous manifestations herald the underlying disease process. Cutaneous lesions may also be the first sign of recurrence after initial treatment of malignancy, which has been more commonly reported in the literature [4]. In all cases, the ability of clinicians to identify cutaneous metastases can result in improved outcomes for patients.

CASE REPORT

Our patient is a healthy 33 year old G2P2 Caucasian female with menarche at age 12 and first live birth at age 27. She used oral contraceptive pills for a total of 12yrs, stopping in 2013 and has no personal or family history of breast cancer. She initially noticed a skin lesion on her right breast in July of 2015, described as a "bump" close to the nipple that she originally thought was a bug bite. On initial exam, approximately 10 days after presentation of the skin lesion, she was found to have a rubbery, freely mobile nodule, less than 1mm in size, located at the 2 o'clock position approximately 4cm from the right nipple. There were no changes to breast size, shape or symmetry and also no nipple discharge or other associated symptoms. A trial of topical mupirocin did not improve the skin lesion and a breast ultrasound combined with diagnostic mammogram showed no radiographic abnormality.

The lesion was re-evaluated by another clinician in October 2015, measured to be approximately 4mm

How to cite this article: Lenz CR, Middleton KA. Cutaneous metastasis heralding invasive ductal carcinoma of the breast in a 33 year old patient. Our Dermatol Online. 2016;7(4):415-418.

Submission: 03.06.2016; **Acceptance:** 26.07.2016

DOI:10.7241/ourd.20164.114

in diameter and described as a pink, raised papule (Fig. 1). A trial of topical clobetasol cream also proved to be of no benefit and, upon evaluation by the local dermatologist in early December 2015, a 4mm punch biopsy was taken for definitive diagnosis. The results of this biopsy showed dermal infiltration of atypical epithelial cells forming small clusters, with presence of glandular structures. The lesion was strongly highlighted with immunohistochemical (IHC) stain for GATA-3 which, in this clinical setting was considered specific for primary carcinoma of the breast. The pathological diagnosis was thus deemed carcinoma, consistent with infiltrating ductal breast carcinoma. It exhibited nuclear grade 2 and was shown to be estrogen and progesterone receptor positive. The patient's care was quickly transferred to a multi-disciplinary breast cancer center.

At this multi-disciplinary breast cancer center in early January 2016, repeat mammogram and ultrasound of the right breast now showed a 0.5 x 0.7 x 1.0 cm irregular hypoechoic lesion with micro-lobulated and angular margins approximately 1cm below the skin surface at the 2 o'clock position 4cm from the right nipple. The lesion demonstrated multidirectional splitting of cooper's ligaments to the skin surface and color Doppler of the lesion demonstrated increased vascularity. No other lesions or masses were identified. The following week, an MRI of the breasts offered additional visualization of the right breast mass, centered 8mm deep and 8mm caudal to the visible skin lesion, with an overall dimension of 1.4 x 2.0 x 1.4cm. The mass was noted to have the typical appearance of infiltrating ductal carcinoma, with the skin lesion representing direct extension along Cooper's ligaments to the overlying dermis.

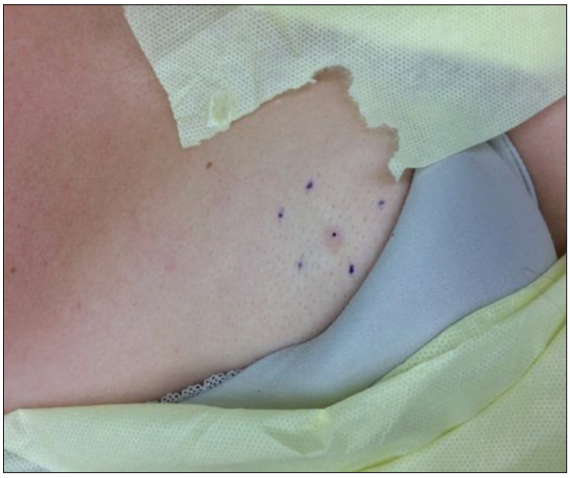

Figure 1: Clinical presentation of infiltrating ductal carcinoma cutaneous metastasis as visualized in October 2015.

After discussing options with the surgeon, the patient elected for right simple mastectomy which was completed in mid-January 2016, along with sentinel lymph node biopsy. Intra-operative pathology showed no disease in the sentinel node, but final pathologic evaluation did reveal micro-metastasis and the patient was then taken for a completion axillary dissection. Pathology from the axillary dissection showed reactive changes but no evidence of malignancy. Medical and radiation oncology evaluations in February and early March 2016 assigned staging of IIA (pT1cN1aMx); ER (40%)/PR(70%)+ HER-2 neu negative (IHC 1+); moderately differentiated; oncotypeDx score 22; s/p R simple mastectomy ALND; 1/1 SLNS & ALSND 0/52 LN's +. Though she did not meet the typical criteria for adjuvant radiotherapy (tumor over 5cm, four or more lymph nodes positive, or positive margins after surgical excision), adjuvant chemotherapy and radiotherapy were recommended based on her younger age as well as the fact that one of her lymph nodes had extracapsular extension and lymphovascular space invasion noted within the primary breast specimen. All of these facts put her at higher risk for local regional recurrence, thus she agreed to adjuvant chemotherapy and radiation treatment.

Dose dense adjuvant Chemotherapy (Doxorubicin and Cylcophosphamide) was initiated in early March 2016. She experienced mild anemia, gastroesophageal reflux and constipation, but otherwise no significant side effects from treatment. She completed her fourth and final cycle in mid-April 2016 and started Taxol treatment in early May, with plans for 28 day cycles for a total of 3 cycles of treatment. At the time of this publication, she remains cancer free and continues to tolerate treatment well.

DISCUSSION

The prevalence of cutaneous metastasis, particularly in breast cancer, warrants attention from primary care clinicians as well as dermatology specialists. Key to recognition is knowing what skin lesion characteristics should raise concern. These metastatic lesions may mimic a variety of benign dermatological conditions such as cutaneous cysts, hemangiomas, herpes zoster eruptions, alopecia, and erysipelas depending on the clinical scenario [5]. In a retrospective analysis of 4,020 patients, Lookingbill et al found nodules to be the most frequent clinical presentation in cutaneous metastases [6]. Another review by Mordenti et al

also supported this finding, reporting papules and/or nodules in 80% of patients with cutaneous metastases. They noted telangiectatic carcinomas in 3%, alopecia neoplastica in 2% and zosteriform type in 0.8% of patients [7]. The findings are slightly different in inflammatory breast carcinoma, with erythema noted in 51% of cases, a palpable mass in another 51% of cases, and breast enlargement in 43%. These skin changes started, on average, 10 weeks prior to diagnosis [8]. Nodular metastatic carcinomas can present as firm, solitary or multiple skin masses and may also be accompanied by pigmentation or irregular borders suggestive of melanoma or pigmented basal cell carcinoma [9,10]. Telangiectatic metastatic carcinoma is characterized by papulovesicular lesions with dilated vascularity on an erythematous base which is often associated with intense pruritus. Alopecia neoplastica is believed to be caused by hematogenous spread and manifests as circular areas of alopecia on the scalp which may easily be confused with other types of alopecia (i.e. Areata), but with marked induration [9]. A study out of Turkey evaluating 1,287 cases of cutaneous metastases found that 40% of those individuals with cutaneous metastases also exhibited internal metastases. The cutaneous metastasis was the first sign of malignancy in one case and diagnosed simultaneously in one other patient with breast cancer. The most common sites of cutaneous metastases were the anterior chest wall and lateral trunk [10]. The findings common to all of these studies were that the most common site for cutaneous metastasis is the anterior chest wall, and the most common clinical presentation is multiple papulo-nodular lesions.

There are numerous mechanism by which malignancies may metastasize to the skin. In the Turkish study, cutaneous metastases were noted to be the result of direct invasion in 4 cases, local metastasis in 5 cases, and distant metastasis in 6 cases. All 4 of the direct extensions and one case of local metastasis were breast cancers. The authors also noted that cutaneous metastases showed predilection for certain regions based on the type of primary malignancy, with breast and lung cancers frequently metastasizing to the chest wall and bowel, ovary and bladder cancers metastasizing to the abdominal wall [10]. One additional mechanism for cutaneous metastasis not discussed in the Turkish study is iatrogenic implantation, such as that seen in the case presented by Cho et al in which a 53 year old female with invasive ductal carcinoma presented with a metastatic skin lesion 3yrs after ultrasound guided core needle biopsy at the site. Their investigation supported the recommendation for excision of the needle tract at the time of definitive surgery for invasive breast cancers [11].

Dermal lesions are not uncommon in the breast, and imaging studies are often relied upon to rule out underlying malignancy. As our case demonstrates, breast imaging may not always reveal the underlying malignancy at the time of dermatological presentation. Standard dermal lesions are extra-parenchymal in location, lying anterior to the superficial pectoral fascia in subcutaneous fat and in the echogenic layer of deep dermis on ultrasound. Most of these lesions are benign, and not specific to the breast (such as epidermal inclusion cyst, sebaceous cyst, vascular tumors, lipoma, infections, scars and fat necrosis), making identification of cutaneous metastasis difficult. The nipple areola complex should, however, be given special attention when it comes to evaluation of dermal lesions of the breast, because this complex is unique in that it contains lactiferous ducts which extend from deep mammary glands and are associated with modified sebaceous glands. This causes lesions in this area to be intra-parenchymal in location and subject to development of abnormalities of ductal origin, including carcinoma [12]. There have been several case reports of malignancy (primarily IDC) which appeared as a benign cyst on ultrasound. Because the masses may be indistinguishable on imaging, clinical history is key and there should be a low threshold for biopsy, particularly when there is no obvious sign of infection [13].

Because imaging cannot be relied upon to definitively identify all breast malignancies, biopsy is often necessary when sufficient clinical concern is present. However, even histologic evaluation may prove difficult in some cases, particularly with cutaneous metastasis. It may be difficult to track the differentiation from the primary malignancy, as tumor cells can mimic specific dermal structures. This phenomenon was well demonstrated in the case study presented by Müller et al in which a moderately differentiated IDC of the right breast resulted in cutaneous metastasis (presenting as a reddish, indolent scalp nodule with local alopecia) which mimicked a sebaceous gland neoplasm. In this case, it was primarily the patient's past medical history of IDC in the left breast 5 years earlier that increased suspicion for breast etiology and eventually lead to the proper diagnosis [14].

Hisaoka et al offer an additional evaluation of the available literature regarding identification of sebaceous carcinoma of the breast, and emphasize the importance of IHC evaluation as a means by which to differentiate the etiology of the abnormal cells [15]. One final publication which demonstrates the role of IHC in assessment of suspicious breast lesions is a case of IDC presenting as a breast abscess, presented by Bhandari et al. This review importantly highlights the fact that invasive cancers demonstrate a lack of both basement membrane and myoepithelial cells, and places emphasis on utilization of the numerous myoepithelial markers which can help identify the invasive nature of the malignancy, with SMM-HC (smooth muscle myosin heavy chain) thought to be the most specific [16].

CONCLUSION

Clinicians should be suspicious of acute-onset, persistent, firm papulo-nodules, especially on the chest. A thorough medical history and physical exam should be accompanied by breast imaging and a low threshold for biopsy of any concerning skin lesions as described above. As this case demonstrates, there are lethal malignancies which, in the early stages, may evade all traditional forms of screening and present solely with cutaneous manifestations. The well trained evaluating clinician with low threshold for biopsy of suspicious lesions will lead to improved clinical outcomes for patients experiencing cutaneous metastases, whether early or late in the course of malignancy.

ACKNOWLEDGEMENTS

The authors would like to thank Dr. Jason Ballin for his guidance during the evaluation of this patient, as well as his professional review of this article. The views expressed in this article are those of the authors and do not necessarily reflect the official policy or position of the Air Force, the Department of Defense, or the U.S. Government.

Consent

The examination of the patient was conducted according to the Declaration of Helsinki principles.

REFERENCES

1. Krathen RA, Orengo IF, Rosen T. Cutaneous metastasis: A meta analysis of data. South Med J. 2003;96:164-7.
2. Nava G, Greer K, Patterson J, Lin KY. Metastatic cutaneous breast carcinoma: A case report and review of the literature. Can J Plas Surg. 2009;17:25-7.
3. Santiago F, Saleiro S, Brites MM, Frutuoso C, Figueiredo A. A remarkable case of cutaneous metastatic breast carcinoma. Dermatol Online J. 2009;15:10.
4. Pakula A. Recognizing malignant skin changes following breast cancer. Am Fam Physician. 992;45:1287-92.
5. Hussein MR. Skin metastasis: a pathologist's perspective. J Cutan Pathol. 2010;37:e1-20.
6. Lookingbill DP, Spanger N, Helm KF. Cutaneous metastases in patients with monastic carcinoma: A retrospective study of 4020 patients. J Am Acad Dermatol. 1993;29:228–36.
7. Mordenti C, Peris K, Concetta Fargnoli M, Cerroni L, Chimenti S. Cutaneous metastatic breast carcinoma. Acta Dermatovenerol. 2000;9.
8. Haagensen CD, ed. Diseases of the Breast. Philadelphia: WB Saunders, 1971:576-84.
9. Schwartz RA. Cutaneous metastatic disease. J Am Acad Dermatol. 1995;33:161-82.
10. Gül U, Kiliç A, Gönül M, Külcü Cakmak S, Erinçkan C. Spectrum of cutaneous metastases in 1287 cases of internal malignancies: A study from Turkey. Acta Derm Venereol. 2007;87;160-2.
11. Cho E, Kim MH, Cha SH, Cho SH, Oh SJ, Lee JD. Breast Cancer Cutaneous Metastasis at Core Needle Biopsy Site. Ann Dermatol. 2010;22:238-40.
12. Shafqat G, Khan S, Minhas K, Afzal S. Infiltrating ductal carcinoma of breast presenting as areolar dermal lesion. J Coll Physicians Surg Pak. 2012;22:323-4.
13. Moon WK, Park JM, Kim Yi. Inflammatory and infectious diseases of the breast: imaging findings. Postgraduate Radio.l 2000;20:131-242.
14. Müller CS, Körner R, Takacs FZ, Solomayer EF, Vogt T, Pfoehler C. Metastatic breast carcinoma mimicking a sebaceous gland neoplasm: a case report. J Med Case Rep. 2011;5:428.
15. Hisaoka M, Takamatsu Y, Hirano Y, Maeda H, Hamada T. Sebaceous carcinoma of the breast: case report and review of the literature. Virchows Arch. 2006;449:484-8.
16. Bhandari V, Gunasekeran G, Naik D, Yadav AK. Infiltrating ductal carcinoma of the breast presenting as breast abscess. Nat J Med Res. 2013;3:422-3.

Copyright by Crystal R. Lenz, et al. This is an open access article distributed under the terms of the Creative Commons Attribution License, which permits unrestricted use, distribution, and reproduction in any medium, provided the original author and source are credited.

Source of Support: Nil, **Conflict of Interest:** None declared.

Case Report

Keratoacanthoma of the nose coexisted with xeroderma pigmentosum in a Yemeni child: A rare case

Mohamed Ahmed Al-Kamel[1,2]

[1]*Regional Leishmaniasis Control Center (RLCC), P.O. Box 12692, Sana'a, Yemen,* [2]*Dermatology Department, Sana'a University Hospital, Sana'a, Yemen*

Corresponding author: Dr. Mohamed Ahmed Al-Kamel, E-mail: dralkamel@hotmail.com

ABSTRACT

Xeroderma pigmentosum (XP) is a rare, progressive, degenerative, autosomal recessive genodermatosis. Keratoacanthoma (KA) is a rapidly growing skin tumor, occurring primarily in older men. XP associated with KA has been infrequently reported. Here, We report a rare case of KA of the nose associated with XP in an 8-year-old Yemeni child. A KA in child should suggest consideration of XP. Early medical follow up can prevent developing, and help to diagnose tumors at a curable stage before they spread out.

Key words: Keratoacanthoma; Xeroderma pigmentosum; Squamous cell carcinoma; Leonine face; Yemen

INTRODUCTION

Xeroderma pigmentosum (XP) is a rare, progressive, degenerative, autosomal recessive genodermatosis. Clinical manifestations of XP include mild to extreme sensitivity to ultraviolet radiation resulting in inflammation and neoplasia in sun-exposed areas of the skin, mucous membranes, ocular surfaces and occasionally, neurologic degeneration [1].

XP has a prevalence of about 1:1,000,000 in the U.S and Europe, for example, with higher figures in some Asian and African countries, particularly in communities with a high degree of consanguinity. XP patients have a greater than 1000-fold increase in the incidence sunlight-associated skin cancer [1,2].

Keratoacanthoma (KA) is a rapidly growing skin tumor, occurring primarily in older men, but rarely in children. XP associated with KA is extremely rare in children.

We describe here the clinical features of XP with probable KA in an 8-year-old Yemeni child with a leonine face.

CASE REPORT

In February 26, 2016, an offspring of consanguineous parents, 8-year-old Yemeni tribal male was presented to office complaining of a big mass on the nose. On inspection, the child was mentally retarded, uncooperative and photosensitive. Dermatologic examination showed (Figs. 1 and 2); leonine face; an about 33 mm × 30 mm, well-circumscribed, hemispherical tumor on the right ala of his nose, with a rough surface, brown patches and telangiectasias (closely resembles Keratoacanthoma); xerosis, different-sizes hyper- and hypo-pigmented freckle-like macules and some spots of actinic keratosis, on the face and the other exposed parts of his body. On ocular examination photophobia, bilateral corneal opacity and conjunctivitis, were observed. History revealed that; pigmentary lesion started to develop at the first year after birth; tumor started to develop around 18 months ago; and a history of continuous sun exposure.

Diagnosis of Xeroderma pigmentosum (XP) associated with keratoacanthoma was made on the basis of clinical findings and family history.

How to cite this article: Al-Kamel MA. Keratoacanthoma of the nose coexisted with xeroderma pigmentosum in a Yemeni child: A rare case. Our Dermatol Online. 2016;7(4):419-421.

Submission: 29.02.2016; **Acceptance:** 07.06.2016

DOI:10.7241/ourd.20164.115

© Our Dermatol Online 4.2016

Figure 1: Photograph showing leonine face, keratoacanthoma mass on the right ala of the nose corneal opacity, hyper- and hypo-pigmented freckles-like macules all over the face with some spots of actinic keratosis.

Figure 2: Dry pigmented skin of trunk and lower limbs.

On the day of presentation, tumor was excised and reported histopathology.

Patient was given supplementary vitamins, had been advised to avoid sun exposure, apply sunscreen and wear sunglasses, and then referred for other systems' investigation.

DISCUSSION

Xeroderma pigmentosum (XP) was first described in 1874 by Hebra and Kaposi. In 1882, Kaposi coined the term "XP" for the condition referring to its characteristic dry, pigmented skin [1,2].

XP is a rare irreversible disorder, based on a genetic defect in the DNA repair system, transmitted in an autosomal recessive manner, diagnosed in early childhood and caused by exposure to ultraviolet radiation that shows that the skin is sensitive to light. It frequently manifests as extreme photosensitivity (usually the first sign in about 60% of patients), skin desquamation, freckle-like pigmentation in sun-exposed areas as early as two years of age (in 40% of patients), and may result in tumors on the skin and viscera, as well as damage to the eyes (in approximately 40% of XP patients). Therapeutic procedures for XP are based on the protection from sunlight exposure, and surgery is an effective therapeutic regimen for XP patients with complicated tumors. Prognosis is poor, and the majority of patients do not reach adult, but die from metastatic cutaneous malignancies [1-3].

Most clinical features are subject to amount of exposure to sunlight, the complementation group, the mutation, and some unknown factors. Factors aggravating the skin lesions include sunny weather, outdoor living, fair skin, smoking, poor accessibility of diagnostic amenities and improper shield from sunlight [1].

Keratoacanthoma (KA) is a rapidly growing cutaneous tumor that most commonly presents as a dome-shaped nodule with a central keratin-filled crater skin tumor, regarded as midway between a benign and malignant tumor or as a malignant tumor, equivalent to a highly differentiated squamous cell carcinoma (SCC). These tumors occur mostly on the head and face of middle-aged and elderly adults with fair complexions. There have been few reports of the associations of KA with XP. XP associated with KA is extremely rare in children. A KA in child should suggest consideration of XP [1-4].

To sum up, We reported a rare case of KA of nose coexisted with XP in a young Yemeni child.

CONCLUSION

Patients with xeroderma pigmentosum (XP) are likely to develop skin tumors like keratoacantoma (KA). Early medical follow up can prevent developing, and help to diagnose tumors at a curable stage before they spread out.

REFERENCES

1. Hasan S, Saeed S. Xeroderma Pigmentosum-A rare genodermatosis: Overview of Literature. Pigment Dis. 2015;2:230.
2. Kleijer WJ, Laugel V, Berneburg M, Nardo T, Fawcett H, Gratchev A, et al. Incidence of DNA repair deficiency disorders

in Western Europe: Xeroderma pigmentosum, Cockayne syndrome and trichothiodystrophy. DNA Repair (Amst). 2008;7:744-50.
3. Lehmann AR, McGibbon D, Stefanini M. Xerodermapigmentosum. Orphanet J Rare Dis. 2011;6:70.
4. Gleich T, Chiticariu E, Huber M, Hohl D. Keratoacanthoma: A distinct entity? Exp Dermatol. 2016;25:85-91.

Copyright by Mohamed Ahmed Al-Kamel. This is an open access article distributed under the terms of the Creative Commons Attribution License, which permits unrestricted use, distribution, and reproduction in any medium, provided the original author and source are credited.

Source of Support: Nil, **Conflict of Interest:** None declared.

Case Report

Basal cell carcinoma of the skin with clear cell differentation: A report of two cases

Vladimír Bartoš[1], Tatiana Bulejčíková[2]

[1]Department of Pathology, Faculty Hospital in Žilina, V. Spanyola 43, Žilina, 012 07, Slovakia, [2]Department of Dermatovenerology, Faculty Hospital in Žilina, V. Spanyola 43, Žilina, 012 07, Slovakia

Corresponding author: Vladimír Bartoš, MD, PhD, MSc., E-mail: vladim.bartos@gmail.com

ABSTRACT

Basal cell carcinoma with clear cell differentiation is extremely rare variant of this cutaneous malignancy. Here, two new cases are described in a 68-year old man arising on the scapula and in a 76-year old man arising on the face. Histologically, sharply demarcated islands consisting of the large cells with clear and focally foamy cytoplasm were found within a conventional nodular and superficial-nodular basal cell carcinoma. In both cases, clear cell population showed no mitoses, low or absent proliferative activity and was immunohistochemically positive for p53 protein. In one case, it apparently stained with alcian blue, but not with periodic acid-Shiff method, suggesting the accumulation of acid mucopolysacharides. Present results are compared with the literature data and knowledge on histogenesis of this tumor entity is discussed.

Key words: Basal cell carcinoma; Clear cell differentiation; Histological subtypes

INTRODUCTION

Basal cell carcinoma (BCC) of the skin exhibits a very heterogeneous histomorphology. This neoplasia is thought to arise from pluripotent stem cells in the epidermis that are capable of differentiating into pilosebaceous unit or sweat glands [1]. Perhaps as a consequence, there is marked histopathologic diversity among BCC, and many subtypes and variants have been described until now [1-4]. When classifying BCCs, most authors start from the growth pattern, which gives more information about biological behavior [2]. Based on it, nodular, superficial and infiltrative (morpheic) BCCs are the most common subtypes representing the vast majority of diagnosed cases [2,3]. In addition to these conventional (sometimes referred to as undifferentiated) subtypes, several unusual (differentiated) BCC variants showing a variety of specific cell lineage differentiation features have also been described [1,3,4]. However, the only proven histologic prognosticator of biologic behaviour, and therefore a key determinant of what constitutes an appropriate therapeutic strategy, is the architectural growth pattern. Thus, the microarchitecture is an essential issue, while the differentiation features need to be considered only insofar as they impact differential diagnosis [3]. A spectrum of various differentiated and unusual variants of BCC are precisely reported and illustrated in the textbook published by Kazakov et al. [4]. Amongst these, the clear cell variant is very rare entity. Histologically, it manifests apparent clear cell change in tumor tissue, the extent of which ranges from focal to striking [1,4]. Nowadays, data about its origin and pathogenesis are sparse and controversial in many aspects. Moreover, it is not definitive elucidated, whether it represents a form of true specific histogenetic differentiation, or only a degenerative phenomenon. Herein, we briefly present two patients, who were diagnosed to have this peculiar dermatopathological entity. We also tried to explain its percentage proportion in the large cohort of consecutively diagnosed cutaneous BCCs.

How to cite this article: Bartoš V, Bulejčíková T. Basal cell carcinoma of the skin with clear cell differentation: A report of two cases. Our Dermatol Online. 2016;7(4):422-426.

Submission: 06.05.2016; **Acceptance:** 06.07.2016

DOI: 10.7241/ourd.20164.116

CASE PRESENTATION

Case 1

A 76-year old male manifested with a dome-shaped ulcerated tumor on the right side of the face above zygomatic arch. On physical examination, the lesion was well-defined, light brown and 9x9 mm in size. A presumptive clinical diagnosis of BCC was made. A total surgical extirpation was carried out at the outpatients' dermatology department and a biopsy sample was send for histopathological examination. Hematoxylin and eosin (H&E) stained paraffin sections revealed a conventional nodular BCC containing large, sharply demarcated islands consisting of the large cells with clear and focally foamy cytoplasm (Fig. 1). Ocassionally, condensed nuclei were pushed to the edge giving a signet-ring appearence. In certain areas, peculiar zonation with peripheral palisading of the clear cells with their nuclei located at the opposite pole from the basement membrane have been discerned (Fig. 2). This clear cell population stained apparently with alcian blue at pH 2.3 (Fig. 3), but not with periodic acid-Shiff (PAS) method (Fig. 4), suggesting the accumulation of acid mucopolysacharides. Immunohistochemical examination revealed a similar diffuse staining with protein p53 (clone DO-7, DAKO, dilution 1: 50) in both, basaloid and clear cell components (Fig. 5). The expression of proliferative Ki-67 antigen (clone MM1, LEICA, dilution 1: 200) was low (< 10%) in the basaloid cancer nests and virtually absent in the clear cell population. No mitotic figures were found in both tumor components. Based on histopathology, a diagnosis of nodular BCC with clear cell differentiation was made. Resection margins were free of tumor and no local recurrence has been observed.

Case 2

A 68-year-old male presented with slightly protuberant cutaneous tumor on his left scapular region. The lesion was gray-brownish and measured 25x15 mm. The clinical impression was BCC. At the outpatients' department od dermatology, the tumor was partially excised (probatory biopsy) and a sample was send for histological investigation. The pathologic examination showed mixed superficial-nodular BCC that manifested all features of ordinary BCC. However, a sharply defined nests composed of the clear cells were observed within a typical basaloid tumor component (Fig. 6). The cells had striking appearance with a large

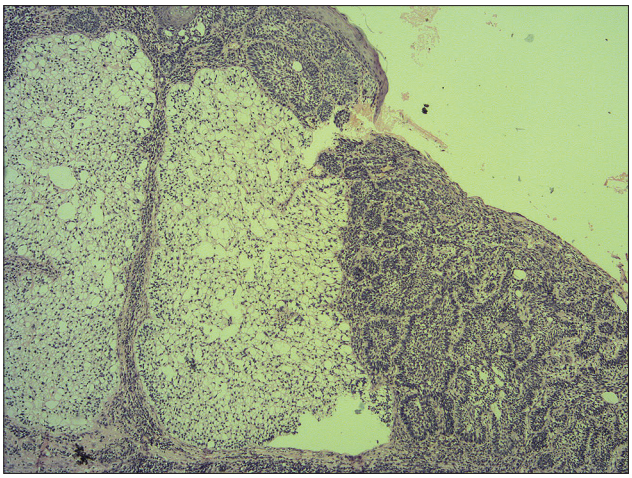

Figure 1: Case 1. A sharp demarcation between a conspicous clear cell population (left) and a conventional basaloid tumor tissue (right). (H&E, original magnification 120x).

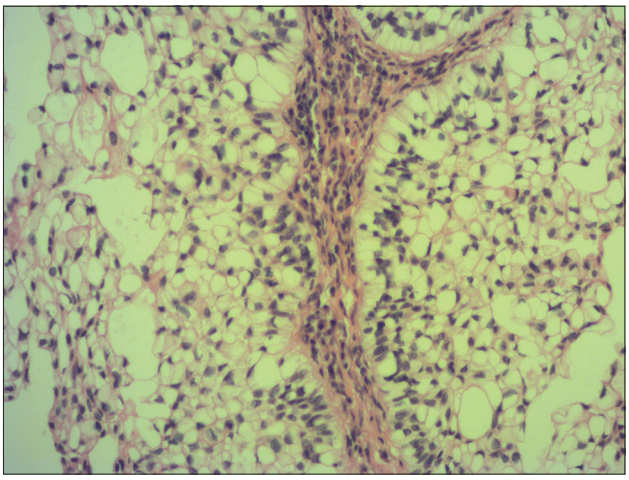

Figure 2: Case 1. Detail on peripheral palisading of the clear cells with their nuclei located at the opposite pole from the basement membrane. This feature is reminiscent of trichilemmal differentiation. (H&E, original magnification 240x).

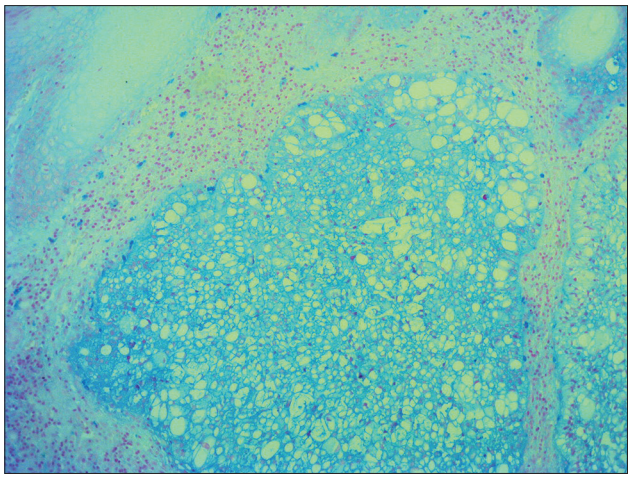

Figure 3: Case 1. Diffuse and intensive staining of the clear cell population with alcian blue. (original magnification 120x).

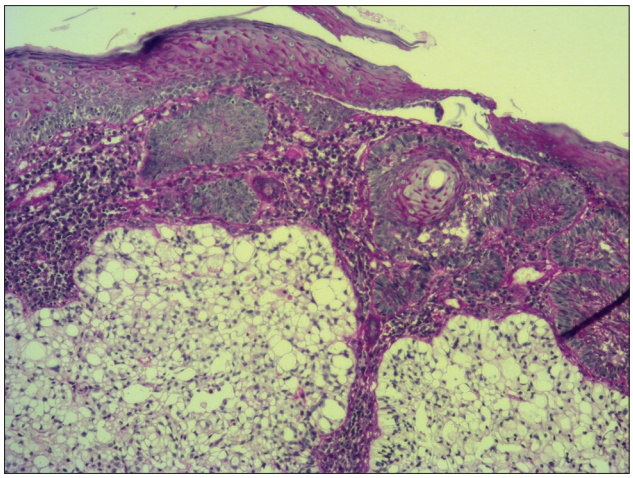

Figure 4: Case 1. Negative staining of the clear cell population with periodic acid-Shiff (PAS) method. (original magnification 120x).

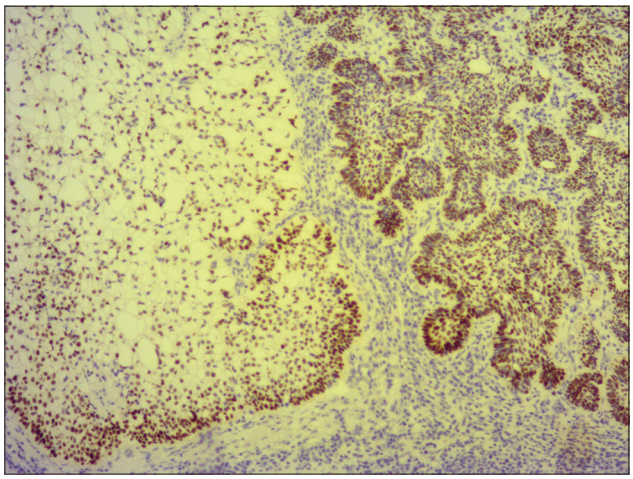

Figure 5: Case 1. Immunohistochemical reactivity for protein p53 with nearly the same extent in both, basaloid (right) and clear cell (left) tumor components. (antibody against p53, clone DO-7, original magnification 240x).

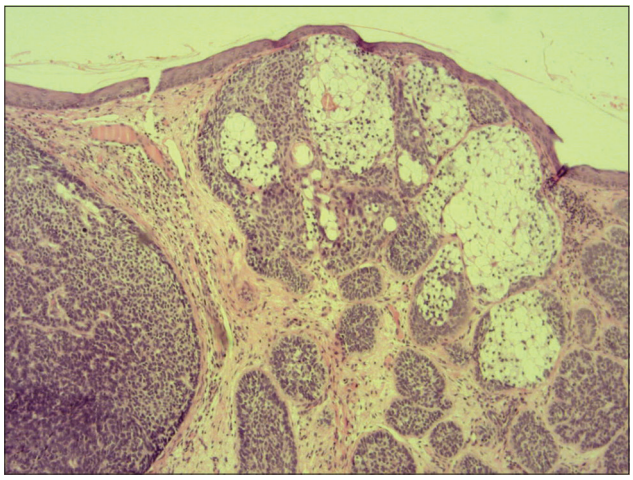

Figure 6: Case 2. Islands of the clear cells (right) within a typical basaloid tumor component (H&E, original magnification 120x).

clear cytoplasm and a small, dark nuclei. They also showed a tendency of faint palisading at the periphery in some histologic sections. No mitotic figures were seen in the clear cell component in contrast to basaloid tumor part. Immunohistochemical study showed positive staining for protein p53 (clone DO-7, DAKO, dilution 1: 50) with nearly the same extent in both components. Expression of Ki-67 antigen (clone MM1, Leica, dilution 1: 200) was less pronounced in the clear cell population (<10%) compared to conventional nodular tumor islands (20%). Unfortunatelly, other special histopathological investigations would have been worthless, because clear cell component had dissapeared during processing of the tissue specimen. A pathologic diagnosis of superficial-nodular BCC with clear cell differentiation was established. The lesion was further treated by local application of Efudix cream.

DISCUSSION

Clear cell BCC is exceedingly rare histologic variant of this common cutaneous neoplasm. In 1984, Barr & Williamson [5] were probably the first, who reported it in the medical journal and since that time, there have been approximatelly 30 cases published in the English-language literature [6]. In our current paper, we present an additional two cases. As a result of very sporadic reporting, reliable data concerning the occurrence, histogenesis and clinicopathological aspects of this BCC variant are insufficient. Therefore, we attempted to estimate its prevalence and for this purpose, we analysed all consecutive BCCs of the skin registered in the database of our Department of Pathology between January 2007 and May 2016. During this nearly 10-year period, a total of 1115 primary cutaneous BCCs were diagnosed, of which only these two ones (0.17 %) exhibited such unique microscopic feature.

In the clear cell BCC variant, the clear cell pattern may occupy all or a part of the tumor islands [1,4]. In both present cases, it comprised a minor proportion of a given cancer tissue. Our findings are consistent with those of a previous studies that reported [6-9], nodular BCC subtype has been seen in association with this phenomenon in the vast majority of the cases. Since the clear cell changes in cutaneous BCC often affect a tumor tissue only partially and probably do not have prognostic significance, someone can debate, as to

whether it would not be better to use a term „clear cell" only as additional description, for example superficial or nodular BCC with clear cell differentiation (pattern). In our patients, such terminology was preferred. A designation clear cell BCC *per se* does not provide an information on growth pattern, that is much more important for the clinicians.

The clear cell population in BCC usually contains intracytoplasmic glycogen vacuoles, that often cause peripheral displacement of the nucleus, giving them a signet ring appearence in some cases [1]. However, histochemical observations between cases have been inconsistent. While periodic acid-Shiff (PAS) staining with or without diastase has been positive for glycogen in some cases [5,7,10,11], other authors revealed only sparse or no PAS positivity [6,8,9,12,13], such as in the current case. In addition, Kim et al. [10] noted the presence of sialomucin deposition and they hypothesized, sialomucin in clear cell BCC might be obtained as one of the products of tumor glandular differentiation. Even in the current study, Case 1 showed intracellular acummulation of acid mucopolysacharides, a finding that may support this idea. Electron microscopic studies have also been variable, as some have found the large intracellular vacuoles to be membrane bound [13,14], while the others have not [7,9,12]. Therefore, it is not suprising, an origin of the clear cell population in BCC is not fully understood. Barr & Williamson [5] initially suggested, its pathogenesis was related to trichilemmal differentiation. However, many investigators subsequently considered the large vacuoles, which occupied the cytoplasm on electron microscopy, as phagolysomes or end-stage products of intracellular organelles [7,13,14]. Thus, clear cell changes were later thought to be a degenerative phenomenon. Nevertheless, an alternative view is inclined to believe that this finding recapitulates outer root sheath (trichilemmal) differentiation due to characteristic palisading of peripherally located clear cells [3,4]. This feature was visible in both our cases, too. Furthermore, because the clear cell islands were coherent and sharply demarcated from the surrounding cancer tissue, that did not show any regressive changes, we are more likely to think, it is not a degenerative phenomenon but a form of a special histogenetic differentiation. Since both, conventional basaloid and clear cell population shared a similar pattern of p53 expression, molecular alterations of p53 gene probably play a central role in the development of both tumor parts.

In conclusion, despite the rarity in a routine dermatopathological practice, due to potential diagnostic difficulties, the pathologist should be aware of this unusual BCC variant. Especially in a limited biopsy specimen containing little or no conventional areas of BCC, distinguishing the tumor from another skin neoplasms with clear cell pattern (e.g., sebaceous carcinoma, hidroadenocarcinoma or metastatic renal cell carcinoma) may be difficult. In such cases, a possible diagnosis of BCC with clear cell differentiation should be kept in mind.

Consent

The examination of the patients was conducted according to the Declaration of Helsinki principles.

ACKNOWLEDGMENTS

The authors would like to thank Dr. Pokorný Dušan, Dr. Jančovičová Viktória and Ms. Hanajíková Taťána for their outstanding educational and technical assistance.

REFERENCES

1. Elder DE, Elenitsas R, Johnson BL jr, Xu G. *Lever's* Histopathology of the Skin. Tenth Edition. Wolters Kluwer Health/Lippincott Williams & Wilkins, Philadelphia. 2009. 1408 pages. ISBN 978-0781773638
2. Vantuchová Y, Čuřík R. Histological types of basal cell carcinoma. Scripta Medica (Brno) 2006; 79: 261-270.
3. Crowson AN. Basal cell carcinoma: biology, morphology and clinical implications. Mod Pathol 2006; 19: S127-S147.
4. Kazakov DV, Michal M, Kacerovska D, McKee PH. Cutaneous Adnexal Tumors. Wolters Kluwer Health/Lippincott Williams & Wilkins, Philadelphia, 2012. 814 pages. ISBN 978-1605478548
5. Barr RJ, Williamson C. Clear-cell basal cell carcinoma. Arch Dermatol 1984; 120:1086.
6. Sarma DP, Olson D, Olivella J et al. Clear cell basal cell carcinoma. Pathol Res Int 2011; 2011:386921.
7. Barnadas MA, Freeman RG. Clear cell basal cell epithelioma: light and electron microscopic study of an unusual variant. J Cutan Pathol 1988; 15: 1-7.
8. Forman SB, Ferringer TC. Clear-cell basal cell carcinoma: differentation from other clear cell tumors. Am J Dermatopathol 2007; 29: 208-209.
9. Starink TM, Blomjous CEM, Stoof TJ et al. Clear cell basal cell carcinoma. *Histopathology* 1990; 17: 401-405.
10. Kim DY, Cho SB, Chung KY, Kim YC. Clear cell basal cell carcinoma with sialomucin deposition. Yonsei Med J 2006; 47: 870-872.
11. Garg C, Agarwal A, Siddiqui B, Faridi S. Clear cell basal cell carcinoma – Un unusual entity in indian male. Ind J Med Report 2015; 4: 66-70.
12. Reck A, Pathmanathan T, Lagnado R, Parham DM. Clear cell basal carcinoma: an unusual variant. *Histopathology* 1996; 29: 390-391.

13. Oliver GF, Winkelmann RK. Clear-cell, basal cell carcinoma: histopathological, histochemical, and electron microscopic findings. J Cutan Pathol 1988; 15: 404-408.
14. Barr RJ, Alpern KS, Santa Cruz DJ, Fretzin DF. Clear cell basal cell carcinoma: an unusual degenerative variant. J Cutan Pathol 1993; 20: 308-316.

Copyright by Vladimír Bartoš, et al. This is an open access article distributed under the terms of the Creative Commons Attribution License, which permits unrestricted use, distribution, and reproduction in any medium, provided the original author and source are credited.
Source of Support: Nil, **Conflict of Interest:** None declared.

Our Dermatology Online

Case Report

Pigmented basal cell carcinoma: A rare clinical variant treated with excision and grafting

Manjunatha Puttaiah[1], Deekshith Rajmohan[2], Shishira R. Jartarkar[1]

[1]*Department of Dermatology, Venereology and Leprosy, KVG Medical College and Hospital, Kurunjibhag, Sullia, India,*
[2]*Department of Otorhinolaryngology, KVG Medical College and Hospital, Kurunjibhag, Sullia, India*

Corresponding author: Dr. Shishira R. Jartarkar, E-mail: dr.shishira@gmail.com

ABSTRACT

Basal cell carcinoma (BCC) is a most common malignant tumour of skin. It develops on sun-exposed skin of lighter skinned individuals. It is a slow growing, locally invasive tumor. It is rare in dark skin because of the inherent photoprotection of melanin and melanosomal dispersion. The frequency of pigmented variant of BCC can reach up to 6% of total BCC in Hispanics. A 62yr old female came with the complaint of hyperpigmented plaque over the right lateral wall of the nose at the osseo-cartilagenous junction since 2yrs with evidence of central ulceration and bleeding. A wide local excision was planned with 5mm margins and covered with a full thickness graft obtained from the right retroauricular area. Post operation photographs taken. BCC is the most common non-melanoma skin cancer in the world. Though, pigmented BCC is the rare variant, it is becoming increasingly common in Asian population. UV radiation is the most important preventable risk factor for BCC. With increasing awareness and advent of newer treatment modalities, better cosmetic outcome with improved survival are expected.

Key words: Pigmented BCC; Locally invasive; Wide local excision

INTRODUCTION

Basal cell carcinoma (BCC) is the most common skin cancer in humans. The malignancy accounts for 75% of all non-melanoma skin cancers. It develops on sun-exposed skin of lighter skinned individuals [1]. It is a slow growing, locally invasive tumor. It is rare in dark skin because of the inherent photo protection of melanin and melanosomal dispersion. Pigmented BCC is a rare clinical and histological variant of BCC that exhibits increased pigmentation. The frequency of pigmented BCC varies, being 6% of all the BCCs [2].

CASE REPORT

A 62year old female came with the complaint of asymptomatic darkly pigmented lesion over the right side of the nose since one year, initially small in size, measuring about 0.2x0.2cms, gradually progressed to the present size of 1x1cms. Patient gives history of spontaneous bleeding from the lesion. No history of significant loss of weight or appetite. On examination, a solitary, oval, well-defined, hyperpigmented plaque, measuring about IxI cm with irregular margins, surface showing area of ulceration, present over the right lateral wall of the nose, above the right ala (Fig. 1). No regional lymphadenopathy was noted. A differential diagnosis of pigmented basal cell carcinoma, keratoacanthoma, malignant melanoma was considered. A wide local excision with full thickness graft was planned (Fig. 2). Under aseptic precautions, after local infiltration of the lesion, an elliptical incision was placed with 0.5cm margin all around the lesion and the tumor was removed in toto and sent for histo-pathological examination. A same sized full thickness graft was harvested from the right post auricular area and placed over the recipient site and sutured with no tension (Fig. 3). The margins of the biopsy specimen were marked and sent for histo-pathological examination which revealed that the tumor was arising near the basal layer consisting

How to cite this article: Puttaiah M, Rajmohan D, Jartarkar SR. Pigmented basal cell carcinoma: A rare clinical variant treated with excision and grafting. Our Dermatol Online. 2016;7(4):427-430.

Submission: 04.05.2016; **Acceptance:** 25.07.2016

DOI: 10.7241/ourd.20164.117

of large and small nests of basaloid cells (tumor cells) with peripheral palisading. The stroma showed the presence of melanophages and melanin interspersed amongst tumor cells along with lymphoplasmacytic infiltrate is seen. The tumor is seen extending from entire dermis upto the muscle. The lateral and deeper resected margins were free of tumor (Fig. 4).

At day 7, the sutures were removed and the graft was taken up well (Fig. 5). Since, the resected border was free of the tumor residues, no further therapeutic intervention was undertaken and patient followed up regularly.

Prior to the study, patient gave written consent to the examination and biopsy after having been informed about the procedure.

Figure 1: Hyper-pigmented plaque over right side of the nose.

Figure 2: The tumor site after wide local excision.

Figure 3: Intraoperative photograph showing the graft placement after wide excision of the tumor.

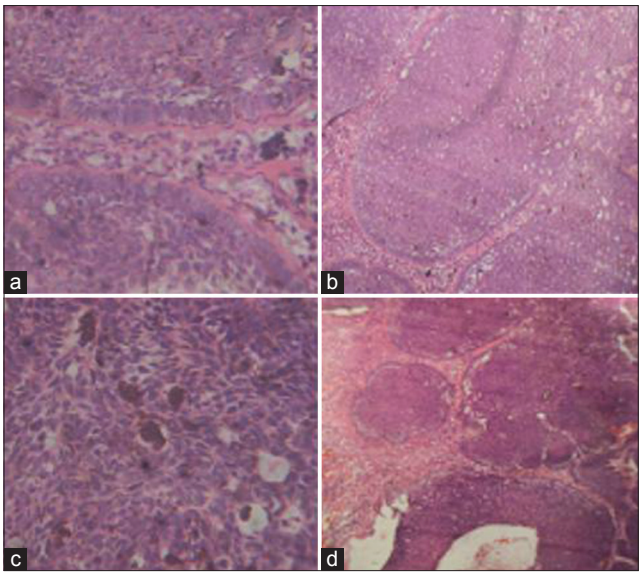

Figure 4: a) Palisaded arrangement of tumor cells (x40), b) tumor nests with melanin pigment interspersed among tumor cells (x10), c) basaloid tumor cells with melanin and melanophages (x40), (d) tumor nests with peripheral palisading of the basaloid cells (x4).

Figure 5: Postoperative day 8 with good take-up of the graft.

DISCUSSION

BCC was first described in the year 1827 by Jacob [1]. The Basal cell carcinoma is a common malignant neoplasm of the skin, accounting for 75% of all the non-melanoma skin cancers. Pigmented basal cell carcinoma is a clinical and a histological variant of BCC which is characterized by brown or black pigmentation, comprising of 6% of total BCCs [2]. The tumor predominantly occurs on the sun-exposed areas of the skin. It is relatively rare in dark-skinned individuals. Head and neck is the most common site seen in about 85% of the patients. In the remaining 15%, the tumor develops on the shoulder, back or chest. BCC is the most important malignant tumor involving the lower eyelid and as at other sites, exposure to sunlight is an important risk factor [3].

Ultraviolet (UV) radiation induces mutations in certain genes such as p53 gene for BCC and squamous cell carcinoma (SCC) and the patched (PTCH1) gene for BCC. It also causes alteration in substitution of the base at di-pyrimidine sites and induces inflammation via cyclooxygenase-2 pathway [4]. The other risk factors include exposure to ionizing radiations, arsenic and coal tar derivatives [5].

BCC is derived from the basaloid epithelium located in the follicular bulges, anagen hair bulbs and the follicular matrix cells. In adults, the cell of origin is believed to be pluripotent progenitor epithelial cells, resulting in diversity of histological patterns of BCC [6].

The clinical picture of BCC is variable. It can present as a papulonodular lesion with pearly translucent edge, as a plaque with variable pigmentation, as an ulcerated destructive lesion (rodent ulcer), an erythematous plaque or a cystic nodule. Aggressive tumors are larger with more frequent ulceration and can be locally destructive [7].

Histopathologically, BCCs share the following common features – predominant cell type is basaloid, with specialized stroma, predominant palisading of the lesional nucWlei and clefting artefact between epithelium and the stroma. Various morphological and histological subtypes have been defined. These include nodular (solid), micronodular, cystic, superficial (superficial multifocal), pigmented, adenoid, infiltrating, sclerosing, keratotic, infundibulo-cystic, metatypical, basosquamous and fibroepitheliomatous. The most common variant is nodular type, characterized by nodular masses of basaloid cells extending into the dermis. The tumor cells resemble those of basal layer of the epidermis, having relatively small amount of cytoplasm. The nuclei of the tumor cells are compact, darkly staining and closely set. The cytoplasm stains poorly and cell margins are indistinct. The characteristic feature is peritumoral lacunae or retraction clefts. Pigmented BCC is a variant of BCC showing increased melanin pigments which are produced by benign melanocytes colonizing the tumor [8]. Functional melanocytes are scattered throughtout the islands of tumors, with numerous melanophages in the stroma. There are melanosomes complexes in the tumor cells, as a result of repeated phagocytosis of melanosome containing tumor cells that have undergone apoptosis.

The primary treatment option for BCC is excision with atleast 3-6mm margins for small and well delineated tumors, as this achieves satisfactory tumor clearance of about 84.9%. Surgical defects are repaired with primary closure, grafts, flaps or left to heal by secondary intention [9].

The other modalities of treatment include curettage and electrodessication, radiotherapy, Mohs' micrographic surgery (highest cure rate and greater tissue conservation), cryosurgery, photodynamic therapy and interferons. The topical modalities for low risk BCCs include 5-fluorouracil and imiquimod creams. Also, the patient should be advised regarding sunprotection, protective clothing and regular sunscreens [4].

CONCLUSION

BCC is the most common non-melanoma skin cancer in the world. Though, pigmented BCC is the rare variant, it is becoming increasingly common in Asian population. UV radiation is the most important preventable risk factor for BCC. With increasing awareness and advent of newer treatment modalities, better cosmetic outcome with improved survival are expected.

REFERENCES

1. Crowson AN. Basal cell carcinoma: Biology, morphology and clinical implications. Med Pathol. 2006;19:S127-47.
2. Deepadarshan K, Mallikarjun M, Abdu NN. Pigmented basal cell carcinoma: A clinical variant, report of two cases. J Clin Diagc Res. 2013;7:3010-11.
3. Saldanha P, Shantala PR, Upadhaya K. Cutaneous basal cell carcinoma: A morphological spectrum. Arch Med Health Sci. 2015;l3:24-8.

4. Nouri K, Ballard CJ, Patel AR, Brasie RA. Basal cell carcinoma. In: Nouri K, editor. Skin Cancer, New York Mc Graw Hill. 2007;61-85.
5. Panda S. Non melanoma skin cancer in India: Current Scenario. Indian J Dermatol. 2010;55:373-8.
6. Dourmishev LA, Rusinova D, Botev I. Clinical variants, stages, and management of basal cell carcinoma. Indian Dermatol Online J. 2013;4:12-7.
7. Annessi G, Baliva G. Basal cell and squamous cell carcinomas. Clinico-histological features. Ann Ist Super Sanita. 1996;32:29-36.
8. Elder DE, Elenitsas R, Johnson BL, Murphy GF, Xu X. Basal cell carcinoma. In, Eider DE, editor. Histopathology of the skin. 10th ed. Philadelphia: Lippincott Williams and Wilkins. 2009;823-35.
9. Goh BK, Ang P, Wu YJ, Goh CL. Characteristics of basal cell carcinoma amongst Asians in Singapore and a comparison between completely and incompletely excised tumors. Int J Dermatol. 2006;45:561-4.

Copyright by Manjunatha Puttaiah, et al. This is an open access article distributed under the terms of the Creative Commons Attribution License, which permits unrestricted use, distribution, and reproduction in any medium, provided the original author and source are credited.

Source of Support: Nil, **Conflict of Interest:** None declared.

Case Report

Epidermoid carcinoma involving on chronic ulcer of the upper lip in a patient infected with HIV

Muriel Sidnoma Ouédraogo[1,2], Nina Korsaga/Somé[1,2], Aimé Sosthène Ouédraogo[2,3], Nomtondo Amina Ouédraogo[2,4], Gilbert Patrice Tapsoba[1,2], Tarcissus Konsem[2,5], Jean-Baptiste Andonaba[6], Jean Sakandé[2,7], Pascal Niamba[1,2], Adama Traoré[1,2]

[1]Service de Dermatologie-Vénéréologie, Centre Hospitalier Universitaire Yalgado, Ouédraogo, Ouagadougou, Burkina Faso, [2]Université Ouaga I Pr Joseph Ki Zerbo, Ouagadougou, Burkina Faso, [3]Service d'Anatomie Pathologie, Centre Hospitalier Universitaire Yalgado Ouédraogo, Ouagadougou, Burkina Faso, [4]Service de Dermatologie-Vénéréologie, Centre Raoul Follereau, Ouagadougou, Burkina Faso, [5]Service de Chirurgie Maxillo-Faciale, Centre Hospitalier Universitaire Yalgado Ouédraogo, Ouagadougou, Burkina Faso, [6]Service de Dermatologie-Vénérologie, Centre Hospitalier Universitaire Sanon Souro, Bobo-Dioulasso, Burkina Faso, [7]Service des Laboratoires, Centre Hospitalier Universitaire Yalgado Ouédraogo, Ouagadougou, Burkina Faso

Corresponding author: Dr. Muriel Sidnoma Ouédraogo, E-mail: sidnomam@yahoo.fr

ABSTRACT

Epidermoid carcinomas account for one third of cutaneous carcinomas. These are the most common cancers in adults. On dark skin, epidermoid carcinomas do not mainly occur on photo-exposed areas but rather complicate chronic ulcers. We are reporting the case of a 39 years old patient, HIV 1 positive being consulted for a budding tumor of the upper lip occurred on chronic erosion that appeared three years before. The histopathological examination of the bioptic specimen and of the resection specimen objectified a differentiated and mature epidermoid carcinoma. The patient was classified as Stage II: T3 N0 M 0. A complete tumor resection was performed followed by a double labial reconstruction by local advancement flap. Chronic ulceration and HIV infection have been identified as factors that favored malignant transformation. Limited access to health facilities has reportedly favored the evolution of lesions towards a complicated form and difficult medical care. The therapeutic challenge was to remove the tumor while preserving the function and aesthetics of the mouth.

Key words: Epidermoid carcinoma; HIV; Chronic ulceration

How to cite this article: Ouédraogo MS, Korsaga/Somé N, Ouédraogo AS, Ouédraogo NA, Tapsoba GP, Konsem T, Andonaba JB, Sakandé J, Niamba P, Traoré A. Epidermoid carcinoma involving on chronic ulcer of the upper lip in a patient infected with HIV. Our Dermatol Online. 2016;7(4):431-435.

Submission: 24.05.2016; **Acceptance:** 06.07.2016

DOI: 10.7241/ourd.20164.118

Carcinome épidermoïde sur ulcère chronique de la lèvre supérieure chez une patiente infectée par le VIH

Muriel Sidnoma Ouédraogo[1,2], Nina Korsaga/Somé[1,2], Aimé Sosthène Ouédraogo[2,3], Nomtondo Amina Ouédraogo[2,4], Gilbert Patrice Tapsoba[1,2], Tarcissus Konsem[2,5], Jean-Baptiste Andonaba[6], Jean Sakandé[2,7], Pascal Niamba[1,2], Adama Traoré[1,2]

[1]Service de Dermatologie-Vénéréologie, Centre Hospitalier Universitaire Yalgado, Ouédraogo, Ouagadougou, Burkina Faso, [2]Université Ouaga I Pr Joseph Ki Zerbo, Ouagadougou, Burkina Faso, [3]Service d'Anatomie Pathologie, Centre Hospitalier Universitaire Yalgado Ouédraogo, Ouagadougou, Burkina Faso, [4]Service de Dermatologie-Vénéréologie, Centre Raoul Follereau, Ouagadougou, Burkina Faso, [5]Service de Chirurgie Maxillo-Faciale, Centre Hospitalier Universitaire Yalgado Ouédraogo, Ouagadougou, Burkina Faso, [6]Service de Dermatologie-Vénérologie, Centre Hospitalier Universitaire Sanon Souro, Bobo-Dioulasso, Burkina Faso, [7]Service des Laboratoires, Centre Hospitalier Universitaire Yalgado Ouédraogo, Ouagadougou, Burkina Faso

Corresponding author: Dr. Muriel Sidnoma Ouédraogo, E-mail: sidnomam@yahoo.fr

RESUME

Les carcinomes épidermoïdes représentent un tiers des carcinomes cutanés. Ce sont les cancers les plus fréquents chez l'adulte. Sur peau foncée, les carcinomes épidermoïdes ne surviennent pas majoritairement sur les zones photo- exposées mais plutôt compliquent les ulcères chroniques. Nous rapportons l'observation d'une patiente de 39 ans, séropositive pour le VIH 1, consultant pour une tumeur bourgeonnante de la lèvre supérieure survenue sur une érosion chronique apparue 3 ans auparavant. L'examen histopathologique du prélèvement biopsique de la pièce d'exérèse objectivait un carcinome épidermoïde différencié et mature. La patiente était classée au Stade II: T3 N0 M 0. Une exérèse tumorale complète était pratiquée suivie d'une reconstruction labiale par double lambeau local d'avancement. L'ulcération chronique et l'infection par le VIH ont été retenus comme des facteurs qui ont favorisé la transformation maligne. L'accès limité aux structures de santé aurait favorisé l'évolution des lésions vers une forme compliquée et de prise en charge plus difficile. Le défi thérapeutique a été de faire l'ablation de la tumeur tout en préservant la fonction et l'esthétique de la bouche.

Mots clés: Carcinome épidermoïde; VIH; Ulcération chronique

INTRODUCTION

Les carcinomes cutanés sont les cancers les plus fréquents chez l'adulte. Ils représentent environ 30% des tumeurs malignes. Ils sont plus fréquents chez les phototypes clairs que les phototypes foncés. Les facteurs carcinogènes impliqués dans leur survenue sont multiples notamment l'irradiation par les ultraviolets, les dermatoses précancéreuses, l'immunosuppression (Virus de l'Immunodéficience Humaine, greffés d'organe) [1,2]. Sur peau foncée, les carcinomes cutanés surviennent plus sur les zones non exposées, et souvent sur des cicatrices chroniques [3,4]. Ils sont relativement rares dans notre contexte. Il en est de même pour les carcinomes épidermoïdes (CE) cutanés [3].

Les CE cutanés représentent près de 10% des cancers cutanés, un tiers des carcinomes cutanés, et 90% des cancers des lèvres [1]. Ils peuvent survenir de novo ou plus souvent marquer l'évolution de lésions considérées comme des précurseurs non invasifs: les kératoses actiniques et la maladie de Bowen. Les CE cutanés sont plus fréquents chez les phototypes foncés que les carcinomes basocellulaires; ceux-ci étant plus fréquents chez les phototypes clairs que

How to cite this article: Ouédraogo MS, Korsaga/Somé N, Ouédraogo AS, Ouédraogo NA, Tapsoba GP, Konsem T, Andonaba J-B, Sakandé J, Niamba P, Traoré A. Carcinome épidermoïde sur ulcère chronique de la lèvre supérieure chez une patiente infectée par le VIH. Our Dermatol Online. 2016;7(4):431-435.

Submission: 24.05.2016; **Acceptance:** 06.07.2016

DOI: 10.7241/ourd.20164.118

les CE cutanés [4,5]. Barro-Traoré F et *coll* trouvaient dans leur étude sur les tumeurs cutanées (1024 cas) colligées sur une période de 5 ans dans le service de dermatologie du Centre Hospitalier Universitaire Yalgado Ouédraogo (CHUYO) de OUAGADOUGOU une fréquence de 0,5% de carcinomes cutanés dont 3 cas de CE [6]. Le pronostic (morbidité fonctionnelle, esthétique, vital) est habituellement réservé par leur siège périorificiel [7-9]. Leur localisation sur la lèvre inférieure est plus couramment décrite que celle sur la lèvre supérieure [10,11]. Les CE cutanés atteignent préférentiellement l'homme de plus de 60 ans. Nous rapportons un cas de CE cutané chez une femme de 43 ans, de phototype VI, survenu sur une ulcération chronique de la lèvre supérieure dans un contexte d'immunodépression par le Virus de l'Immunodéficience Humaine (VIH).

OBSERVATION

Il s'est agit d'une patiente de 39 ans, ménagère, de phototype VI, qui consultait le 06/01/2009 pour des lésions érosives des lèvres supérieure et inférieure. Ces lésions évoluaient par poussées-rémissions depuis 3 ans. Il s'agissait de lésions squameuses et prurigineuses au début, devenues secondairement érosives, suintantes et douloureuses. La patiente était séropositive pour le VIH 1, connue depuis 3ans, traitée par Zidovudine (AZT), Lamivudine (3TC), Efavirens (EFV) et cotrimoxazole comprimés 960 mg/jour, avec une réponse favorable aux plans clinique et biologique. Il n'y avait pas de notion d'exposition au tabac ni de brûlure des lèvres, ni de dermatose préexistante. L'examen notait une bande érosive croûteuse melicérique et sanguinolente mal limitée du bord libre des lèvres débordant sur le vermillon et plus marquée sur la lèvre supérieure. Le diagnostic d'une chéilite chronique avait été retenu sans qu'une étiologie ait été plus probable qu'une autre (lichen, lupus, eczéma, infection herpétique ou carcinome). L'examen anatomopathologique n'était pas contributif pour le diagnostic. Le diagnostic présomptif de lichen érosif était posé. Un traitement par dermocorticoïde à raison d'une application par jour et par corticoïde retard (triamcinolone 40 mg) une injection par mois était institué pendant 2 mois. La patiente a par la suite été perdue de vue pendant 4 ans et demi. Elle était revue le 12/07/2013 pour une tumeur bourgeonnante de la lèvre supérieure dans un contexte de succès thérapeutique sur le plan de la prise en charge de l'infection par le VIH (CD4 à 610 cellules/ml, charge virale indétectable en mai 2013). L'examen physique notait une lésion ulcéro bourgeonnante de 5,5 ×3,5 ×3 cm, à surface érythémateuse papillomateuse, intéressant la quasi-totalité de la lèvre supérieure (Figs. 1 and 2). Il n'y avait pas d'adénopathie des aires ganglionnaires de proximité (cervicale, axillaire, sous angulo maxillaire). Le reste de l'examen était sans particularité. Le diagnostic de carcinome épidermoïde dans sa forme ulcérovégétante était évoqué. Un second examen anatomopathologique du prélèvement biopsique et un 3è de la pièce d'exérèse montraient une prolifération carcinomateuse sous forme de lobules centrés par des globes cornés. Les cellules étaient de type malpighien différencié, mature et présentaient une anisocaryose modérée et quelques mitoses. Le stroma

Figure 1: Carcinome épidermoïde ulcéro végétant, vue de face; [Epidermoid carcinoma ulcerovegetant, view of face].

Figure 2: Carcinome épidermoïde ulcéro végétant, vue de profil; [Epidermoid carcinoma ulcerovegetant, view of profil].

était réduit et inflammatoire, polymorphe constitué de lymphocytes et de polynucléaires neutrophiles. Il y avait la présence d'un remaniement nécrotique (Fig. 3). L'aspect histologique était en faveur d'un carcinome épidermoïde différencié et mature classé au Stade II: T3 N0 M 0. La tomodensitométrie de la région cervicale, la radiographie pulmonaire et l'échographie hépatique étaient normales. L'exérèse tumorale complète était réalisée emportant toute l'hémilèvre supérieure à gauche et la moitié de l'hémilèvre supérieure droite (Fig. 4). La reconstruction labiale était réalisée par double lambeau local d'avancement dans le même temps. Deux ans après l'exérèse, l'examen clinique de la cicatrice et des aires ganglionnaires régionales était normal.

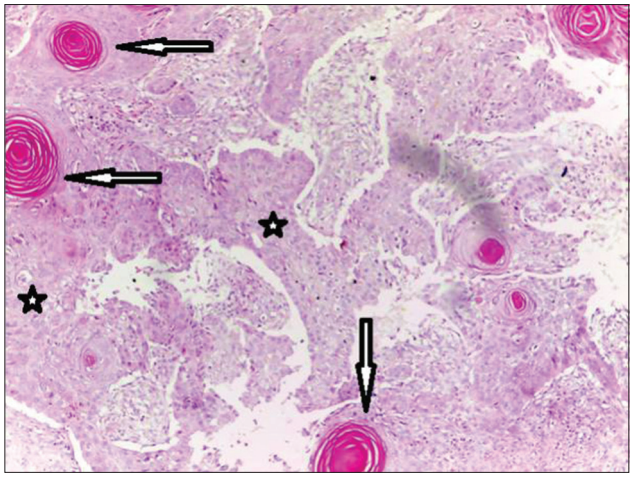

Figure 3: Carcinome spinocellulaire COLORATION H E, Gx100. Prolifération carcinomateuse sous forme de lobules (étoiles) centrés par des globes cornés (flèches); [Epidermoid carcinoma coloring H E, Gx100. Proliferation cancerous form of lobules (stars) centered by horny globes (arrows)].

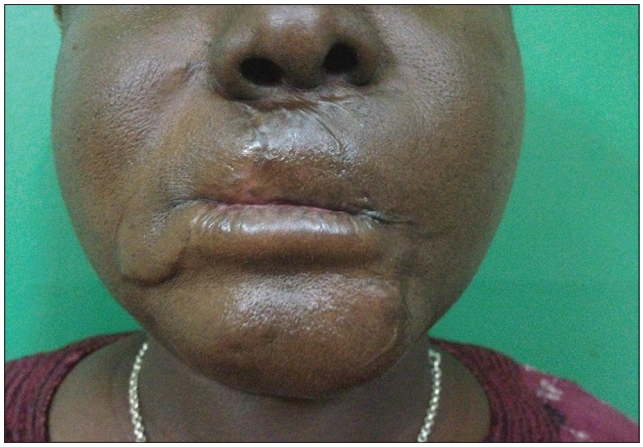

Figure 4: Cicatrisation 1 an après exérèse de la tumeur; [Healing one year after tumor's exeresis].

DISCUSSION

Cette observation est particulière par sa localisation sur la lèvre supérieure alors que la lèvre inférieure était également érosive. C'est le premier cas de CE sur cette localisation rapporté dans notre pays. La dégénérescence carcinomateuse de la lèvre supérieure est rare. Les cancers des lèvres sont plus fréquents sur la lèvre inférieure qui est plus exposée aux rayons ultraviolets [12]. Plusieurs études le rapportent notamment en Afrique. Adegbidi H et *coll*. dans leur étude rétrospective sur les cancers cutanés au Centre Hospitalier Universitaire de Cotonou rapportaient 6 cas de CE dont un localisé sur la lèvre inférieure sur 19 cas de cancers colligés en 20 ans [13]. Zaraa I et *coll*. en Tunisie rapportaient la localisation sur la lèvre inférieure dans 24 cas sur 30 cas de CE des lèvres colligés en 11 ans [10].

La particularité du cas est la survenue du CE chez une femme. En effet, le CE des lèvres atteint préférentiellement l'homme [1].

Plusieurs facteurs peuvent expliquer le développement du CE chez notre patiente: l'ulcération chronique et son mauvais suivi (par l'inaccessibilité aux moyens diagnostiques et thérapeutiques par manque de moyens financiers chez une patiente sans assurance santé), le terrain immunodéprimé par le VIH [8]. Ce terrain explique également la survenue de ce cancer à 42 ans, plus précocement que ce qui est habituellement décrit vers l'âge de 60 ans.

Histologiquement, le diagnostic étiologique de cette ulcération n'avait pas été possible probablement à cause du terrain et des remaniements chroniques.

Sur le plan clinique, l'aspect de la tumeur de notre patiente est fréquemment rapporté sur les lèvres. Zaraa I et *coll*. retrouvaient également dans leur série la forme ulcérovégétante dans 70% des cas [10].

Dans le cas de notre patiente, il était urgent de pratiquer l'exérèse complète de la tumeur de façon à préserver la fonction et l'esthétique de la cavité orale au mieux. Le curage ganglionnaire n'a pas été systématique en raison de l'absence d'adénopathie cervico-faciale. Le pronostic à long terme peut être compromis car le risque de récidive locale serait multiplié par 2 et celui de métastases locorégionales multiplié par 3 quand

la taille de la tumeur est supérieure à 2 cm [1]. Le délai de consultation était également long. Il existe un risque accru de métastase en cas d'atteinte ou de dépassement du derme réticulaire. L'infection à VIH vient encore grever le pronostic. Le pronostic est également fonctionnel et esthétique du fait de la réduction de l'ouverture de la bouche et de l'absence du galbe de la lèvre supérieure due à son amputation.

Cette situation rappelle la problématique des ulcérations traînantes et négligées dans notre contexte du fait du difficile accès aux soins de santé.

CONCLUSION

Ce cas rare de carcinome épidermoïde développé sur une ulcération chronique de la lèvre supérieure rappelle la nécessité de ne pas négliger les ulcérations chroniques quelque soit leur siège. Il rappelle également la vigilance dont il faut faire preuve sur les terrains immunodéprimés sachant que ceux-ci exposent à un risque important de CE [8].

RÉFÉRENCES

1. Basset-Séguin N, Renaud-Vilmer C, Huguenin R, Verolat O. Carcinomes spinocellulaires. EMC Dermatologie. 2002;98:1-9.
2. Kim DY, Rha EY, Yoo G, Lim JS. Squamous cell carcinoma on the upper lip of a patient with discoid lupus erythematous. Arch plast Surg. 2013;40:155-7.
3. Dieng MT, Diop NN, Deme A, Sy TN, Niang SO, Ndiaye B. Carcinome épidermoïde sur peau noire: 80 cas. Ann Dermatol Venereol. 2004;131:1055-57.
4. Napo-Koura G, Pitche P, Tchangaï-Walla K, James K, Kpodzro K. Les cancers cutanés au Togo. Bull Cancer. 1997;84:877-9.
5. Couppié P and Traoré A. Cutaneous cancers (Including Melanoma). In: Droz J.-P., Carme B, Couppié P, Nacher M, Thiéblemont C. Eds. Tropical Hemato-Oncology. First. Switzerland: Edition Springer International Publishing Switzerland; 2015:405-17.
6. Barro-Traoré F, Traoré A, Konaté I, Traoré SS, Sawadogo NO, Sanou I, et al. Tumeurs cutanéo-muqueuses: aspects épidémiologiques dans le service de dermatologie du centre hospitalier national Yalgado Ouédraogo de Ouagadougou, Burkina Faso. Cahiers d'études et de recherches francophones/Santé. 2003;13:101-4.
7. Vaillant L, Machet L. Muqueuse buccale. Dans: Saurat J-H, Lachapelle JM, Lipsker D, Thomas L, eds. Dermatologie et Infections Sexuellement Transmissibles. 5è édition. Paris-Milan-Barcelone- Mexico: Masson, 2009;821-33.
8. Guillaume J-C, Mateus C, Robert C. Carcinomes spinocellulaires. Dans: Saurat J-H, Lachapelle JM, Lipsker D, Thomas L, eds. Dermatologie et Infections Sexuellement Transmissibles. 5è édition. Paris-Milan-Barcelone- Mexico: Masson, 2009;646-52.
9. Burusapat C, Pitiseree A. Advanced squamous cell carcinoma involving both upper and lower lip and oral commissure with simultaneous reconstruction by local flap: a case report. J Med Case Reports. 2012;6:23.
10. Zaraa I, Taazayet SB, Dakhli I, Chelly I, Mokni M, Zitouna M, et al. Carcinome épidermoïde des lèvres: à propos de 30 cas. Tunisie Méd. 2013;91:148-53.
11. Zitsch RP. Carcinoma on the lip. Otolaryngol Clin North Am. 1993;26:265-77.
12. Luna-Ortiz K, Güema-Meza A, Mosqueda-Taylor A. Upper lip malignant neoplasms. A study of 59 cases. Med Oral Patol Oral Cir Bucal. 2012;17:e371-6.
13. Adegbidi H, Yedomon H, Atadokpede F, Balley-Pognon M-C, do Ango-Padonou F. Skin cancers at the National University Hospital of Cotonou from 1985 to 2004. Int J Dermatol. 2007;46:26-9.

Copyright by Muriel Sidnoma Ouédraogo, et al. This is an open access article distributed under the terms of the Creative Commons Attribution License, which permits unrestricted use, distribution, and reproduction in any medium, provided the original author and source are credited.
Source of Support: Nil, Conflict of Interest: None declared.

Case Report

Aggressive angiomyxoma of the vulva - A rare entity

Archana Shivamurthy[1], Padmapriya Jaiprakash[2], Paramasivam Lavanya[3]

[1]Department of Pathology, Melaka Manipal Medical College, Manipal University, Manipal, India, [2]Department of Pathology, Kasturba Medical College, Manipal University, Manipal, India, [3]Post graduate student, Kasturba Medical College, Manipal University, Manipal, India

Corresponding author: Dr. Archana Shivamurthy, E-mail: archana_018@yahoo.co.in

ABSTRACT

Aggressive angiomyxoma (AA) is a rare locally invasive soft tissue tumor that is known for its local recurrence. It affects women of reproductive age group. Clinically it presents as a pedunculated polyp or a polypoidal mass usually involving the pelvis, vulva, vagina and the urinary bladder. Excision is the treatment of choice. Due to its tendency for local recurrence long term follow up is adviced. We present AA in a 43year old woman involving the vulva.

Key words: Aggressive angiomyxoma; Vulva; Polyp

INTRODUCTION

Aggressive angiomyxoma is a rare, locally invasive, slowly growing, recurrent soft tissue tumor that occurs in women of reproductive age [1,2]. It usually involves the pelvis, vulva, perineum, vagina and urinary bladder. Clinically it presents as a pedunculated polyp or a polypoidal mass and needs to be differentiated from other polypoidal lesions that occur at the same site [2-4]. Owing to its high rate of recurrence appropriate management and a close long term clinical follow up is required [4,5].

CASE REPORT

A 43 year old woman presented with a slowly growing mass in the vulva since 4 months. It was gradually progressive in size and painful. The patient also complained of serous discharge. On examination a polypoidal, spongy mass was present in the vulva measuring 6 x 4 cm. Skin over the lesion was focally ulcerated. An excision biopsy was performed and the specimen was sent for histopathological examination. On gross examination the skin covered polypoidal, soft nodular mass measured 6.5 x 4 x 3.5 cm. Focal the skin surface was ulcerated (Fig. 1). Cut section revealed myxoid areas with focal cystic areas (Fig. 2). On histopathological examination, focally ulcerated stratified squamous epithelium was observed overlying tumor composed of spindle to stellate cells with ill-defined cytoplasm in a fibrocollagenous myxoid stroma, interspersed varying sized blood vessels ranging from small thin walled capillaries to thick walled dilated, congested blood vessels (Figs. 3 and 4), few showing perivascular hyalinization and lymphocytic infiltrate (Fig. 5). Hence a diagnosis of aggressive angiomyxoma was rendered.

DISCUSSION

AA was initially described by Steeper and Rosai in 1983 [1,2]. The aggressive nature of the lesion is explained by its local invasiveness and tendency for recurrence. It has a very low propensity for metastasis and few cases of metastasis to the lung have been reported in literature. Angiomyxomas are classified either as superficial (cutaneous myxoma) or AA [5,6]. The former occur in middle aged adults, involving the head and neck region presenting as polyps or nodules. On histopathology, the lesion shows edematous stroma with myxoid material. The latter occurs exclusively in the perineal and pelvic regions of women during re reproductive years. Occasionally it has been reported in men [6,7].

AA are hormonally responsive tumors. Estrogen and progesterone receptors are commonly found to be positive.

How to cite this article: Shivamurthy A, Jaiprakash P, Lavany P. Aggressive angiomyxoma of the vulva - A rare entity. Our Dermatol Online. 2016;7(4):436-438.
Submission: 14.04.2016; **Acceptance:** 15.06.2016
DOI:10.7241/ourd.20164.119

Figure 1: Gross photograph showing a polypoidal skin coversed nodular tissue mass.

Figure 2: Gross photograph showing cut section with myxoid areas and focal cystic areas.

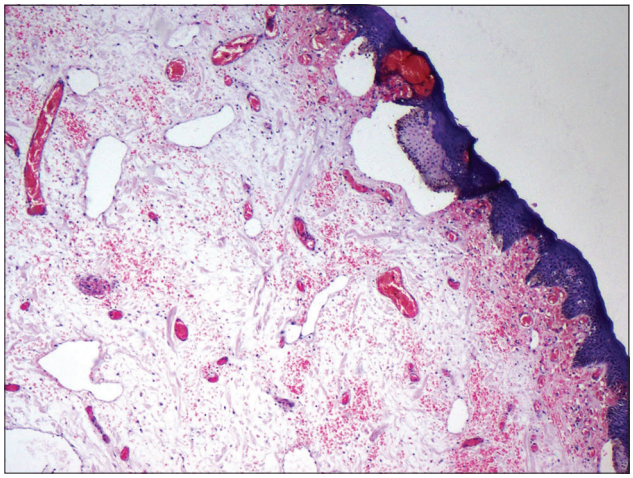

Figure 3: Stratified squamous epithelium overlying tumor composed of spindle to stellate cells in a fibrocollagenous myxoid stroma [H & E x40].

The origin of this tumor has been attributed to specialized mesenchymal cells present in the pelvic–perineal region and the multipotent perivascular progenitor cells, which often display both myofibroblastic and fibroblastic features [4,7]. This had been substantiated with the tumor cells expressing desmin and, in some cases, a smooth muscle actin. A variety of molecular

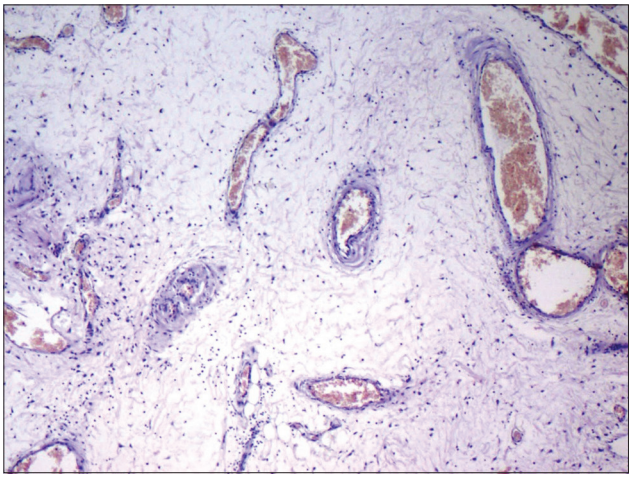

Figure 4: Interspersed varying sized blood vessels ranging from small thin walled capillaries to thick walled dilated, congested blood vessels [H & E x40].

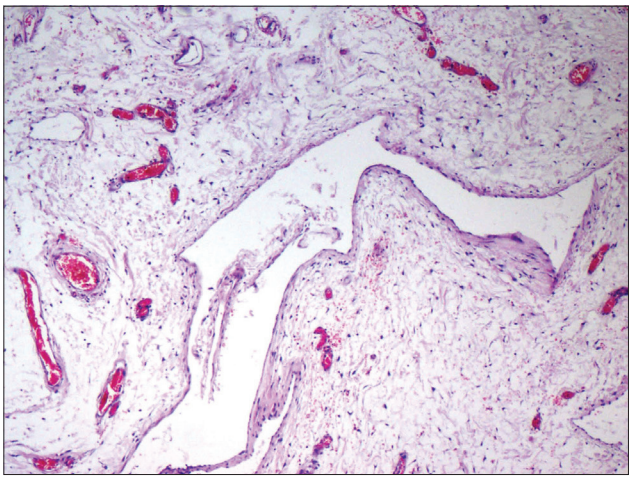

Figure 5: Perivascular hyalinization and lymphocytic infiltrate [H & E x100].

genetic alterations have been identified involving the chromosome 12, in the region 12q13-15 [7,8]. It has been described that high-mobility group protein isoform I-C (HMGIC) gene, which encodes proteins involved in the transcriptional regulation, plays a role in the pathogenesis of this tumor. Immunohistochemical detection using anti HMGI-C antibody can also be used for detection of residual disease [4,7,8].

On microscopy AAs show widely separated spindle-shaped neoplastic cells in a loose myxoid stroma rich in collagen fibers, hyaluronic acid, along with prominent irregular-shaped blood vessels. The myxoid stroma is also sometimes weakly positive with alcian blue at pH 2.5 [6,8]. Immunohistochemically, the tumor cells are positive for vimentin and may stain for smooth muscle actin and desmin. The differential diagnosis of AA included myxomas, angiomyofibroblastoma, fibroepithelial stromal polyp, superficial angiomyxoma,

Table 1: Differential diagnosis of aggressive angiomyxoma

Lesions	Sites	Age	Histopathological features
Fibroepithelial stromal polyp	Vagina, vulva	Adult women during pregnancy	Central fibrovascular core covered by normal appearing squamous epithelium without intervening grenz zone, edematous stroma with hypocellular or myxoid areas. May have atypical stromal cells including stellate and multinucleated cells
Angiomyofibroblastoma	Vagina, vulva	Middle aged females (fourth and fifth decades of life)	Encapsulated tumor with hyper- and hypocellular areas and numerous vessels Vessels may be hyalinized Hypercellular areas composed of plump stromal cells that often congregate around vessels Hypocellular areas are more spindled Rarely mitotic figures and multinucleated cells
Superficial angiomyxoma	Perineum	2nd decade	Frequently multinodular, long thin walled vessels , stromal neutrophils Frequently involves subcutis Paucicellular
Myxoid neurofibroma	vulva	Young patients with Von Recklinghausen's disease	Bundles of wavy and spindle cell with palisade arrangement, intervening few collagen fibers, areas of mucoid degeneration
Sarcoma botryoides	Vulva	Childhood and young adulthood	Hypercellular zone immediately beneath epithelium (Nicholson's cambium layer - resembles hypercellular zones that produce growth rings in trees) Cells are undifferentiated, round or spindled with minimal cytoplasm, frequent mitotic figures Less cellular in deeper layers, composed of differentiating and undifferentiated cells

myxoid neurofibroma, myxoid liposarcoma, myxoid variant of malignant fibrous histiocytoma, sarcoma botryoides and myxofibrosarcoma [9,10] (Table 1).

Clinical differential diagnosis includes bartholin cyst, labial cyst, gartner duct cyst, lipoma, levator hernia or sarcoma [6,7]. The treatment of choice is wide surgical excision. Recurrences may occur from a few months to several years after excision ranging from 2 months to 15 years. Hence patients need to have long term follow up [4,9]. Incomplete resection is acceptable where fertsility is to be preserved as local recurrences can be treated with further resection. Tamoxifen, raloxifene and gonadotropin-releasing hormone analogues can be used to reduce the tumor size, thus helping to make complete excision feasible in large tumors [7,10]. They are also used in the treatment of recurrence. The present patient has been kept on close follow. No recurrence has been noted in the last 6 months.

CONCLUSION

AA is a locally invasive tumor that probably arises from the common pluripotential primitive cell located around the vessels of connective tissue. Recurrence is known to occur. Hence long term follow up of these patients is mandatory.

Consent

The examination of the patient was conducted according to the Declaration of Helsinki principles.

REFERENCES

1. Alameda F, Munne A, Baro T, Iglesias M, Condom E, Lloreta-Trull J, et al. Vulvar angiomyxoma, aggressive angiomyxoma and angiomyofibroblastoma: An immunohistochemical and ultrastructural study. Ultrastruct Pathol. 2006;30:193-205.
2. Nucci MR, Fletchr CD. Vulvovaginal soft tissue tumors: Update and review. Histopathology. 2000;36:97-108.
3. Blandamura S, Cruz J, Faure-Vergara L, Machado-Puerto I, Ninfo V. Aggressive angiomyxoma: A second case of metastasis with patient's death. Hum Pathol. 2003;34:1072-4.
4. Behranwala KA, Thomas JM. Aggressive angiomyxoma: A distinct clinical entity. Eur J Surg Oncol. 2003;29:559-63.
5. McCluggage WG, Jamieson T, Dobbs SP, Grey A. Aggressive angiomyxoma of the vulva: Dramatic response to gonadotropin-releasing hormone agonist therapy. Gynecol Oncol. 2006;100:623-5.
6. Magtibay PM, Salmon Z, Keeney GL, Podratz KC. Aggressive angiomyxoma of the female pelvis and perineum: A case series. Int J Gynecol Cancer. 2006;16:396-401.
7. Schoolmeester JK, Leifer AJ, Wang L, Hameed MR. Vulvar myxoid liposarcoma and well differentiated liposarcoma with molecular cytogenetic confirmation: case reports with review of malignant lipomatous tumors of the vulva. Int J Gynecol Pathol. 2015;34:390-5.
8. Srinivasan R, Mohapatra N, Malhotra S, Rao SK. Aggressive angiomyxoma presenting as a vulval polyp. Indian J Cancer. 2007;44:87-9.
9. Mandal S, Dhingra K, Roy S, Khurana N. Aggressive angiomyxoma of the vulva presenting as a pedunculated swelling.Indian J Pathol Microbiol. 2008;51:259-60.
10. Salman MC, Kuzey GM, Dogan NU, Yuce K. Aggressive angiomyxoma of vulva recurring 8 years after initial diagnosis. Arch Gynecol Obstet. 2009;280:485-7.

Copyright by Archana Shivamurthy, et al. This is an open access article distributed under the terms of the Creative Commons Attribution License, which permits unrestricted use, distribution, and reproduction in any medium, provided the original author and source are credited.

Source of Support: Nil, **Conflict of Interest:** None declared.

Our Dermatology Online

Case Report

A case of multiple lipomas coexisting with angiolipomas: Familial multiple lipomatosis or a distinct entity?

Funda Tamer[1], Mehmet Eren Yuksel[2]

[1]Department of Dermatology, Turgut Ozal University Faculty of Medicine, Alparslan Turkes Caddesi, No: 57 Emek, Ankara, Turkey, [2]Department of General Surgery, Devrek State Hospital, Devrek, Zonguldak, Turkey

Corresponding author: Dr. Funda Tamer, E-mail: fundatmr@yahoo.com

ABSTRACT

Familial multiple lipomatosis and familial multiple angiolipomatosis are both rare and autosomal-dominantly inherited diseases. Familial multiple lipomatosis is characterized by multiple lipomas on the trunk and extremities, while familial multiple angiolipomatosis presents with multiple angiolipomas. Hereby, we present a 50-year-old Caucasian male patient with both multiple lipomas and angiolipomas on his trunk, arms and thighs with a family history of similar subcutaneous lesions. As multiple lipomas and angiolipomas coexist in the same patient, we suggest that this condition should be nominated as a distinct entity rather than a traditional familial multiple lipomatosis case.

Key words: Familial; Multiple; Lipomatosis; Angiolipomatosis

INTRODUCTION

Familial multiple lipomatosis is a rare, autosomal dominant inherited disease with an incidence of 0.002% in the general population. It is characterized by multiple, mobile, encapsulated subcutaneous nodules on forearms, thighs and trunk. On the other hand, familial multiple angiolipomatosis is an autosomal dominant inherited disease presenting with several angiolipomas typically on arms and trunk. A lipoma with an excessive vascular component is called an angiolipoma. Therefore, familial angiolipomatosis has been usually considered as subtype of familial multiple lipomatosis.

However, lipomas and angiolipomas may coexist. Hereby, we present a 50-year-old Caucasian male patient suffering from both multiple lipomas and angiolipomas on his trunk, arms and thighs with a family history of subcutaneous nodules. As multiple lipomas and angiolipomas coexist in the same patient, we suggest that this condition should be described as a distinct entity rather than a traditional familial multiple lipomatosis case.

CASE REPORT

A 50-year-old Caucasian male patient complaining of multiple swellings on his trunk, arms and legs which had been slowly increased in size and number in the last 35 years, was admitted for further clinical evaluation. The patient stated that the lesions were painless, however he had cosmetic concerns. The past medical history was unremarkable. The patient admitted that his two sisters had similar swellings on their arms and legs. The physical examination revealed multiple, skin colored, mobile, soft, well defined, round shaped subcutaneous nodules (Figs. 1a and 1b). Laboratory tests including total cholesterol and LDL cholesterol levels were within normal limits, 177 mg/dl and 96 mg/dl respectively (reference ranges of total cholesterol and LDL cholesterol are 10-200 mg/dl and 10-150 mg/dl respectively). However, serum level

How to cite this article: Funda Tamer, Mehmet Eren Yuksel. A case of multiple lipomas coexisting with angiolipomas: Familial multiple lipomatosis or a distinct entity?. Our Dermatol Online. 2016;7(4):439-441.

Submission: 22.02.2016; **Acceptance:** 20.04.2016

DOI:10.7241/ourd.20164.120

of triglyceride was 279 mg/dl (normal range is 10 to 150 mg/dl) which was higher than the normal range. HDL cholesterol was 25 mg/dl (normal range is 30 to 80 mg/dl) which was lower than the normal range. In addition, serum level of hemoglobin was 17 g/dL (normal range is 10 to 16,5 g/dL) and aspartate transaminase was 83 u/l (normal range is 5 to 34 u/l). As triglyceride and aspartate transaminase levels were higher than expected, hepatosteatosis was initially suspected. Therefore, an abdominal ultrasonography was performed. It revealed multiple abdominal echogenic subcutaneous nodules of 2.5 cm maximum diameter, hepatomegaly and grade 2 hepatosteatosis.

As the patient had cosmetic concerns, he demanded the surgical removal of the lesions. Therefore, 18 yellowish brown colored nodules on the patient's arms with a minimum of 0,8x0,4x0,2 cm and a maximum of 4,5x3x1,5 cm in size were surgically removed under local anesthesia (Figs. 2a and 2b). The patient did well postoperatively. The histopathological examination of 10 of 18 lesions revealed lipomas and the 8 of 18 lesions were found to be angiolipomas.

Figure 1: (a.b) Multiple subcutaneous nodules on the trunk and arms.

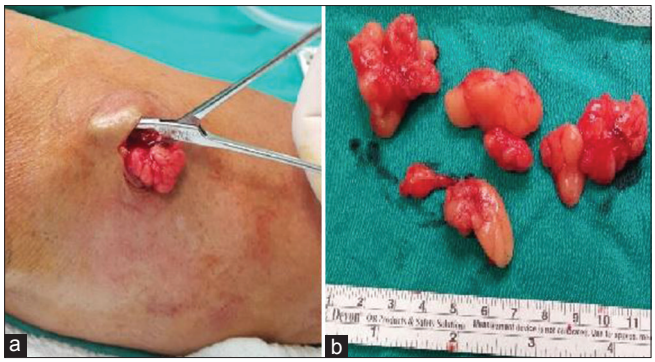

Figure 2: (a.b) Intraoperative and postoperative views of the lesions.

DISCUSSION

Familial multiple lipomatosis is a rare hereditary disorder which is characterized by multiple lipomas mainly on trunk and extremities. It has been first reported by Brodie as ''lipomatose circonscrite multiple'' in 1846 [1]. It is a matter of debate whether familial multiple lipomatosis is associated with abnormalities of lipid metabolism. Some of the authors like Wilson and Rubinstein mentioned that familial multiple lipomatosis might be associated with hyperlipidemia [2,3]. However, the patient presented above had hypertriglyceridemia and low HDL cholesterol levels.

Moreover, familial multiple lipomatosis might coexist with other diseases. Celiac disease and cytophagic histiocytic panniculitis have been reported in patients with familial multiple lipomatosis [4,5]. Recently, Nunes et al. described a female patient who had brain lipoma, corpus callosum hypoplasia, polymicrogyria and familial multiple lipomatosis [6]. In addition, Madelung's disease, Dercum`s disease, Bannayan-Zonana syndrome and Cowden syndrome clinically present with subcutaneous lipomas. Therefore, they should be kept in mind in the differential diagnosis of familial multiple lipomatosis. Surgical excision, liposuction and lipolysis with phosphatidyl choline injection are some of the options in the treatment of familial multiple lipomatosis [7].

On the other hand, familial multiple angiolipomatosis is a benign, autosomal dominant condition which clinically presents with numerous angiolipomas. Angiolipoma is a rare variant of lipoma with excessive vascular component. Angiolipomas can cause pain and thus, it may be helpful to differentiate angiolipomas from lipomas clinically. Besides, they usually do not require treatment like lipomas. Therefore, familial angiolipomatosis is generally considered as a subtype of familial multiple lipomatosis [7,8]. However, Hapnes et al. and Kumar et al. regard familial multiple angiolipomatosis as a distinct disease [9,10].

The case presented above is unique as the patient had both multiple lipomas and angiolipomas with a family history of subcutaneous nodules. In addition to familial lipomatosis and familial angiolipomatosis, we suggest that the coexistence of lipomas and angiolipomas should be classified as a distinct entity.

CONSENT

The examination of the patient was conducted according to the Declaration of Helsinki principles.

REFERENCES

1. Gologorsky Y, Gologorsky D, Yarygina AS, Surti U, Zirwas MJ. Familial multiple lipomatosis: Report of a new family. Cutis. 2007;79:227-32.
2. Wilson D, Boland J. Sporadic multiple lipomatosis: a case report and review of the literature. W V Med J. 1994;90:145-6.
3. Rubinstein A, Goor Y, Gazit E, Cabili S. Non-symmetric subcutaneous lipomatosis associated with familial combined hyperlipidaemia. Br J Dermatol. 1989;120:689-94.
4. Sayar I, Demirtas L, Gurbuzel M, Isik A, Peker K, Gulhan B. Familial multiple lipomas coexisting with celiac disease: A case report. J Med Case Rep. 2014;8:309.
5. Krilis M, Miyakis S. Cytophagic histiocytic panniculitis with haemophagocytosis in a patient with familial multiple lipomatosis and review of the literature. Mod Rheumatol. 2012;22:158-62.
6. Nunes JC, Martins RF, Bastos A, Claudino LS, Guarnieri R, Lima Dde C, et al. Brain lipoma, corpus callosum hypoplasia and polymicrogyria in familial multiple lipomatosis. Clin Neurol Neurosurg. 2013;115:1157-9.
7. Rosmaninho A, Pinto-Almeida T, Fernandes IC, Machado S, Selores M. Do you know this syndrome? An Bras Dermatol. 2012;87:324-5.
8. Abbasi NR, Brownell I, Fangman W. Familial multiple angiolipomatosis. Dermatol Online J. 2007;13:1-3.
9. Hapnes SA, Boman H, Skeie SO. Familial angiolipomatosis. Clin Genet. 1980;17:202-8
10. Kumar R, Pereira BJ, Sakhuja V, Chugh KS. Autosomal dominant inheritance in familial angiolipomatosis. Clin Genet. 1989;35:202-4.

Copyright by Funda Tamer, et al. This is an open access article distributed under the terms of the Creative Commons Attribution License, which permits unrestricted use, distribution, and reproduction in any medium, provided the original author and source are credited.

Source of Support: Nil, **Conflict of Interest:** None declared.

Case Report

Palisaded encapsulated neuroma: an uncommon tumour at uncommon location

Anup Kumar Tiwary, Shyam Sundar Chaudhary, Dharmendra Kumar Mishra

Department of Dermatology, Venereology and Leprosy, Rajendra Institute of Medical Sciences, Ranchi, India

Corresponding author: Dr. Anup Kumar Tiwary, E-mail: anup07tunnu07@gmail.com

ABSTRACT

Palisaded encapsulated neuroma (PEN) is an uncommon, sporadic, benign, intraneural tumour presenting as an asymptomatic, solitary, sessile, immobile, skin-coloured papule or nodule, commonly affecting the "butterfly area" of face in middle-aged person. Other less commonly involved sites are trunk, shoulder and distal part of extremities. We herein report a 45 years old male presenting with a painless, firm,nodular growth over the posteromedial aspect of right knee which was further confirmed to be the case of PEN on histopathological examination.

Key words: Intraneural; Palisaded encapsulated neuroma; Schwannoma

INTRODUCTION

PEN also known as 'solitary circumscribed neuroma' is an uncommon, sporadic, cutaneous, benign, intraneural tumor, which usually presents as asymptomatic, solitary or multiple, firm, rubbery, skin-coloured or pink, papule or nodule, commonly localized on the face or close to a muco-cutaneous junction in middle - aged adults with equal sex preponderance [1]. It was first described by Reed et al in 1972 [1]. Being solitary or multiple, it has never been seen to be associated with neurofibromatosis or multiple endocrine neoplasia [2]. Clinically, it is more commonly misdiagnosed with schwannoma, neurofibroma and dermatofibroma so it is imperative to histopathological evaluation in all such cases.

CASE REPORT

A 45 year old male presented with a single, firm, skin coloured, nodular growth on postero-medial aspect of right knee which began as a papule one year back and gradually increased in size to 2 cm x 1 cm over one year. Initially it was asymptomatic but in last 3 months mild pain and itching was started. The patient was born of non-consanguineous parents and none of the family members were affected.

On general physical examination, patient was healthy and normal looking. All routine investigations and laboratory parameters were within normal limits and non contributory. Systemic examinations including ophthalmological and neurological examinations were also normal and none of the features of neurofibromatosis were detected. On local cutaneous examination, the lesion was solitary, skin coloured, immobile, firm, rubbery, pedunculated, nodular growth, neither warm nor tender but mildly painful and pruritic (Fig. 1). There was no history of trauma, oozing or bleeding from the lesion. Telangiectasia, ulceration or discharge was also absent. Mucosa, hairs, nails and teeth were found to be normal looking on examination. Regional lymph nodes were not enlarged.

Appendageal tumours, schwannoma and dermatofibroma were kept as provisional diagnosis. Excisional biopsy was then performed and histopathological study was done. HPE demonstrated partially encapsulated, well circumscribed dermal neoplasm that was differentiated towards nerves (Fig. 2). It showed several nerve bundles like structure in the form of fascicles containing interdigitating spindle cells having ill defined palisades of nuclei (Verocay bodies) and in between acellular area (Fig. 3).

How to cite this article: Tiwary AK, Chaudhary SS, Mishra DK. Palisaded encapsulated neuroma: An uncommon tumour at uncommon location. Our Dermatol Online. 2016;7(4):442-444.

Submission: 16.03.2016; **Acceptance:** 07.06.2016

DOI:10.7241/ourd.20164.121

Figure 1: Solitary, firm, skin coloured, nodular growth on postero-medial aspect of right knee.

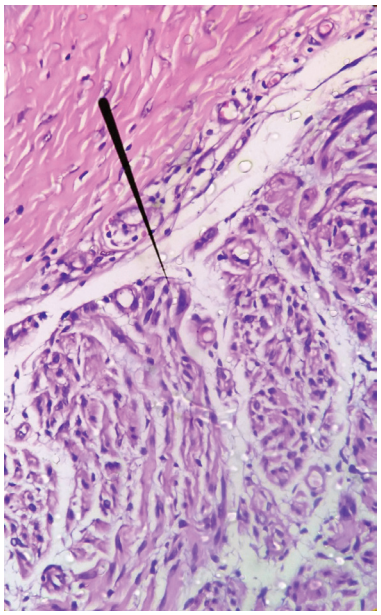

Figure 2: Partially encapsulated, well-circumscribed dermal nodules several nerve bundles like structures in the form of fascicles containing interdigitating spindle shaped shwann cells (H&E, ×40).

Increased number of small blood vessels were also seen in dermis.

Based on the histopathological findings, diagnosis of PEN was made. After excisional biopsy, wound was closed with mersilk 3-0 suture and patient was advised for follow up to look for any recurrence of the lesion.

DISCUSSION

PEN is an intradermal benign, intraneural neoplasm accounting for 25% of all dermal nerve sheath tumours [3]. It presents as solitary or multiple, firm, rubbery, skin or pink coloured, papule or nodule most

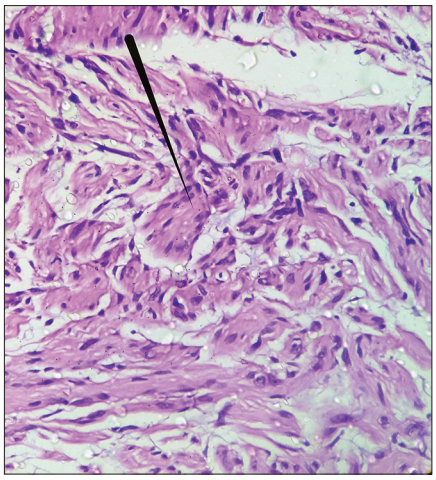

Figure 3: Spindle shaped schwann cells having eosinophilic cytoplasm, pointed and wavy basophilic nuclei and palisading of nuclei and acellular reticular fibres in between these nuclei forming 'verocay bodies' (H&E, ×100).

commonly involving face in 90% of cases. Other less common sites of predilection are trunk, shoulder, arm, hand, foot, oral mucosa, nasal fossa and glans penis [3-5]. There is no sex predilection and usually affects 30-60years age group. Its size usually ranges from 2mm to 6 mm and gradually enlarges over the time. Over the time traumatic ulceration may occur as a secondary complication but haemorrhage and necrosis has not been reported and telangiectasia is minimal or absent. No hairs are seen to come out of the surface.

PEN is supposed to be caused by reactive hyperplasia or hamartomatous growth of schwann cells and axons causing bulbous expansion of nerves but triggering factors are yet to be known [6]. Clinically it is closely simulated by schwannoma, neurofibroma, dermatofibroma, appendageal tumours of skin, epidermal cyst, basal cell carcinoma and intradermal naevi [1,4,7]. Relatively, very lower occurrence of telengienctasia and ulceration helps in ruling out the diagnosis of basal cell carcinoma [4]. Neurofibroma, schwannoma and intradermal naevi simulate the clinical picture but can be differentiated on HPE [1,4].

On HPE, it is seen as intradermal nodule composed of encapsulated interlacing distinct fascicles containing spindle cells and separated by artifactual clefts [8]. The tumour has fine capsule or is partially encapsulated because it doesn't include epidermis.

The capsule contains epithelial membrane antigen (EMA) positive flattened, elongated perineural cells [7]. The tumour cells include schwann cells and axons. The schwann cells have eosinophilic cytoplasm,

pointed and wavy basophilic nuclei and palisading of nuclei may be seen in few fascicles. The palisaded nuclei and acellular reticular fibres in between these nuclei form 'verocay bodies' but are ill-defined usually [7,5]. These verocay bodies are more distinct and consistent finding in schwannoma rather than in PEN [5]. Apart from the nodular pattern of intradermal fascicles, other less common patterns have also been reported like plexiform, epithelioid, multinodular, fungating and vascular [9].

On immunohistochemical analysis, capsule stains for EMA, and schwann cells stain for S-100, collagen type IV and vimentin. Axons stain with neuron specific enolase (NSE) and antibodies against neurofilaments.

Histopathologically the close differential diagnoses are schwannoma, traumatic neuroma, neurofibroma, leiomyoma. Usually Schwannoma is located subcutaneously having Antoni – A and Antoni – B areas which are rich in varocay bodies and lack axons [5]. Neurofibroma lacks capsule, rich in mucopolysaccharide ground substance and have fewer axons [8]. Traumatic neuroma closely mimcks the histopathological picture but can be differentiated by the presence of inflammatory cells and scarring. The presence of smooth muscle cells and positive staining for desmin and vimentin clinches the diagnosis of leiomyoma.

Treatment of choice is complete excision and chance of recurrence is very less even after incomplete excision [4,9].

CONCLUSION

As Palisaded encapsulated neuroma can easily be misdiagnosed with other neural and soft tissue tumours, histopathological evaluation is imperative to confirm the diagnosis of PEN. Moreover, very rare chances of recuurence even after incomplete excision points in favour of reactive and benign nature of this tumour.

Consent

The examination of the patient was conducted according to the Declaration of Helsinki principles.

ACKNOWLEDGEMENTS

The authors sincerely thank Dr. Uday Khopkar for their contribution by giving valuable suggestions for the histopathological findings.

REFERENCES

1. Reed R, Fine R, Meltzer H. Palisaded encapsulated neuromas of the skin. Arch Dermatol. 1972;106:865-70.
2. Halder C, Sen S, Gangopadhyay A, Bala S. Zosteriform palisaded encapsulated neuroma: An unusual presentation. Indian J Dermatol. 2013;58:492.
3. Navarro M, Vilata J, Requena C, Aliaga A. Palisaded encapsulated neuroma (solitary circumscribed neuroma) of the glans penis. Br J Dermatol. 2000;142:1061-2.
4. Golod O, Soriano T, Craft N. Palisaded encapsulated neuroma-A classic presentation of a commonly misdiagnosed neural tumor. J Drugs Dermatol. 2005;4:92-4.
5. Zelger B, Steiner H, Kutzner H, Rutten A, Zelger B. Verocay body-prominent cutaneous schwannoma. Am J Dermatopathol. 1997;19:242-9.
6. Dover J, From L, Lewis A. Palisaded encapsulated neuromas. A clinicopathologic study. Arch Dermatol. 1989;125:386-9.
7. Argenyi ZB. Immunohistochemical characterization of palisaded, encapsulated neuroma. J Cutan Pathol. 1990;17:329-35.
8. Dubovy SR, Clark BJ. Palisaded encapsulated neuroma (solitary circumscribed neuroma of skin) of the eyelid: Report of two cases and review of the literature. Br J Ophthalmol. 2001;85:949-51.
9. Koutlas IG, Scheithauer BW. Palisaded encapsulated ("solitary circumscribed") neuroma of the oral cavity: A review of 55 cases. Head Neck Pathol. 2010;4:15-26.

Copyright by Anup Kumar Tiwary, et al. This is an open access article distributed under the terms of the Creative Commons Attribution License, which permits unrestricted use, distribution, and reproduction in any medium, provided the original author and source are credited.
Source of Support: Nil, **Conflict of Interest:** None declared.

Case Report

Lupus and pulmonary nodules consistent with bronchiolitis obliterans organizing pneumonia induced by carbamazepine in a man

Awatef Kelati, Salim Gallouj, Mariame Meziane, Fatima Zahra Mernissi

Department of Dermatology of the Hospital Hassan II, Faculty of Medicine, Fez, Morocco

Corresponding author: Dr. Awatef Kelati, E-mail: awatkelati@gmail.com

ABSTRACT

Several drugs have been implicated in the induction of systemic lupus erythematosus (SLE), but there are only some observations of carbamazepine induced SLE since the first case described in 1966, this drug has also been implicated in the induction of other disorders and rarely pulmonary toxicity; but the occurrence of two rare side effects of this drug: the induced SLE and pulmonary nodules consistent with the bronchiolitis obliterans organizing pneumonia in same patient is really unusual and -to our knowledge- the second observation reported in the literature.

Key words: Carbamazepine; Lupus; Bronchiolitis obliterans organizing pneumonia

INTRODUCTION

Several drugs have been implicated in the induction of systemic lupus erythematosus (SLE), but there are only some observations of carbamazepine induced SLE since the first case described in 1966 [1], this Carbamazepine (CBZ) has been used as an anticonvulsant since 1962 and is a drug of choice for treatment of simple or complex partial seizures and generalized secondary seizures in both children and adults [2,3] and which could be responsible for many side effects including sleep disorders, anorexia, nausea, vomiting, irritability, ataxia and diplopia, yet, CBZ pulmonary toxicity is rare, because only few case reports of interstitial pneumonitis, bronchospasm, pulmonary edema, pulmonary nodules and bronchiolitis obliterans organizing pneumonia (BOOP) have been reported [4-6].

Our case demonstrates two rare side effects of this drug: the induced SLE and pulmonary nodules consistent with the BOOP which is really unusual and -to our knowledge- the second observation [7] reported in the literature.

CASE REPORT

A 59 -years- old man followed since the age of 12 years for epilepsy and was under treatment by CBZ since one year.

He presented after 2 months of the use of CBZ, erythematous plaques like the butterfly wings on the face according to the patient tell and erythema on the back, the hands and feet with photosensitivity, inflammatory arthralgias and intermittent dry cough.

Clinical examination found bilateral malar erythematous plaques (Fig. 1) and erythematous plaques of the neckline, the back and the dorsal surface of the hands and purpuric plaques at the palmar surfaces of the hands and soles of the feet (Figs. 2 and 3) with a nibbled appearance on pulps of the fingers and erythematous alopecia patches of the scalp.

Initial Blood investigations revealed anemia (haemoglobin of 10.5 g/dl), thrombocytopenia (platelet count of 100 000/mm^3), leukopenia (white cell count of 1900/mm^3) and especially lymphopenia (lymphocytes

How to cite this article: Kelati A, Gallouj S, Meziane M, Mernissi FZ. Lupus and pulmonary nodules consistent with bronchiolitis obliterans organizing pneumonia induced by carbamazepine in a man. Our Dermatol Online. 2016;7(4):445-447.

Submission: 29.01.2016; **Acceptance:** 07.03.2016

DOI:10.7241/ourd.20164.122

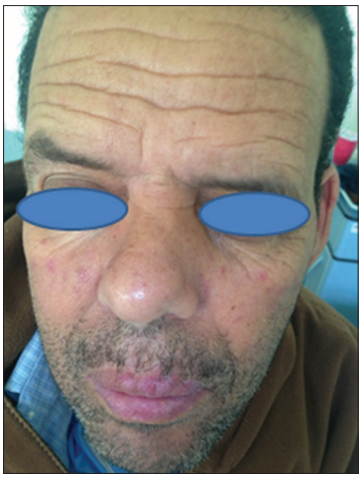

Figure 1: Clinical image showing bilateral malar erythematous plaques of lupus.

Figure 3: Clinical image showing erythematous purpuric plaques at the soles of the feet.

Figure 2: Clinical image showing erythematous purpuric plaques at the palmar surfaces of the hands.

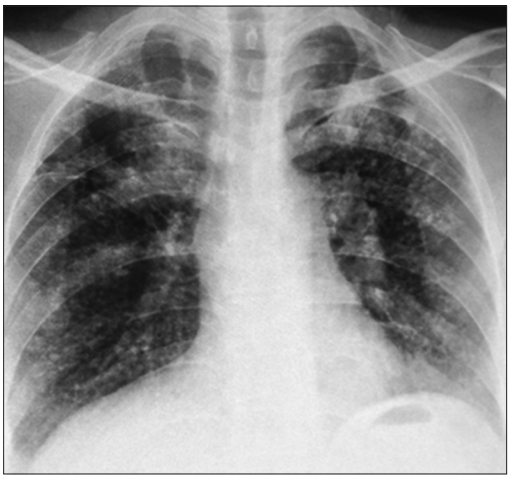

Figure 4: The chest radiography image demonstrating bilateral interstitial infiltrates with multiple lung nodules.

count of 1000/mm^3) with a positive rate of antinuclear antibodies in a titer of l/160, anti-dsDNA: 100 u/ml and positive rate of anti-histones without complement deficiency. The erythrocyte sedimentation rate and the levels of C-reactive protein were slightly increased (35 mg/L and 50 mm/h).

The skin biopsy confirmed the diagnosis of lupus. The chest radiography demonstrated bilateral interstitial infiltrates with multiple lung nodules (Fig. 4) more visible in the chest tomographic scan (Fig. 5), so a pulmonologist advice was asked and an infectious or occupational (silicone) origin were eliminated. The histological examination of this pulmonary infiltrate was not performed.

Ultimately, the diagnosis of CBZ induced lupus was retained based on clinical, biological and histological criteria and after the pharmacovigilance advice. In addition, the lung lesions were diagnosed as BOOP also induced by the CBZ.

Based on these facts, the CBZ was stopped and we prescribed a low dose of corticosteroids to our patient (0.5 mg/kg/j) and Hydroxychloroquine with a good evolution.

DISCUSSION

The drug induced lupus has been known since more than 50 years. In 1945, this diagnosis was suggested by Hoffman [8] and has been described in 1952 with Hydralazine, since then, hundreds of publications have been devoted to this subject [9-11], including some cases of CBZ induced SLE since Simpson described the first case in 1966 [8,12-14].

Figure 5: The chest tomographic scan image showing nodules of Bronchiolitis Obliterans Organizing Pneumonia.

On the other hand, BOOP is a nonspecific scarring process that occurs in response to injury of the bronchioles, it is characterized histologically by the presence of inflammatory fibrinous plugs obstructing the terminal and respiratory bronchioles (bronchiolitis obliterans) and extending into the alveolar ducts and adjacent alveoli (organizing pneumonia) [15]. It was first described in 1985 as an idiopathic entity and rarely a secondary process in several clinical settings, such as wegener granulomatosis, lymphoma or other neoplasms, bronchiectasis, acute respiratory infections, radiation treatment, or appear idiopathically [6]. BOOP has been also described in association with the use of some drugs like the acebutolol, amiodarone, cephalosporin, bleomycin, tryptophan, gold salts, barbiturates, sulfasalazine, o-penicillamine, [7] and in one case, it was described as a side effect of CBZ in a lupus patient, as the case of our patient which is the second observation reported.

Generally, both the induced lupus and the BOOP have usually a good outcome after the cessation of the drug [6], and corticosteroids improves the visceral involvement in the systemic lupus, which was the case of our patient.

CONCLUSION

The originality of our case is the rare induction of SLE and BOOP by Carbamazepine in a man, which represent another real warning regarding this drug use.

Consent

The examination of the patient was conducted according to the Declaration of Helsinki principles.

REFERENCES

1. Simpson JR. "Collagen disease" due to carbamazepine (Tegretol). BMJ. 1966;2:1434.
2. Goncalves D, Moura R, Ferraz C, Vitor AB, Vaz L. Carbamazepine-induced interstitial pneumonitis associated with pan-hypogammaglobulinemia. Respir Med Case Rep. 2012;5:6-8.
3. Loiseau P. Carbamazepine: clinical efficacy and use in epilepsy. Antiepileptic drugs. 5th ed. Philadelphia: Lippincott Williams & Wilkins; 2002:262-72.
4. Archibald N, Yates B, Murphy D, Black F, Lordan J, Dark J, Corris PA. Carbamazepine-induced interstitial pneumonitis in a lung transplant patient. Respir Med. 2006;100:1660-2.
5. Banka R, Ward MJ. Bronchiolitis obliterans and organising pneumonia caused by carbamazepine and mimicking community acquired pneumonia. Postgrad Med J. 2002;78:621-2.
6. Tamada T, Nara M, Tomaki M, Ashino Y, Hattori T. Secondary bronchiolitis obliterans organising pneumonia in a patient with carbamazepine-induced hypogammaglobulinemia. Thorax. 2007;62:100.
7. Milesi-Lecat AM, Schmidt J, Aumaitre O, Kemeny JL, Moinard J, Piette JC. Lupus and pulmonary nodules consistent with bronchiolitis obliterans organizing pneumonia induced by carbamazepine. Mayo Clin Proc. 1997;72:1145-7.
8. Hoffman BJ. Sensitivity of sulfadiazine resembling acute disseminated lupus erythematosus. Arch Dermatol Syph. 1945;51:130-2.
9. Morrow JD, Schroeder HA, Perry HM. Studies on the control of hypertension by hyphex. II. Toxic reactions and side effects. Circulation. 1953;8:829-39.
10. Le Goff P, Saraux A. Les lupus induits. Rev Rhum [Ed Fr]. 1999;66:43-8.
11. Masson C, Couchouron T, Audran M. Lupus induits. Rev Rhumat. 2005;72:168-75.
12. Molina-Ruiz AM, Lasanta B, Barcia A, Pérez-Vega E, Requena L. Drug-induced systemic lupus erythematosus in a child after 3 years of treatment with carbamazepine. Australas J Dermatol. 2015 Sep 30.
13. Harnett DT, Chandra-Sekhar HB,Hamilton SF. Drug-induced lupus erythematosus presenting with cardiac tamponade: a case report and literature review. Can J Cardiol. 2014;30:247.e11-2.
14. Pelizza L, De luca P, La Pesa M, Minervino A. Drug-induced systemic lupus erythematosus after 7 years of treatment with carbamazepine. Acta Biomed. 2006;77:17-9.
15. Gray R E. Bronchiolitis Obliterans Organizing Pneumonia. Arch Intern Med. 2001;161:158-64.

Copyright by Awatef Kelati, et al. This is an open access article distributed under the terms of the Creative Commons Attribution License, which permits unrestricted use, distribution, and reproduction in any medium, provided the original author and source are credited.

Source of Support: Nil, **Conflict of Interest:** None declared.

Case Report

Miliaria pustulosa misdiagnosed as a case of acne vulgaris

Iqbal Bukhari[1], Aala Alayoubi[1], Muhannad Alzahrani[2]

[1]Dermatology Department, College of Medicine, University of Dammam and King Fahd Hospital of the University, Dammam, Saudi Arabia, [2]Medical student, College of Medicine, University of Dammam and King Fahd Hospital of the University, Dammam, Saudi Arabia

Corresponding author: Prof. Iqbal A. Bukhari, E-mail: ibukhari@uod.edu.sa

ABSTRACT

Miliaria is a skin disorder of eccrine glands. Based on the level of sweat duct obstruction, miliaria is subdivided into three main types: Miliaria crystallina, miliaria rubra and miliaria profunda. Besides, resident skin bacteria are thought to play a role in its pathogenesis. In this report we are presenting a case of miliaria pustulosa which was misdiagnosed initially as a case of acne vulgaris.

Key words: Miliaria; Eccrine gland; Sweat duct; Acne vulgaris

INTRODUCTION

Miliaria is a common skin disorder of eccrine glands. It is common in hot and humid climates such as in the tropics. Usually children and infants are more prone due to their underdeveloped sweat glands. Based on the level of sweat duct obstruction, miliaria is subdivided into three main types: Miliaria crystallina, miliaria rubra and miliaria profunda [1]. Resident skin bacteria, such as *Staphylococcus epidermidis* and *Staphylococcus aureus*, are thought to play a role in the pathogenesis of miliaria [2,3]. In this report we are presenting a case of miliaria pustulosa which was wrongly diagnosed for 6 months as a case of acne vulgaris. Mismanagement of such cases may rarely predispose the patient to severe complication due to the resulting anhidrosis.

Case Report

A 20 year-old Arabic male presented to our dermatology clinic with history of pruritic erythematous papular lesions affecting his chest, back and upper and lower extremities for the past 6 months (Fig. 1). The condition started during exercise at the gym and worsened after exposure to high temperature with profuse sweating. The patient discontinued going to the gym for 3 months during which the lesions disappeared completely without any treatment. Four weeks before presenation he started going to the gym and the condition recurred with more severe rash. His past medical history, family history and drug history was unremarkable. He was diagnosed in different private clinics as a case of acne vulgaris and treated with different topical and systemic antibiotics but with no response. On examination of the skin there was 1-2 mm non-follicular erythematous vesicles and pustules distributed over the chest, back and few on extremities. There was no comedones. Systemic evaluation was normal. So our differntial diagnosis included miliaria pustulosa, acne vulgaris and drug eruption. His laboratory investigations including complete blood count, liver function and renal function tests were within normal. A skin punch biopsy revealed intraepidermal vesicle, intraepidermal neutrophilic pustule with several lymphocytes and histiocytes, mild parakeratosis and absent granular layer. The dermis showed superficial moderate perivascular and periadnexal inflammatory lymphocytic infiltration. Gram stain and Periodic acid schiff stain were negative. So the case was diagnosed as a case of miliaria pustulosa. We instructed the patient to avoid hot humid weather

How to cite this article: Bukhari I, Alayoubi A, Alzahrani M. Miliaria pustulosa misdiagnosed as a case of acne vulgaris. Our Dermatol Online. 2016;7(4):448-450.

Submission: 28.03.2016; **Acceptance:** 02.05.2016

DOI:10.7241/ourd.20164.123

Figure 1: Classical miliaria lesions on the chest of patient with small erythematous non-follicular papules.

environment and physical exercise. Initially we started him on topical soothing agent, mild topical steroid and topical mupiricin for two weeks. Upon follow up, the condition was almost the same so we started him on oral doxycycline 100 once daily for 6 weeks after which the condition completely resolved.

DISCUSSION

Miliaria is a common disorder of the eccrine glands. It commonly occurs in tropical humid environments. Individuals prone to this condition include: Infants, children, athletes, obese or overweight persons, military troops, bedridden patients and individuals with congenital absence or decreased sweating [4-6]. The disease affects both sexes equally and the most common affected site is the trunk, the upper back and the lower back. Miliaria is caused by occlusion of the sweat ducts. It is thought that the first event in the production of miliaria is an increase in Staphylocuccous epidermidis which produce a sticky substance occluding the eccrine ducts at different levels in the epidermis leading to the leakage of sweat into the epidermis or dermis leading to miliaria [7,8]. There are many clinical forms of miliaria based on the level of occlusion [1]. Miliaria crystallina or sudamina is caused by obstruction of the sweat ducts close to the surface of the skin and appears as small superficial clear vesicles that break easily not associated with any inflammatory reaction [9]. Miliaria rubra which is the most commonly encountered form in which obstruction causes leakage of sweat into the deeper layers of the epidermis, provoking a local inflammatory reaction and giving rise to the typical appearance of erythematous vesicular lesions. It is often accompanied by intense itching and anhidrosis to the affected areas [9]. There is a small risk of heat exhaustion due to inability to sweat if the patient continues to engage in heat-producing activity [10]. Miliaria profunda generally occurs as a complication of repeated episodes of miliaria rubra. The obstruction is located deep in the structure of the eccrine gland, causing the gland's secretions to leak between the superficial and deep layers of the dermis. The symptoms, tend to appear within hours of an activity provoking sweating but similarly fade within hours when the stimulus for the sweating is removed. Miliaria profunda is characterised by non-pruritic, flesh-colored, deep-seated papules [9]. Miliaria pustulosa occurs due to inflammation and bacterial infection. A rare complication of miliaria include postmiliarial hypohidrosis which can be severe enough to impair the individual's ability to perform sustained work in a hot environment [9]. Tropical anhidrotic asthenia is a rare form of miliaria, with long-lasting poral occlusion, which produces anhidrosis and heat retention [9,10].Occlusion miliaria is accompanied by anhidrosis and increased heat-stress susceptibility such as after the application of extensive polyethylene film occlusion for 48 hours or longer [9]. The differential diagnosis of miliaria include: Folliculitus, acne vulgaris, eczema, allergic rash, drug eruption and Grover's disease. In most cases the rash of miliaria will resolve without intervention. However, severe cases can last for weeks. General measures including moving to an air-conditioned environment, avoiding sweat-provoking activities, occlusive clothing, excessive soap and contact of the skin with irritants and taking frequent cool showers. To reduce the severity of symptoms topical agents that has soothing effect such as calamine or menthol or camphor-based preparations should be used. In moderately severe cases mild topical steroids and antibacterial creams can be used [11]. Our patient was an athelete who seemingly had recurrent miliaria rubra which was mismanaged as a case of acne vulgaris. Since he failed topical treatments we started him on oral antibiotic. The condition completely resolved after 6 weeks. It should be emphasized that taking good history and clinical examination in dermatology is mandatory to reach to a correct diagnosis. Besides, miliaria should be included in the differential diagnosis of papulopustular eruption in young atheletic individual and should not be restricted to neonates.

REFERENCES

1. Hashimoto K, Gross BG, Lever WF. The ultrastructure of the skin of human embryos. I. The intraepidermal eccrine sweat duct. J Invest Dermatol. 1965;45:139.

2. Holzle E, Kligman AM. The pathogenesis of miliaria rubra. Role of the resident microflora. Br J Dermatol. 1978;99:117-37.
3. Mowad CM, McGinley KJ, Foglia A, Leyden JJ. The role of extracellular polysaccharide substance produced by Staphylococcus epidermidis in miliaria. J Am Acad Dermatol. 1995;33:729-33.
4. Al-Hilo M, Al-Saedy S, Alwan A. Atypical Presentation of Miliaria in Iraqi Patients Attending Al-Kindy Teaching Hospital in Baghdad: A Clinical Descriptive Study. Am J Dermatol Venereol. 2012;1:41-6.
5. Hidano A, Purwoko R, Jitsukawa K. Statistical survey of skin changes in Japanese neonates. Pediatr Dermatol. 1986;3:140-4.
6. Moosavi Z, Hosseini T. One-year survey of cutaneous lesions in 1000 consecutive Iranian newborns. Pediatr Dermatol. 2006;23:61-3.
7. Szabo G. The number of eccrine sweat glands in human skin, in Advances in Biology of Skin, edited by Montagna W, Ellis R, Silver A. New York, Pergamon, 1962, p 1
8. Sato K, Dobson RL. Regional and individual variations in the function of the human eccrine sweat gland. J Invest Dermatol. 1970;54:443.
9. James WD, Berger T, Elston D. Andrews' Diseases of the Skin: Clinical Dermatology. Saunders Elsevier 2015.
10. Rapini RP, Bolognia JL, Jorizzo JL. Dermatology: 2-Volume Set. St. Louis: Mosby. 2007;541.
11. Carter R, Garcia A, Souhan B. Patients presenting with miliaria while wearing flame resistant clothing in high ambient temperatures: A case series. J Med Case Report. 2011;5:474.

Copyright by Iqbal Bukhari, et al. This is an open access article distributed under the terms of the Creative Commons Attribution License, which permits unrestricted use, distribution, and reproduction in any medium, provided the original author and source are credited.

Source of Support: Nil, **Conflict of Interest:** None declared.

Case Report

Cutaneous actinomycosis. A case report

Tomasz Wasyłyszyn[1,2], Katarzyna Borowska[3,4]

[1]Medical Center Gabinet Dermatologiczny Tomasz Wasyłyszyn, 25/421 Generała Andersa Street, 00-159 Warsaw, Poland, [2]Department of Dermatology, Military Institute of Medicine in Warsaw, Szaserów, 128 Street, 04-141 Warsaw, Poland, [3]Medical Center CADERM, 87/113 Marszalkowska Street, 00-683 Warsaw, Poland, [4]Department of Histology and Embryology with Experimental Cytology Unit, Medical University of Lublin, 11 Radziwiłowska Street, 20-080 Lublin, Poland

Corresponding author: Prof. Katarzyna Borowska, E-mail: k_borowska@wp.pl

ABSTRACT

A 27 year old patient presented a swollen lesion in the right mandibular area. Prior to the visit the patient was diagnosed with acne and was treated for 6 consecutive months with oral limecycline with no positive response. During the visit the cervicofacial actinomycosis was diagnosed and the patient was administered treatment containing oral amoxycilin plus clavulanic acid among others. The skin lesion disappeared within three weeks. The authors discuss this case in spite of diagnostic difficulties of this uncommon condition, especially while differentiating from acne conglobata.

Key words: Actinomycosisl; Cicatrical alopecia; Sinuses; Acne conglobata

INTRODUCTION

The term "Actinomycosis" was derived from the Greek terms aktino, which refers to the radiating appearance of a sulfur granule, and mykos, which labels the condition a mycotic disease. Actinomycosis is a rare subacute or chronic bacterial infection caused by Gram positive, anaerobic or microaerophilic bacilli, Actinomyces spp. These are higher prokaryotic bacteria belonging to the family Actinomyceataceae. Actinomycosis israelii as the causative organism was isolated in 1891 [1].

In most cases the disease spreads endogenously as a secondary infection from the infection foci in the oral cavity, especially from those related to teeth like in the present study. In rare cases though the primary skin actinomycosis may occur [2]. Cervicofacial actinomycosis is the most common form of the disease found in the skin; other forms including soft tissue tumors [3] or coexistence of other bacterial or fungal infections [4] making the diagnosis even more difficult.

CASE REPORT

A twenty-six years old man presented a skin lesion having the form of reddish indurated complex of nodules, located in the mandibular area (Fig. 1). Patient confirmed the appearance of the lesion from at least one year ago, followed by complicated endodontic treatment. During the next few months the patient was diagnosed with "acne" and treated with systemic limecycline (300 mg daily for three months, then 150 mg daily for an additional three months) with little or no response.

A physical examination revealed that the lesion was palpably hard, having the consistence of cartilage. It was moderately painful. Submandibular lymph nodes were not swollen. The area over the nodules bore the evidence of scaring with permanent hair loss over the beard (cicatrical alopecia). Further examination showed the presence of the sinuses in the central part of the lesion. Gently pressing the lesion allowed to evacuate a few milliliters of pus which contained small yellowish so called "grains of sulfur".

Considering the above the diagnosis of cervicocranial actinomycosis was stated. The patient was administered orally: amoxycilin plus clavulanic acid (875 mg + 125 mg) twice a day for three weeks, nabumetonum 500mg once a day for ten days; topically an aerosol containing neomycine plus dexamethasone twice a day

How to cite this article: Wasyłyszyn T, Borowska K. Cutaneous actinomycosis. A case report. Our Dermatol Online. 2016;7(4):451-452.
Submission: 66.05.2016; **Acceptance:** 31.08.2016
DOI: 10.7241/ourd.2016.4.124

Figure 1: Initial status. Please note swollen area bearing the evidence of cicatrical alopecia.

Figure 2: Status after the treatment. The lesion disappeared however the scaring on the skin of the cheek remained.

during whole course of treatment. A control visit after three weeks revealed the disappearance of the lesion however the scaring on the skin of the cheek remained (Fig. 2). The patient was advised to use an ointment containing 2% chloramphenicol (twice a day for three months) in order to prevent recurrence.

DISCUSSION

Cervicofacial actinomycosis is typically differentiated from tertiary syphilis and tuberculosis, in the 21st century though there are very little cases of both, especially in Europe and North America. It seems that younger generations of dermatologists from which the majority have never seen neither tertiary syphilis nor skin tuberculosis may have problems with diagnosing conditions which are clinically similar.

In the present case even given the evidence, well prepared dermatologists may have problems with differentiating actinomycosis from quite common *acne conglobata*. In both conditions there are nodules, there may be sinuses; the course is long and the location may be similar. In contrary to actinomycosis, *acne conglobata* lesions are soft, they may be located in upper parts of the face and some lesions disappear while others appear in other places. But the most evident symptom of actinomycosis is the presence of so called "sulfur granules", yellow structures being in fact the colonies of Actinomyces Israeli. The later ones are present in most types of the disease, even in cutaneous fistulas in pulmonary actinomycosis [1].

Unlike acne, actinomycosis responds well to the treatment with penicillins [1,2]. In milder cases the antimicrobic treatment accompanied with the administration of anti inflammatory drugs gives satisfactory results. In more serious cases, which may involve the mandibular bone, surgical intervention is necessary.

REFERENCES

1. Mabeza G.F., Macfarlane J. Pulmonary actinomycosis. Eur Respir J. 2003;21:545-51.
2. Nair PA, Bodiwala NA, Patel SA, Patel KB. A rare case of cutaneous actinomycosis. Indian Dermatol Online J. 2013;4:157-8.
3. Akhtar M, Zade MP, Shahane PL, Bangde AP, Soitkar SM. Scalp actinomycosis presenting as soft tissue tumour: A case report with literature review. Int J Surg Case Rep. 2015;16:99–101.
4. Beniwal NS, Arora S, Baveja S, Sood A, Mehta R, Bal AS. Coexistent Actinomycosis and Eumycetoma in an Immunocompetent Patient. Indian J Dermatol. 2014;59:413-4.

Copyright by Tomasz Wasyłyszyn, et al. This is an open access article distributed under the terms of the Creative Commons Attribution License, which permits unrestricted use, distribution, and reproduction in any medium, provided the original author and source are credited.
Source of Support: Nil, **Conflict of Interest:** None declared.

Case Report

Ainhum: Clinical, radiographic and therapeutic aspects, about 3 cases

Amina Nomtondo Ouédraogo[1], Patrick Wendpouiré Hamed Dakouré[2], Maodo Ndiaye[3], Seraphine Zeba/Lompo[4], Fagnima Traoré[5], Sayouba Tinto[6], Sidnoma Muriel Ouédraogo[7], Patrice Gilbert Tapsoba[7], Pascal Niamba[7], Fatou Barro-Traoré[7], Adama Traoré[7]

[1]Department of Dermatology, University Ouaga I Professor Joseph Ki-Zerbo, Raoul Follereau Dermatology Center, Ouagadougou, Burkina Faso, [2]Department of Surgery, High Institut of Health Sciences, Orthopaedics and Traumatology Service, University Hospital Souro Sanou, Bobo Dioulasso, Burkina Faso, [3]Departement of Dermatology, Cheick Anta Diop University Dakar, Dermatology clinic, Aristide Le Dantec University Hospital, Dakar, Senegal, [4]Raoul Follereau Dermatology Center, Ouagadougou, Burkina Faso, [5]Dermatology Service of Regional Hospital of Ouahigouya, Burkina Faso, [6]Department of Surgery, University Ouaga I Professor Joseph Ki-Zerbo, Orthopaedics and Traumatology Service, University Hospital Yalgado Ouédraogo, Ouagadougou, Burkina Faso, [7]Department of Dermatology, University Ouaga I Professor Joseph Ki-Zerbo, Dermatology Service University Hospital Yalgado Ouédraogo, Ouagadougou, Burkina Faso

Corresponding author: Dr. Amina Nomtondo Ouédraogo, E-mail: nomtondo2000@yahoo.fr

ABSTRACT

The ainhum or spontaneous dactylolysis is a rare pathologic condition in which a hyperkeratosis necking groove is formed around the proximal portion of the fifth toe leading to its auto-amputation. They were three all male patients, aged 32-52 years, without concept of smoking, or similar family pathology, no notion of barefoot walking long distances or previous trauma. They consulted for pain of the fifth toe or for a desire of amputation of the fifth toe. Disease duration ranged from 18 months to 6 years. On examination, the patient was in good condition without fever. We noted a keratotic consistency constriction ring loose or tight enclosing the base of the right fifth toe. The other ends were free from any constriction. Radiography of the foot noted constriction adjacent soft parts in all patients and bone involvement in 2 patients. The diagnosis of aïnhum was made. A surgical treatment with Z-plasty or amputation was performed. The outcome was favorable with no uncommitted functional prognosis.The ainhum spontaneous is a rare disease, the diagnosis is clinical. The prognosis after surgical treatment is favorable. These observations by their diversity show different aspects of aïnhum.

Key words: Dactylolysis spontaneous; Self-amputation; Z-plasty; Dry gangrene

How to cite this article: Ouédraogo AN, Dakouré PWH, Ndiaye M, Zeba/Lompo S, Traoré F, Tinto S, Ouédraogo SM, Tapsoba PG, Niamba P, Barro-Traoré F, Traoré A. Ainhum: Clinical, radiographic and therapeutic aspects, about 3 cases. Our Dermatol Online. 2016;7(4):453-458.

Submission: 17.08.2016; **Acceptance:** 18.09.2016

DOI:10.7241/ourd.20164.125

Case Report

Aïnhum: Aspects cliniques, radiographiques et thérapeutiques à propos de 3 cas

Amina Nomtondo Ouédraogo[1], Patrick Wendpouiré Hamed Dakouré[2], Maodo Ndiaye[3], Seraphine Zeba/Lompo[4], Fagnima Traoré[5], Sayouba Tinto[6], Sidnoma Muriel Ouédraogo[7], Patrice Gilbert Tapsoba[7], Pascal Niamba[7], Fatou Barro-Traoré[7], Adama Traoré[7]

[1]Department of Dermatology, University Ouaga I Professor Joseph Ki-Zerbo, Raoul Follereau Dermatology Center, Ouagadougou, Burkina Faso, [2]Department of Surgery, High Institut of Health Sciences, Orthopaedics and Traumatology Service, University Hospital Souro Sanou, Bobo Dioulasso, Burkina Faso, [3]Departement of Dermatology, Cheick Anta Diop University Dakar, Dermatology clinic, Aristide Le Dantec University Hospital, Dakar, Senegal, [4]Raoul Follereau Dermatology Center, Ouagadougou, Burkina Faso, [5]Dermatology Service of Regional Hospital of Ouahigouya, Burkina Faso, [6]Department of Surgery, University Ouaga I Professor Joseph Ki-Zerbo, Orthopaedics and Traumatology Service, University Hospital Yalgado Ouédraogo, Ouagadougou, Burkina Faso, [7]Department of Dermatology, University Ouaga I Professor Joseph Ki-Zerbo, Dermatology Service University Hospital Yalgado Ouédraogo, Ouagadougou, Burkina Faso

Corresponding author: Dr. Amina Nomtondo Ouédraogo, E-mail: nomtondo2000@yahoo.fr

RESUME

L'aïnhum ou dactylolyse spontanée est une condition pathologique rare au cours de laquelle une striction hyperkératosique est formée autour de la partie proximale du 5ème orteil conduisant à son auto-amputation. La maladie intéresse le 5ème orteil de façon unilatérale ou bilatérale . Elle a été rapportée chez les sujets de race noire d'Afrique, mais aussi de l'Amérique du sud, de l'Asie et de l'Inde. Nous rapportons 3 cas d'aïnhum chez des patients burkinabés. Il s'agissait de 3 patients tous de sexe masculin, âgés de 32 à 52 ans, sans notion de tabagisme, ni de pathologie familiale similaire, ni de notion de marche prolongée pied nus, ni de traumatisme antérieur. Ils consultaient soit pour une douleur du 5ème orteil, soit pour un désir d'amputation du 5ème orteil. La durée d'évolution variait de 18 mois à 6 ans. A l'examen, les patients étaient en bon état général et apyrétiques. On notait un anneau de striction de consistance kératosique lâche ou serré enserrant la base du 5ème orteil droit. Les autres extrémités étaient indemnes de toute constriction. La radiographie du pied notait une constriction des parties molles adjacentes chez tous les patients et une atteinte osseuse chez deux patients permettant de poser le diagnostic d'aïhnum. Un traitement chirurgical par plastie en Z ou par amputation était réalisée. L'évolution était favorable et le pronostic fonctionnel n'était pas engagé. L'aïnhum ou dactylolyse spontanée du 5ème orteil est une pathologie rare, plus souvent rapportée chez les sujets de race noire. Le diagnostic est clinique. Le pronostic après le traitement chirurgical est favorable. Ces observations par leur diversité montrent les différents aspects cliniques et évolutifs de l'aïnhum.

Mots clés: Dactylolyse spontanée; Auto-amputation; Plastie en Z; Gangrène sèche

INTRODUCTION

L'aïnhum aussi appelée dactylolyse spontanée est une condition pathologique rare au cours de laquelle une striction hyperkératosique est formée autour de la partie proximale du 5ème orteil conduisant à son auto-amputation [1]. La maladie intéresse le 5ème orteil de façon unilatérale, mais des cas bilatéraux ont été rapportés [2]. Elle a été décrite chez les sujets de race noire d'Afrique, mais aussi de l'Amérique du Sud et de

How to cite this article: Ouédraogo AN, Dakouré PWH, Ndiaye M, Zeba/Lompo S, Traoré F, Tinto S, Ouédraogo SM, Tapsoba PG, Niamba P, Barro-Traoré F, Traoré A. Aïnhum: Aspects cliniques, radiographiques et thérapeutiques à propos de 3 cas. Our Dermatol Online. 2016;7(4):453-458.

Submission: 17.08.2016; **Acceptance:** 18.09.2016

DOI:10.7241/ourd.20164.125

l'Inde [1,3,4]. Des facteurs infectieux et traumatiques liés à un mode vie rural ont été souvent incriminés dans sa survenue mais actuellement cette théorie semble de moins en moins évoquée [2].

L'histoire naturelle de l'aïnhum peut être décrite en quatre stades différents, allant d'une fissure à la face plantaire du 5ème orteil jusqu'à l'auto-amputation de l'orteil [5]. En dehors des aïnhums vrais d'étiologie inconnue, il existe des pathologies pouvant conduire à des états pseudo-aïnhumoïdes telles que la kératodermie palmoplantaire héréditaire de Vohwinkel, des maladies acquises comme l'arthropathie goutteuse, la lèpre,, les corps étrangers etc [6,11].

Si le traitement au stade de début fait recours à une plastie en Z, dans les stades avancés, l'amputation spontanée ou chirurgicale reste la seule issue [1,12].

Nous rapportons 3 cas d'aïnhum chez des patients burkinabés, tous de sexe masculin et ne présentant pas de tableau de pseudo-aïnhum des doigts et des orteils.

CASE REPORTS

Patient 1: Monsieur K S était âgé de 32 ans de sexe masculin, sans notion de tabagisme, ni de pathologie familiale similaire, ni de notion de marche prolongée pieds nus, ni de traumatisme antérieur. Il a consulté en dermatologie, pour une constriction du 5ème orteil droit évoluant depuis 6 ans. La lésion aurait débuté par un petit anneau constrictif à la base du petit orteil droit qui se serait lentement élargi, avec des douleurs intermittentes de l'orteil lors du port de chaussures serrées. A l'examen, le patient était en bon état général et apyrétique. On notait un anneau de constriction lâche d'environ 0,5 cm de largeur, de consistance kératosique enserrant la base du 5ème orteil droit (Figs 1 et 2). On notait un intertrigo macéré à la face plantaire de l'orteil. Les autres extrémités y compris le 5ème orteil gauche étaient indemnes de toute constriction. A l'examen neurologique, la douleur n'était pas de type neuropathique. Le reste de l'examen physique était normal ainsi que les examens biologiques (NFS, uricémie, glycémie à jeun, créatininemie, transaminases seriques). La sérologie syphilitique et l'examen du suc dermique à la recherche de bacille de Hansen étaient négatifs. La radiographie du pied ne notait pas d'atteinte osseuse, mais une discrète constriction des parties molles adjacentes. Le diagnostic d'aïnhum au stade I était posé. Un traitement à base d'antifongique topique et une cure chirurgicale consistant en une plastie en Z étaient proposés au patient. Le patient était perdu de vue.

Patient 2: Z N âgé de 50 ans, sans notion de tabagisme, ni de pathologie familiale similaire, ni de notion de marche prolongée pieds nus, ni de traumatisme antérieur a consulté en dermatologie, pour des douleurs lancinantes, insomniantes du 5ème orteil gauche, avec une gêne à la marche évoluant depuis 5 ans, mais aggravées depuis quelques mois. A l'examen, le patient était en bon état général et apyrétique. On notait une striction très serrée par une bande kératosique de la base du 5ème orteil gauche (Figs. 3 et 4). L'orteil en aval était noirâtre avec une diminution de la sensibilité tactile et algésique. La partie en amont de la striction était douloureuse à la mobilisation. Les autres extrémités y compris le 5ème orteil droit étaient indemnes de toute constriction. L'examen neurologique ne mettait pas en évidence une douleur neuropathique.

Figure 1: Aïnhum au stade I avec anneau de constriction à la base du 5ème orteil du patient 1.

Figure 2: Iconnographie des deux pieds du patient 1: atteinte du 5ème orteil droit, 5ème orteil gauche intact.

Le reste de l'examen physique était normal ainsi que les examens biologiques (NFS, uricémie glycémie à jeun, créatininemie, transaminases seriques). La sérologie syphilitique et l'examen du suc dermique à la recherche de bacille de Hansen étaient négatifs. La radiographie du pied notait une ostéolyse en regard de la striction ainsi qu'une striction serrée des parties molles. Le diagnostic d'aïnhum stade 3 était posé. Un antalgique était prescrit et une amputation de l'orteil réalisée. L'évolution après traitement était favorable.

Patient 3: Monsieur A C, âgé de 52 ans, sans notion de tabagisme, ni de pathologie familiale similaire, ni de notion de marche prolongée pieds nus, ni de traumatisme antérieur a consulté en orthopédie, pour un désir d'amputation de son 5ème orteil droit qui présentait des douleurs lancinantes, insomniantes, avec une gêne à la marche. La symptomatologie était d'aggravation progressive depuis 18 mois. L'examen physique notait une striction de la base du 5ème orteil droit par une bande kératosique très serrée. La partie en aval de l'orteil était globuleuse, déviée de son axe normal et douloureuse à la mobilisation (Fig. 5). Le patient était en bon état général, apyrétique, et les autres extrémités y compris le 5ème orteil gauche étaient indemnes de toute constriction. L'examen neurologique ne mettait pas en évidence une douleur neuropathique. Le reste de l'examen physique était normal ainsi que les examens biologiques (NFS, uricémie, glycémie à jeun, créatininemie, transaminases seriques). La sérologie syphilitique et l'examen du suc dermique à la recherche de bacille de Hansen étaient négatifs. La radiographie du pied notait une ostéolyse en regard de la striction avec une constriction des tissus mous. Le diagnostic d'aïnhum stade 3 était posé, un antalgique prescrit et une amputation réalisée (Fig. 3). L'évolution après traitement était favorable.

DISCUSSION

La première description d'aïnhum a été faite en 1860 par Clarke, comme étant une gangrène sèche du petit orteil survenant chez des sujets originaires d'Afrique de l'Ouest [2]. En 1867, Da Silva Lima et Wucherer ont introduit le terme d'«aïnhum» tiré d'un dialecte d'Afrique et signifiant «vu» [13]. Il intéresse le 5ème orteil, fait d'une constriction fibreuse, kératosique enserrant le pli plantaire de l'orteil y créant une douleur lancinante. La constriction est légère au stade I de début, comme chez notre premier patient. Cette bande constrictive va progressivement se resserrer, donnant

Figure 3: Iconographie du pied gauche du patient 2 montrant l' aïnhum au stade 3.

Figure 4: Iconographie du patient 2 montrant l'aïnhum sur une vue de la face plantaire du pied.

Figure 5: Iconographie du patient 3 montrant l'aïnhum stade 3, avant et après amputation.

les stades 2 et 3 (cas de nos patients 2, 3) créant une gangrène sèche de l'orteil, jusqu'à l'amputation complète de l'orteil, correspondant au stade 4 [2]. Une atteinte osseuse est retrouvée dans les derniers stades, tandis que la constriction des parties molles est observée dans tous les cas [2,14,15].

L'aïnhum constitue une affection rare puisque quelques cas sont rapportés dans la littérature [2,14,16]. Il survient principalement chez les sujets d'ascendance africaine et majoritairement de sexe masculin comme observé chez nos patients. Cependant, dans la série de 3 cas rapportés par de Koudoukpo, tous les malades étaient de sexe féminin [12]. Le diagnostic est souvent tardif en milieu tropical, après une durée d'évolution moyenne supérieure à 18 mois chez nos malades. Et ceci s'expliquerait par le fait que les malades ne consultent qu'au stade de douleur invalidante.

Aucun de nos malades ne présentait de facteurs traumatiques susceptibles de créer une striction du 5ème orteil et d'autres lésions à distance pouvant s'intégrer dans le cadre d'une maladie générale. En effet, en zone tropicale devant toute mutilation spontanée de membre, il est important d'éliminer la maladie de Hansen ou une syphilis dans sa phase tardive. En outre, l'absence d'arthropathie chez nos malades et le taux normal de l'uricémie éliminaient le diagnostic d'une goutte.

Le pseudo-aïnhum peut survenir également dans les maladies de système à tropisme articulaire et vasculaire comme le lupus systémique, la sclérodermie systémique, la polyarthrite rhumatoïde et/ou les troubles de vascularisation des extrémités liés au diabète . Ces pathologies n'ont pas été retrouvées chez nos malades. De plus, il est important d'éliminer les tableaux de pseudo-aïhnums qui peuvent être retrouvés dans plusieurs troubles de la kératinisation tels que les kératodermies palmoplantaires congénitales ou acquises, le syndrome de Vohwinkel [10,11] la maladie de Papillon-Lefèvre [8], le mal du syndrome Méléda, l'hyperkératose acral focale dans le pityriasis rubra pilaire et la porokératose de Mibelli [7]. Souvent le caractère transgrédient ou progrédient, l'existence de lésions à distance et des cas similaires au sein de la famille y sont souvent associés.

L'étiopathogénie de l' aïnhum n'est pas encore bien élucidée, mais plusieurs hypothèses ont été émises:

-une production accrue de fibroplastes en réponse à un stimuli excessif lors d'infections ou de traumatismes répétés [14].

-une fibrose localisée formant une bande de collagène constrictive en réponse à des lésions tissulaires d' inflammation chronique, ou d'un processus de cicatrisation de l'orteil [7,17]. -une anomalie de la vascularisation du calcanéum par l'artère tibiale postérieure [5].

La prise en charge thérapeutique de l' aïnhum est chirurgicale. Elle fait recours à une plastie en Z au stade de début. Dans les stades avancés, l'amputation est de mise [18,19], et le patient peut être lui-même demandeur de cette amputation « salvatrice » devant la douleur intense, insomniante comme noté chez notre dernier patient. Malgré le risque de récidive après la plastie en Z, le pronostic fonctionnel n'est généralement pas engagé [18]. En effet, l'amputation aboutissant à une absence du dernier orteil ne gêne ni la marche, ni la station debout car l'appui du pied se fait sur le métatarse et le gros orteil.

CONCLUSION

L'aïnhum ou dactylolyse spontanée du 5ème orteil est une pathologie rare, plus souvent rapportée chez les sujets de race noire, mais également en Asie et en Inde . Le diagnostic positif est clinique. La radiographie permet mettre en evidence la constriction des parties molles et d'apprécier le degré de l'atteinte osseuse. Le traitement est chirurgical. Le pronostic fonctionnel est bon après traitement. L'intérêt de nos cas réside en leur diversité montrant les différents aspects cliniques et évolutifs du aïnhum.

RÉFÉRENCES

1. Cole GJ. Ainhum: an account of fifty-four patients with reference to etiology and treatment. J. Bone Joint Surg. 1965;47:43-51
2. Browne SG. Ainhum: a clinical and etiological study of 83 cases. Ann Trop Med Parasitol. 1961;55:314-20.
3. Jemmott T, Foster A V, Edmonds ME. An unusual cause of ulceration: ainhum (dactylolysis spontanea). Int Wound J. 2007;4:251-4.
4. Prabhu R, Subbaraju N K, Vinoth S, Balasubramanian C. Ainhum - A rare case report. J Clin Diagn Res. 2016;10:17-8.
5. Carvalho N, Silveira J, Rodrigues L, Tirado A, Ferreira M. Ainhum (Dactylolysis spontanea): a case report. Foot Ankle Surg. 2000;6:189-92.
6. Kanitakis J, Tsoitis G, Kanitakis C. Hereditary epidermolytic palmoplantar keratoderma (Vörner type): report of a familial case and review of the literature. J Am Acad Dermatol. 1987;17: 414-22.
7. Hohl D, Görög J P. Kératodermies palmoplantaires. Encycl Méd Chir Dermatologie. 1999;98-205-A10,18.
8. Mashhood A A, Humayun A, Saleem M, Arshi I. Papillon-Lefèvre syndrome associated with pseudoainhum. J Am Acad Dermatol. 2004;51:134-6.
9. Mrabet D, Monastiri I, Elleuch M, Meddeb N, Sellami S. Pseudoainhum in gout: A Case-Report. Joint Bone Spine. 2010;77:368-9.
10. Cavalcante L I de S, Holanda É de M, Almeida TLP de, Accioly-Filho J. W.Vohwinkel' s mutilating keratoderma: report of

three familial cases. An Bras Dermatol. 2003;78: 311-8.
11. Choudhary N, Ahar R, De A, Biswas P. Vohwinkel's syndrome: A rare disorder of keratinization. Indian J Dermatol. 2014;59:619.
12. Koudoukpo C, Bourrat E, Rausky J, Yédomon H, Bagot M, Blanchet-Bardon C, et al.Aïnhum et «kératodermies acrales africaines»: trois cas. Ann Dermatol Vénéréol. 2015;142,170-5.
13. Da Silva Lima JF. On ainhum. Arch Dermatol. 1880;6:367.
14. Daccarett M, Espinosa G, Rahimi F, Eckerman CM, Wayne-Bruton S, Couture M, et al. Ainhum (dactylolysis spontanea): a radiological survey of 6000 patients. J Foot Ankle Surg. 2002;41:372-8.
15. Barve DJ, Gupta A. Ainhum: A Spot Diagnosis. Indian J Surg. 2015;77:1411-2.
16. Bergner LH Winfield JM. Ainhum (dactylolysis spontanea): Review of the literature and report of a case. Am J Surg. 1960;100:480-5.
17. Morand JJ, Lightburn E. Aïnhum et pseudo-aïnhum. Panorama clinique et hypothèses étiopathogéniques. Méd Trop. 2002;62:166-70.
18. Maruis KF, Cedrick SM, Mireille KZ, Felix MJ. Maladie d'Aïnhum (dactylolyse spontanée): à propos d'un cas Clinique. Pan Afr Med J. 2014;19:60.
19. Roesch A, Kinner B, Schaechinger U, Obermann EC, Landthaler M, Hohenleutner U. A woman with a dangling digit. J Dtsch Dermatol Ges. 2007;11:1008-9.

Copyright by Amina Nomtondo Ouédraogo, et al. This is an open access article distributed under the terms of the Creative Commons Attribution License, which permits unrestricted use, distribution, and reproduction in any medium, provided the original author and source are credited.
Source of Support: Nil, **Conflict of Interest:** None declared.

Our Dermatology Online

Case Report

Kawasaki disease: First observation in a togolese child 3 years old

Koussake Kombaté[1,2], Julienne Noudé Teclessou[1,2], Nadiédjoa Kokou Douti[2,3], Bayaki Saka[1,2], Abla Séfako Akakpo[1,2], Abas Mouhari-Touré[4,5], Garba Mahamadou[1], Palokinam Pitche[1,2]

[1]Department of Dermatologic, Teaching Hospital of Lomé, Togo, [2]Department of Health Sciences, University of Lomé, Togo, [3]Department of Pediatrics, Teaching Hospital of Lomé, Togo, [4]Department of Dermatologic, Teaching Hospital of Kara, Togo, [5]Department of Health Sciences, University of Kara, Togo

Corresponding author: Prof. Koussake Kombaté, E-mail: rosekombat@yahoo.fr

ABSTRACT

Kawasaki disease, first cause of heart disease acquired in child in industrialized countries has been poorly described in Africa. We report a complete form of Kawasaki disease with dilatation of the coronary arteries in a patient. A 3 year old girl was seen in dermatology for persistent fever, itching and flaking broadcasts lasting for three weeks. At initial examination, she had a fever of 39.5°C, bilateral non-purulent conjunctivis, cheilitis, erythema and edema of the backs of the hands and feet moving toward membranous desquamation, non-purulent cervical lymphadenopathy and dilation of the coronary arteries. Acetylsalicylic acid and intravenous immunoglobulin allowed complete remission of clinical symptoms and regression of cardiac complications. This suggests that it is necessary to evoke Kawasaki disease in the presence of a fever in the long term that does not respond to the usual treatments accompanied by a rash and look for other manifestations of the disease.

Key words: Complete Kawasaki disease; Child; Lomé; Togo

How to cite this article: Kombaté K, Teclessou JN, Douti NK, Saka B, Akakpo AS, Mouhari-Touré A, Mahamadou G, Pitche P. Kawasaki disease: First observation in a togolese child 3 years old. Our Dermatol Online. 2016;7(4):459-464.

Submission: 22.06.2016; **Acceptance:** 30.08.2016

DOI: 10.7241/ourd.20164.126

Case Report

Maladie de Kawasaki: Premier cas togolais chez un enfant de 3 ans

Koussake Kombaté[1,2], Julienne Noudé Teclessou[1,2], Nadiédjoa Kokou Douti[2,3], Bayaki Saka[1,2], Abla Séfako Akakpo[1,2], Abas Mouhari-Touré[4,5], Garba Mahamadou[1], Palokinam Pitche[1,2]

[1]Dermatologic Department of Teaching Hospital of Lomé, Togo, [2]Health sciences Department of University of Lomé, Togo, [3]Pediatrics Department of Teaching Hospital of Lomé, Togo, [4]Dermatologic Department of Teaching Hospital of Kara, Togo, [5]Health Sciences Department of University of Kara, Togo

Corresponding author: Prof. Koussake Kombaté, E-mail: rosekombat@yahoo.fr

RESUME

La maladie de Kawasaki, première cause de cardiopathie acquise de l'enfant dans les pays industrialisés, a été très peu décrite en Afrique. Nous rapportons une forme complète de la maladie de Kawasaki avec dilatation des artères coronaires chez une patiente. Une fillette de 3 ans était emmenée en dermatologie pour une fièvre persistante, un prurit et une desquamation diffuse évoluant depuis trois semaines. A l'examen, elle avait une fièvre à 39,5°C, une conjonctivite bilatérale, une chéilite, un érythème et œdèmes aux dos des pieds et des mains évoluant vers une desquamation en doigts de gants, des adénopathies cervicales aiguës non suppuratives et une dilatation des artères coronaires.L'administration d'acide acétylsalicylique et des immunoglobulines intraveineuses a permis une rémission complète des manifestations cliniques et une régression des complications cardiaques. Cette observation suggère qu'il il faut évoquer la maladie de Kawasaki en présence d'une fièvre au long cours qui ne répond pas aux traitements usuels accompagné d'une éruption cutanée et rechercher d'autres manifestations de la maladie.

Mots clés: Maladie de Kawasaki complète; Enfant; Lomé; Togo

INTRODUCTION

La maladie ou syndrome adéno-cutanéo-muqueux de Kawasaki est une vascularite fébrile aiguë systémique qui touche principalement le jeune enfant et le nourrisson [1]. Elle a été décrite pour la première fois en 1967 par Tomisaku Kawasaki [2] et constitue la première cause de maladie cardiaque acquise de l'enfant dans les pays industrialisés [3]. Elle survient dans 80% à 90% chez les enfants de moins de 5 ans [3-5].

Bien que rapportée de par le monde entier [3], la maladie de Kawasaki est plus fréquente dans les populations asiatiques, en particulier au Japon. En Afrique, des cas de la maladie de Kawasaki ont également été rapportés [6-10], mais aucun cas n'a concerné le Togo. Nous rapportons un premier cas de la maladie de Kawasaki chez un enfant de 3 ans traité efficacement avec des immunoglobulines intraveineuses et de l'acide acétylsalicylique.

CASE REPORT

Une fillette de 3 ans était emmenée en consultation dermatologique pour une fièvre persistante, un prurit et une desquamation diffuse évoluant depuis trois semaines. Cette fièvre était résistante aux traitements antipyrétiques, aux antibiotiques et aux antipaludéens usuels.

La fillette était née par césarienne d'une grossesse gémellaire monoamniotique monochoriale à terme

How to cite this article: Kombaté K, Teclessou JN, Douti NK, Saka B, Akakpo AS, Mouhari-Touré A, Mahamadou G, Pitche P. Maladie de Kawasaki: Premier cas togolais chez un enfant de 3 ans. Our Dermatol Online. 2016;7(4):459-464.

Submission: 22.06.2016; **Acceptance:** 30.08.2016

DOI: 10.7241/ourd.20164.126

et les suites de couches étaient simples. La sœur jumelle était en bonne santé apparente. Il n'y avait pas d'histoire familiale de maladie de Kawasaki. A l'examen, le poids (15Kg) et la taille (96 centimètre) étaient normales pour son âge. L'enfant était en mauvais état général, très irritable, avec une hyperthermie à 39°5C et des œdèmes aux dos des pieds et des mains. A l'examen, il y avait une érythrodermie avec accentuation de l'érythème au niveau des plis, des paumes des mains et des plantes des pieds (Fig. 1). On notait une desquamation en lambeau plus accentuée au cuir chevelu, avec un aspect en doigt de gants au niveau des mains et des pieds (Fig. 2), une excoriation diffuse, des érosions et des fissures au cou, plis axillaires, plis inguinaux et creux poplités. Il n'y avait pas d'inflammation cutanée au site de vaccination par le BCG. Le signe de Nikolski était absent. On notait également une chéilite avec des lèvres rouge sèche fissuraire et une langue dépapillée. La muqueuse oropharyngée était érythémateuse entrainant une dysphagie. La muqueuse oculaire était le siège d'une conjonctivite bilatérale non purulente avec hyperhémie (Fig. 3) et un érythème palpébral. On notait une mélanonychie avec onycholyse distale des ongles des pieds et des mains. Les lésions cutanées étaient associées à des adénopathies cervicales mesurant environ 3mm de grand axe mobiles de consistance ferme n'adhérant pas au plan profond. Il n'y avait pas de douleur ou de masse abdominale à la palpation. Le reste de l'examen physique était normal.

A la biologie, il y avait un syndrome inflammatoire avec une vitesse de sédimentation à 90 mm à la 1ère heure, la protéine C-réactive à 245,01mg/l, une hypo albuminémie à 27,5g/l. L'hémogramme notait une anémie normocytaire normochrome à 9,5g/dl, une thrombocytose à 840.000/mm^3 et une hyperleucocytose à polynucléaires neutrophiles à 19.648 PNN/mm^3. Les fonctions rénale et hépatique étaient normales. La sérologie VIH, la goutte épaisse à la recherche du P*lasmodium falciparum*, l'hémoculture et l'examen cytobactériologique des urines étaient négatives. L'échographie doppler cardiaque avait objectivé une dilatation des artères coronaires droite (ostium coronaire droit = 3,5 à 3,9 millimètre, tronc droit = 4mm) et gauche (ostium coronaire gauche: 3,5mm à 3,8mm, tronc gauche 3,6mm) (Fig. 4).

Nous avons retenu le diagnostic de la maladie de Kawasaki en phase de complication cardiovasculaire et mis la patiente sous Immunoglobuline intraveineuse à la dose unique de 2g/kg à passer par paliers en 12 heures associée 75mg/kg/j d'acide acétylsalicylique.

Figure 1: Érythrodermie, chéilite et atteinte palmo-plantaire

Figure 2: Érythème et desquamation plantaire.

Figure 3: Conjonctivite bilatérale non purulente.

L'évolution était favorable avec une apyrexie à la 48heures, une régression progressive de l'érythrodermie.

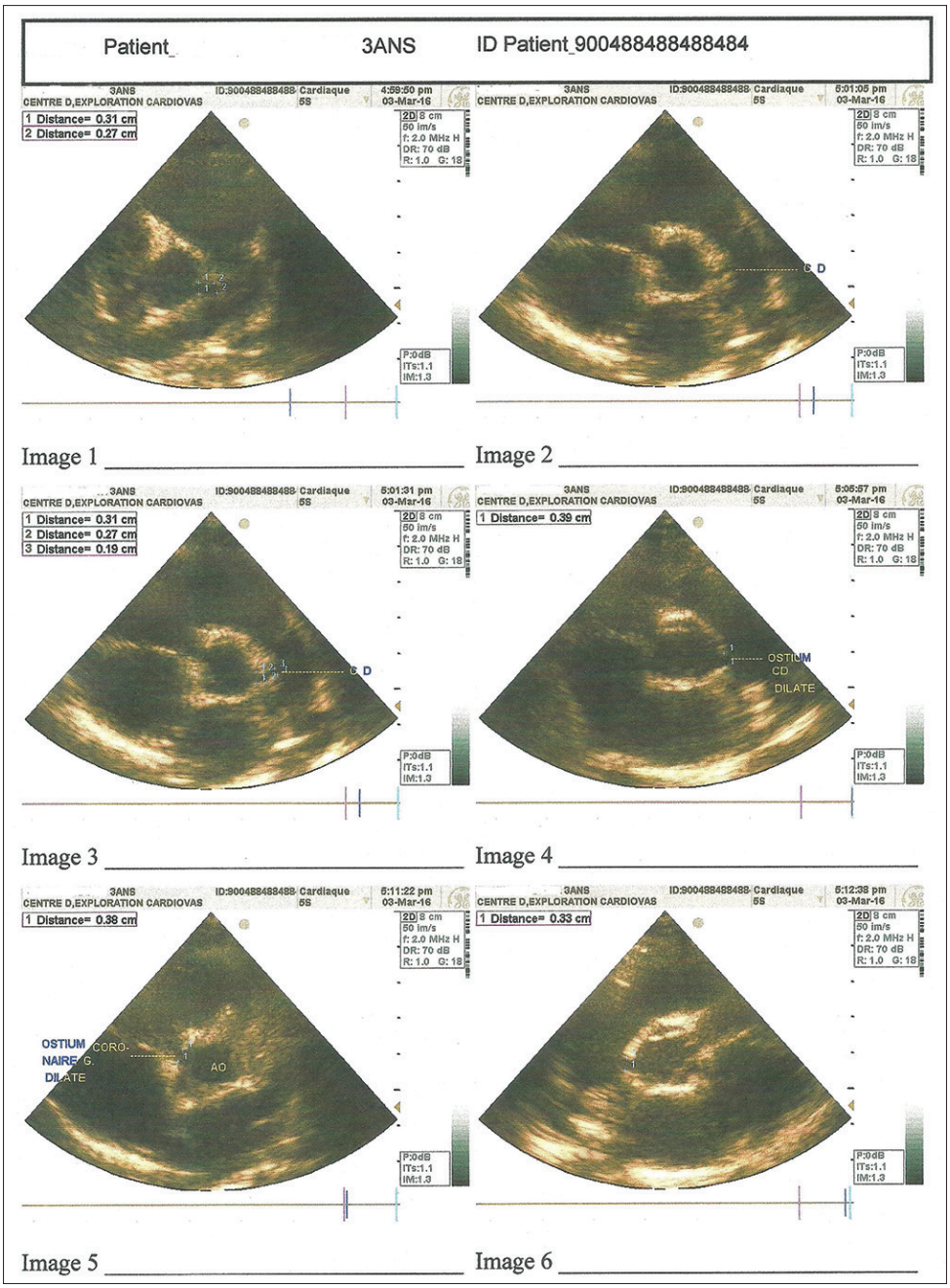

Figure 4: Dilatation des artères coronaires.

Le contrôle échographique fait un mois après a noté une régression de la dilatation des artères coronaires droit (ostium coronaire droit = 3 mm tronc =2,4mm) et gauche (ostium coronaire gauche =3mm tronc = 2,6mm).

DISCUSSION

Le diagnostic de maladie de Kawasaki avait été retenu devant la présence chez un enfant de 3 ans: i) d'une fièvre à 39,5°C persistante et ne répondant pas aux antipyrétiques et antibiotiques usuels; ii) d'une conjonctivale bilatérale non purulente; iii) de lésions buccales à type de chéilite avec des lèvres rouge sèche fissuraire et une langue dépapillée; iv) d'un érythème et œdèmes aux dos des pieds et des mains évoluant vers une desquamation en doigts de gants; v) d'un exanthème scarlatiniforme et vi) d'adénopathies cervicales aigues non suppuratives, La maladie de Kawasaki est une vascularite fébrile aigue systémique dont la physiopathologie encore mal connue est probablement liée à la production importante de

cytokines pro inflammatoires probablement en réponse à un agent infectieux, chez des patients génétiquement prédisposés [1]. En effet, le risque de survenue de la maladie chez les jumeaux est de 13% et les cas rapportés de maladie de Kawasaki chez les enfants de parents ayant eu la maladie dans l'enfance supportent également le rôle des facteurs génétiques [1]. Dans notre observation, la deuxième jumelle était indemne et il n'y avait pas d'histoire de maladie de Kawasaki chez les parents.

Elle survient dans 80 à 90% des cas chez les enfants de moins de 5 ans [3], ce qui est concordant avec l'âge de notre patiente. Une série congolaise de 11 cas de maladie de Kawasaki rapporte une moyenne d'âge de 16,5 ± 5,9 mois [10].

La maladie de Kawasaki est caractérisée par un polymorphisme clinique et une absence de signes para cliniques spécifiques d'où des difficultés diagnostiques et une élaboration de critères diagnostiques qui sont au nombre de six [2,11]. Le diagnostic est probable si cinq de ces six critères sont présents.

Comme dans notre observation, neuf des 11 patients de la série congolaise avaient une forme complète avec la présence des six critères diagnostiques [10]. Aucune biologie n'est spécifique de la maladie de Kawasaki. Cependant, une hyperleucocytose à polynucléaires neutrophile, une anémie normocytaire, une thrombocytose à la deuxième semaine, une élévation de la vitesse de sédimentation et de la C-réactive protéine sont souvent rapportés [11]. L'élévation de la C-réactive protéine et la thrombocytose étaient rapporté respectivement dans 41% de cas et 100% de cas chez les patients ayant une maladie de Kawasaki dans une étude cas-témoins en Inde [12]. Chez notre patiente, ces anomalies biologiques étaient présentes notamment un syndrome inflammatoire biologique, une hyperleucocytose à polynucléaires neutrophiles et une thrombocytose.

L'atteinte cardiaque fait toute la gravité de la maladie de Kawasaki. Elle était retrouvée chez 48,2% des patients en Inde [12]. Au Congo, l'échographie cardiaque avait été réalisé chez un seul patient, 34 jour après le début de la maladie, et était normale [7]. Chez notre patiente, l'échographie cardiaque notait une dilatation des artères coronaires témoignant d'un diagnostic assez tardif. La rareté et la méconnaissance de la maladie expliquent les errances diagnostiques qui ont contribué au retard diagnostique. Les complications cardiaques de la maladie de Kawasaki à type de dilatation des artères coronaires ou d'anévrisme coronarienne surviennent chez 15% à 25% des patients non traités [11]. Ces complications constituent la principale cause de la morbi-mortalité de la maladie à long terme [1]. La survenue d'un anévrysme est favorisée par un âge supérieur à 8 ans, un taux de plaquettes inférieur à 350000/mm3 et surtout l'administration tardive des immunoglobulines, après 10 jours de fièvre [4].

Les immunoglobulines intraveineuses restent le traitement de choix de cette affection et permet de diminuer le risque de survenue des anévrysmes [1]. Cependant, le coût élevé de ce traitement et sa non disponibilité dans les pays en développement limitent sont utilisation. Dans les séries de cas rapportés en Afrique, seul l'acide acétylsalicylique a été utilisé [7,10].

L'utilisation de l'acide acétylsalicylique est surtout nécessaire pour diminuer les risques de thrombose coronarienne pendant la phase aiguë, et doit être continuée à dose faible à distance de la phase aigue de la maladie.

Chez notre patiente, nous avons associé un traitement à base d'immunoglobulines et d'acide acétylsalicylique. La non disponibilité au Togo des immunoglobulines et leur coût très élevé ont contribué à retarder la prise en charge de notre patiente. En effet les immunoglobulines ont été commandées en France.

Malgré le retard dans la prise en charge, l'évolution à été favorable chez notre patiente avec une régression progressive de la dilatation des artères coronaires au contrôle échographique. L'administration même tardive d'immunoglobulines semble bénéfique, comme le suggère une étude multicentrique française dans laquelle les complications cardiovasculaires sévères sont en réalité rares et l'évolution des atteintes cardiaques est le plus souvent favorable [9].

CONCLUSION

La maladie de Kawasaki est une affection cosmopolite. Cependant sa rareté en Afrique subsaharienne peu s'expliquer par un sous diagnostic des cas. Il faut y penser devant une fièvre persistante ne répondant pas aux traitements habituels, des lésions cutanées distales associées à une atteinte muqueuse, et rechercher les autres critères cliniques. Le traitement repose sur les immunoglobulines associées à l'acide acétylsalicylique et doit être institué tôt afin de limiter les complications cardiaques.

REFERENCES

1. Newburger JW, Takahashi M, Gerber MA, Gewitz MH, Tani LY, Burns JC, et al. Diagnosis, treatment, and long-term management of Kawasaki disease: a statement for health professionals from the Committee on Rheumatic Fever, Endocarditis and Kawasaki Disease, Council on Cardiovascular Disease in the Young, American Heart Association. Circulation. 2004;110:2747-71.
2. Cimaz R, Lega JC. La maladie de Kawasaki. Rev Prat. 2007;57:1985-8.
3. Kawasaki T. Acute febrile mucocutaneous syndrome with lymphoid involvement with specific desquamation of the fingers and toes in children. Arerugi. 1967;16:78.
4. Rakotovao DN, Miandrisoa RM, Ramanitrarivo VL, Rakotonirina G, Rakotomamonjy SP, Imbert P. Kawasaki disease: a case report from Madagascar. Med Trop. 2008;68:637-9.
5. Yunjia Tang, Xiang Gao, Jie Shen, Ling Sun,Wenhua Yan. Epidemiological and Clinical Characteristics of Kawasaki Disease and Factors Associated with Coronary Artery Abnormalities in East China: Nine Years Experience. J Trop Ped. 2016;62:6-93.
6. Condat JM, Chauvet J, Mourrieras P. Syndrome de Kawasaki chez un nourrisson ivoirien: premier cas africain. Nouv Presse Med. 1981;10:25.
7. Mouko A, Nkoua JL, Louaka-Samba C, Ball Mamadou, Senga P. Le syndrome de Kawasaki: à propos de deux cas observés à Brazzaville. Bull Soc Pathol Exot. 2001;2:109-111.
8. Barabe P, Mbaye E, Peghini M, Brullard B, Gueye PM. Premier cas sénégalais de maladie de Kawasaki. Presse Med. 1987;16:1977-8.
9. Mahdhaoui A, Tabarki B, Bouraoui H, Majdoub MA, Mahdhaoui N, Jeridi G et al. Manifestations cardiovasculaires du syndrome de Kawasaki: Apport de l'échocardiographie dans le diagnostic et l'évolution. Tunis Med. 2003;81:879-84.
10. Mabiala Babela JR, Ollandzobo Ikobo LC, Nika RE, Moyen G. Study of 11 new cases of Kawasaki disease Congolese. Bull Soc Pathol Exot. 2015;108:250-4.
11. Singh S, Kawasaki T. Kawasaki Disease: An Indian Perspective. Indian Ped. 2009;46:563-7.
12. Suresh N, Varadarajan V V, Ranjith MS. Kawasaki disease in south India: a prospective, case–control study. Ann of Trop Ped. 2007;27:277-83.

Copyright by Koussake Kombaté, et al. This is an open access article distributed under the terms of the Creative Commons Attribution License, which permits unrestricted use, distribution, and reproduction in any medium, provided the original author and source are credited.
Source of Support: Nil, **Conflict of Interest:** None declared.

Our Dermatology Online

Review Article

A brief update on trichotillomania

Julio Torales[1], Beatriz Di Martino Ortiz[2]

[1]Psychodermatology Unit, School of Medical Sciences, National University of Asunción, San Lorenzo, Paraguay, [2]Department of Dermatology, Clinicas Hospital, Faculty of Medical Sciences, National University of Asuncion, San Lorenzo, Paraguay

Corresponding author: Prof. Julio Torales, E-mail: jtorales@med.una.py

ABSTRACT

Trichotillomania is a chronic disorder characterized by the fact of tearing the hair by oneself, resulting in considerable loss of it. This disorder appears to be a relatively common in pediatric population. Its ocurrence is associated with significant morbidity, comorbidity and functional impairment in adults, surprisingly few studies investigating the psychopathology of trichotillomania actually they included teenagers or children. Recent reviews have shown the efficacy of cognitive-behavioral pediatric trichotillomania, therapy but have also noted problems with relapse; these same reviews have mentioned the general lack of benefit associated with treatment only with selective inhibitors of serotonin reuptake. Recent developments in pharmacotherapy has been suggested that other medicines (atypical antipsychotics, opioid blockers and modulators glutamate) are promising as treatments for trichotillomania, both children and adults. This article has the overall objective to conduct a general review of the prevailing trends in pediatric trichotillomania, emphasizing the evaluation of pathology and the most current treatment recommendations.

Key words: Trichotillomania; Children and adolescents; Cognitive behavioral therapy; Pharmacotherapy

How to cite this article: Torales J, Di Martino Ortiz B. A brief update on trichotillomania. Our Dermatol Online. 2016;7(4):465-471.
Submission: 10.05.2016; **Acceptance:** 23.07.2016
DOI: 10.7241/ourd.20164.127

Review Article

Una pequeña puesta al día sobre la tricotilomanía

Julio Torales[1], Beatriz Di Martino Ortiz[2]

[1]Psychodermatology Unit, School of Medical Sciences National University of Asunción, San Lorenzo, Paraguay, [2]Department of Dermatology, Clinicas Hospital, Faculty of Medical Sciences, National University of Asuncion, San Lorenzo, Paraguay

Corresponding author: Prof. Julio Torales, E-mail: jtorales@med.una.py

RESUMEN

La tricotilomanía es un trastorno crónico, que se caracteriza por el hecho de arrancar el propio cabello, lo que resulta en la pérdida notable del mismo. Si bien la parece ser un trastorno pediátrico de aparición relativamente común asociado con una morbilidad significativa, comorbilidad y deterioro funcional en adultos, sorprendentemente pocos estudios de investigación de la psicopatología de la tricotilomanía han incluido en realidad a adolescentes o niños. Revisiones recientes han puesto de manifiesto la eficacia de la terapia cognitivo-conductual para la tricotilomanía pediátrica, pero también han señalado problemas con la recaída; estas mismas revisiones han mencionado la falta general de beneficio asociado con el tratamiento solo con inhibidores selectivos de la recaptación de serotonina. La evolución reciente de la farmacoterapia ha sugerido que otros medicamentos (antipsicóticos atípicos, bloqueadores opiáceos y moduladores del glutamato) son prometedores como tratamientos para el tricotilomanía, tanto en niños como adultos. El presente artículo tiene el objetivo general de realizar una revisión general de las tendencias reinantes en tricotilomanía pediátrica, haciendo hincapié en la valoración de la patología y las recomendaciones más actuales de tratamiento.

Palabras clave: Tricotilomanía; Niños y adolescentes; Terapia cognitivo-conductual; Farmacoterapia

INTRODUCCIÓN

Then Rapunzel let down the braids of her hair, and the enchantress climbed up to her. 'If that is the ladder by which one mounts, I too will try my fortune,' said he, and the next day when it began to grow dark, he went to the tower and cried: 'Rapunzel, Rapunzel, Let down your hair to me.' Immediately the hair fell down and the king's son climbed up. The Grimm Brothers, 1812.

Durante el transcurso de la historia de la humanidad el pelo ha tenido diversos significados, por lo que ha sido objeto de tradiciones y creencias. Tiene un papel fundamental para definir la individualidad y apariencia de cada persona. El término tricotilomanía (tricotilomanía) define las características del padecimiento y corresponde a una palabra compuesta por: trico (pelo), tilo (jalar) y manía (afecto anormal por un objeto, lugar o acción específica) [1].

La tricotilomanía es un trastorno del control de impulsos, crónico, que se caracteriza por el hecho de arrancar el propio cabello, lo que resulta en la pérdida notable del mismo [2,3].

Si bien la tricotilomanía parece ser un trastorno pediátrico de aparición relativamente común asociado con una morbilidad significativa, comorbilidad y deterioro funcional en adultos [4], sorprendentemente pocos estudios de investigación de la psicopatología de la tricotilomanía han incluido en realidad a adolescentes o niños y, además, hasta el momento, no se han publicado ensayos controlados aleatorios de las intervenciones psicofarmacológicas para jóvenes con tricotilomanía.

En ese sentido, el presente artículo tiene el objetivo general de realizar una revisión general de las tendencias reinantes en tricotilomanía pediátrica, haciendo hincapié en la valoración de la patología y las recomendaciones más actuales de tratamiento.

How to cite this article: Torales J, Di Martino Ortiz B. Una pequeña puesta al día sobre la tricotilomanía. Our Dermatol Online. 2016;7(4):465-471.
Submission: 10.05.2016; **Acceptance:** 23.07.2016
DOI: 10.7241/ourd.20164.127

TRICOTILOMANÍA: CARACTERÍSTICAS EPIDEMIOLÓGICAS Y CLÍNICAS

Epidemiología

Aunque estudios epidemiológicos completos y de gran escala aún no se han llevado a cabo, se estima, por estudios más pequeños, que la tricotilomanía afecta a 1-3.5% de adolescentes y adultos jóvenes; no obstante, su prevalencia entre los niños más pequeños siguen siendo desconocidas [5].

El inicio de tricotilomanía en la infancia o en la adolescencia (inicio entre los 5 y 13 años de edad) parece ser la norma; en la infancia la relación hombre-mujer es igual, mientras que en la adolescencia y la edad adulta las mujeres la padecen más [6].

Clínica

El autoarrancamiento del pelo ocasiona placas pseudoalopécicas de diversos tamaños, con distintos grados de extensión, de forma geométrica (lineales o circulares), con diferentes tamaños de pelo, pelos nuevos y otros cortos y rotos (Fig. 1). El daño ocasionado al jalar el pelo llega a la raíz haciéndola distrófica, generalmente con ausencia de inflamación o anormalidades en la piel cabelluda, en algunas ocasiones puede existir eritema perifolicular, hemorragia o excoriaciones. Algunos pacientes tienen el signo del "fraile Tuck", ya que asemejan las características adoptadas por ciertos monjes cristianos y se distingue por áreas con pérdida de pelo, pelos rotos o de varias longitudes en un patrón circular, rodeados por pelos normales [1].

FiWgura 1: Clínica. Niño de 1 año y 4 meses. Desde hace 4 meses el niño empieza a arrancarse cabellos. El evento coincide con el inicio de la actividad laboral de la madre.

Los niños tienden a jalarse el pelo en diversos sitios siendo más frecuente la cabeza, sobre todo en regiones parietotemporales, habitualmente en forma simétrica. En adultos, además de estas áreas descritas, y en orden de frecuencia, se produce autoarrancamiento en pestañas, cejas, región púbica, brazos, cara, bigote, piernas, pecho y abdomen.

El autoarrancamiento puede realizarse con la mano dominante, no dominante o con ambas, pero pueden valerse de otros instrumentos, como: Tijeras, cepillos, rastrillos; muchos pacientes no quedan conformes con arrancar el pelo y llegan incluso a examinar, jugar o manipular el pelo arrancado con manos o la boca, llegando a masticarlo e ingerirlo (tricofagia), y como resultado llegan a padecer tricobezoar (bola de pelos) en el lumen del conducto digestivo, lo que origina complicaciones gastrointestinales graves como: Obstrucción intestinal, intususcepción, ulceración o perforación [7].

FUNCIONALIDAD EN LA TRICOTILOMANÍA

El efecto que produce la tricotilomanía en la funcionalidad ha sido un tema de mayor estudio en la última década, y lo que se ha hecho evidente a partir de estas investigaciones es que la tricotilomanía está lejos de ser trivial en términos de su impacto. Adolescentes y adultos afectos de tricotilomanía informan de deterioro importante en las áreas escolar, laboral y en el funcionamiento social, disminución de las aspiraciones profesionales y gran ausentismo, tanto escolar como laboral [8].

La población adolescente también informa buscar considerables recursos en los métodos de ocultamiento de la afección y, ya de adultos, solicitar diversos tratamientos con diferentes grados de éxito [9].

Como la tricotilomanía generalmente se produce durante los años sensibles del desarrollo, la misma puede ser particularmente discapacitante; de hecho, se ha probado que la tricotilomanía puede menoscabar los ámbitos social y académico de los niños mayores y adolescentes. Muchos adolescentes con tricotilomanía expresan gran temor de que sus compañeros de clase y amigos descubran sus partes calvas y los evalúen negativamente como consecuencia de ello. Esto se puede también traducir en un impacto negativo en el funcionamiento familiar, contribuyendo a las discusiones familiares y al secreto, que a su vez

pueden aumentar el estrés y empeorar los síntomas de tricotilomanía [10].

No está claro si estas dificultades de la familia son causales o en gran medida consecuencia del desarrollo de la tricotilomanía; aún faltan de investigaciones longitudinales para hacer frente a esta importante cuestión.

FACTORES DE DESARROLLO, PSICOPATOLOGÍA Y TRATAMIENTO DE LA TRICOTILOMANÍA

Una de las principales prioridades de la investigación de la psicopatología y el tratamiento de la tricotilomanía es reclutar muestras de población de edades más pequeñas, con el objetivo de mejorar la comprensión de la patología más cerca de su momento de aparición y, por extensión, del tratamiento de la misma tricotilomanía en las primeras edades.

El tratamiento temprano de la tricotilomanía reducirá quizá el futuro deterioro funcional y prevendrá el desarrollo de trastornos comórbidos debilitantes. Los pocos estudios que han examinado la tricotilomanía y su tratamiento en muestras más jóvenes han documentado la presencia de tricotilomanía desde en niños hasta adolescentes y han sugerido que esta población presenta respuesta positiva a las intervenciones conductuales [11]. Sin embargo, a pesar del hecho de que la tricotilomanía parece ser un trastorno pediátrico de aparición relativamente común asociado con una morbilidad significativa, comorbilidad y deterioro funcional en adultos [4], sorprendentemente pocos estudios de investigación de la psicopatología de la tricotilomanía han incluido en realidad a adolescentes o niños. Hasta el momento, no se han publicado ensayos controlados aleatorios de las intervenciones psicofarmacológicas para jóvenes con tricotilomanía. Los resultados iniciales de la terapia cognitivo-conductual han sido alentadores [2], pero las cuestiones fundamentales relacionadas con el papel de los factores de desarrollo en la psicopatología y la respuesta al tratamiento de la tricotilomanía aún no se han abordado.

Hasta hoy se sabe muy poco acerca de la presentación de síntomas en niños pequeños, pero parece que el cuero cabelludo es el sitio donde se arrancan más comúnmente los adultos y los niños mayores y adolescentes. El arrancado puede ser tanto automático (es decir, fuera de la conciencia) y centrado (es decir, en respuesta a desencadenantes identificables afectivos) dentro de cada individuo, en lugar de exclusivamente una forma u otra [12], aunque parece que podría haber una mayor preponderancia de arrancado automático en muestras más jóvenes.

El concepto de impulso premonitorio, que se ha debatido ampliamente en el contexto de los trastornos por tics crónicos [2], también parece ser importante, ya que la mayoría de los participantes en los estudios de tricotilomanía hasta la fecha han informado de al menos algo de tensión o alguna otra sensación desagradable precede, aunque no precipite, al arrancado [13]. Es posible que los niños pequeños no hayan desarrollado las habilidades de expresividad emocional y la conciencia necesaria para poder identificar y reportar este tipo de fenómenos, lo que pudiera requerir un énfasis en el tratamiento conductual para la identificación de los momentos de alto riesgo para estirar el cabello, en lugar de depender de la capacidad del paciente para reconocer e informar de que el impulso de tirar va en aumento.

OPCIONES ACTUALES DE TRATAMIENTO

Un estudio completo de toda la literatura existente sobre el tratamiento va más allá del alcance del presente artículo, pero las revisiones recientes han puesto de manifiesto varios puntos clave:

1. La terapia cognitivo-conductual es muy beneficiosa;
2. Los inhibidores selectivos de la recaptación de serotonina generalmente no parecen ser eficaces en la reducción de los síntomas de la conducta de arrancamiento per se;
3. Varios compuestos que parecen afectar a otros sistemas de neurotransmisores constituyen alguna promesa para el tratamiento de la tricotilomanía;
4. Los tratamientos combinados de terapia cognitivo-conductual más medicación pueden eventualmente resultar útiles; y,
5. La ausencia de pruebas de ensayos controlados aleatorizados en muestras pediátricas obstaculiza el desarrollo de tratamientos y planes terapéuticos para esta población tan vulnerable.

Las intervenciones conductuales para la tricotilomanía por lo general han incluido tres elementos fundamentales [2]: En primer lugar, la formación de la conciencia, en el que las técnicas (por ejemplo, el auto-control) se implementan para mejorar el conocimiento

del paciente acerca de su conducta de arrancamiento y, mejor aún, la conciencia de la sensación de urgencia que precede a la conducta; en segundo lugar, el control de estímulos, que incluye una variedad de métodos que sirven como "reductores de velocidad" para reducir la probabilidad de que los arranques se inicien; y tercero, la capacitación en competencia de respuesta, donde a los pacientes se les enseña que a la primera señal de tirar el pelo, o de la urgencia de tirar, realicen una conducta que es físicamente incompatible con el arranque por un breve período de tiempo hasta que la urgencia desaparezca.

Opiniones de expertos coinciden con la literatura al señalar que la terapia cognitivo-conductual que incluya entrenamiento en revisión del hábito es la opción de primera línea en la tricotilomanía pediátrica [14]. También es generalmente aceptado, hoy por hoy, que los ISRS, aunque potencialmente útiles para tratar los síntomas comórbidos de ansiedad y depresión, no se consideran tratamientos de primera línea para las conductas de arranque per se. Un estudio reciente apoyó la eficacia de la combinación entre un ISRS con terapia conductual, con resultados positivos por encima de la terapia conductual o la medicación solas; no obstante, se necesita la replicación de estos hallazgos, a través de otros estudios, para poder validarlos.

La terapia cognitivo-conductual, aunque eficaz, no está exenta de limitaciones, la más importante de las cuales es la observación de que la recaída después del tratamiento es común.

Actualmente, existe la esperanza de que las herramientas de investigación desarrolladas para examinar más específicamente estilos de arranquen (automático o centrado), ayudarán a los investigadores clínicos en la generación de intervenciones conductuales más específicas que se pueden adaptar a los perfiles de arranque individuales.

La evolución reciente de la investigación psicofarmacológica informa fármacos que modulan los sistemas de neurotransmisores distintos a la serotonina podrían llegar a ser útiles para reducir el comportamiento y la urgencia de las conductas de arrancamiento. Como se mencionó previamente, los ISRS ofrecen muy poco beneficio clínico en los pacientes con tricotilomanía, más allá de lo que puede esperarse de una píldora de placebo [2]. La clomipramina, un antidepresivo tricíclico con propiedades serotoninérgicas y otras, parece ser más eficaz que el placebo, pero su desfavorable perfil de efectos secundarios hace que sea un tratamiento de segunda línea. En su lugar, han surgido nuevos datos para apoyar, al menos preliminarmente, la eficacia de un antagonista opioide (naltrexona), un modulador del glutamato (N-acetilcisteína [NAC]) y un antipsicótico atípico (olanzapina) para el tratamiento de la tricotilomanía.

La Tabla 1 informa las evidencias para los fármacos citados arriba.

RECOMENDACIONES TERAPÉUTICAS

Como se indicó más arriba, los niños y adolescentes con tricotilomanía deben recibir terapia cognitivo-conductual, que incluya específicamente entrenamiento en la reversión del hábito [19-21]. Desafortunadamente, la falta de ensayos controlados aleatorizados en poblaciones más jóvenes, hace que quiénes tratamos a niños y adolescentes con tricotilomanía carezcamos aún de pruebas suficientes para guiar la toma de decisiones terapéuticas y clínicas. Además de la terapia de reversión del hábito, en la Unidad de Psicodermatología de la Facultad de Ciencias Médicas de la Universidad

Tabla 1: Nuevos fármacos para el tratamiento de la tricotilomanía

Naltrexona	Muchos investigadores han hecho hincapié en la superposición neurobiológica y fenomenológica subyacente entre la tricotilomanía y las conductas adictivas. En consecuencia, los medicamentos que bloquean la unión de opiáceos pueden también ser útiles en la disminución del refuerzo positivo derivado de las conductas de arrancamiento, disminuyendo, por lo tanto, la fuerza y el impulso que afecta el comportamiento [15]. Un primer ensayo abierto en 14 niños con tricotilomanía encontró que la naltrexona reduce el arranque de pelo, no asociándose su uso con ningún efecto secundario significativo [16]. No obstante, aún se necesitan más estudios sobre la eficacia y seguridad de esta droga en la población pediátrica
N-acetilcisteína	El NAC, modulador del glutamato, ha resultado ser superior al placebo en ensayos controlados aleatorizados en adultos con tricotilomanía. Las tasas de respuesta de tratamiento fueron superiores en el grupo tratado con NAC que en el grupo control, y además, estas tasas fueron comparables a las observadas con terapia cognitivo-conductual. Además, su escaso perfil de efectos secundarios, hace de esta droga muy prometedora para el futuro cercano del tratamiento de la tricotilomanía [17]
Olanzapina	La similitud formal, si no funcional, entre los comportamientos repetitivos observados en los trastornos de tics y los vistos en la tricotilomanía es la que llevó a algunos investigadores a examinar la utilidad potencial de los antipsicóticos atípicos para el tratamiento de la tricotilomanía, ya sean solos o en combinación con los ISRS. En el primer estudio controlado aleatorio de esta intervención, se encontró que la monoterapia con olanzapina es superior al placebo en los adultos, aunque el perfil de efectos secundarios para esta clase de medicamentos, que incluye el aumento de peso significativo, disfunción metabólica y síntomas extra piramidales [18], hace que sean considerados como de segunda línea, cuando otros tratamientos no están disponibles

Nacional de Asunción, el plan terapéutico de la tricotilomanía pediátrica se centra en la psicoeducación y consejería de apoyo para niños y adolescentes con tricotilomanía.

En lo que respecta a la utilidad de la farmacoterapia en el tratamiento de la tricotilomanía, estudios controlados con NAC y otras medicaciones prometedoras, solas o en combinación con la terapia cognitivo-conductual, son todavía necesarios a lo largo de todo el espectro de desarrollo de la población pediátrica.

Nuestra opinión como integrantes de la Unidad de Psicodermatología de la Facultad de Ciencias Médicas de la Universidad Nacional de Asunción, sobre las opciones de tratamiento para la tricotilomanía incluye la llamada de atención de que si bien la terapia cognitivo-conductual es el tratamiento de primera línea para la tricotilomanía, ésta es a veces de difícil acceso a los pacientes, en el caso de la República del Paraguay. Muchos psiquiatras no practican la terapia cognitivo-conductual, ni incorporan el entrenamiento en la reversión del hábito en su ejecución. Los esfuerzos para difundir esta técnica deben ser aumentados, a fin de permitir que este tratamiento sea ejecutado con más frecuencia en la comunidad.

Si bien los últimos 5 años han sido muy productivos en lo que respecta a la investigación sobre la tricotilomanía, y el trabajo que se ha llevado a cabo recientemente sienta las bases para la próxima generación de investigadores para seguir avanzando en nuestro conocimiento sobre la psicopatología de la tricotilomanía, su neurobiología subyacente, su capacidad de respuesta al tratamiento existente, el desarrollo de tratamientos empíricamente informados, y la difusión de los métodos más eficaces en entornos comunitarios, en la actualidad los avances logrados en no han impactado la práctica clínica más allá del ámbito académico.

Todavía se necesitan más ensayos controlados aleatorizados para replicar los resultados recientes con la terapia cognitivo-conductual en niños y adolescentes, para el tratamiento combinado en los adultos, y para la utilización de NAC, antipsicóticos atípicos y antagonistas opiáceos en todo el espectro del desarrollo.

Particularmente, la NAC puede llegar a ser la más influyente de las nuevas medicaciones, teniendo en cuenta las conclusiones iniciales sobre su eficacia y seguridad, aunque todavía se necesitan estudios de su eficacia y seguridad a largo plazo en muestras más jóvenes.

CONCLUSIONES

En los próximos años, será fundamental para los investigadores orientados clínicamente a la tricotilomanía, satisfacer la creciente demanda de información y formación mediante el desarrollo de modelos optimizados de terapéutica; estos esfuerzos pueden ser la mejor manera de hacer frente a la gran escasez de terapeutas expertos en tricotilomanía, lo que es lamentablemente evidente en muchos países de América Latina, Estados Unidos, y en nuestro caso, Paraguay.

A modo de conclusiones, podemos afirmar que:

- Revisiones recientes han puesto de manifiesto la eficacia de la terapia cognitivo-conductual para la tricotilomanía, pero también han señalado problemas con la recaída; estas mismas revisiones han mencionado la falta general de beneficio asociado con el tratamiento solo con ISRS.
- La evolución reciente de la farmacoterapia ha sugerido que otros medicamentos (antipsicóticos atípicos, bloqueadores opiáceos y moduladores del glutamato) son prometedores como tratamientos para el tricotilomanía.
- Se necesita más investigación para desarrollar una mejor comprensión de la fenomenología tricotilomanía en todo el espectro del desarrollo, los mecanismos psicológicos y biológicos que subyacen a la enfermedad, y la mejor manera de hacer uso de los tratamientos ya desarrollados que han mostrado eficacia para la tricotilomanía.
- Demostrar la eficacia del tratamiento ahora debe ir seguida de la divulgación de esta información a los proveedores de salud mental con el fin de hacer frente a la escasez de terapeutas disponibles para proporcionar estos tratamientos para los niños, adolescentes y familias que los necesitan.

REFERENCIAS

1. Moreno Vázquez K, Ponce Olivera, RM, Cano AS, Narváez Rosales V, Sanabria Deseuza JA, Jurado Santa Cruz J, et al. Dermatol Rev Mex. 2007;51:280-6.
2. Franklin ME, Zagrabbe K, Benavides KL. Trichotillomania and its treatment: a review and recommendations. Expert Rev Neurother. 2011;11:1165-78.
3. American Psychiatric Association. Diagnostic and Statistical Manual of Mental Disorders. 5th ed. Arlington: American Psychiatric Association; 2013.
4. Woods DW, Flessner CA, Franklin ME, Keuthen NJ, Goodwin RD, Stein DJ, et al. Trichotillomania Scientific Advisory Board. The Trichotillomania Impact Project (TIP): exploring phenomenology, functional impairment, and treatment utilization. J Clin Psychiatry.

2006;67:1877-88.
5. Christenson GA, Pyle RL, Mitchell JE. Estimated lifetime prevalence of trichotillomania in college students. J Clin Psychiatry. 1991;52:415-17.
6. Woods DW, Flessner C, Franklin ME, Wetterneck CT, Walther MR, Anderson ER, et al. Understanding and treating trichotillomania: what we know and what we don't know. Psychiatr Clin North Am. 2006;29:487-501.
7. Hautmann G, Hercogova J, Lotti T. Trichotillomania. J Am Acad Dermatol. 2002;46;807-21.
8. Diefenbach GJ, Tolin DF, Crocetto J, Maltby N, Hannan S. Assessment of trichotillomania: a psychometric evaluation of hair-pulling scales. J Psychopathol Behav Assess. 2005;27:169-78.
9. Wetterneck CT, Woods DW, Norberg MM, Begotka AM. The social and economic impact of trichotillomania: results from two nonreferred samples. Behav Interven. 2006;21:97-109.
10. Moore PS, Franklin ME, Keuthen NJ. Family functioning in pediatric trichotillomania. Child Fam Behav Ther. 2009;31:255-69.
11. Wright HH, Franklin ME, Edson AL, Freeman JB. Behavior therapy for pediatric trichotillomania: exploring the effects of age on treatment outcome. Child Adolesc Psychiatry Ment Health. 2010;4:123-27.
12. Flessner CA, Conelea CA, Woods DW, Franklin ME, Keuthen NJ. Styles of pulling in trichotillomania: exploring differences in symptom severity, phenomenology, and functional impact. Behav Res Ther. 2008;46:345-57.
13. Franklin ME, Edson AL, Ledley DA, Cahill SP. Behavior therapy for pediatric trichotillomania: a randomized controlled trial. J Am Acad Child Adolesc Psychiatry. 2011;43:234-45.
14. Flessner, CA, Penzel F, Keuthen NJ. Trichotillomania Learning Center–Scientific Advisory Board: current treatment practices for children and adults with trichotillomania: Consensus among experts. Cogn Behav Pract. 2010;17:290-300.
15. Grant JE, Odlaug BL, Potenza MN. Addicted to hair pulling? How an alternate model of trichotillomania may improve treatment outcome. Harv Rev Psychiatry. 2007;15:80-5.
16. De Sousa A. An open-label pilot study of naltrexone in childhood-onset trichotillomania. J Child Adolesc Psychopharmacol. 2008;18:30-3.
17. Grant JE, Odlaug BL, Kim SW. N-acetylcysteine, a glutamate modulator, in the treatment of trichotillomania. Arch Gen Psychiatry. 2009;66:756-63.
18. Komossa K, Rummel-Kluge C, Hunger H, Schmid F, Schwarz S, Duggan L, et al. Olanzapine versus other atypical antipsychotics for schizophrenia. Cochrane Database Syst Rev. 2010;3:1-150.
19. Tolin DF, Franklin ME, Diefenbach GJ, Anderson E, Meunier SA. Pediatric trichotillomania: Descriptive psychopathology and an open trial of cognitive–behavioral therapy. Cogn Behav Ther. 2007;36:129-144.
20. Woods DW, Flessner C, Franklin ME, Wetterneck CT, Walther MR, Anderson ER, et al. Understanding and treating trichotillomania: What we know and what we don't know. Psychiatr Clin North Am. 2006;29:487-501.
21. Torales J, Arce A, Viola L. Guía esencial de tricotilomanía pediátrica. 1ª ed. Asunción. EFACIM, 2014.

Copyright by Julio Torales, et al. This is an open access article distributed under the terms of the Creative Commons Attribution License, which permits unrestricted use, distribution, and reproduction in any medium, provided the original author and source are credited.
Source of Support: Nil, **Conflict of Interest**: None declared.

Clinical Image

Cutaneous myasis in trophic leg ulcers

Patricia Chang[1], Gustavo Adolfo Oliva Vega[2], Edlin Mayté Lizama Auyón[2]

[1]Department of Dermatology, Hospital General de Enfermedades IGSS and Hospital Ángeles, Guatemala, [2]Hospital General de Enfermedades IGSS and Hospital Ángeles, Guatemala

Corresponding author: Dr. Patricia Chang., E-mail: pchang2622@gmail.com

An 80 year-old male patient is brought to the emergency department due to his nephew noticing a putrid smell coming from the patient´s leg ulcers. The patient´s family had abandoned him 9 months ago and thus lived alone. Local debridement was performed on the ulcers and a culture was taken. Due to poor health conditions, he was transferred to the general medicine ward. There he received treatment for his Type-II Diabetes and chronic kidney failure.

On physical examination, the patient was in poor health conditions with dermatosis located in both lower extremities but mainly on the right one. Both legs presented numerous, well-circumscribed ulcers with fibrinous tissue as well as a mobile whitish larvae moving in one of the ulcers (Fig. 1) and multiple whitish parasites (Fig. 2). Time since onset of the current clinical presentation was unknown.

Relevant comorbidities included: Type-II Diabetes with onset 15 years ago, as well as KDOQI V Chronic Kidney Failure and obstructive pulmonary disease. The following diagnoses were made: cutaneous myasis, sepsis, Type-II Diabetes and chronic renal failure.

On admission, laboratories and cultures were performed. Relevant values are as follow: Hemoglobin – 7.77 g/dL, Hematocrit – 23.93%, BUN – 65 mg/dL, Creatinine 1.31 mg/dL. *P. aeruginosa* was isolated in the culture. On a microscopic analysis, a larva with two oral hooks was seen (Fig. 3) and a histological analysiswas later performed on it (Fig. 4).

The following diagnoses were now made: cutaneous myasis, *P. aeruginosa*-induced sepsis, Type-II Diabetes and uncontrolled chronic kidney failure. The following medications are begun: Meropenem 500mg IV TID, Amikacin 500mg IV BID, hemodyalisis thrice per week and Erithropoietin 2000U SC thrice-in week. Regrettably, the patient died 8 days after admittance.

Myasis is described as an infestation of vertebrated animals and humans by larvae coming from dipters (flies) which feed on live and dead tissue cells of the host.Depending on the cause of the myasis, the flies

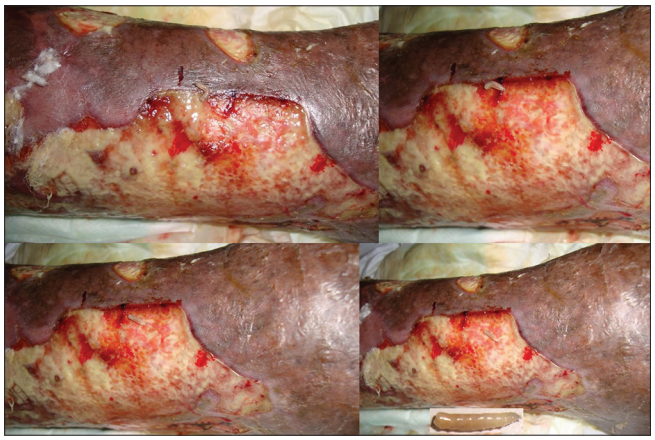

Figure 1: Larvae in movement within a trophic ulce.

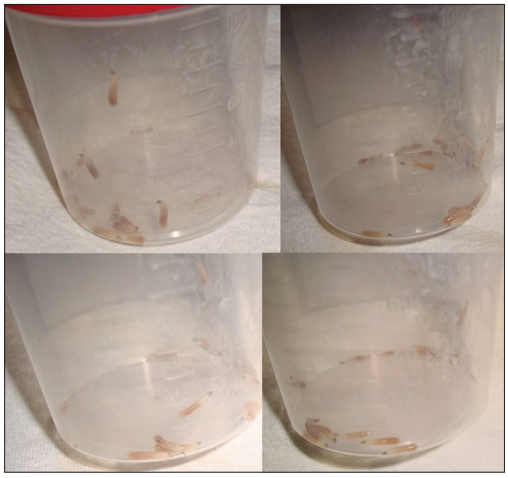

Figure 2: Multiple larvae extracted from the ulcer.

How to cite this article: Chang P, Oliva Vega GA, Lizama Auyón EM. Cutaneous myasis in trophic leg ulcers. Our Dermatol Online. 2016;7(4):472-474.
Submission: 20.01.2016; **Acceptance:** 29.03.2016
DOI: 10.7241/ourd.20164.128



Figure 3: On microscopic analysis, the presence of oral hooks.

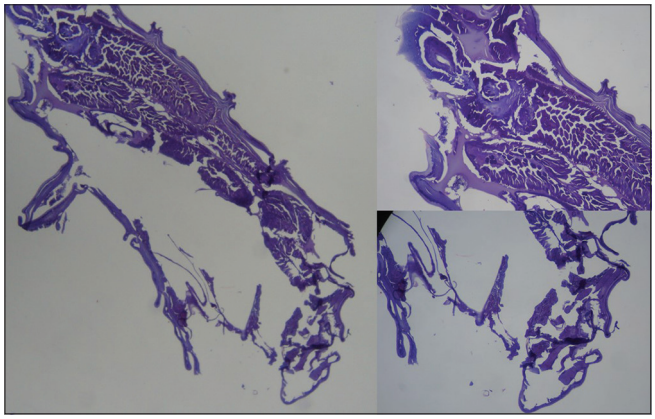

Figure 4: Histopathological aspect of the larva.

are categorized into three groups according to their parasitic relationship with the host in: obligatory parasites, facultative parasites and accidental parasites. The main responsible for furunculous myasis in México, Central America and South America is the *Dermatobia hominis* fly. From the moment of infection onwards, the larvae will remain in the hostfor 5-12 weeks; period in which it reaches sufficient maturity to leave the host during the night in order to become an adult fly after a month [1-3].

It is more common to become infected during summer. These infestations tend to occur in weakened people or in those who do not heal their wounds. It occurs in both sexes and in any age but it becomes more frequent in people with low socioeconomic status [2,3].

Clinically, myases can be divided according to the site in which they develop in: cavitary, cutaneous and intestinal myasis. Cutaneous myases can further be divided into furunculous or wound-related sub-types [2,3].The initial lesion is a small erythematous papule, which grows until it becomes a node with a diameter between 3-12 mm. These lesions are found in exposed body parts. Normally only one lesion is found, but in some cases there can be multiple lesions and the skin between them will usually be indurated by inflammatory tissue. These lesions may be asymptomatic, but in most caseswill cause itchiness followed by local pain and a sensation of "something moving below the skin". Serous exudate is frequent and the patient may present enlarged lymph nodes, fever and general malaise [3-5].

The diagnosis is clinical and based on the patient´s history, prior comorbidities, symptoms and injury characteristics. An important sign is the discovery of a lone furuncle with antibiotic resistance and the presence of a small pore within it, with serous exudate and sensation of a foreign body moving below the skin. The definitive diagnosis is made with direct visualization of the larvae via microscopy. A patient usually harbors between 1-8 larvae. Laboratory examination usually reveals leukocytosis and eosinophilia [4].

The treatment consists in the extirpation of the larvae via incision or direct pressure over the furuncle in order to expel the parasite. Afterwards it is necessary to close the respiration orifice of the larvae with solid Vaseline, oil or liquid wax. Local application of aniseed essence makes the parasite evacuate due to it being neurotoxic. 1%-Ivermectin in a propylene glycol solution, 5%-chloroform in olive oil or ether has also been used to paralyze the parasite. After the larva is removed, the node spontaneously resolves without leaving a scar [6].

Mortality for this disease is around 10% and often associated with CNS injuries. The use of screens and flytraps is recommended and care must be taken to cover any wound to prevent it from becoming an entry-point for the infection. The most important complications are overlying bacterial infection or tetanus [7,8].

REFERENCES

1. Cruz Reyes A, Camargo B. Parasitology and related sciences glossary. 1st ed. Mexico; 2001: v.1 p 151-2.
2. Alcalá D, Yánez S. Furunculous myasis caused by Dermatobia hominis. Rev Cent Dermatol Pascua (Mexico). 2006;15:23-5.
3. Chanccour C. Forunculous myasis: Forunculous myasis–case series of five patients belonging to the Pemon ethnic group and literature revision. Venezuelan Rev. Dermatology (Venezuela). 2005;43:8-15.
4. Calleja Pascual JM, Pérez Urrutia E, Calvo Gainzarain C, Lecuona Irigoyen A, Miskovic N, Iturralde iriso J. Forunculous myasis caused by Dermatobia hominis in a tropical country tourist. Gac Med Bilbao (Spain). 2008;105:100-4.
5. Contreras Ruíz J, Arenas Guzmán R, Vega Memije ME, Castillo Díaz M. Forunculous myasis caused by Dermatobia hominis. A mexican, costarican-imported case. Gac Méd Méx (Mexico). 2004;140:81-4.
6. Moya J, Spelta MG, Gavazza S, Barbarulo A, Fontana MI, Barerra M, Lafo jurjo L, et al. Cutaneous myasis: a literature revision and

presentation of a forunculous myasis case. Arch Argent Dermatol (Argentina). 2007;57:217-23.
7. Pastor C, Briceño G, Schafer F. Forunculous cutaneous myasis caused by Dermatobia hominis. Rev Med Chile (Chile). 2013;141:1081-2.
8. Allevato M. Myasis. Act Terap Dermatol (Buenos Aires). 2005;28:272-9.

Copyright by Patricia Chang, et al. This is an open access article distributed under the terms of the Creative Commons Attribution License, which permits unrestricted use, distribution, and reproduction in any medium, provided the original author and source are credited.
Source of Support: Nil, **Conflict of Interest:** None declared.

Historical Image

Hibernoma of cervical region

Chidambharam Choccalingam

Department of Pathology, Chettinad Medical College, Kelambakkam, Tamil Nadu, India

Corresponding author: Dr. Chidambharam Choccalingam, E-mail: chidambharam@gmail.com

A 42 year old male presented with swelling in the right posterior cervical region for a period of 2 months. Palpation revealed a soft, non tender, mobile swelling measuring 2 x 1 cms. An elective excision biopsy was performed. Gross examination showed a yellow to pale brown soft mass. On microscopy, a well circumscribed tumour composed of two populations of cells(uni-vacuolated white adipocytes and multi-vacuolated brown adipocytes) was seen (Fig. 1). Gradual transition between the two populations was seen (Fig. 2). The white adipocyte cells with clear cytoplasm and peripheral nucleus were seen in the periphery of tumour. The brown adipocyte cells with granular eosinophilic multi-vacuolated cytoplasm and central round vesicular nucleus were seen in the central areas of tumour (Fig. 3). No atypia or necrosis or mitosis was seen. With the morphological features a diagnosis of hibernoma- benign tumour of brown fat was made.

Hibernoma is a benign tumour of brown fat that is also known as fetal lipoma, lipoma of embryonic fat and usually is seen in interscapular, neck, axilla, mediastinal and retro-peritoneal regions of adults where vestiges of brown foetal fat persists beyond foetal life [1,2]. Brown adipocyte characterized by

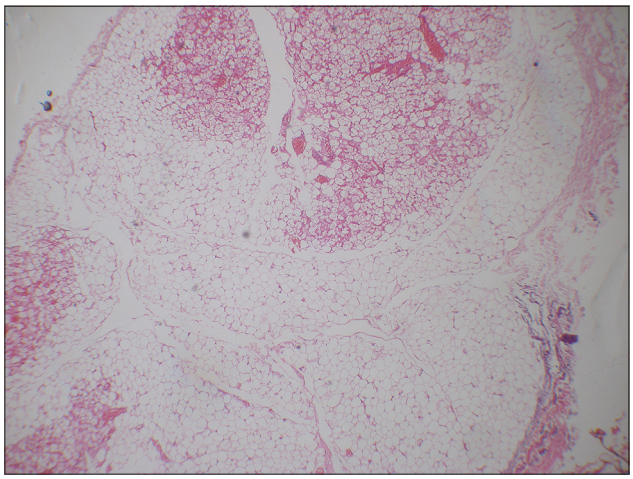

Figure 1: Lobulated tumour with two population of uni-vacuolated and multi-vacuolated adipocytes seen (H&E x 4).

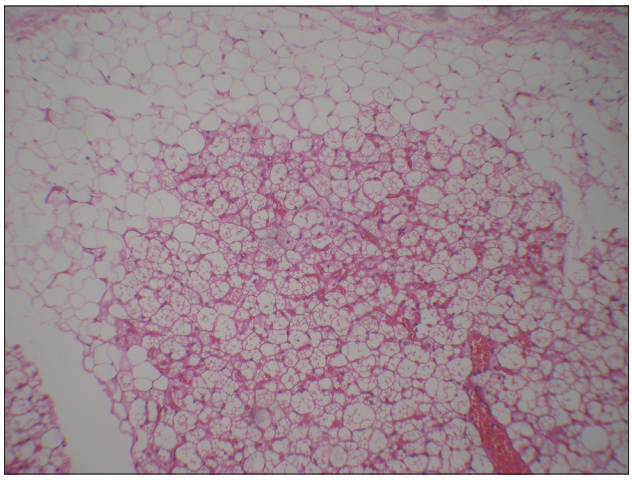

Figure 2: Smooth transition between uni-vacuolated and multi-vacuolated adipocytes seen (H&E x 10).

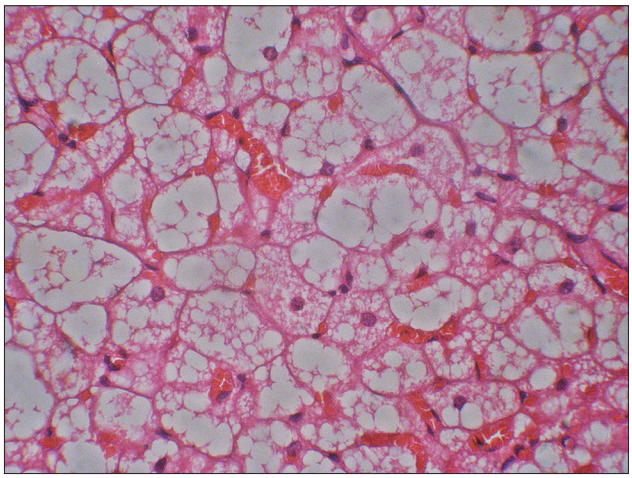

Figure 3: Brown adipocyte cells with granular eosinophilic multi-vacuolated cytoplasm and central round vesicular nucleus (H&E x 40).

How to cite this article: Choccalingam C. Hibernoma of cervical region. Our Dermatol Online. 2016;7(4):475-476.
Submission: 14.04.2016; **Acceptance:** 13.06.2016
DOI:10.7241/ourd.20164.129

small lipid droplets, high mitochondrial content is seen mostly in newborns and in hibernating mammals and is postulated to play a role in thermoregulation [3]. The high iron content within the mitochondria and the rich blood supply imparts the brown colour to the hibernoma [1,3]. Microscopically, presence of brown adipocyte cells is common to all the four variants namely typical(lobular pattern with uni-vacuolar and multi-vacuolar adipocytes), myxoid (prominent myxoid change), lipoma like (predominantly and spindle cell type. Surgical resection of tumour is curative with no recurrence or transition to malignancy [1].

REFERENCES

1. Weiss SW, Goldblum JR. Enzinger and Weiss's Soft tissue Tumours. 5 ed: Mosby, Inc; 2008.
2. Furlong M, Fanburg-Smith J, Miettinen M. The morphologic spectrum of hibernoma: a clinicopathologic study of 170 cases. Am J Surg Pathol. 2001;25:809-14.
3. Chen C-L, Chen W-C, Chiang J-H, Ho C-F. Interscapular hibernoma-Case report and literature review. Kaohsiung J Med Sci. 2011;27:348-52.

Copyright by Chidambharam Choccalingam. This is an open access article distributed under the terms of the Creative Commons Attribution License, which permits unrestricted use, distribution, and reproduction in any medium, provided the original author and source are credited.
Source of Support: Nil, **Conflict of Interest:** None declared.

Historical Image

Folliculosebaceous cystic hamartoma

Leila Bouhaja[1], Meriam Jones[2], Soumaya Rammeh[1]

[1]Department of Pathology, Charles Nicolle Hospital, Tunis, Tunisia, [2]Department of Dermatology, Charles Nicolle Hospital, Tunis, Tunisia

Corresponding author: Dr. Leila Bouhajja, E-mail: bouhaja.leila@gmail.com

Sir,

We report a 34 year-old man, with no past medical history, who presented with a 2-year history of a nodule on the nose. At physical examination the lesion was firm, pedunculated, and flesh-colored with a smooth surface. Clinically, the diagnosis of adnexal tumor was suggested and a surgical resection of the lesion was performed. Grossly, the tumor was firm pedunculated measuring 6 mm in size, raising the epidermis (Fig. 1). Histological examination showed a well-circumscribed lesion of the dermis composed of numerous sebaceous follicles structures. Some were dilated forming cysts and connected directly to the epidermis (Fig. 2). These epithelial structures were surrounded by a fibrohyalin stroma combined with a fibrous component containing adipocytes (Fig. 3). These features were reminiscent with the diagnosis of folliculosebaceous cystic hamartoma. At 10 months of follow-up, the patient was asymptomatic and had no recurrence.

The patient's informed consent was obtained.

Prior to the study, patient gave written consent to the examination and biopsy after having been informed about the procedure.

Folliculosebaceous cystic hamartoma (FSCH) is a rare cutaneous hamartoma composed of dilated folliculosebaceous units associated with mesenchymal elements [1]. This tumor may occur in all age groups, and females are affected more often than males [2]. Clinically, it manifests as a solitary skin-colored sessile or pedunculated nodule that is most commonly located on the face and scalp, with approximately 30% occurring in the nasal or paranasal regions. The lesion is usually less than 3 cm in size [3,4]. The main differential diagnoses are nevus lipomatosus superficialis or "sebaceous" trichofolliculoma which may include sebaceous glands but no central cyst [5]. FSCH can be readily identified by the presence of

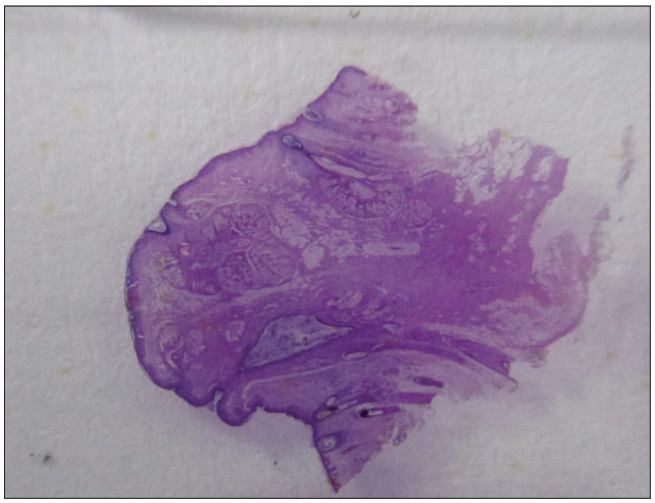

Figure 1: A slide-mounted pedunculated tumor raising the epidermis.

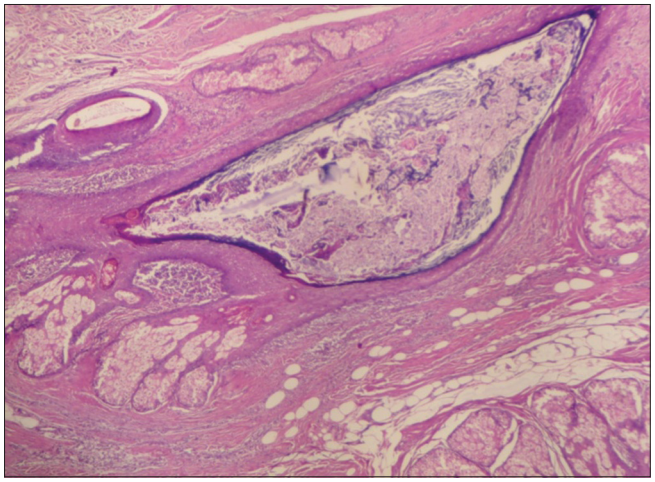

Figure 2: Dilated follicular cyst structure with infundibular keratinization surrounded by numerous sebaceous lobules in the dermis (HEx100).

How to cite this article: Bouhaja L, Jones M, Rammeh S. Folliculosebaceous cystic hamartoma. Our Dermatol Online. 2016;7(4):477-478.
Submission: 18.03.2016; **Acceptance:** 13.06.2016
DOI:10.7241/ourd.20164.130

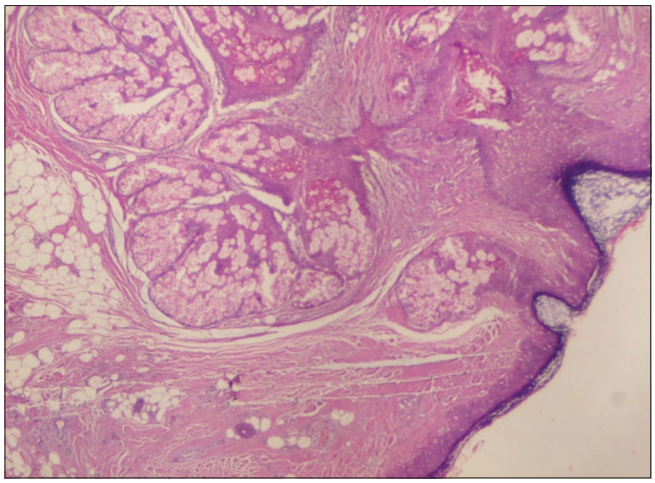

Figure 3: Stroma surrounding the folliculosebaceous structures consisting of collagen bundles interspersed with adipocytes (HEx40).

adipocytes and a fibrous stroma. The treatment consists of total excision of the tumor.

Consent

The examination of the patient was conducted according to the Declaration of Helsinki principles. Written informed consent was obtained from the patient for publication of this article.

REFERENCES

1. Osipov VO, Vincent P, Packer AM., Oliver GF. Folliculosebaceous cystic hamartoma of the ear and periauricular skin. Austral J Dermatol. 2012;53:e8-e9.
2. Ansai S, Kimura T, Kawana S. A clinicopathologic study of folliculosebaceous cystic hamartoma. Am J Dermatopathol. 2010;32:815-20.
3. Watanabe-Okada E, Kurihara Y, Miyakawa S, Tanaka M. Dermatoscopy of folliculosebaceous cystic hamartoma. Dermatol Pract Concept. 2014;4:47-9.
4. Nguyen CM, Skupsky H, Cassarino D. Folliculosebaceous Cystic Hamartoma With Spindle Cell Lipoma-Like Stromal Features. Am J Dermatopathol. 2015;37:e140-2
5. Merklen-Djafri C, Batard M.-L, Guillaume J-C, Kleinclauss I, Cribier B. Folliculosebaceous cystic hamartoma: Anatomo-clinical study. Ann Dermatol Venereol. 2012;139:23-30.

Copyright by Leila Bouhaja, et al. This is an open access article distributed under the terms of the Creative Commons Attribution License, which permits unrestricted use, distribution, and reproduction in any medium, provided the original author and source are credited.
Source of Support: Nil, **Conflict of Interest:** None declared.

Letter to the Editor

An interesting case of neurofibroma of face

Arjun Cukkemane, Vickey Katheria, Sreekar Harinatha

Department of Dermatology, M.V.J. Medical College & Research Hospital, Hoskote, Bangalore, India

Corresponding author: Dr. Arjun Cukkemane, e-mail: arjuncm226@gmail.com

Sir,

Neurofibromatosis or Von Recklinghausens disease is rare and found only in 1-4000 births.It is Autosomal Dominant, Involving chromosome 17. It is associated with pigmented spots (coffee coloured) in the skin, commonly seen on the back, abdomen and limbs (café au lait spots) [1].

A 45 years old female, presented with complains of Painless large swelling over right side of nose and upper lip (Fig. 1) since childhood. The swelling was present since childhood, was initially the size of a peanutand gradually progressed to the present size of a lemon. There was a gradual increase in size of the swelling. There was no pain associated with the swelling. She also complained of similar swellings all over the body (Fig. 2) and right nasal obstruction. patients father and brother have similar swellings all over the body. On examination a Single, large diffuse irregular swelling measuring 6 X 5 cms over the right alae of the nose extending to the upper lip and nasolabial fold, soft in consistency, non tender.

Multiple, nodular swellings seen all over the body (Fig. 3).

On ophthalmic examination, Lisch nodules were present over iris. No evidence of optic glioma on fundoscopy.

ENT Examination- Normal. A provisional diagnosis of Neurofibromatosis Type 1/Von Recklinghausens disease was made systemic examination was normal and all routine investigations were normal. Debulking was planned Incision was made along the edge of the swelling along the alae of the nose and the lip.Incision was deepened till Orbicularis Oris. Then entire swelling was elevated off the muscle.

Figure 1: Pre operation pic of lesion over nose.

Figure 2: Multiple macules and lesions over back typical of neurofibromatosis.

Another plane was created at sub-dermal level and skin was separated. The swelling was de-bulked and extra skin excised. Skin was re-draped, adjusted and sutured with ethilon 6-0 swelling was sent for histopathology (Fig 4). According to the report, Multiple sections studied show epidermis, dermis and

How to cite this article: Cukkemane A, Katheria V, Harinatha S. An interesting case of neurofibroma of face. Our Dermatol Online. 2016;7(4):479-481.
Submission: 04.02.2016; **Acceptance:** 27.07.2016
DOI: 10.7241/ourd.20164.131

Figure 3: Swelling over left limb wid deformity.

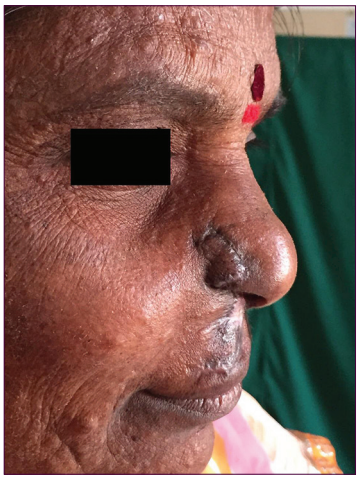

Figure 4: Post operation pic after excision and plastic reconstruction.

an ill circumscribed tumour. Epidermis shows mild hyperkeratosis, acanthosis and pigment incontinence in the upper dermis. Lower dermis shows an ill circumscribed tumour composed of bundles and nodules of spindle cells having spindle shaped to wavy nucleus amidst which are seen one prominent blood vessels with inflammatory cell infiltrate. Borders show infiltration into the adjacent fibro adipose tissue and muscle bundles (Fig 5).

Impression-Excised swelling shows diffuse neurofibroma.

Neurofibromatosis or von Recklinghausens disease is rare and found in1-4000 births. It is autosomal dominant, involving chromosome 17. It is associated with pigmented spots (coffee coloured) in the skin, commonly seen on the back, abdomen and limbs (café au lait spots). Axillary freckling and lisch nodules may be present [1,2].

Diagnostic criteria include two or more of the following [2,3]:

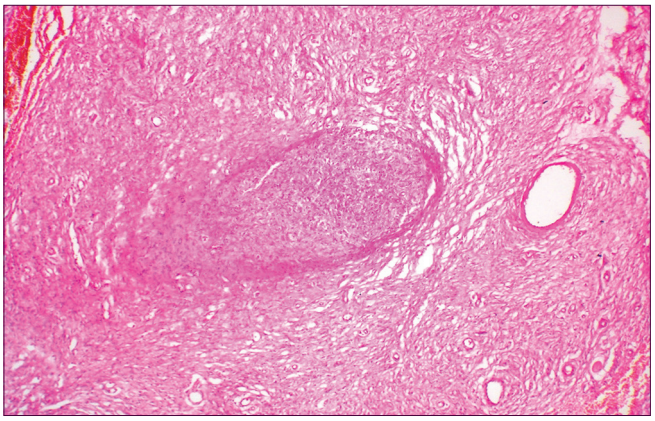

Figure 5: Microscopic appearance of excised specimen.

Six or more café-au-lait spots 1.5 cm or larger in post-pubertal individuals, 0.5 cm or larger in pre-pubertal individuals.

Two or more neurofibromas of any type or one or more plexiform neurofibroma.

Freckling in the axilla or groin.

Optic glioma (tumor of the optic pathway).

Two or more Lisch nodules (benign iris hamartomas).

A distinctive bony lesion: Dysplasia of the sphenoid bone or dysplasia or thinning of long bone cortex.

A first-degree relative with NF1.

It may be associated with MEN type 2 (multiple neurofibromatosis of eyelid, lips and face, medullary carcinoma of thyroid, pheochromocytoma and hyperparathyroidism.

Complications include -sarcomatous changes (5%), cystic degeneration, haemorrhage into the tissues, muscle atrophy [4,5].

Treatment – Excision/Debulking.

The patient described here is a very typical case of NF-1 which presents a considerable interest because of the high generalization of the skin lesion. In such cases, a detailed patient investigation is required,because of the possibility for generalized involvement of other organs. The proper clinical and genealogic analysis is important for the determination of genetic risk and prognosis for relatives of proband. The treatment of such kind of patient is surgical,

seeking to achieve cosmetic improvement and may be only palliative.

REFERENCES

1. El Bouihi M, Lahmiti S, Aimadeddine S, Zaroual A, Fawzi S, Hattab NM. A columellar deformity caused by a congenital schwannoma. Our Dermatol Online. 2013;4:224-5.
2. Chang P, Meaux T, Calderon G. Solitary Neurofibroma. Our Dermatol Online. 2015;6:362-4.
3. Hassan I, Keen A, Shah PA. Facial Plexiform neurofibromatosis in a patient with neurofibromatosis type 1: a case report. Our Dermatol Online. 2012;3:24-7.
4. Lubinska M, Sworczak K. Pheochromocytoma and paraganglioma: an overview. OncoReview. 2014;4:A18-A25.
5. Walker JA, Bernards A. A Drosophila screen identifies neurofibromatosis-1 genetic modifiers involved in systemic and synaptic growth. Rare Dis. 2014;2:e28341.

Copyright by Sreekar Harinatha, et al. This is an open access article distributed under the terms of the Creative Commons Attribution License, which permits unrestricted use, distribution, and reproduction in any medium, provided the original author and source are credited.

Source of Support: Nil, **Conflict of Interest:** None declared.

Letter to the Editor

Molusco contagioso y SIDA [AIDS and molluscum contagiosum]

Patricia Chang, Edlin Mayté Lizama Auyón

Department of Dermatology, Hospital General de Enfermedades IGSS and Hospital Ángeles, Guatemala

Corresponding author: Dr. Patricia Chang, E-mail: pchang2622@gmail.com

Sir,

Paciente masculino 57 años de edad hospitalizado por un cuadro diarreico sin ningún antecedente familiar de importancia de reciente diagnóstico de infección VIH que es enviado en interconsulta al Servicio de Dermatología por presentar una dermatosis localizada a la cara con predominio en la frente constituida por numerosas neoformaciones blanquecinas de diferentes tamaño algunas umbilicadas (Fig. 1) a la dermatoscopía se observa una lesión blanquecina polilobullida (Fig. 2). Resto del examen dentro de límites normales. Al momento de su diagnóstico el conteo de CD4 fue de 99, carga viral.

Se hace el diagnóstico clínico de moluscos contagiosos se le realiza biopsia de una de las lesiones, la cual mostro los característicos cuerpos del molusco llamados de (Fig. 3).

Se inicio tratamiento con efavirenz 600 mg/día, trimetropin/sulfa 960 mg/d, fluconazol 150 mg/día, tenofovir 300 mg + emtricitabina 200 mg/d cada 24 horas,

El molusco contagioso o molusco sebáceo de Hebra, enfermedad benigna de la piel ocasionada por el virus del molusco contagioso (VMC) perteneciente a la familia de los poxviridae, virus DNA de doble cadena realiza su replicación en el citoplasma de los queratinocitos. En 1817 Bateman fue el pionero en describir la enfermedad, y en el año de 1841 Henderson y Paterson describieron por primera vez las inclusiones intracitoplasmáticas, las cuáles son llamadas por su nombre.

Es de distribución mundial, con una incidencia del 2-8% [1] afecta con mayor frecuencia a tres grupos principales: 1- la infancia con un pico de incidencia de 10-12 años de edad. 2- personas con actividad sexual, posicionándose como una enfermedad de transmisión sexual y 3- pacientes con alteraciones inmunitarias especialmente pacientes con VIH-SIDA donde se reporta una incidencia del 5 al 18% [2], se puede asociar con linfocitos TCD4 menor de 200 u/mL [3].

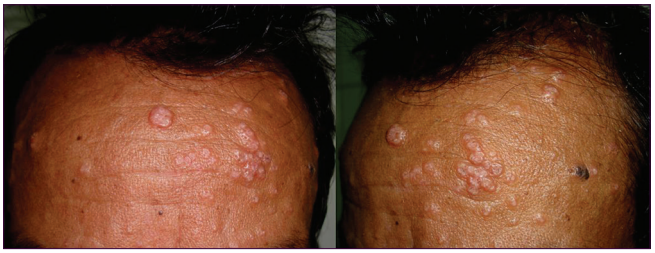

Figure 1: Múltiples moluscos contagiosos en región frontal.

Figure 2: Aspecto dermatoscópico de la lesión.

Hay 4 subtipos principales siendo: VMCI, VMCII, VMCII y VMCIV. Entre estos subtipos destacan el VMCI, con mayor prevalencia mundial (75-90%)

How to cite this article: Chang P, Lizama Auyón EM. Molusco contagioso y SIDA [AIDS and Molluscum Contagiosum]. Our Dermatol Online. 2016;7(4):482-484.
Submission: 25.02.2016; **Acceptance:** 18.04.2016
DOI:10.7241/ourd.20164.132

principalmente en niños; y el VMCII que predomina en pacientes VIH positivos.

En pacientes VIH-SIDA, esta virosis puede aparecer y exacerbarse luego de empezar la terapia antirretroviral, formando parte del síndrome de reconstitución inmunitaria y cuando el recuento de linfocitos TCD4 se encuentre en un rango menor de 100 u/mL [4]. En adultos la aparición del VMC requiere la evaluación del estado de inmunosupresión, ya que se manifiesta en fases avanzadas de la enfermedad, pero en niños rara vez se asocia con él. Se reporta un caso interesante de un niño de 2 años de edad con lesiones de VMC en nalgas. Se revela por prueba de ELISA estado de inmunosupresión intensa confirmando diagnóstico de VIH-SIDA con linfocitos TCD4 120 u/mL y carga viral 200.000 copias/mL [5].

Clínicamente las lesiones son pápulas o lesiones de aspecto nodular, esféricas, brillantes, firmes, elevadas e indoloras y su principal característica es ser umbilicadas en el centro; el color de las lesiones varía, y puede ser de color de la piel, blanca perlada, rosada, o amarilla, de 2 a 5mm de diámetro, y comúnmente los pacientes tienen 1 a 30 lesiones al mismo tiempo [6], se puede localizar en tronco, axilas y extremidades en niños, cara interna de muslos, piernas, abdomen, genitales y glúteos en pacientes infectados por vía sexual

En pacientes con VIH-SIDA la morfología de las lesiones es distinta, pueden ser numerosas (Figs. 4a-4c), grandes (Fig. 5) y si miden más de un centímetro se clasifican como molusco contagioso gigante [7]. Las lesiones suelen ser predominantemente en cara y cuello pero puede verse en cualquier otro sitio del cuerpo (Fig.6)

El diagnóstico es clínico la histopatología muestra la presencia los cuerpos de inclusión Henderson- Paterson [2].

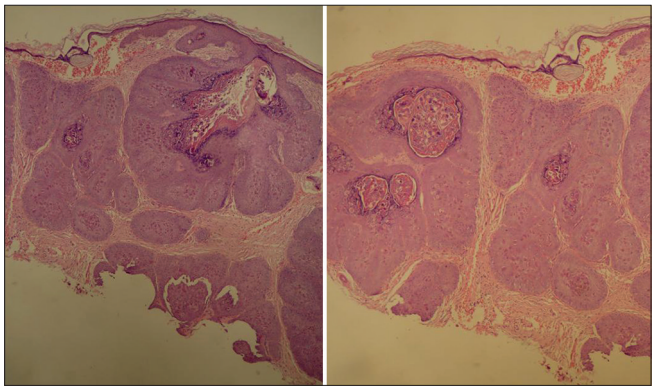

Figure 3: Cuerpos del molusco en biopsia de piel.

El diagnóstico diferencial debe hacerse con criptococosis, peniciliosis, histoplasmosis, granuloma piógeno, carcinoma basocelular nódulo quístico, carcinoma basocelular superficial, queratoacantoma, verrugas vulgares, hidrocistomas, siringomas, tricoepiteliomas, glándulas sebáceas ectópicas, xantoma eruptivo,

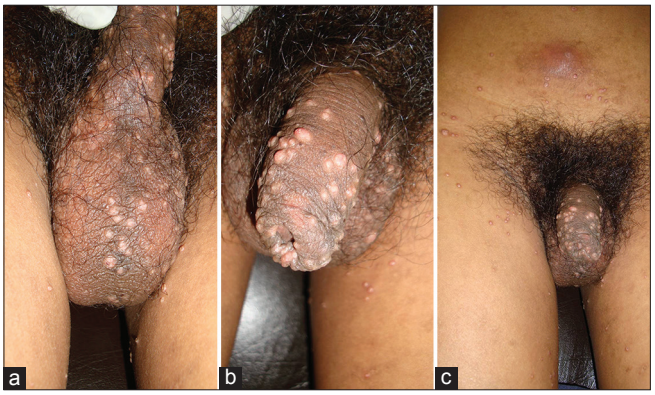

Figure 4: a-c Múltiples moluscos contagiosos en área genital.

Figure 5: Molusco contagioso grande.

Figure 6: Diferentes áreas de localización del molusco.

xantoma diseminado, foliculitis, hiperqueratosis folicular y quistes de millium [8]. Todos estos diferenciales han sido agrupados bajo el término de ''síndrome moluscoide'' [9].

Para el tratamiento se puede usar extracción, curetaje, crioterapia, podofilina, podofilotoxina, laser, hidróxido de potasio al 15%, cantaridina, electrodesecación e inmunomoduladores como: el imiquimod tópico al 5% el cual ha demostrado ser más eficaz que el ácido salicílico petrolato al 5% [10].

Ciertos antivirales como el ritonavir y especialmente el cidofovir, el cúal ha demostrado buenos resultados en pacientes con VIH-SIDA [9].

BIBLIOGRAFÍA

1. Garza R, Gonzáles S, Ocampo J. Manifestaciones cutáneas del VIH. Gac. Méd Méx. 2014;150:194-221.
2. Martínez M, Villena M, Villena A. Molluscum contagiosum. Rev Clín Med Fam. 2009;2:312-4.
3. Grisel L, Pérez S, Peralta M. Manifestaciones dermatológicas en los pacientes con VIH y su correlación con la cantidad de linfocitos CD4 en la clínica de infecciones de trasmisiónsexual del Centro Dermatológico Dr. Ladislao de la Pacua. Dermatol Rev Mex. 2014;58:3-9.
4. Drain P, Mosam A, Gounder L, Gosnell B, Manzini T, Moosa M. Recurrent giant molluscum contagiosum immune reconstitution inflammatory syndrome (IRIS) after initiation of antiretroviral therapy in a HIV-infected south african male. Int J STD AIDS. 2014;25:235-8.
5. Basu S, Kumar A. Giant Molluscum contagiosum - A clue to the diagnosis of Human Immunodeficiency infection. J Epidemiol Global Health. 2013;3:289-91.
6. Imali F, Pritchard J, Edwards S, Grover D. UK National Guideline for the management of Genital Molluscum in adults 2014. Clinical effectiveness group British Association for Sexual Health and HIV. Int J of STD & AIDS. 2015;26:687-95.
7. Loyo M, Zapata G, Santana G. Molusco contagioso. Evaluación de diversas modalidades terapéuticas. Dermatol Venez. 2003;41:25-8.
8. Vora R, Pilani A, Kota R. Extensive giant molluscum contagiosum in a HIV positive patient. J Clin Diag Res. 2015;9:1-2.
9. Aldama A, Acosta R, Pereira J, Arenas R. Síndrome moluscoide. Rev. Dermatología, cosmética, médica y quirúrgica. 2014;12:288-92.
10. Theiler M, Kempf W, Kerl K, French L, Hofbauer G. Disseminated molluscum contagiosum in a HIV-positive child. Improvement after therapy with 5% imiquimod. J Dermatol Case Rep. 2011;2:19-23.

Copyright by Patricia Chang, et al. This is an open access article distributed under the terms of the Creative Commons Attribution License, which permits unrestricted use, distribution, and reproduction in any medium, provided the original author and source are credited.

Source of Support: Nil, **Conflict of Interest:** None declared.

Letter to the Editor

Neurothekoma of the scalp

Olfa El Amine El Hadj[1], Leila Bouhajja[1], Aida Goucha[1], Jameleddine Ben Hassouna[2], Wafa Rekik[1], Ahmed El May[1], Amor Gamoudi[1]

[1]Department of Pathology, Carcinological Institute Salah Azaiez, Tunis, Tunisia, [2]Department of Carcinological Surgery, Carcinological Institute Salah Azaiez, Tunis, Tunisia

Corresponding author: Dr. Olfa El Amine El Hadj, E-mail: olfaelamine@yahoo.fr

Sir,

We report a 30 year-old woman with a history of lumpectomy for a benign breast tumor, presented with a 10-year history of an exophytic lesion of the scalp. The physical examination revealed a giant mass on the scalp, which was immobile, tender and exhibited distinct borders. A total excision of the lesion was performed. Grossly, the tumor was nodular, exophytic, and measured 19 cm of diameter. Histological examination showed a tumor consisting of spindle to epitheloid cells forming micro nodules in a concentric whorled shape pattern (Fig 1) embedded in abundant myxoïd stroma (Fig. 2). These features confirmed the diagnosis of a neurothekoma. At 3 years of follow-up, the patient was asymptomatic and there was no recurrence.

The patient's informed consent was obtained.

Prior to the study, patient gave written consent to the examination and biopsy after having been informed about the procedure.

Neurothekoma (NT) is an uncommon and benign dermal tumor, originating from the sheath of peripheral nerves. It is mainly located on the face, neck, arms and shoulders of young adults, and is more frequent in females [1,2].

Clinically, it manifests as an asymptomatic, pink-erythematous, dome-shaped, solitary papule or nodule, with a slow growth rate [2]. The clinical differential diagnosis of NT includes epidermal cyst, dermatofibroma, adnexal tumor (e.g. pilomatricoma), Fibrohistiocytic tumor, Basal cell carcinoma, hemangioma, amelanotic melanoma and cutaneous metastasis [2].

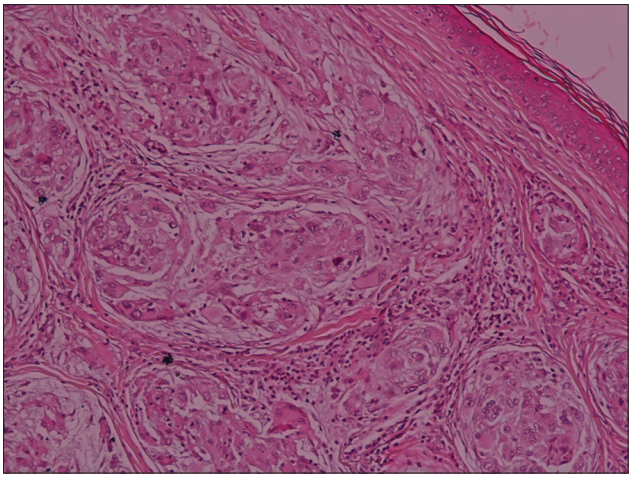

Figure 1: Subcutaneous layer containing whorls of regular fusiform cells.

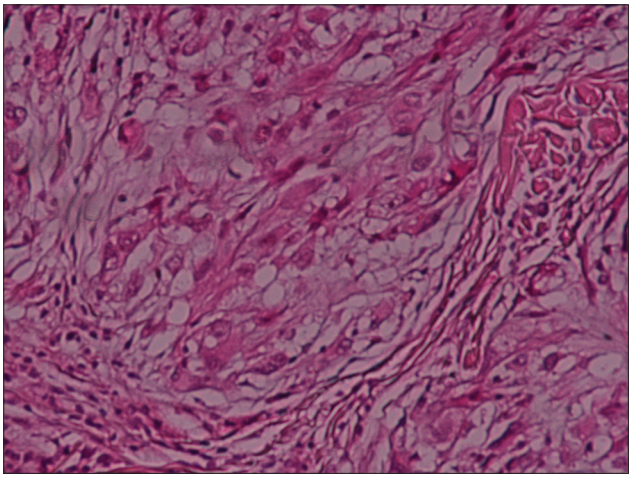

Figure 2: Epitheloid and fusiform cells embedded into a myoid stroma.

Histological examination shows the presence of spindle and epithelioid cells with abundant granular-eosinophilic cytoplasm and a tendency to be grouped in whorled nodules spared by collagen bundles in the dermis and subcutaneous area. There may be sclerotic

How to cite this article: El Hadj OE, Bouhajja L, Goucha A, Hassouna JB, Rekik W, El May A, Gamoudi A. Neurothekoma of the scalp. Our Dermatol Online. 2016;7(4):485-486.

Submission: 06.03.2016; **Acceptance:** 24.04.2016

DOI:10.7241/ourd.20164.133

collagen and osteoclast-like cells [3]. Furthermore, this tumor is subclassified histopathologically into 3 groups: myxoid, mixed, and cellular type depending on the amount of myxoid matrix [4]. Immunohistochemically, the S100 protein is useful to differenciate the myxoid type from the cellular type. The tumor cells of the cellular variant are not generally stained with markers for nerve-origin cells, but are positively stained with NKI/C3, Ki-M1p, and CD68 [4].

The histological differencial diagnosis includes melanocytic tumor variants (e.g. Spitz Nevus), neurofibroma, schwannoma or neuroma variants [2]. An atypical variant of NT has recently been described. It is described like a larger tumor (up to 6cm) of deep penetration (skeletal muscle and subcutaneous fat involvement), diffuse infiltrative borders, vascular invasion, a high mitotic index (>3 mitosis per 10 high power fields) and pleomorphism [5].

The real recurrence of NT is around 3%. Risk factors for recurrence are: myxoid type, being female, facial location, younger age at diagnosis, positive margins, and absence of fat-tissue in the sample [3].

CONCLUSION

Neurothekoma is a rare tumor. The diagnosis is based on histopathological and eventually immunohistichemical exam. The evolution is marked by the risk of recidive.

Consent

The examination of the patient was conducted according to the Declaration of Helsinki principles. Written informed consent was obtained from the patient for publication of this article

REFERENCES

1. Ding YI, Zou F, Peng W, Dai M, Gu H, Zhang B, et al. A giant neurothekeoma of the left shoulder blade: A case report Oncol Lett. 2016;11:1130-34.
2. Navarrete-Dechent C, Curi-Tuma M, Marín C, González S, Sandoval-Osses M. Cellular neurothekeoma: case report and its relation with nerve sheath myxoma An Bras Dermatol. 2015;90:156-59.
3. Fetsch JF, Laskin WB, Hallman JR, Lupton GP, Miettinen M. Neurothekeoma: an analysis of 178 tumors with detailed immunohistochemical data and long-term patient follow-up information. Am J Surg Pathol. 2007;31:1103-14.
4. Yun SJ, Park HS, Lee JB, Kim SJ, Lee SC, Won YH. Myxoid Cellular Neurothekeoma: A New Entity of S100-Negative, CD68-Positive Myxoid Neurothekeoma. Ann Dermatol. 2014;26:510-13.
5. Campanati A, Brandozzi G, Sisti S, Bernardini ML, Offidani AM. Atypical neurothekeoma: a new case and review of the literature. J Cutan Pathol. 2007;34:435-37.

Copyright by Olfa El Amine El Hadj, et al. This is an open access article distributed under the terms of the Creative Commons Attribution License, which permits unrestricted use, distribution, and reproduction in any medium, provided the original author and source are credited.

Source of Support: Nil, **Conflict of Interest:** None declared.

Letter to the Editor

Calcifying fibrous tumor of axillary region

Olfa El Amine El Hadj[1], Leila Bouhajja[1], Aida Goucha[1], Jameleddine Ben Hassouna[2], Ahmed El May[1], Amor Gamoudi[1]

[1]Department of Pathology, Carcinological Institute Salah Azaiez, Tunis, Tunisia, [2]Department of Carcinological Surgery, Carcinological Institute Salah Azaiez, Tunis, Tunisia

Corresponding author: Dr. Olfa El Amine El Hadj, E-mail: olfaelamine@yahoo.fr

Sir,

We report a 17 year-old woman who presented with a 1-year history of left axillary palpable mass. At physical examination the lesion was firm, lipomatous. The breast ultrasonography showed a left voluminous axillary mass, measuring 54mm, hyperechoic and ill limited. A surgical resection of the mass was performed. Grossly, it was a white firm well-circumscribed and lobed mass measuring 15x10x6 cm. Histological examination showed a benign mesenchymal tumor. It consisted of abundant fibrosis with hyalinised vessels, containing mononuclear infiltrate and foci of psammomatous calcifications (Fig. 1). Lymphoid follicles were noted around vessels and psammomas (Fig. 2). The tumor did not show any features of malignancy. Immunohistochemically, the spindle cells were vimentin positive (Fig. 3) and vessels showed CD34 positivity. These features confirmed the diagnosis of Calcifying fibrous tumors. At 4 years of follow-up, the patient was asymptomatic and there was no recurrence.

The patient's informed consent was obtained.

Prior to the study, patient gave written consent to the examination and biopsy after having been informed about the procedure.

Calcifying fibrous tumor (CFT) is a rare, usually solitary, benign tumor of uncertain etiology. The most common sites are the soft tissues of the extremities, pleura, or peritoneum [1]. It usually affects children and young adults, and it is composed of hyalinized fibrous tissue with dispersed bland fibroblastic spindled cells, scattered psammomatous, and/or dystrophic calcifications, and variably prominent mononuclear inflammatory infiltrate [2]. Macroscopically, CFT is

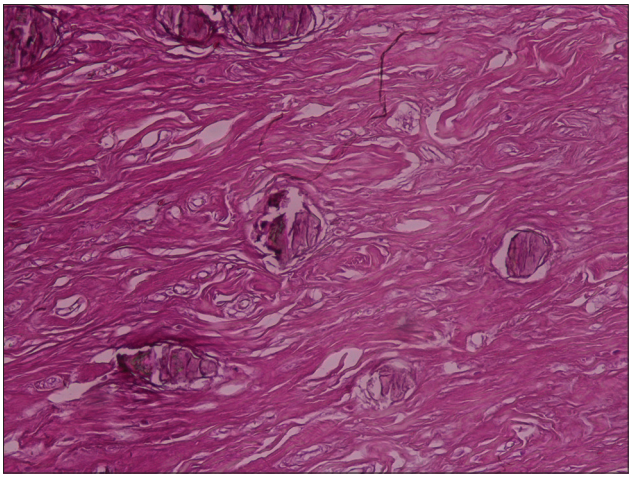

Figure 1: Tumor composed of abundant fibrosis with hyalinised vessels, containing mononuclear infiltrate and foci of psammomatous calcifications.

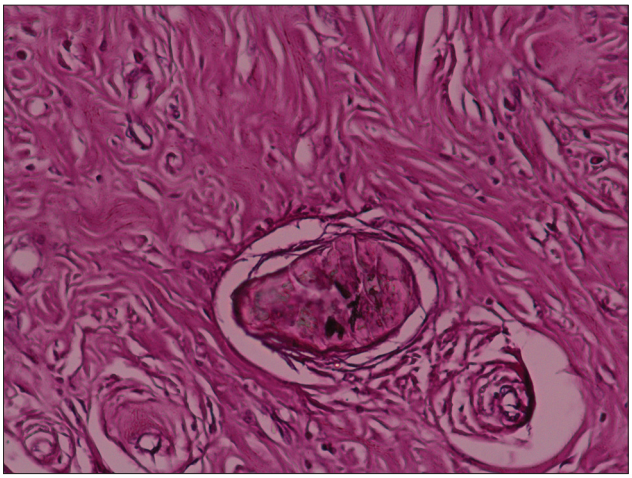

Figure 2: Lymphoid follicles were noted around vessels and psammomas.

How to cite this article: El Hadj OE, Bouhajja L, Goucha A, Hassouna JB, El May A, Gamoudi A. Calcifying fibrous tumor of axillary region. Our Dermatol Online. 2016;7(4):487-488.

Submission: 05.03.2016; **Acceptance:** 25.04.2016

DOI:10.7241/ourd.20164.134

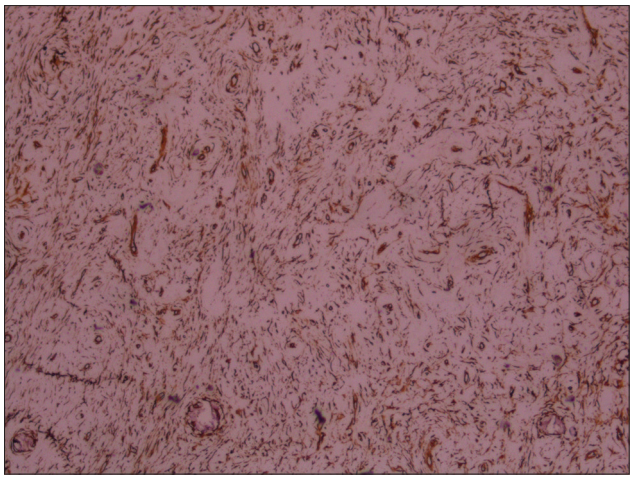

Figure 3: Spindle cells showing strong expression of vimentin.

well circumscribed and unencapsulated. Its diameter ranges from 1 to 15 cm. Their etiopathogenesis has not been fully clarified yet. However, in the literature, there are cases that may be related to trauma and Castleman's disease [3]. Resection of CFT is usually curative. Local recurrence rate is approximately 10% [1].

Consent

The examination of the patient was conducted according to the Declaration of Helsinki principles. Written informed consent was obtained from the patient for publication of this article.

REFERENCES

1. Giardino AA, Ramaiya NH, Shinagare AB, Jagannathan JP, Stachler MD, Raut CP. Case report: Calcifying fibrous tumor presenting as an asymptomatic pelvic mass. Indian J Radiol Imaging. 2011;21:306-8.
2. Jang KY, Park HS, Moon WS, Lee H, Kim CY. Calcifying fibrous tumor of the stomach: A case report. J Korean Surg Soc. 2012;83:56-9.
3. Gamsizkan M, Yildirim C, Daş K, Günhan Ö. Calcifying Fibrous Tumor: A Case Report Turk Patoloji Derg. 2015;31:141-4.

Copyright by Olfa El Amine El Hadj, et al. This is an open access article distributed under the terms of the Creative Commons Attribution License, which permits unrestricted use, distribution, and reproduction in any medium, provided the original author and source are credited.
Source of Support: Nil, **Conflict of Interest:** None declared.

Letter to the Editor

A rare clinic type of angiokeratoma: angiokeratoma circumscriptum naeviforme

Esra Arı[1], Seray Külcü Çakmak[1], Ayşe Yılmaz Çiftçi[2], Emine Tamer[1], Ferda Artüz[1]

[1]*Department of Dermatology, Ankara Numune Education and Research Hospital, Ankara, Turkey,*
[2]*Department of Patology, Ankara Numune Education and Research Hospital, Ankara, Turkey*

Corresponding author: Dr. Esra Arı, E-mail: esra88ari@hotmail.com

Sir,

Angiokeratomas are verrucous, hyperkeratotic, red-black, well-demarcated papules and plaques consisting of vascular enlargement and hyperkeratosis [1]. Five different clinical variants of angiokeratoma have been identifined including angiokeratoma corporis diffusum (Fabry's disease), angiokeratoma Mibelli, angiokeratoma Fordyce, angiokeratoma circumscriptum, solitary and multiple angiokeratomas [2]. Angiokeratoma circumscriptum naeviforme, is a rare clinic type of angiokeratomas [1]. We report here a case of angiokeratoma circumscriptum naeviforme, on the lower extremity of a male patient.

A 43-year-old man presented with a red-black lineer eruption on his left leg which had been present since infancy. He gave a history of several episodes of mild bleeding from the lesions after minor trauma. There were no other local or systemic symptoms. There was no history of similar disease in his family. Dermatological examination revealed hyperkeratotic papules over dark red-black plaques on his gluteus, thigh and calf extending to the dorsum of the foot following the lines of Blaschko (Fig. 1). On the lateral part of the thigh, there were purpuric, red-black patches and on the medial part of the pretibial region there were verrucous, well-circumscribed nodules and linear plaques (Figs. 2 and 3). Both lower extremities were equal in length and diameter. No pulsation was detected by palpation of the lesions. Skin biopsy revealed hyperkeratosis and acanthosis of the stratified squamous epithelium, congestion and dilated vascular structures in papillary dermis (Fig. 4). Based on clinical and histopathological features, the diagnosis of angiokeratoma circumscriptum naeviforme was made. The patient did not accept further investigation and therapy.

Figure 1: Hyperkeratotic papules over dark red-black plaques on the left gluteal region.

Figure 2: The verrucous nodule and hyperkeratotic patches on the pretibial region.

How to cite this article: Arı E, Çakmak SK, Çiftçi AY, Tamer E, Artüz F. A rare clinic type of angiokeratoma: angiokeratoma circumscriptum naeviforme. Our Dermatol Online. 2016;7(4):489-491.

Submission: 01.02.2016; **Acceptance:** 10.06.2016

DOI: 10.7241/ourd.20164.135

© Our Dermatol Online .2016

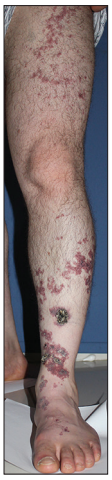

Figure 3: The lesions extending from left glutea to dorsum of the foot following the lines of Blaschko.

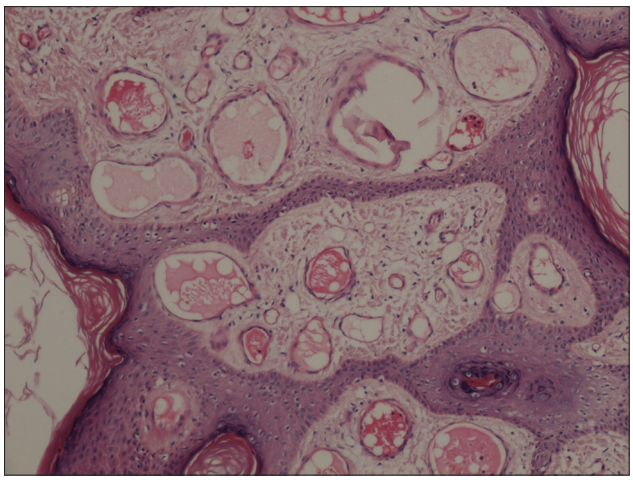

Figure 4: Hyperkeratosis and acanthosis of the stratified squamous epithelium, congestion in the papillary dermis and dilated vascular structures (HE × 100).

Angiokeratoma sircumscriptum naeviforme is the rarest reported type of angiokeratomas. The lesions of angiokeratoma sircumscriptum neviforme are typically present since birth or infancy. Women are affected more commenly than men [1]. The lesions are located unilaterally on the lower site of legs or feet, but may occur on the thighs, buttocks or sometimes elsewhere. They can be varying in color from dark-red to blue-black [2]. The lesions are macular and in time can turn into warty keratotic well-circumscribed papules or nodules [3]. They tend to take a zosteriform configuration or segmental layout pattern [4]. Our patient had extensive lesions extending from left glutea to dorsum of the foot following the lines of Blaschko.

Although different in terms of appearance and layout, morphological variants of angiokeratoma are histologically similar [5,6]. Histologically, the overlying epidermis shows compact hyperkeratosis, acanthosis and papillamatosis and dilated capillaries are found in the papillary dermis. There is no involvement of the deep dermis and subcutaneus tissue [2,5].

Although the exact reason of the formation of angiokeratomas are unknown, several causal factors, such as congenital development, pregnancy, trauma, subcutaneous hematomas, and tissue asphyxia, have all been proposed [7]. The main pathogenetic mechanism is, ectatic dilatation of capillaries in the papillary dermis with resultant secondary epidermal changes of hyperkeratosis, acanthosis [5]. Nevoid malformation of the underlying vascular network is thought to be the main cause of angiokeratoma circumscriptum neviforme [1]. The lesions may be associated with underlying vascular malformation,atrophy or hypertrophy of soft tissue and bone [6]. In our patient we could not perform imaging studies as the patient didn't accept further examination.

Our main differential diagnosis of the case was verrucous hemangioma. Verrucous hemangioma is a congenital, localized vascular malformation. Histopathologically, it is characterized by dilated capillaries and red blood cell-filled spaces extending well into the reticular dermis and subcutaneous tissue with an overlying hyperkeratotic epidermis [8].

There is no tendency of spontaneous regression in angiokeratoma sircumscriptum naeviforme. Patients may require the removal of the lesions for cosmetics reasons. Smaller lesions may be managed by diathermy, electrocautery, cryosurgery, currettage and surgery. Laser ablation [carbon dioxide or argon laser] may be used for larger lesions which are not suitable for surgery [3].

We reported here a case with congenital, linear, unilateral, verrucous plaques on the lower extremity, diagnosed as angiokeratoma circumscriptum neviforme. We report this case due to its rarity and want to emphasize that, in spite of its rarity, anigokeratoma circumscriptum should be considered in the differential diagnosis of linear verrucous lesions.

REFERENCES

1. Sardana K, Koranne RV, Sharma RC, Mahajan S. Angiokeratoma circumscriptum naeviforme: rare presentation on the neck. Australas J Dermatol. 2001;42:294-5.
2. Atherton DJ. Naevi and other developmental defects. In: Champion RH, Burton JL, Ebling FJG, eds. Textbook of

Dermatology, 5th edn. Oxford: Blackwell Science Ltd,1992:504.
3. del Pozo J, Fonseca E. Angiokeratoma circumscriptum naeviforme: successful treatment with carbon-dioxide laser vaporization. Dermatol Surg. 2005;31:232-6.
4. Requena L, Sangueza OP. Cutaneus vascular anomalies. PartI. Hamartomas, malformations, and dilatation of preexisting vessels. J Am Acad Dermatol. 1997;37:523-49.
5. Imperial R, Helwing EB, Angiokeratoma. A clinicopathological study. ArchDermatol. 1967;95:166-74.
6. Mittal R, Aggarwal A, Srivastava G. Angiokeratoma Circumscriptum: a case report and review of the literature. Int J Dermatol. 2005;44:1031-4.
7. Das A, Mondal AK. Angiokeratoma circumscriptum neviforme: an entity, few and far between. Indian Dermatol Online J. 2014;5:472-4.
8. Calonje E. Vascular Tumors: tumors and tumor-like conditions of blood vessels and lymphatics. In: Elder DE, Elenitsas R, Johnson BL, Murphy GF, Xu X, editors. Lever's Histopathology of Skin. 10th ed. Philadelphia: Lippincott Williams and Wilkins publishers; 2009. p. 101.

Copyright by Esra Arı, et al. This is an open access article distributed under the terms of the Creative Commons Attribution License, which permits unrestricted use, distribution, and reproduction in any medium, provided the original author and source are credited.

Source of Support: Nil, **Conflict of Interest:** None declared.

Letter to the Editor

An epidermal cyst mimicking a breast tumor in a male patient: A case report

Mehmet Eren Yuksel[1], Funda Tamer[2]

[1]Department of General Surgery, Devrek State Hospital, Zonguldak, Turkey, [2]Department of Dermatology, Turgut Ozal University School of Medicine, Ankara, Turkey

Corresponding author: Dr. Funda Tamer, E-mail: fundatmr@yahoo.com

Dear Editor,

A 61-year-old Caucasian male presented with a breast lump for futher clinical evaluation. The patient admitted that the slowly growing mass had been present for a year. The lesion was asymptomatic, however the patient was concerned about the risk of malignancy. The past medical history and family history were both unremarkable. The physical examination of the patient revealed a skin coloured, well-defined, firm, subcutaneous nodule with a punctum and telangiectasias on the surface (Fig. 1). The lesion was located on the trunk, laterally to the right areola measuring 3x2.5 cm. There was no axillary lymphadenopathy. The lesion was surgically removed without any complications (Fig. 2). The histopathological examination of the specimen revealed an epidermal cyst.

Figure 1: A skin coloured, well-defined, firm, subcutaneous nodule with a punctum and telangiectasias on the surface.

Figure 2: Intraoperative view of the cyst, keratin content is draining through the elliptical incision.

An epidermal cyst is a benign lesion which consists of lamellated keratin. The etiology of an epidermal cyst remains unknown. However, it can be congenital or it can occur due to obstruction of hair follicles and trauma as a result of implantation of epidermis into the dermis. An epidermal cyst usually presents as a small, subcutaneous papule or nodule on the head, neck, trunk and extremities [1]. An epidermal cyst is rare in the breast, however it should be considered in differential diagnosis of benign and malignant breast tumors. A few cases of epidermal cyst in the breast have been reported previously. Taira et al. reported a 85-year-old woman with an epidermal cyst measuring 3x2 cm in the right breast and a 45-year-old woman with an epidermal cyst measuring 9x8 cm in the left breast [2]. Lee et al. reported a 47-year-old female with an epidermal cyst measuring 7x6 cm which mimicked a large fibroadenoma or phyllodes tumor [1]. Martin et al. reported a 42-year-old female with an epidermal

How to cite this article: Yuksel ME, Tamer F. An epidermal cyst mimicking a breast tumor in a male patient: A case report. Our Dermatol Online. 2016;7(4):492-493.
Submission: 07.04.2016; **Acceptance:** 13.06.2016
DOI:10.7241/ourd.20164.136

cyst of 3.8 cm in size in the subareolar area of the right breast mimicking malignancy [3]. Gupta et al. reported a 32-year-old male with an epidermal cyst of 10x10 cm in size which slowly grew in 5 years [4].

Presentation of an epidermal cyst as a breast lump in a male patient is an unusual condition [4]. To the best of our knowledge, only 8 male patients with epidermal cysts of the breast have been reported in the English literature [5]. Epidermal cyst of the breast in a male patient should be differentiated from benign and malignant lesions such as gynecomastia, lipoma, intraductal papilloma, subareolar abscess, hematoma, fibroadenoma, invasive ductal carcinoma, papillary carcinoma and primary lymphoma of the breast. Furthermore, an epidermal cyst can undergo malignant transformation in the form of squamous cell carcinoma, basal cell carcinoma, mycosis fungoides, and melanoma [4]. Moreover, Paliotta et al. suggested that malignant transformation might occur more frequently in epidermal cysts of the breast compared to epidermal cysts occuring in the other parts of the body [5]. Hence, histopathological examination is mandatory to reach a definitive diagnosis and to exclude malignancy. Therefore, surgical removal of an epidermal cyst is highly recommended [4].

REFERENCES

1. Lee YA, Park SG. Giant sized epidermal inclusion cyst of the breast initially mimicking a large fibroadenoma or phyllodes tumor. J Korean Surg Soc. 2012;83:107-10.
2. Taira N, Aogi K, Ohsumi S, Takashima S, Kawamura S, Nishimura R. Epidermal inclusion cyst of the breast. Breast Cancer. 2007;14:434-7.
3. Martin C, Bombard T, Coker M, Payne E, Yoxtheimer ML, Elsamaloty H. Rare case of benign epidermal inclusion cyst mimicking malignancy. Appl Radiol. 2016;45:34-6.
4. Gupta R, Paul R, Sharma SB. Giant epidermoid cyst presenting as breast lump in male. Sch J App Med Sci. 2014;2:1869-73.
5. Paliotta A, Sapienza P, D'Ermo G, Cerone G, Pedullà G, Crocetti D, et al. Epidermal inclusion cyst of the breast: A literature review. Oncol Lett. 2016;11:657-60.

Copyright by Mehmet Eren Yuksel, et al. This is an open access article distributed under the terms of the Creative Commons Attribution License, which permits unrestricted use, distribution, and reproduction in any medium, provided the original author and source are credited.

Source of Support: Nil, **Conflict of Interest:** None declared.

Letter to the Editor

Herpes zoster in patients with systemic lupus erythematosus

Maria Bibiana Leroux

Centro de Referencia en Raynaud y Colagenopatías, Rosario, Argentina

Corresponding author: Dra. Maria Bibiana Leroux, E-mail: leroux_mb@hotmail.com

Sir,

The onset of cutaneous herpes zoster (HZ) is due to a reactivation of the varicella zoster virus and it is characterized by a painful vesicular eruption following one or more dermatomes. Post herpetic neuralgia, the most common complication could develop persisting during months or even years. The HZ it is considered the most frequent viral etiology affecting patients with systemic lupus erythematosus (SLE).

Recently, Borda et al. describe the epidemiological characteristics of HZ in a Brazilian population affected with SLE. Fifty five episodes of HZ were reported in 51 patients. The onset of most of them was 5 years after the SLE diagnosis and frequently during inactive or mild activity. The majority of patients show a typical distribution and a good response to treatment. Nevertheless, complications such as secondary bacterial infection and post herpetic neuralgia could be present [1-3].

INCIDENCE

The HZ incidence is 1.2 - 4.9/1000 affected individuals annually. In SLE patients is significantly higher reaching 16-22/1000 annually. It is to be noticed that is associated with abnormal cytotoxicity mediated by T cells and aggravated by treatment with corticoids and immunosuppressant [1,2,4,5]. Infection risk factors in patients with SLE in Table I. .

CLINICS

The classic HZ topography is in general unilateral affecting one dermatome, although 20% of patients could be extended to 3 contiguous dermatomes. Some authors classify this pattern as a disseminated HZ (Figs. 1a and b). A varicelliform eruption could be present in non selected patients and most frequently in immunocompromised ones. In cutaneous disseminated high risk patients visceral compromise i.e. disseminated intravascular clotting, encephalitis,

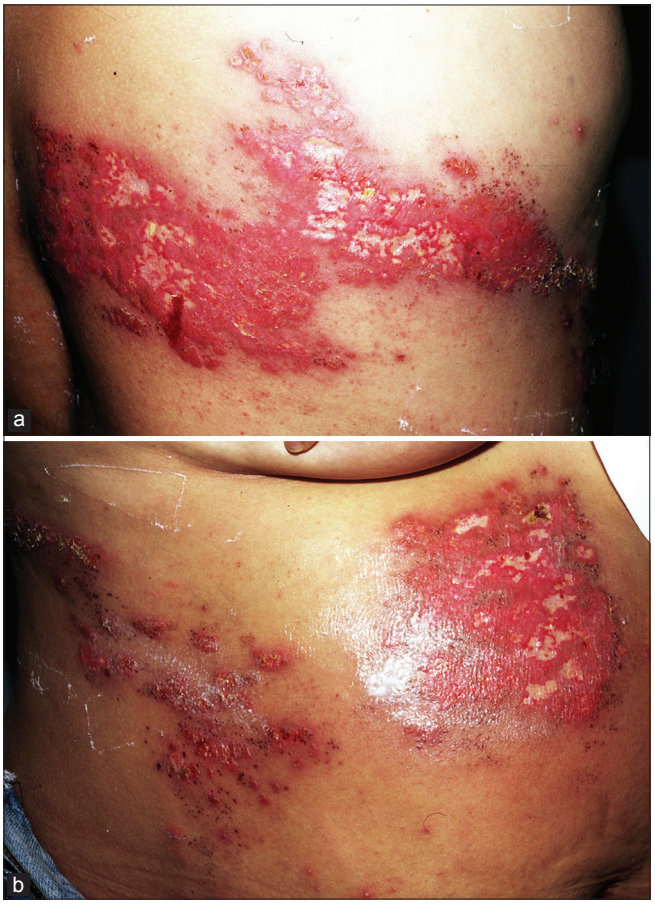

Figure 1a and b: Patient with systemic lupus erythematosus and severe disseminated herpes zoster in the body affecting three dermatomes. (T 7-8-9). a- Back. b- Trunk forehead.

How to cite this article: Leroux MB. Herpes zoster in patients with systemic lupus erythematosus. Our Dermatol Online. 2016;7(4):494-495.
Submission: 15.03.2016; **Acceptance:** 16.05.2016
DOI:10.7241/ourd.20164.137

hepatitis, neumonitis and pancreatitis among others could complicate [4,5].

Diagnostic methodology shown in Table 2 [1-6].

TREATMENT

It is strongly recommended to initiate antiviral treatment within 72 hours of rash onset. The drugs above mentioned shall be maintained for 7-10 days and for 2 days after all the lesions are covered by a crust (Tabl. 3) [1-4].

Primary medications for acute zoster–associated pain include: analgesics, neuro active and anticonvulsant agents. Prompt treatment of acute zoster and its associated pain can prevent the development of post herpetic neuralgia. Hospital admission should be considered in these cases: severe symptoms, immunosuppression, significant bacterial super infection, disseminated herpes zoster, ophthalmic involvement or meningoencephalopathy involvement [1-4,6,7].

Table 1: Infection risk factors in patients with systemic lupus erythematosus

Disease activity	Anti Sm DNA high titers
LES Nephritis	Low Complement levels
Hemolytic Anemia	Thrombocytopenia
Leucopenia	Antiphospholipid antibodies
Prednisone doses higher than 10 mg/d	Cyclophosphamid
Corticoids high pulse doses	Azathioprine
Micophenolate mofetil	Neoplasia history or present one actual

Table 2: Diagnostic methodology in herpes zoster

- Tzanck test
- Serology
  - IgM antibodies by Elisa Kit/recent infection
  - IgG antibodies /previous contact

  High antibodies titers could be detected HZ in its early onset
  - Viral antigens by immunofluorescence
- PCR detection of viral DNA in vesicles aqueous solutions or in cerebrospinal fluid.

It is to take into account that the serological response could be altered in immunodeprived patients.
Viral cultures are not a common daily practice.

Table 3: Treatment with antiviral drugs

1. Aciclovir	800 mg 5 times orally 10mg/kg IV / every 8 hours
2. Famciclovir	500 mg every 8 hours orally during 10 days
3. Valaciclovir	1000 mg/8 hours orally
4. Brivudina	125 mg/6 hours orally

In case of patients with renal insufficiency drugs 1-2-3 doses must be adjusted.
Drugs 2 and 3 have an easier dosing.
In case of resistance foscarnet 60 mg/kg/12 hours IV is recommended.

VACCINATION

It was introduced in 2006. It is a live attenuated vaccine recommended for 60 years old patients comporting a reactivation risk. In these individuals a diminished HZ incidence (50%) as well as post herpetic neuralgia has been observed (60%).There is no clear evidence to recommend HZ vaccine in patients with SLE. There are researchers that propose that the same rule could be applied to the general population but only in those that are not medicated with immunosupressors before of after vaccination [6-7].

CONCLUSION

Herpes zoster can be a serious problem in systemic lupus erythematosus. Its complications and its antiviral treatment are known, however, the indication of the vaccine to prevent it is not recommended in all patients.

REFERENCES

1. Chen H-H, Chen Y-M, Chen T-J, Lan J-L, Lin C-H, Chen D-Y. Risk of herpes zoster in patients with systemic lupus erythematosus: a three-year follow-up study using a nationwide population-based cohort. Clinics. 2011;66:1177-82.
2. Navarra SV, Leynes MSN. Infections in systemic lupus erythematosus. Lupus. 2010;19:1419-24.
3. Danza A, Ruiz-Irastorza G. Infection risk in systemic lupus erythematosus patients: susceptibility factors and preventive strategies. Lupus. 2013;22:1286-94.
4. Ruiz-Irastorza G, Olivares N, Ruiz-Arruza I, Martinez-Berriotxoa A, Egurbide MV, Aguirre C. Predictors of major infections in systemic lupus erythematosus. Arthritis Res Ther. 2009;11:R109.
5. Tektonidou MG, Wang H, Dasgupta A, Ward MM. Burden of Serious Infections in Adults With Systemic Lupus Erythematosus: A National Population-Based Study, 1996– 2011. Arthritis Care Res (Hoboken). 2015;67:1078-85.
6. Pasoto SG, Ribeiro ACM, Bonfa E. Update on infections and vaccinations in systemic lupus erythematosus and Sjogren's syndrome. Curr Opin Rheumatol. 2014;26:528-37.
7. Barbera C, Goldb WL, Fortin PR. Infections in the lupus patient: perspectives on prevention. Curr Opin Rheumatol. 2011;23:358-65.

Copyright by Maria Bibiana Leroux. This is an open access article distributed under the terms of the Creative Commons Attribution License, which permits unrestricted use, distribution, and reproduction in any medium, provided the original author and source are credited.
Source of Support: Nil, **Conflict of Interest:** None declared.



Our Dermatology Online

www.odermatol.com

4.2016 (10.October.2016)